Acute Epiglottitis

58

Definition

It is an inflammation of the epiglottis and adjacent supraglottic structures. It is primarily due to infection. Epiglottitis can progress to life-threatening airway obstruction, if not treated.

Epidemiology

After the introduction of the *Haemophilus influenzae* vaccine, epiglottitis has mostly become a disease seen in the adult population. The annual incidence in children is as low as two cases per 10 million populations. The prevalence has shifted to school-age children and adolescents rather than preschool children.

Etiology

Most frequently caused by infectious agents. Bacteria were most common among them **(Table 1)**.

TABLE 1: Etiology of acute epiglottitis.

Bacterial	***Viral***
Immunocompetent	
Haemophilus influenzae (primarily in unvaccinated or incompletely immunized children)	Influenza type a and b
Staphylococcus aureus	Parainfluenza virus
Streptococcus pneumoniae	HSV
Streptococcus pyogenes	EBV
Neisseria meningitidis	HIV
Pasteurella multocida	SARS-CoV-2
Immunocompromised	
Pseudomonas aeruginosa	***Fungal***
Serratia species	*Candida* species
Enterobacter species and anaerobic flora	*Histoplasma capsulatum*

(EBV: Epstein–Barr virus; HIV: human immunodeficiency virus; HSV: herpes simplex virus; SARS-CoV-2: severe acute respiratory syndrome coronavirus 2)

Noninfectious Causes: (Rare)

Noninfectious causes are presented in **Box 1**.

BOX 1: Noninfectious causes.

- ☑ Inhalation injury from heat, smoke, or chemical irritants
- ☑ Thermal injury from ingestion of hot beverages or food
- ☑ Direct trauma to the epiglottis
- ☑ Caustic ingestion or inhalation
- ☑ Lymphoproliferative disease or graft-versus-host disease after bone marrow or solid organ transplantation
- ☑ Chronic granulomatous disorders

Pathogenesis

Swelling of the epiglottis results from inflammatory edema in the potential space created by the loosely attached squamous epithelial layer and the epiglottal cartilage, which can progress rapidly.

Mechanisms of Airflow Obstruction

- ☑ Reduced caliber of the upper airway by swelling causing turbulent flow.
- ☑ Posterior and inferior curling of the epiglottis, acting as a ball valve.

Clinical Features

Clinical features are presented in **Table 2**.

TABLE 2: Clinical features.

Young children (<6 years of age) (Hib) epiglottitis	*Older children and adolescents*
☑ Acute rapidly progressive and potentially fulminating course of high fever, sore throat, dyspnea, and rapidly progressing respiratory obstruction ☑ Within hours, the patient appears toxic, swallowing is difficult, and breathing is labored ☑ Stridor and drooling is often present ☑ Cough is typically absent ☑ Characteristic "tripod" or "sniffing" posture* ☑ They may be reluctant to lie down	☑ Low-grade fever with progressively painful sore throat ☑ Can lead to severe sore throat, dysphagia, and drooling ☑ Relatively normal oropharyngeal examination ☑ Minimal respiratory distress

*Tripod posture (sitting position with the trunk leaning forward, neck hyperextended, and chin thrust forward in an effort to maximize the diameter of the obstructed airway).
(Hib: *Haemophilus influenzae* type b)

Epiglottitis should be suspected in older children and adolescents in whom the severity of sore throat is out of proportion to the findings on oropharyngeal examination.

In young children, the differential diagnosis of epiglottitis includes other causes of acute upper airway obstruction **(Flowchart 1)**.

Flowchart 1: Diagnostic approach to upper airway obstruction in children.

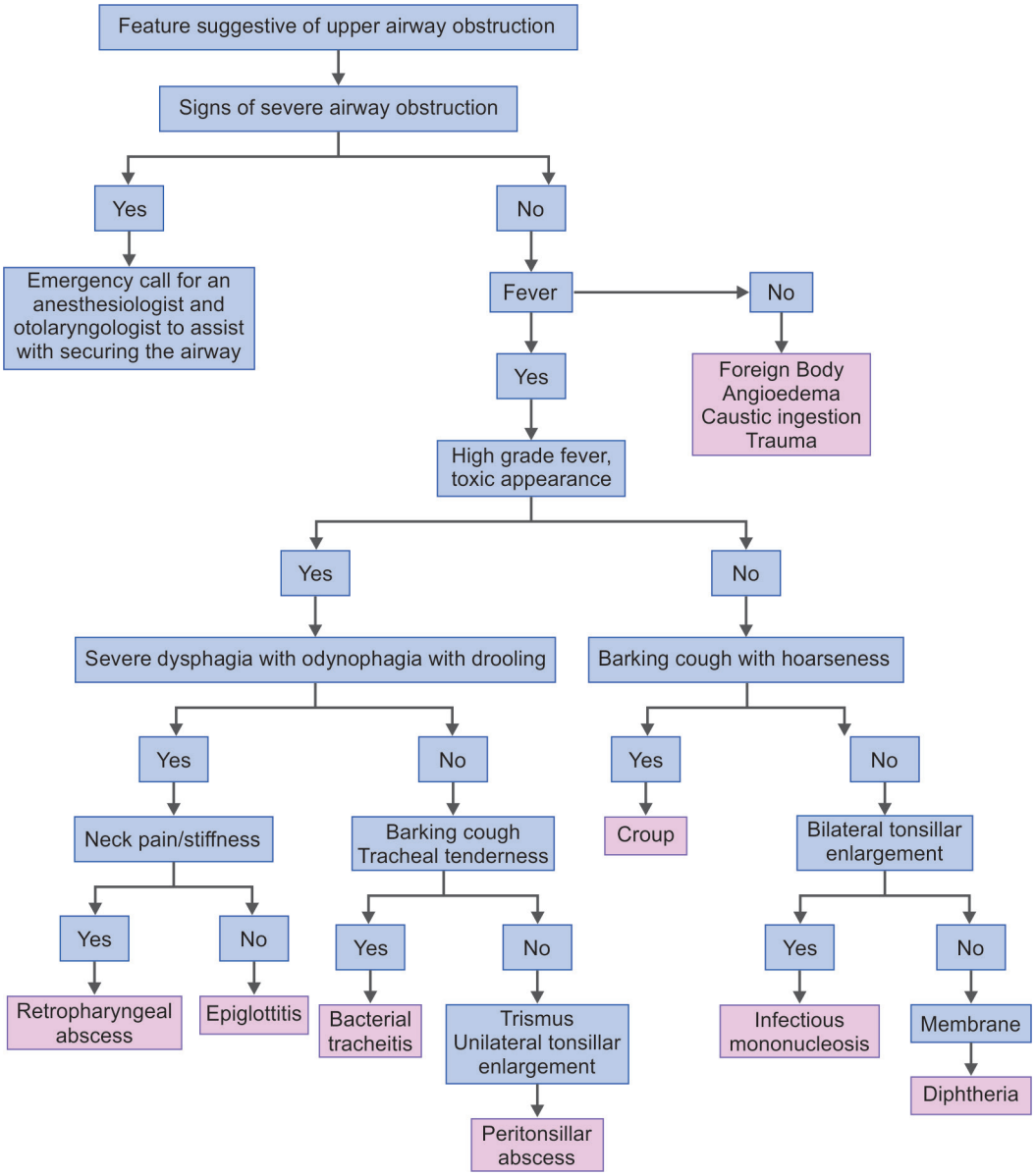

TABLE 3: Comparison of clinical features of infectious conditions associated with upper airway obstruction.

	Acute epiglottitis	***Croup***	***Bacterial tracheitis***	***Retropharyngeal abscess***
Age	3–14 years	6 months to 3 years	6 months to 14 years	2–4 years
Speed of onset	Very rapid (in hours)	Gradual	Rapid	Gradual
Appearance	Toxic	Nontoxic	Toxic	Toxic
Fever	High grade	Low grade	High grade	High grade
Cough	No	Characteristic "barking"	Characteristic "barking", painful, and productive	No
Sore throat	Yes	No	No	Yes
Dysphagia and odynophagia	Yes	No	No	Yes
Drooling	Yes	No	No	Yes
Voice	Muffled	Hoarse	Very hoarse	± Muffled
Tracheal tenderness	No	No	Yes	No
Neck pain/stiffness	No	No	No	Yes
Preferred position	Tripod with extended neck	No preference	Supine	No preference
Neck X-ray (anteroposterior)	Normal	Steeple sign	Steeple sign	Normal
Neck X-ray (lateral)	Thumb sign	Normal	Haziness in subglottic area and irregularity of the anterior wall of the trachea	Enlarged prevertebral space
Response to inhaled adrenaline	No	Very good	No or minimal	No

Diagnosis

In view of the potential for rapid progression to complete airway obstruction, the threshold for suspicion of epiglottitis should be low.

Confirmation

Confirmation is made by direct visualization under controlled circumstances of a large, cherry red, and swollen epiglottis by laryngoscopy.

In patients with signs of total or near-total upper airway obstruction, airway control necessarily precedes diagnostic evaluation.

Visualization of the epiglottis should only be attempted in a setting where the airway can be secured immediately, if necessary [e.g., emergency room (ER), intensive care unit (ICU), or operation theater] and, whenever possible, by the appropriate airway experts (e.g., anesthetist and otolaryngologist or pediatrician with similar expertise).

Imaging

Imaging should not delay the definitive airway management. The patient must be accompanied by personnel skilled with advanced airway management, proper equipment, and medications.

Plain Radiographs

Soft-tissue lateral neck radiographs can confirm the diagnosis of epiglottitis although not necessary in many cases.

Radiographic features of epiglottitis include:

- ☑ An enlarged epiglottis protruding from the anterior wall of the hypopharynx (the "thumb sign")
- ☑ Thickened aryepiglottic folds
- ☑ Loss of vallecular air space and distended hypopharynx (nonspecific).

Imaging

Ultrasonography

Its role is unclear in children.

Laboratory Studies

- ☑ Complete blood count (CBC) can show an elevated white blood cell count (nonspecific).
- ☑ Blood and epiglottic cultures yield is variable.

Until the airway is secured, laboratory studies should not be performed in young children with imminent complete airway obstruction because agitation caused by pain may worsen respiratory distress and precipitate sudden respiratory arrest.

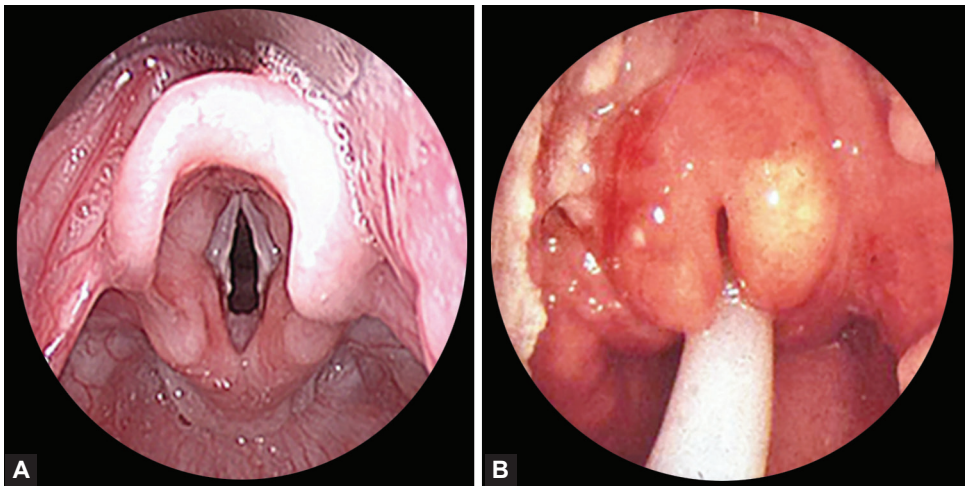

Figs. 1A and B: (A) Normal epiglottis; (B) Swollen and red epiglottis as seen in acute epiglottitis.

Imaging

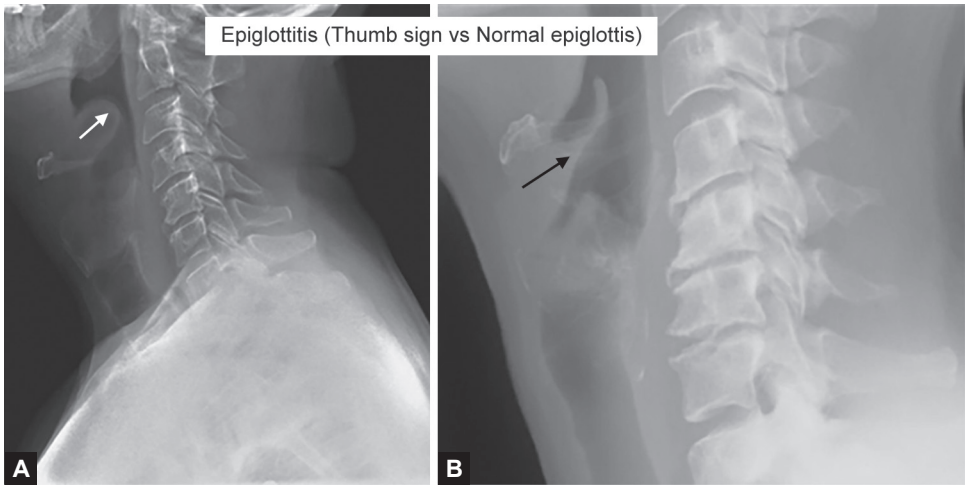

Figs. 2A and B: Lateral X-ray of neck showing thumb sign.

The approach to diagnosing epiglottitis, including which patients should undergo attempts at direct visualization depend upon the patient's presentation and the clinician's suspicion for epiglottitis.

Treatment (Flowchart 2)

Maintenance of the airway is the mainstay of treatment followed by appropriate antimicrobial therapy.

Flowchart 2: Algorithm for management of acute epiglottitis.

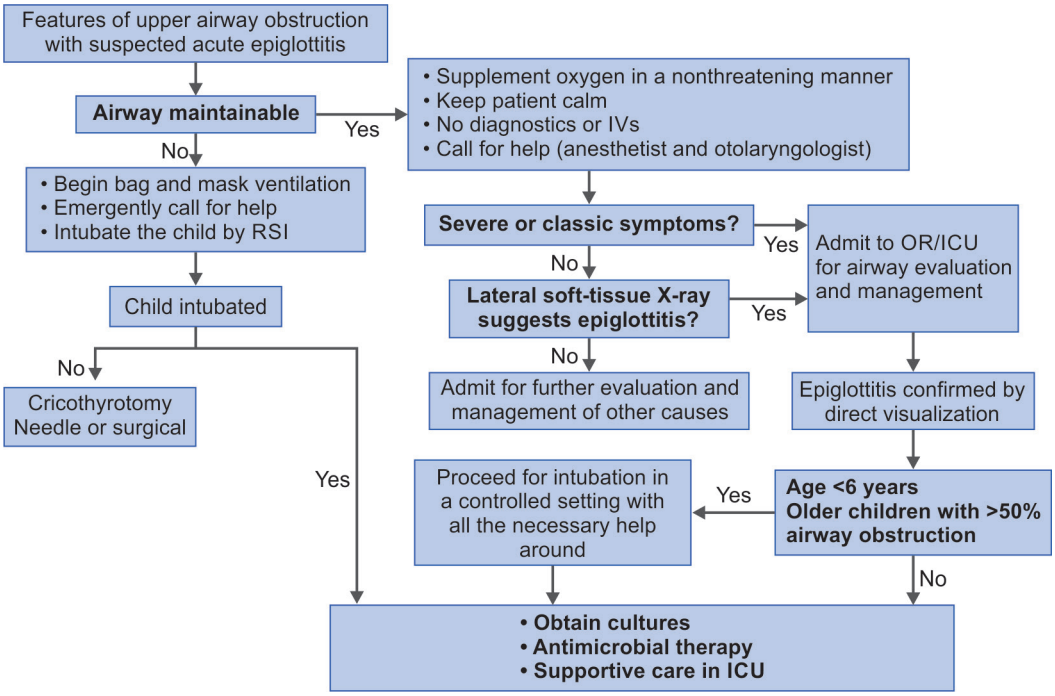

(ICU: intensive care unit; OR: operating room; RSI: rapid sequence intubation)

Treatment

Basic Considerations

- ☑ If there is high suspicion of epiglottitis summon airway specialist (anesthesiologist/critical care specialist and otolaryngologist).
- ☑ Ensure that basic as well as difficult airway devices and medication are kept ready in the patient's room.
- ☑ Do not perform invasive procedures (e.g., IV placement, phlebotomy, or any other painful or frightening intervention) until after airway management in younger children.
- ☑ Do not attempt to examine the oral cavity, pharynx, or larynx.

Pharmacotherapy

- ☑ Ceftriaxone 50 mg/kg/day IM or IV once daily or cefotaxime 50 mg/kg/dose 8 hourly for 7–10 days.
- ☑ Start vancomycin, if *Staphylococcus* is suspected.
- ☑ There is no role for steroids or bronchodilators.

- ☑ The progression of epiglottic swelling generally halts within 24 hours of starting of antimicrobial therapy and improves after 2–3 days.
- ☑ So, if child was intubated, can plan for extubation after 3 days but need to confirm resolution of epiglottic swelling by reexamination.

Prevention

- ☑ Adherence to immunization guidelines.
- ☑ *Chemoprophylaxis*: Has to be started as soon as possible.
- ☑ *Drug of choice*: Rifampicin 20 mg/kg (maximum 600 mg) once a day for 4 days for adults and children older than 3 months.
- ☑ Infants younger than 3 months should receive 10 mg/kg once a day for 4 days.
- ☑ *Alternatives*: IV or IM ceftriaxone (50 mg/kg maximum 1 g) once a day for 2 days or azithromycin (10 mg/kg, maximum dose 500 mg) once a day for 3 days.

Who should receive: All the family members of the household or close contact group including the index case if the group has vulnerable persons, e.g.:

- ☑ Infants younger than 12 months or
- ☑ Children younger than 4 years who are incompletely vaccinated or
- ☑ Immunocompromised child

Further Reading

- ☑ Brown CA. Adult and pediatric epiglottitis. In: Berkow LC, Sakles JC (Eds). Cases in Emergency Airway Management. Cambridge: University of Cambridge; 2015. pp. 71-9.
- ☑ Ditmar MF. Infectious diseases. In: Polin RA, Ditmar MF (Eds). Pediatric Secrets, 5th edition. Missouri, United States: Mosby; 2011. pp 354-422.
- ☑ Rodrigues K, Roosevelt G. Acute inflammatory upper airway obstruction (croup, epiglottitis, laryngitis, and bacterial tracheitis). In: Kligeman R, St Geme III J (Eds). Nelson's Textbook of Pediatrics, 21st edition. Philadelphia: Elsevier; 2020. pp. 2202-5.
- ☑ Tebruegge M, Pantazidou A, Yau C, Chisti MJ, Curtis N. Bacterial tracheitis—tremendously rare, but truly important: a systematic review. J Pediatr Infect Dis. 2009;4:199-209.
- ☑ Woods CR. Clinical features and diagnosis. In: Edwards MS, Isaacson GC, Fleisher GR (Eds). Epiglottitis (Supraglottitis). Waltham, MA: UpToDate; 2022.

Indian Academy of Pediatrics (IAP)

STANDARD TREATMENT GUIDELINES 2022

Iron Deficiency Anemia

Lead Author

Deepak Bansal

Co-Authors

Nita Radhakrishnan, Anand Prakash

Under the Auspices of the IAP Action Plan 2022

Remesh Kumar R
IAP President 2022

Upendra Kinjawadekar
IAP President-Elect 2022

Piyush Gupta
IAP President 2021

Vineet Saxena
IAP HSG 2022–2023

© Indian Academy of Pediatrics

IAP Standard Treatment Guidelines Committee

Chairperson

Remesh Kumar R

IAP Coordinator

Vineet Saxena

National Coordinators

SS Kamath, Vinod H Ratageri

Member Secretaries

Krishna Mohan R, Vishnu Mohan PT

Members

Santanu Deb, Surender Singh Bisht, Prashant Kariya, Narmada Ashok, Pawan Kalyan