Developmental Dysplasia of the Hip

66

Introduction

Developmental dysplasia of the hip (DDH) is a disorder due to abnormal development of acetabulum with or without hip dislocation. Conservative management is often successful when early diagnosis and treatment is done. This prevents long-term complications such as persistent dislocation and early hip osteoarthritis **(Fig. 1)**.

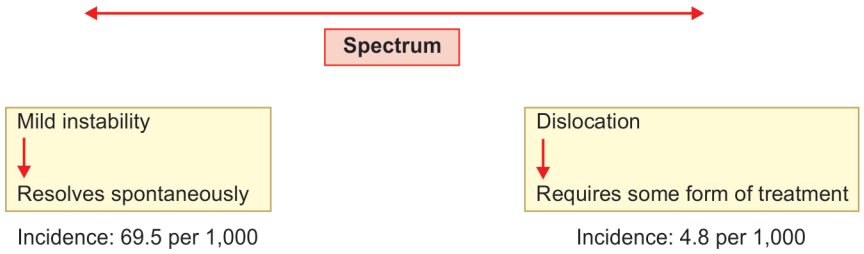

Fig. 1: Spectrum of developmental dysplasia of the hip.

About 63% of these DDH is unilateral and 60% involves the left side.

Importance of Early Diagnosis of Developmental Dysplasia of the HIP

- ☑ Early diagnosis is the fundamental prerequisite to achieve best results and to reduce the possibility of hip osteoarthritis in young adults.
- ☑ The ideal time limit for diagnosis and treatment has been identified as the sixth week of life; after which complexities of treatment increase.

Risk Factors

- ☑ Female sex 1:600
- ☑ First-born infant
- ☑ Breech positioning
- ☑ Family history

An association is noted with congenital muscular torticollis, metatarsus adductus, and talipes equinovarus.

Ideally all children should be evaluated for DDH at birth but this may not be possible, therefore children with at-risk factors should be mandatorily screened clinically and imaging should be done initially and at follow-ups.

Screening

Birth to Neonate

Every newborn should be evaluated for:

- ☑ Asymmetrical skin crease **(Fig. 2)**
- ☑ Limited abduction,
- ☑ Ortolani test **(Fig. 3)**
- ☑ Barlow test **(Fig. 4)**

Fig. 2: Asymmetrical skin folds.

Fig. 3: Ortolani test.

Fig. 4: Barlow test.

Birth to Neonate

Ortolani Maneuver

This maneuver reduces the dislocated hip. In supine position, hip flexed at 90° and in neutral rotation. The hip is held with the thumb on the inner aspect and index and ring finger on the greater trochanter. While applying anterior force on the greater trochanter, gently abduct the hip. If the hip is relocated, one feels a clunk.

Barlow Maneuver

In supine position, while applying posterior force to trochanter, adduct the hip. If hip dislocates, a clunk is felt.

Sensitivity is 92% and specificity is 98%.

Beyond the Neonatal Period

Signs to looks for include:

- ☑ Limited hip abduction **(Fig. 5)**
- ☑ Limp (Trendelenburg gait)
- ☑ Lumbar lordosis
- ☑ Toe walking
- ☑ Leg length discrepancy (LLD) (Galeazzi sign) **(Fig. 6)**

Galeazzi sign identifies femoral shortening by comparing the knee height while hip and knee are flexed and feet flat on the table.

Fig. 5: Limited hip abduction.

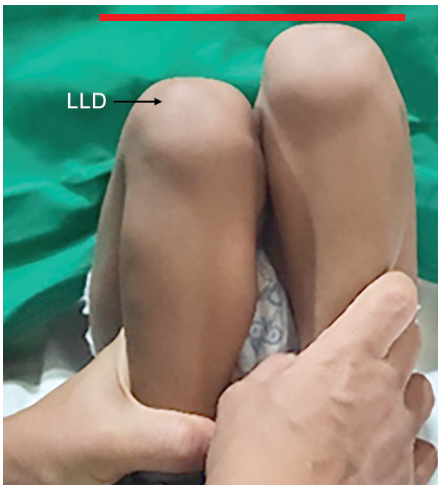

Fig. 6: Leg length discrepancy (LLD).

Screening

Management Algorithm

Periodic surveillance for screening of DDH should be done to prevent late presentation beyond 6 months.

Newborns to 6 Months

- ☑ Normal examination with risk factors—ultrasonogram (USG) of hip at 6 weeks
- ☑ Inconclusive examination—repeat examination in 4 weeks
- ☑ Positive Ortolani or Barlow—refer to a pediatric orthopedic surgeon

Beyond 6 Months

- ☑ Barlow and Ortolani maneuver may not be positive
- ☑ Limited hip abduction—most crucial screening method in older children
- ☑ At 4–6 months, femoral head ossification appears, X-ray becomes the preferred investigation

Normal pelvic radiographs at 4 months reliably exclude DDH in children.

Imaging

Ultrasonogram visualizes acetabular dysplasia, hip dislocation, and femoral head anatomy. It delineates femoral head coverage (minimum 50%) and depth of acetabulum (alpha angle: normally >60°).

Graf classification:

- ☑ Alpha angle-angle between bony acetabulum and ilium (normal > 60°)
- ☑ Beta angle-angle between labrum and ileum (normal < 55°)

Based on these angles, DDH is classified into four types **(Fig. 7)**.

X-ray: Anteroposterior (AP) of the pelvis:

- ☑ *Hilgenreiner's line*: A horizontal line through the right and left triradiate cartilage, head of the femur should be inferior to this line.
- ☑ *Perkin's line*: Perpendicular line to Hilgenreiner's line through a focus at the lateral side of the acetabulum. The femoral head should be medial to this line.
- ☑ *Shenton's line*: Smooth arc that connects the femoral neck to the superior margin of the obturator foramen. Any disruption indicates an abnormality.

Imaging

- ☑ *Acetabular index*: The intersection between Hilgenreiner's line and a line drawn tangential to the lateral ossific margin of the roof of the acetabulum. The normal index is <35° at birth and <25° at age one.
- ☑ *The center-edge angle of Wiberg*: Reliable in patients older than 5 years old. Formed by Perkin´s line and a line coming from the center of the femoral head to the lateral edge of the acetabulum. Values should be >20°.

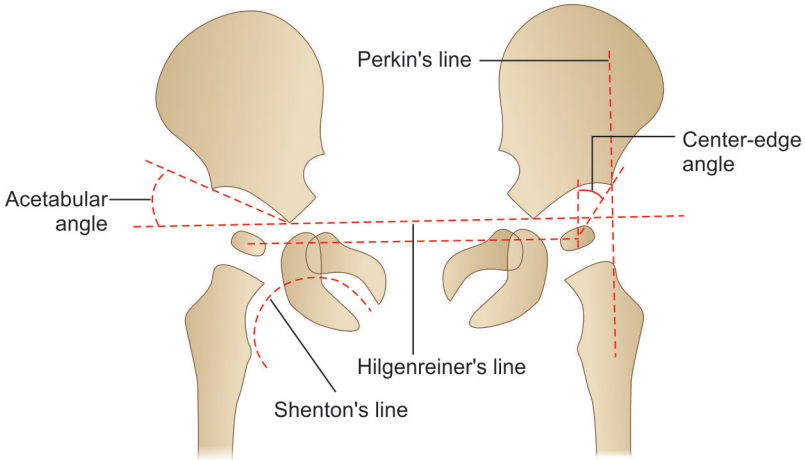

Fig. 7: Classification of developmental dysplasia of the hip.

Management

- ☑ To provide optimal contact between the femoral head and acetabulum, modalities such as abduction splinting, closed reduction, and open reduction are available **(Flowchart 1)**.
- ☑ Double diapering is harmless, but with questionable efficacy.

Flowchart 1: Management modalities of DDH.

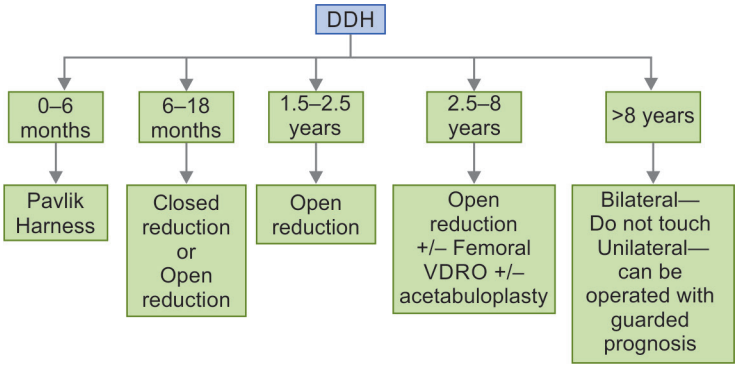

(DDH: developmental dysplasia of the hip; VDRO: varus derotational osteotomy)

Management

0–4 Weeks

- ☑ Mild instability without a dislocatable hip: Observe.
- ☑ Early referral to a pediatric orthopedic surgeon is optimal in dislocatable hips.

1–6 Months

- ☑ Although abduction devices such as von Rosen splint and Frejka pillow have been used, Pavlik harness is the most widely used device for DDH.
- ☑ It consists of an anterior strap that flexes the hip at 90° and prevents extension, posterior strap prevents adduction. It is worn 23 hours per day until the hip is stable. USG of the hip is done every 4 weeks to monitor the position of the femoral head. Success rate is about 90%.

6–18 Months

For infants diagnosed with DDH at this age, closed reduction with hip spica cast is preferred. Under general anesthesia (GA), hip is placed in 90–100° flexion and 40–50° abduction.

18 Months to 8 Years

Open reduction is the preferred option for children diagnosed with DDH over 18 months. A femoral shortening osteotomy may be required.

Acetabular Dysplasia

- ☑ Patients with acetabular dysplasia up to age 5, without dislocation can be treated with abduction orthosis.
- ☑ After age 5, pelvic osteotomies (Salter, Pemberton, and Dega) may be required to increase head coverage.
- ☑ Shelf procedure or Chiari procedure is indicated for children >8 years old with a subluxated femoral head.

Management

Adolescent Hip Preservation

Patients who are presenting with hip pain and with shallow acetabulum and closed triradiate cartilage but without signs of hip degeneration can be treated with a periacetabular osteotomy (PAO).

The International Hip Dysplasia Registry (IHDR) has recommended following DDH severity spectrum:

- ☑ Dysplasia
- ☑ Subluxable
- ☑ Dislocatable
- ☑ Dislocatable but reducible
- ☑ Dislocatable and irreducible

Further Reading

- ☑ Kokavec M, Bialik V. Developmental dysplasia of the hip. Prevention and real incidence. Bratisl Lek Listy. 2007;108(6):251-4.
- ☑ Phelan N, Thoren J, Fox C, O'Daly BJ, O'Beirne J. Developmental dysplasia of the hip: incidence and treatment outcomes in the southeast of Ireland. Ir J Med Sci. 2015;84:411-5.
- ☑ Schwend RM, Shaw BA, Segal LS. Evaluation and treatment of developmental hip dysplasia in the newborn and infant. Pediatr Clin North Am. 2014;61(6):1095-107.

Indian Academy of Pediatrics (IAP)

STANDARD TREATMENT GUIDELINES 2022

Neonatal Hypothermia

Lead Author

Somashekhar Nimbalkar

Co-Authors

Akumtoshi, Ravi Shankar Swamy

Under the Auspices of the IAP Action Plan 2022

Remesh Kumar R
IAP President 2022

Upendra Kinjawadekar
IAP President-Elect 2022

Piyush Gupta
IAP President 2021

Vineet Saxena
IAP HSG 2022–2023

© Indian Academy of Pediatrics

IAP Standard Treatment Guidelines Committee

Chairperson

Remesh Kumar R

IAP Coordinator

Vineet Saxena

National Coordinators

SS Kamath, Vinod H Ratageri

Member Secretaries

Krishna Mohan R, Vishnu Mohan PT

Members

Santanu Deb, Surender Singh Bisht, Prashant Kariya, Narmada Ashok, Pawan Kalyan