Epistaxis in Children

69

Definition

Epistaxis is defined as bleeding from the nostril, nasal cavity, or nasopharynx that is sufficient to warrant medical advice or care. This includes bleeding that is severe, persistent, and/or recurrent, as well as bleeding that affects a patient's quality of life.

Introduction

- ☑ Epistaxis is a common, usually benign condition of childhood and accounts for about 0.5% of all emergency department visits. Children with epistaxis mainly present between 2 and 10 years of age. About 30% of children aged 2–5 years, 56% of children aged 6–10 years, and 64% of children aged 11–15 years developing epistaxis during their lifetime.
- ☑ Since epistaxis is so common, how extensive would be the workup and treatment of a child with nasal bleeding can be a difficult decision. While there is no consensus on the duration or frequency of episodes constituting recurrent epistaxis, some studies have defined recurrent epistaxis as five or more episodes per year.

Pathophysiology

- ☑ There are diverse causes and risk factors, which can lead to epistaxis. Sometimes the etiology is not clear and thus primary (i.e., idiopathic) epistaxis is the main cause.
- ☑ Dry atmospheric conditions lacking humidification leads to dried nasal mucosa and associated fissuring of nasal mucosa, subsequently leading to desiccation and exposure of blood vessels.
- ☑ Mostly, the site of the bleeding is on the anterior nasal septum due to network of small blood vessels known as Kiesselbach's plexus **(Fig. 1)**.
- ☑ These vessels are located in a superficial portion of the septal mucosa, which makes them prone to injury from the slightest mechanical or chemical insult. Other sites of bleeding include the lateral nasal wall, particularly the branches of the sphenopalatine artery. Posteriorly, bleeding can arise from posterior branches of the sphenopalatine artery, Woodruff plexus, and venous sources.

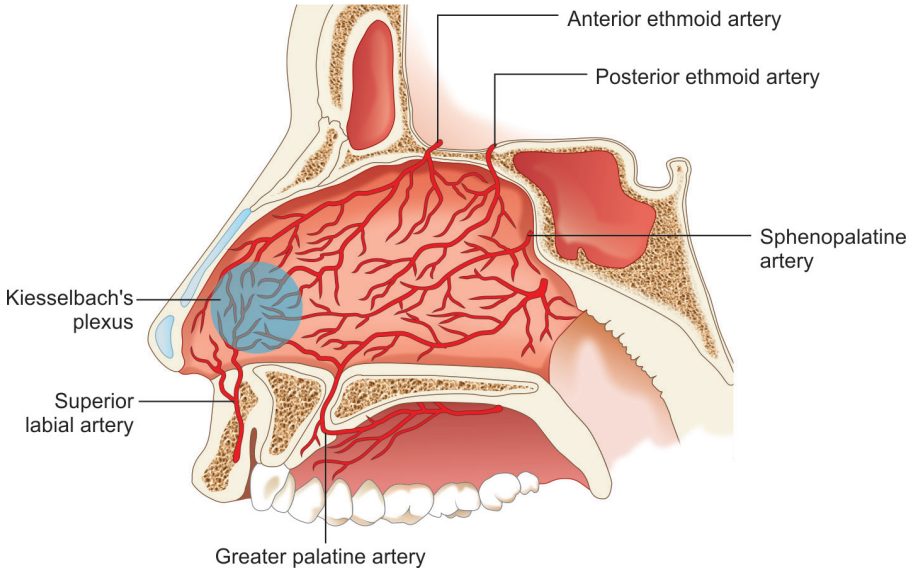

Fig. 1: Kiesselbach's plexus on the anterior nasal septum.

Most nosebleeds are benign, self-limited, and rarely life-threatening. It is crucial to diagnose the cause of the bleeding, whether it is local or secondary to some underlying cause, e.g., inherited systemic coagulopathy or tumor, as this strongly affects the management and might require multidisciplinary team, alongside the otolaryngologist **(Table 1)**.

Risk Factors

- ☑ Local inflammation
- ☑ Prior upper respiratory tract infections
- ☑ Mucosal drying
- ☑ Local trauma (including nose picking)
- ☑ Other specific local (e.g., tumors) or systemic (e.g., clotting disorders) factors.

TABLE 1: Causes of epistaxis in children.

Primary	Idiopathic	
Secondary	Trauma	☑ Digital manipulation (nose picking) ☑ Facial trauma, blunt force ☑ Septal perforation
	Inflammation and infection	☑ Upper respiratory tract infections ☑ Allergic rhinitis ☑ Sinusitis ☑ Foreign body ☑ Vasculitis
	Neoplasms and masses	☑ Nasal polyps ☑ Rhabdomyosarcoma of the head and neck ☑ Juvenile nasopharyngeal angiofibroma (JNA)
	Hematologic conditions and coagulopathies	☑ Hemophilia ☑ Von Willebrand disease ☑ Leukemia ☑ Platelet dysfunction/disorder ☑ Immune thrombocytopenia ☑ Aplastic anemia ☑ Liver disease
	Medications	☑ Anticoagulants ☑ Nasal steroid sprays ☑ Illicit drug inhalation ☑ Natural medications
	Vascular anomalies	☑ Hemangiomas ☑ Hereditary hemorrhagic telangiectasia (Osler–Weber–Rendu syndrome)

Risk Factors and Etiology

Risk Factors

Primary epistaxis is defined as idiopathic bleeds without identifiable and precipitating factors, whereas bleeds known to be associated with a clear and definitive cause are classified as secondary epistaxis.

The etiology varies in different age groups:

☑ *>2 years*: Mainly due to local factors **(Table 2)**.

TABLE 2: Local and systemic causes of secondary epistaxis.

Local causes	***Systemic causes***
☑ Prior upper respiratory tract infections with mucosal inflammation ☑ Mucosal drying ☑ Local trauma (including nose picking) ☑ Other specific local (e.g., tumors)	☑ Clotting disorders: – Hemophilia A/B – Platelet function defect (PFD) – Von Willebrand disease ☑ Platelet related – Platelet function disorder – Idiopathic thrombocytopenic purpura

☑ *<2 years*: Epistaxis is rare (1 per 10,000), must be worked up for:

- Trauma (intentional or unintentional)
- Hematological illness (e.g., thrombocytopenia and clotting disorders)
- Child abuse.

Assessment

☑ A child presenting with epistaxis should be immediately evaluated for airway obstruction and circulatory imbalance due to the bleed. Initial stabilization is a must before proceeding for the detailed evaluation.

☑ A thorough head and neck examination is important in evaluating any patient with epistaxis. Anterior rhinoscopy should be performed using an otoscope.

☑ If there is a history of trauma, neurologic status and associated blood loss from other sites should be actively looked.

☑ Although epistaxis is usually self-limited, it can be potentially life-threatening.

☑ If the bleeding has been recurrent or prolonged and there has been a significant blood loss, urgent blood group and cross matching, clotting studies, and a full blood count to monitor hemoglobin levels should be done.

Once stabilized, a detailed history should be elicited including history of present illness, medical history, and family history.

Assessment

History of Present Illness

- ☑ Age and gender
- ☑ Rhinorrhea/upper respiratory tract infection
- ☑ Onset and duration of the bleed
- ☑ Frequency of the nosebleeds
- ☑ Nasal laterality of the bleeds
- ☑ Estimated blood loss
- ☑ Associated trauma; foreign body; nasal obstruction and discharge; and pain
- ☑ History of allergic rhinitis
- ☑ History of nasal and/or paranasal surgery, benign or malignant tumor
- ☑ Deviated nasal septum.

Past Medical History

- ☑ *Medications*: Antithrombotic agent use (i.e., aspirin, warfarin, etc.)
- ☑ Past medical history (hypertension and hematologic disease)
- ☑ Previous nosebleeds requiring emergency or surgical interventions
- ☑ Underlying chronic illness (i.e., chronic sinusitis, etc.)
- ☑ Allergies
- ☑ Easy or unusual bruising or bleeding from other sites (e.g., gingival, menorrhagia, or hemorrhage after dental extraction)
- ☑ Hematemesis; hematochezia; and melena.

Family History

- ☑ Bleeding disorders
- ☑ Relatives with unusual bleeding tendencies
- ☑ Use of recreational drugs.

Medical Examination

At the emergency room/outpatient department, immediate examination of the vitals and general condition of the child has to be done.

Vitals and General Examination

- ☑ *Vitals*: Peripheral and central pulses, tachycardia, and hypertension/hypotension
- ☑ Facial swelling and injuries
- ☑ Cervical lymphadenopathy (may be associated with malignancies)
- ☑ *Skin*: Jaundice, petechiae, ecchymoses, purpura, telangiectasias, and pallor.

Systemic Examination

- ☑ *Central nervous system examination*: Glasgow Coma Scale, neurological deficits, and vision or hearing changes [may be associated with juvenile nasopharyngeal angiofibroma (JNA)]
- ☑ *Abdomen*: Hepatosplenomegaly (may be associated with malignancies and liver disease)
- ☑ *Cardiovascular system*: Murmurs and signs of congestive cardiac failure

Examination of the Nose and Oral Cavity

- ☑ Inspection and palpation: Possible external findings
- ☑ Erythema, abrasion, discharge, or bleeding at the anterior nares
- ☑ Foul odor and discharge from the nose, often unilateral (may be associated with a foreign body)
- ☑ Transverse skin crease over the bridge of the nose (seen in persons with allergic rhinitis)
- ☑ Atopic pleats or Dennie–Morgan folds below the eyes (seen in persons with allergic rhinitis)
- ☑ Inspection and palpation with a light source (usually an otoscope with a wide-tipped nasal speculum): Possible internal findings
- ☑ Vestibulitis (crusting, erythema, and swelling of the nasal vestibule)
- ☑ Pronounced vessels or obvious bleeding at the anterior septum
- ☑ Boggy turbinates
- ☑ Nasal obstruction, masses, polyps, and septal perforation
- ☑ Sinus tenderness with palpation
- ☑ Palatal masses (may be seen with angiofibromas)
- ☑ Telangiectasia of the mouth or lips
- ☑ Blood in the posterior pharynx and not the nose (may be seen with posterior bleeds).

Assessment

Medical Examination

Bleeding Point Identification

- ☑ The child should be examined for visible bleeding points with a nasal speculum, such as Kiesselbach's plexus (Little's area) and cotton must be placed into the posterior nasal cavity to prevent blood from running down the pharynx.
- ☑ If a bleeding point could not be identified, the patient should be referred to an otolaryngologist for detailed examination using a flexible/rigid endoscope. Since the blood flows from top to bottom when the patient is seated, the search for a bleeding point with an endoscope should be performed in the following order: upper olfactory cleft, upper middle meatus, lower olfactory cleft, lower middle meatus, common meatus, and inferior meatus.

Treatment

Management of most nosebleeds primarily revolves around educating the parent and patient on treatment at the time of the bleed as well as using ways to prevent bleeding in the future. The various modalities of treatment include **(Table 3)**:

TABLE 3: Management of epistaxis in various settings.

Intervention	***Outpatient pediatrics***	***Inpatient or emergency department physician***	***Otolaryngologist***
Pressure	X	X	X
Decongestants (Topical)	X	X	X
Anterior packing	X	X	X
Silver nitrate cautery	X	X	X
Nasal endoscopy	—	X	X
Blood or reversal agents	—	X	X
Posterior packing	—	X	X
Endoscopic ligation	—	—	X

☑ *Nasal care*:

- Patients should be instructed to place constant pressure on the anterior septum by pinching the caudal (soft) portion of the nose with the fingers for 5–10 minutes and should sit straight up or lean slightly forward.
- A common pitfall is holding pressure on the bridge of the nose, which does not provide adequate pressure.
- Blood clots are a source of fibrinolytic enzymes, so if bleeding persists after 5–10 minutes, the nose should be gently blown to evacuate any clots.
- A vasoconstrictor such as oxymetazoline can be sprayed up the nose and pressure reapplied.

☑ *Nasal packing*:

- If bleeding is not controlled after applying adequate pressure or the patient has a frequent or severe recent history of epistaxis, the next step involves doing nasal packing. A rolled-up piece of an absorbable hemostatic agent up against the nasal septum **(Fig. 2)**.
- These are usually left in for 24–48 hours.
- When not controlled with anterior packing, a posterior bleed should be suspected and an otolaryngologist should be consulted.

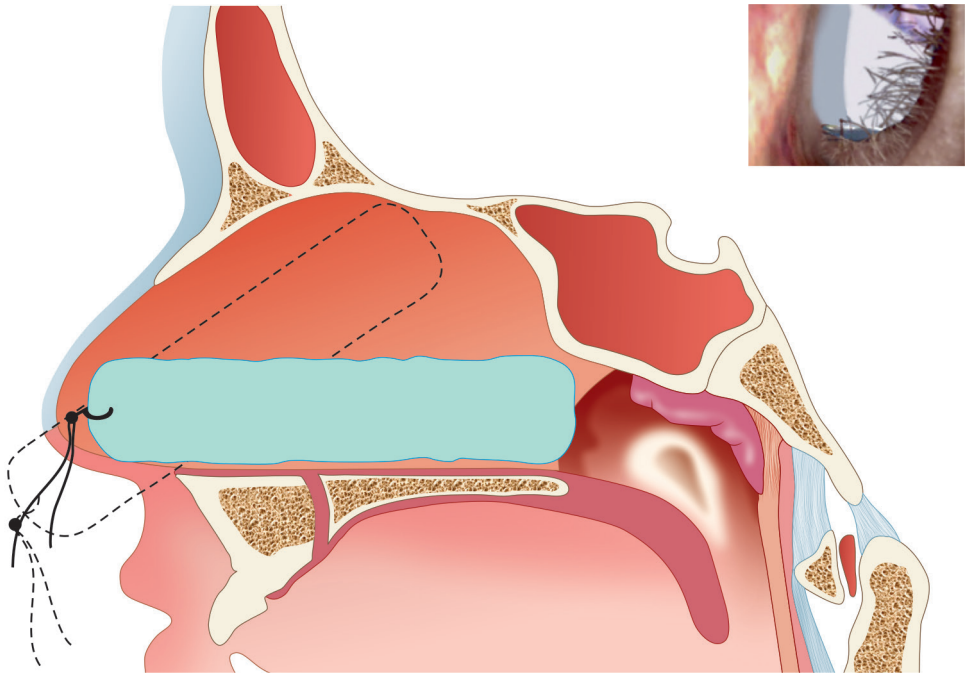

Fig. 2: Correct placement of nasal pack along the floor of the anterior nasal cavity (bold line) and incorrect placement (dotted lines).

- ☑ *Coagulation*:
  - After applying firm pressure, if bleeding has stopped or slowed sufficiently, an attempt should be made to identify prominent or bleeding vasculature on the anterior nasal septum, which can be easily cauterized with topical silver nitrate.
  - Remember use of silver nitrate cautery on both sides of the nasal septum in the same location can cause septal perforation and should be avoided.
  - In the acute setting, optimum treatment would be localization and cauterization of the bleeding area.
- ☑ *Endovascular occlusion/embolization*:
  - It is used in controlling uncontrolled bleeding by occluding the feeding vessels; this significantly reduces the blood supply of the nose and the paranasal sinuses where the epistaxis is originating.
  - This should be used in patients with sinonasal tumors and especially preoperative optimization of select vascular tumors.
  - However, one must consider side effects such as radiation exposure, limited availability, and increased costs.
  - Embolization of the ethmoidal arteries is contraindicated because these are derived from the ophthalmic artery and occlusion can cause blindness.
- ☑ *Minimal invasive surgery*:
  - Patients with significant and brisk bleeding or unremitting bleed and the patient with signs of airway compromise or hypovolemia would require surgical intervention.
  - With improvement in endoscopic technologies, minimally invasive transnasal control of epistaxis has been increasingly performed and is now considered regularly in severe and recurrent epistaxis.
  - Transnasal endoscopic sphenopalatine artery ligation (TESPAL) is routinely performed and epistaxis due to other sources (e.g., ethmoidal arteries) can also be endoscopically addressed.
  - These procedures do not involve any external incisions, can be done on an outpatient basis, and are less painful.
  - *Novel interventions* including propranolol, potassium titanyl phosphate laser therapy, bilateral nasal cautery, and microwave ablation have shown promise, but more research is needed on their long-term effectiveness and safety.

Further Reading

- ☑ Burton MJ, Dorée CJ. Interventions for recurrent idiopathic epistaxis (nosebleeds) in children. Cochrane Database Syst Rev. 2004;1:CD004461.
- ☑ ElAlfy MS, Tantawy A, Eldin BEMB, Mekawy MA, elAziz Mohammad YA, Ebeid FSE. Epistaxis in a pediatric outpatient clinic: could it be an alarming sign? Int Arch Otorhinolaryngol. 2022;26(02): e183-90.
- ☑ Kucik CJ, Clenney T. Management of epistaxis. Am Fam Physician. 2005;71(2):305.
- ☑ Send T, Bertlich M, Eichhorn KW, Ganschow R, Schafigh D, Horlbeck F, et al. Etiology, management, and outcome of pediatric epistaxis. Pediatr Emer Care. 2019;37:466-70.
- ☑ Svider P, Arianpour K, Mutchnick S. Management of Epistaxis in children and adolescents avoiding a chaotic approach. Pediatr Clin N Am. 2018;65:607-21.
- ☑ Tunkel DE, Anne S, Payne SC, Ishman SL, Rosenfeld RM, Abramson PJ, et al. Clinical practice guideline: nosebleed (Epistaxis). Otolaryngol Head Neck Surg. 2020;162(1S):S1-S38.

Indian Academy of Pediatrics (IAP)

STANDARD TREATMENT GUIDELINES 2022

Constipation in Children

Lead Author
Srinivas S

Co-Authors
Mohit Vohra, Vibhor Borkar

Under the Auspices of the IAP Action Plan 2022

Remesh Kumar R
IAP President 2022

Upendra Kinjawadekar
IAP President-Elect 2022

Piyush Gupta
IAP President 2021

Vineet Saxena
IAP HSG 2022–2023

© Indian Academy of Pediatrics

IAP Standard Treatment Guidelines Committee

Chairperson

Remesh Kumar R

IAP Coordinator

Vineet Saxena

National Coordinators

SS Kamath, Vinod H Ratageri

Member Secretaries

Krishna Mohan R, Vishnu Mohan PT

Members

Santanu Deb, Surender Singh Bisht, Prashant Kariya, Narmada Ashok, Pawan Kalyan