Etiopathology

It is an autoimmune disorder characterized by reduced peripheral blood platelet count due to combination of premature platelet destruction and inadequate platelet production.

Clinical Features

In a well looking child with symptoms suggestive of ITP evaluation should include:

TABLE 2: Clinical features of ITP in a well looking child.

History	Isolated mucocutaneous bleeding symptoms (petechia, purpura, ecchymosis, epistaxis, oral bleeds, etc.) without other constitutional symptoms such as fever, weight loss, bone pains, or night sweats No family history of bleeding disorders
Examination	Bleeding symptoms Absence of hepatosplenomegaly, lymphadenopathy, weight loss, bony tenderness, or stigmata of congenital conditions

Though in ITP, there is no linear relationship with the degree of platelet count and the severity of bleeding symptoms, generally patients with ITP do not bleed despite of very low platelet counts.

Diagnosis

- ☑ It is a diagnosis of exclusion with typical history and examination; complete blood count (CBC) showing only isolated thrombocytopenia and no atypical cells. Anemia, if present, is in proportion with external bleeding.
- ☑ Bone marrow examination is not required for diagnosis if peripheral smear is seen by an experienced pathologist or preferably by a pediatric hematologist.
- ☑ No need for routine testing of antinuclear antibody (ANA), immunoglobulin levels, or *H. pylori*.

When to do bone marrow examination?

- ☑ Bone marrow is required before starting steroids by many pediatric hematologists across the country as a good clinical practice, not strictly adhering to the guidelines from West.
- ☑ Abnormalities such as fever or bone or joint pain, a family history of low platelets or easy bruising, risk factors for HIV infection, skeletal or soft-tissue morphologic abnormalities, nonpetechial rash, lymphadenopathy or an abnormal hemoglobin level, and white blood cell count or white cell morphology are not typical of ITP and should prompt additional testing, such as bone marrow evaluation.

The goal is to minimize the risk of hemorrhage. Decreasing the long-term side effects of treatment are the goals of therapy. Treatment is guided by the severity of bleeding rather than on the platelet count.

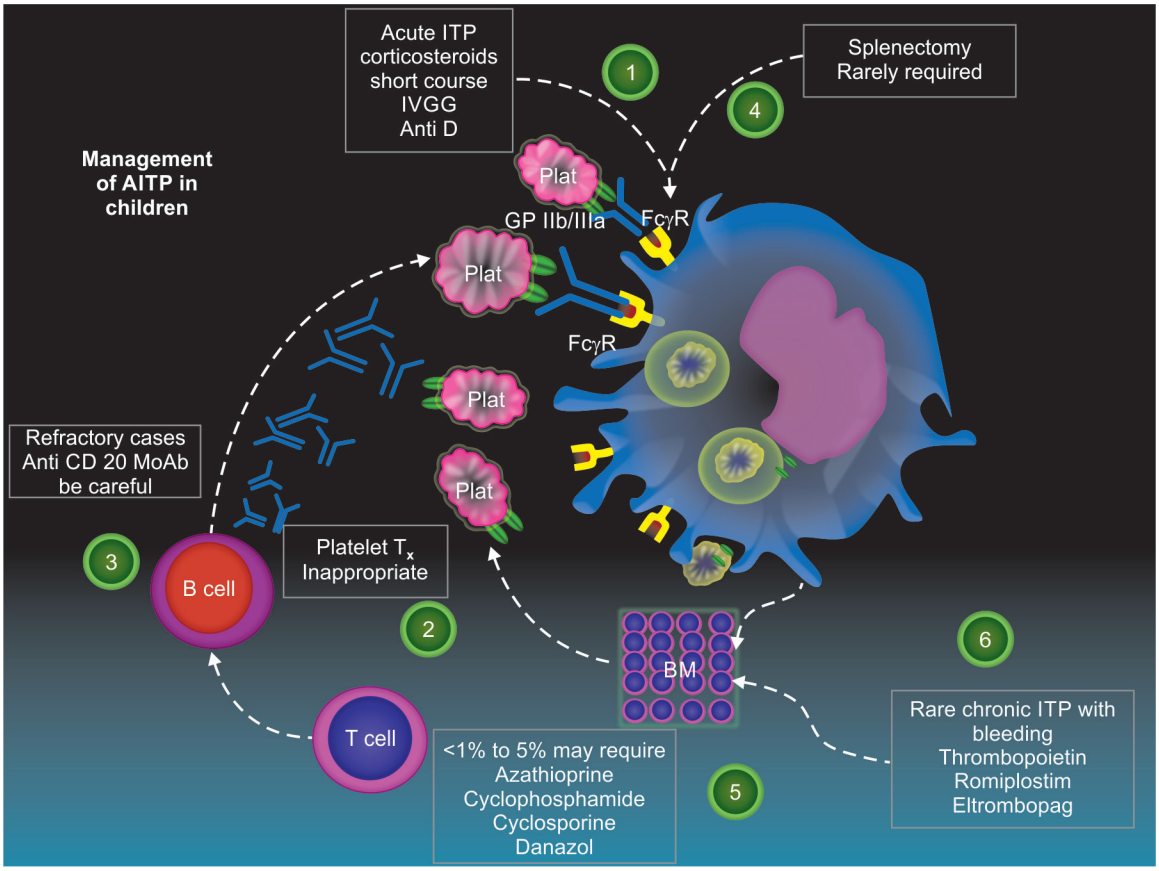

Fig. 1: Site of action of various drugs in immune thrombocytopenic purpura (ITP).

- ☑ The degree of bleeding is based on the World Health Organization (WHO) grading of bleeding, severe bleeding is WHO grade 3 or 4 and those with life-threatening bleeds or intracranial bleeds.
- ☑ Adolescent patients are treated as per pediatric treatment guidelines.
- ☑ *First line of pharmacotherapy* ***(Fig. 1)***:
  - *Short course of steroid*: Prednisolone 2–4 mg/kg/day (maximum 120 mg) for a short course of 5–7 days. It is preferred over dexamethasone 0.6 mg/kg/day (maximum 40 mg) × 4 days
  - *IV immunoglobulins*: 1 g/kg/day for 1–2 days
  - *IV anti-D therapy*: 50–75 mg/kg provided patient has direct Coombs test negative, Rh positive, and Hb >10 g/dL.

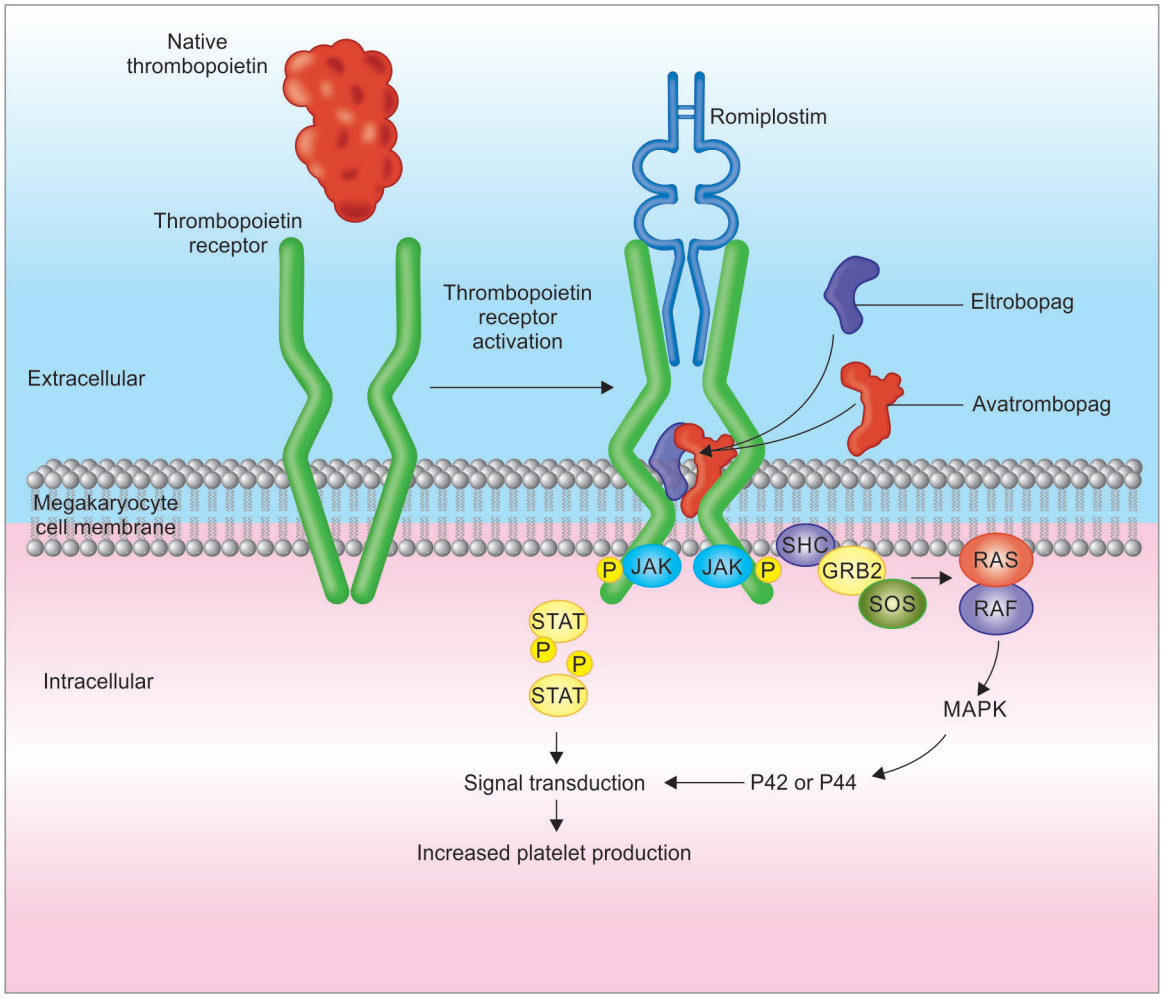

Fig. 2: Site of action of thrombopoietin receptor agonists (TPO-RA) mimetic drugs.

☑ Nonresponders to first-line therapy **(Fig. 2)**

- TPO-RA agonists preferred over rituximab which is preferred over splenectomy.
- TPO-RA agonists are preferred here because of less side effects and to avoid immunosuppression. However, the cost can be exorbitant.
- In the Indian scenario, the cost and availability of TPO-RAs is prohibitive which makes them unsuitable as a frontline therapy. Rituximab is promising with a median response duration of 12.8 months, relative ease of availability, and tolerable side effects.
- *Eltrombopag*: 1–6 years—25 mg once daily, > 6 years old—50 mg once daily. It has to be taken in empty stomach, median onset of action is at 2 weeks and need to monitor liver function test (LFTs).

TABLE 3: Treatment of ITP.

Type of immune thrombocytopenic purpura (ITP)	***Symptoms***	***Treatment options***
Newly diagnosed/acute ITP Persistent ITP	No or minimal bleeding	☑ Home observation ☑ Hospital observation, if unable to follow-up within 24–72 hours or diagnosis is uncertain Irrespective of the platelet count
	Moderate bleeding	Short course of steroid/intravenous immunoglobulin (IVIg)/IV anti-D
	Severe bleeding	Short course of steroid/IVIg/IV anti-D (along with platelet transfusions in life-threating bleeds)
Chronic ITP	No or mild bleeding	Observation
	Moderate or severe bleeding	Treatment options include: ☑ TPO receptor agonists (eltrombopag and romiplostim) ☑ Rituximab ☑ Splenectomy ☑ High-dose dexamethasone/IVIg A combination of the above with platelet transfusions in life-threatening bleeds)

- *Romiplostim*: 1–10 µg/kg subcutaneous once a week
- Injection rituximab 375 mg/m^2 once a week × 4 weeks. Dose as low as 100 mg/m^2 also have been found to be useful and cost effective.

☑ *Alternative immunosuppressive agents*: Dapsone, azathioprine, danazol, mycophenolate mofetil, cyclosporine, cyclophosphamide, anti-CD52 monoclonal antibody, vinca alkaloids, and combination of different agents has been tried but data are sparse, especially in children, and hence the American Society of Hematology (ASH) 2019 categorically mentions that recommendations were not feasible.

Dapsone is an easily available low-cost drug with response rates of around 50%; hemolysis, methemoglobinemia, and sulfa allergy being important side effects and is to be avoided in glucose-6-phosphate dehydrogenase (G6PD) deficient individuals.

☑ *Splenectomy*: It should be deferred, if possible, to beyond 12 months from disease onset. It may be the last resort in situations where ITP is unresponsive to all other therapy, the child shows intolerance to other drugs and quality of life is impaired. It is generally avoided in a child <5 years of age. All age appropriate immunization including meningococcal vaccine should be completed before splenectomy and penicillin prophylaxis should be continued for at least 5 years post-splenectomy.

☑ *Secondary ITP*: Treat the underlying cause or stop the offending drug.

Outcomes

Majority of children (60–75%) have acute ITP that resolves within 2–3 months of diagnosis, regardless of therapy. Approximately, 20% of children go on to have chronic ITP. Fewer than 1% of patients develop an intracranial hemorrhage.

Further Reading

- ☑ Matzdorff A, Meyer O, Ostermann H, Kiefel V, Eberl W, Kühne T, et al. Immune thrombocytopenia—current diagnostics and therapy: recommendations of a Joint Working Group of DGHO, OGHO, SGH, GPOH, and DGTI. Oncol Res Treat. 2018;41:1-30.
- ☑ Neunert C, Lim W, Crowther M, Cohen A, Solberg L Jr, Crowther MA. The American Society of Hematology 2011 evidence-based practice guideline for immune thrombocytopenia. Blood. 2011;117:4190-207.
- ☑ Neunert C, Terrell DR, Arnold DM, Buchanan G, Cines DB, Cooper N, et al. American Society of Hematology 2019 guidelines for immune thrombocytopenia. Blood Adv. 2019;3:3829-66.
- ☑ Patel AP, Patil AS. Dapsone for immune thrombocytopenic purpura in children and adults. Platelets. 2015;26:164-7.
- ☑ Sahi PK, Chandra J. Immune Thrombocytopenia: American Society of Hematology Guidelines, 2019. Indian Pediatr. 2020;57:854-6.

Indian Academy of Pediatrics (IAP)

STANDARD TREATMENT GUIDELINES 2022

Shock in Office Practice

Lead Author
Lokesh Tiwari

Co-Authors
Maninder Singh Dhaliwal, Ajit Chhetri

Under the Auspices of the IAP Action Plan 2022

Remesh Kumar R
IAP President 2022

Upendra Kinjawadekar
IAP President-Elect 2022

Piyush Gupta
IAP President 2021

Vineet Saxena
IAP HSG 2022–2023

© Indian Academy of Pediatrics

IAP Standard Treatment Guidelines Committee

Chairperson

Remesh Kumar R

IAP Coordinator

Vineet Saxena

National Coordinators

SS Kamath, Vinod H Ratageri

Member Secretaries

Krishna Mohan R, Vishnu Mohan PT

Members

Santanu Deb, Surender Singh Bisht, Prashant Kariya, Narmada Ashok, Pawan Kalyan