Myocarditis

76

Introduction

- ☑ Myocarditis is simply known as the inflammation of the myocardium and has a variable clinical presentation. Although autopsy studies have reported the incidence to be approximately 0.12–12%, the true incidence is difficult to ascertain because of its frequent subclinical presentation.
- ☑ Fulminant myocarditis is defined as sudden and severe inflammation of the myocardium resulting in myocyte necrosis, edema, and cardiogenic shock.
- ☑ Bimodal peak in incidence has been reported with most cases occur in infancy and adolescents, with those in infancy having worse outcomes.
- ☑ Dilated cardiomyopathy (DCM) can be a significant sequela and is a common indication for cardiac transplantation.
- ☑ Myocarditis is also identified as the cause of sudden unexpected death in young patients (16–20%).

Etiology

Myocarditis is most commonly caused by viral infection, but other causes such as bacterial, fungal, and parasitic infections; autoimmune diseases; and toxins must be considered. In areas with low vaccination rates, consideration should be given to diphtheria (especially in patients with heart block) and mumps **(Table 1)**.

TABLE 1: Various causes of myocarditis.

Etiology	***Examples***
Infectious	*Viral:* Adenoviruses, echoviruses, enteroviruses (e.g., coxsackieviruses), herpesviruses (human cytomegalovirus, Epstein–Barr virus, human herpesvirus 6), hepatitis C virus, human immunodeficiency virus, influenza A virus, and parvovirus B19 *Bacterial: Chlamydia, Corynebacterium diphtheriae*, *Klebsiella*, *Salmonella*, *Legionella*, *Mycobacterium tuberculosis*, *Mycoplasma*, *Staphylococcus*, *Streptococcus A*, *Streptococcus pneumoniae*, *Treponema pallidum*, and *Haemophilus influenzae* *Fungal: Actinomyces*, *Aspergillus, Candida,* and *Cryptococcus* *Helminthic: Echinococcus granulosus* and *Trichinella spiralis* *Protozoal: Toxoplasma gondii* and *Trypanosoma cruzi* *Rickettsial: Coxiella burnetii* and *Rickettsia typhi* *Spirochetal: Borrelia burgdorferi*, *Leptospira*, and *Treponema pallidum*
Autoimmune diseases	Celiac disease, Churg–Strauss syndrome, Crohn's disease, dermatomyositis, giant cell myocarditis, hypereosinophilic syndrome, Kawasaki disease, lupus erythematodes, lymphofollicular myocarditis, rheumatoid arthritis, sarcoidosis, scleroderma, and ulcerative colitis
Hypersensitivity reactions	Penicillin, ampicillin, cephalosporins, tetracyclines, sulfonamides, antiphlogistics, benzodiazepines, clozapine, loop and thiazide diuretics, methyldopa, smallpox vaccine, tetanus toxoid, and tricyclic antidepressants
Toxic reactions to drugs	Amphetamines, anthracyclines, catecholamines, cocaine, cyclophosphamide, 5-fluorouracil, phenytoin, and trastuzumab
Toxic	Amitriptyline, amphotericin B, cannabis, carbon monoxide, cyclophosphamide, electric shock, ethanol, hymenoptera, isoniazid, lead, lidocaine, methyldopa, nonsteroidal anti-inflammatory drugs, phenytoin, and snake or scorpion venom
Others	Arsenic, copper, iron, radiotherapy, and thyrotoxicosis

More recently, during the coronavirus disease-2019 (COVID-19) pandemic, a novel form of shock with ventricular dysfunction emerged in children and is attributed to severe acute respiratory syndrome coronavirus 2 (SARS-CoV-2). It is termed as multisystem inflammatory syndrome in children (MIS-C) and likely involves inflammation of the heart and vasculature during or after the active infectious phase.

Clinical Features

Acute myocarditis comprises a wide clinical spectrum including the asymptomatic patient with subclinical myocardial dysfunction to severe cardiac failure in shock or sudden cardiac death. In pediatrics, the symptoms and signs can mimic many other common diseases and a high index of clinical suspicion is imperative **(Table 2)**.

TABLE 2: Clinical characteristics at presentation.

History (%)	***Symptoms (%)***	***Signs (%)***
Viral prodrome (41–69)	Fatigue (25–70)	Tachypnea (52–60)
Arrhythmias (11–45)	Shortness of breath (35–69)	Tachycardia (32–57)
Syncope (4–10)	Fever (31–58)	Hepatomegaly (21–50)
Sudden cardiac death*	Nausea/vomiting or abdominal pain (28–48)	Respiratory distress (21–47)
	Rhinorrhea (38–44)	Murmur (26)
	Chest pain (24–42)	Gallop (20)
	Dyspnea (22–25)	Diminished pulses (16–21)
	Cough (17–44)	Edema (7)
	Palpitations (16)	Cyanosis (2)
	Diarrhea (8)	

*Unable to accurately estimate the frequency.
Source: Law YM, Lal AK, Chen S, Čiháková D, Cooper LT Jr, Deshpande S, et al. Diagnosis and management of myocarditis in children a scientific statement from the American Heart Association. Circulation. 2021;144:e123-e135.

Arrhythmias occur in up to 45% and include ventricular and atrial arrhythmias and high-grade atrioventricular block. Syncope occurs in ≈10%. Myocarditis can also present with sudden cardiac death.

Diagnosis

Laboratory Testing

Cardiac Biomarkers

- ☑ Traditional cardiac biomarkers [e.g., cardiac troponin I, troponin T (troponin leak), and creatine kinase B] reflect myocardial injury and are elevated in most, but not all, patients with myocarditis.
- ☑ Studies have shown that a negative troponin is helpful for ruling out myocarditis but has low specificity. It is important to interpret the troponin value in the context of the entire clinical picture and the degree of elevation does not consistently correlate with disease severity.

Diagnosis

Laboratory Testing

- ☑ B-type natriuretic peptide (BNP) and N-terminal pro-BNP (NT-proBNP) may be elevated in myocarditis and is believed to be secondary to ventricular enlargement and stretch of the cardiac myocytes. It is nonspecific and its elevation may aid in establishing a cardiac cause.
- ☑ Nonspecific serum markers of inflammation, including leukocyte count, erythrocyte sedimentation rate, and C-reactive protein, can be elevated, but normal values do not exclude an acute myocardial inflammatory process.
- ☑ Polymerase chain reaction (PCR) can identify viral genome in peripheral blood, stool, and respiratory secretions of patients with myocarditis in about one-third of cases and is often used as a surrogate of tissue PCR to make a presumed diagnosis. However, it should be noted that the correlation of peripheral samples with disease is poor. PCR is available for parvovirus B19, adenovirus, enteroviruses, Epstein–Barr, cytomegalovirus, and herpesvirus type-6.

Electrocardiography

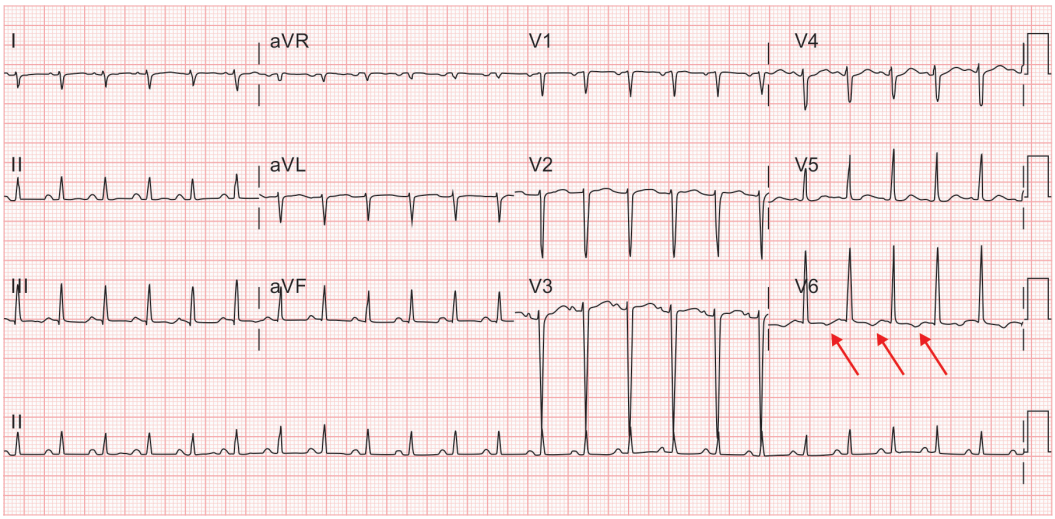

Fig. 1: T wave inversion in the lateral leads of a child presenting with myocarditis. T wave inversion in lateral leads is a sign of left ventricular (LV) strain which may be indicative of myocarditis.

Source: Dasgupta S, Iannucci G, Mao C, Clabby M, Oster ME. Myocarditis in the pediatric population: a review. Congenit Heart Dis. 2019;14(5):868-77.

Electrocardiography

- ☑ Arrhythmias associated with myocarditis may range from premature contractions (early sign) to complete atrioventricular block.
- ☑ An abnormal electrocardiography (ECG) has a high positive predictive value for the diagnosis of myocarditis but not a high negative predictive value.
- ☑ ECG features are variable and include sinus tachycardia, nonspecific ST-T-wave changes, T-wave inversion **(Fig. 1)**, ST-segment elevation, low voltage QRS complexes in the limb lead **(Fig. 2)**, and atrioventricular conduction delays.
- ☑ Myocarditis should always be ruled out in a patient with new-onset third-degree heart block.

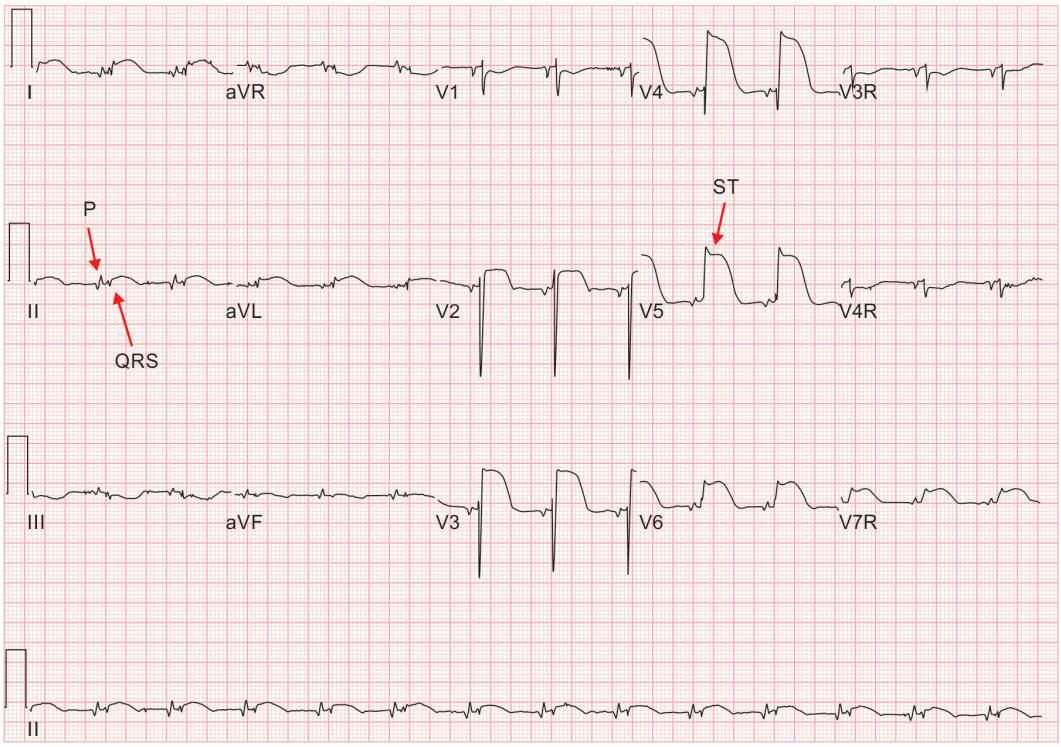

Fig. 2: Electrocardiogram from a child with parvovirus myocarditis demonstrating very-low-voltage QRS complexes in leads I through aVF, V1, and V4 through V7, V3R, and V4R, as well as ST elevation most marked in V2 through V7. This appearance is called "tombstoning". The P waves are actually larger.

Source: Tunuguntla H, Jeewa A, Denfield SW. Acute myocarditis and pericarditis in children. Pediatr Rev. 2019;40(1):14-25.

Echocardiography

Echo reliably demonstrates the variable findings associated with myocarditis, including the following:

- ☑ Subtle to profound changes in global LV or right ventricular systolic function, including regional wall motion abnormalities
- ☑ Variable degrees of LV enlargement
- ☑ Thickened myocardium from wall edema
- ☑ Pericardial effusion
- ☑ Intracardiac thrombus
- ☑ Functional valvar regurgitation.

A DCM phenotype with LV dilatation and diminished ejection fraction is the most common echo finding. LV end-diastolic dimension and severity of dysfunction may be associated with outcomes.

The assessment of right ventricular function is equally important as it has been described as a predictor of the outcome. Studies have demonstrated that the likelihood of death or cardiac transplantation was greater in patients with abnormal right ventricular function.

Cardiac Magnetic Resonance Imaging

Cardiac magnetic resonance (CMR) imaging is currently considered to be the noninvasive gold standard for diagnosing myocarditis and is only secondary to an endomyocardial biopsy (EMB) **(Box 1)**.

BOX 1: Diagnosis of myocarditis by cardiac magnetic resonance (CMR).

Revised Lake Louise criteria

CMR findings are consistent with myocarditis if the following criteria are met:

- ☑ Regional or global myocardial signal intensity increase in T2-weighted images or increase in the myocardial T2 relaxation time and one of the following two criteria
  1. The regional or global increase of the native myocardial T1 relaxation time
  2. Areas with high signal intensity in a nonischemic distribution pattern in late gadolinium enhancement images

Histopathology

Endomyocardial biopsy has been considered the gold standard in diagnosis of myocarditis since the proposal of the Dallas criteria in 1986 **(Table 3)**. Despite that, its use has decreased over time and its utility has been questioned. Reasons for this include low sensitivity due to sampling error, variability in pathologic interpretation, and potential complications such as myocardial perforation and tamponade.

TABLE 3: Classification of myocarditis based on endomyocardial biopsy using the Dallas criteria.

First biopsy	☑ Myocarditis with/without fibrosis ☑ Borderline myocarditis (rebiopsy may be indicated) ☑ No myocarditis
Subsequent biopsies	☑ Ongoing (persistent) myocarditis with or without fibrosis ☑ Resolving (healing) myocarditis with or without myocarditis ☑ Resolved (healed) myocarditis with or without myocarditis

Diagnosis

The classification for diagnostic certainty of myocarditis can be a helpful tool for incorporating the clinical signs and symptoms with the diagnostic studies obtained **(Table 4)**.

TABLE 4: A 3-tiered clinical classification for the diagnosis of myocarditis based on the level of diagnostic certainty.

	Criteria	***Histologic confirmation***	***Biomarker, electro-cardiography (ECG), or imaging abnormalities consistent with myocarditis***	***Treatment***
Possible subclinical acute myocarditis	In the clinical context of possible myocardial injury without cardiovascular symptoms but with at least one of the following: 1. Biomarkers of cardiac injury raised 2. ECG findings that suggest cardiac injury 3. Abnormal cardiac function on echocardiogram or cardiac MRI	Absent	Needed	Not known
Probable acute myocarditis	In the clinical context of possible myocardial injury with cardiovascular symptoms and at least one of the following: 1. Biomarkers of cardiac injury raised 2. ECG findings that suggest cardiac injury 3. Abnormal cardiac function on echocardiogram or cardiac MRI	Absent	Not needed	Per clinical syndrome
Definite myocarditis	Histologic or immunohistologic evidence of myocarditis	Needed	Not needed	Tailored to specific cause

Treatment

Therapy for pediatric myocarditis during the acute phase includes:

☑ *Hemodynamic support*:

- During acute presentation, infants and children with myocarditis usually have signs and symptoms of heart failure. Some of them present in life-threatening cardiogenic shock.
- Supportive care interventions depend upon the degree and severity of clinical presentation. Initial supportive treatment consists of supplemental oxygen/respiratory support and cautious fluid resuscitation.
- Children with mild symptoms can generally be managed with oral diuretics and afterload-reducing agents. Oral heart failure therapy should be initiated once the patient is beyond the acute stage of illness and shows persistent systolic dysfunction or heart failure. Angiotensin-converting enzyme (ACE) inhibitors (mainly enalapril) and beta-blockers (carvedilol) can be continued as reverse remodeling drugs, long-term along with decongestants.
- Children with more severe symptoms (i.e., decompensated heart failure or cardiogenic shock) may require intravenous inotropic support such as milrinone or dobutamine and low dose adrenaline (<0.05 µg/kg/min).
- Low cardiac output state should be treated promptly. Milrinone is typically used as a main stay of therapy for its inodilator properties provided the child is not in hypotension. Inotropes with vasopressor properties such as epinephrine are generally reserved for those with hypotension and cardiogenic shock because these agents have more chronotropic and arrhythmogenic potential.
- Calcium chloride/calcium gluconate infusion can also augment inotropy.
- Noninvasive or invasive positive pressure mechanical ventilation can improve cardiac function by reducing work of breathing, reducing LV afterload, and increasing systemic oxygen levels.
- Using induction drugs (while intubation) in a patient with severely depressed ventricular function carries considerable risks of hemodynamic deterioration and even cardiac arrest.

Hence, these children may require mechanical circulatory support (MCS) like extracorporeal membrane oxygenation (ECMO).

☑ *Recognition and treatment of arrhythmias*:

- High index of vigilance should be there in monitoring these children. Appearance of ventricular premature beats is an early sign and a clue to diagnosis.
- Loss of sinus rhythm may lead to acute deterioration of heart failure and worsening of cardiogenic shock.
- Clinically significant arrhythmias include ventricular arrhythmias and varying degrees of heart block, which may lead to deterioration of LV function and overall poor outcome.

- Most of the antiarrhythmic drugs have negative inotropic effect, which may deteriorate hemodynamic instability. These drugs should be used after carefully considering the risk versus benefit in the particular patient after consultation with pediatric cardiologist, if available.
- In general, arrhythmias can be approached and managed using Indian Academy of Pediatrics-Advanced Life Support (IAP-ALS) tachyarrhythmias and bradyarrhythmias algorithms.

☑ *Anticoagulation*:

- Anticoagulation to prevent venous thromboembolism is not routinely practiced for children with myocarditis and mild-to-moderate ventricular dysfunction unless there are other indications or additional risk factors (e.g., obesity and oral contraceptive use).
- Anticoagulation with aspirin, unfractionated heparin, low molecular weight heparin, or warfarin can be considered in children with severe ventricular dysfunction [~left ventricular ejection fraction (LVEF) < 20%] who may have increased risk for thrombus formation; or whenever there is documented thrombus. There is no standard practice regarding anticoagulation in children.
- Mostly, unfractionated heparin may be used during the acute phase while the patient is in the intensive care unit and then transition to aspirin once the clinical status has improved.
- Aspirin is continued until ventricular function has improved (e.g., LVEF > 40%).

☑ *Potential strategy for mechanical circulatory support* ***(Flowchart 1)****:*

- There should be vigilant monitoring of the cardiovascular status, including the rhythm. If the clinical trajectory is toward hemodynamic compromise, consideration should be given to transfer to a center that provides pediatric MCS and transplantation.
- Bradyarrhythmias and heart block may be associated with poor early outcome. Temporary transvenous pacing should be considered at the right time.
- Early intervention with MCS should be considered and can be life-saving. ECMO is a feasible choice because it can be deployed emergently and also considering the probability of a brisk cardiac recovery in myocarditis. If ECMO cannot be weaned, consideration is given to transition to durable ventricular assist device (VAD) as a bridge to recovery or transplantation. Patients who require long-term MCS or who recover from the acute episode but develop severe chronic heart failure may require heart transplantation.
- Regardless of the choice of MCS, early left-sided heart decompression is important in patients with severe LV dysfunction or stunning to maximize the opportunity for recovery. A percutaneous atrial septostomy, surgical placement of a vent, or use of Impella accomplishes LV unloading.

Flowchart 1: Mechanical circulatory support (MCS) in acute myocarditis.

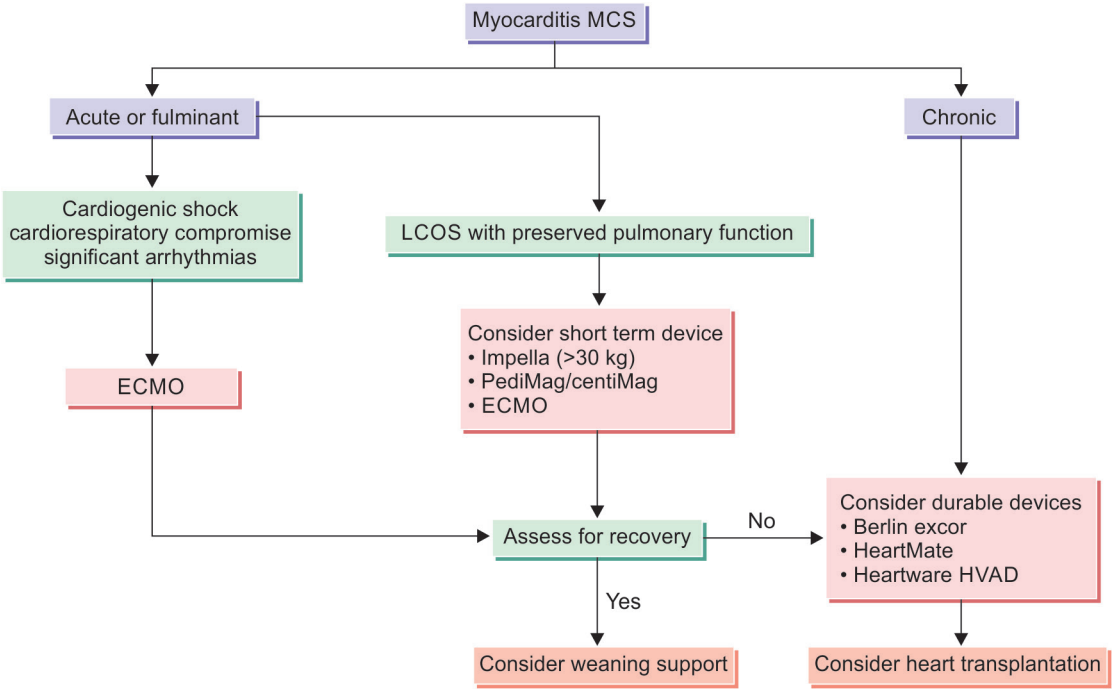

(ECMO: extracorporeal membrane oxygenation; LCOS: low cardiac output syndrome)
Source: Law YM, Lal AK, Chen S, Čiháková D, Cooper LT Jr, Deshpande S, et al. Diagnosis and management of myocarditis in children a scientific statement from the American Heart Association. Circulation. 2021;144: e123-e135.

☑ *Immunomodulatory therapy* ***(Table 5)***:

- Intravenous immunoglobulin (IVIg) is commonly used in children. IVIg has anti-inflammatory, antiviral, and immunomodulatory effects and is considered safe and familiar to most pediatricians.
- However, data are limited and inconclusive as to whether IVIg or glucocorticoids improve outcomes in pediatric myocarditis. Attempts at meta-analysis have not been informative, given small sample sizes and the quality of studies.
- Nevertheless, IVIg has been used commonly because myocarditis is associated with considerable risk of mortality and morbidity and the risks associated with IVIg are usually small in comparison. Drucker et al. suggested echocardiographic and survival benefits with IVIg.
- Corticosteroids are considered immunosuppressive, but they also have potent anti-inflammatory effects. In children, several small studies with prednisone plus azathioprine or cyclosporine, without controls, and often without biopsy or CMR evidence of myocarditis showed improvement, typically of LV function by echocardiography.

- Use of IVIg and glucocorticoids for children with myocarditis has become more common in the COVID-19 era since these therapies are first-line treatments for patients with COVID-19-related MIS-C, which often presents similarly to acute myocarditis. Based on the experience using these therapies in COVID-19-related illness, many experts apply this practice to patients with myocarditis due to other etiologies. Therapy for MIS-C may consist of IVIg, steroids, and other anti-inflammatory drugs used in atypical Kawasaki disease.
- A recent systematic review included two small adult trials and one small pediatric trial. In the pediatric trial, there was a trend toward improved transplant-free survival, but it did not reach statistical significance. LVEF at hospital discharge was higher in the IVIg group compared with control.
- Regarding the benefit of glucocorticoid therapy in patients with myocarditis, evidence of literature remains inconclusive. On a meta-analysis of trials that included children and adults, mortality rates were similar in patients treated with steroids and controls [relative risk 0.93, 95% confidence interval (CI) 0.70–1.24].
- Based on the limited available data, IVIg (2 g/kg over 24 hours) may be given for children with acute myocarditis. We feel that, given the considerable risks of death and morbidity associated with myocarditis, the potential side effects associated with IVIg are justified in this setting. It is reasonable to omit IVIg therapy in patients who are not severely affected.
- The dosing for IVIg in this setting is 2 g/kg administered in a single infusion over 8–24 hours. In obese patients, the dose should be based upon ideal body weight. In children with severe cardiac dysfunction, it can be given in divided doses over 2 days as they may not tolerate the volume load in a single infusion.
- Immunomodulatory or immunosuppressive therapy remains center and practitioner specific, and each center should develop its own multidisciplinary guidelines of care with ongoing review to ensure quality.

☑ *Antiviral therapies*: Viral infection may be the most common identified cause of myocarditis in children; however, the efficacy of antiviral therapy for myocarditis is uncertain and antiviral therapy is not a routine component of treatment for myocarditis in children. No evidence of support for interferon beta therapy in children with chronic DCM and confirmed myocardial viral infection.

TABLE 5: Drugs, indications, and dose.

Drug class and indication	***Drug***	***Dose***
Diuretics Anticongestive therapy for relief of symptoms	Furosemide	1–4 mg/kg/day Q6–12 hourly oral/IV Maximum: 6 mg/kg/dose (40 mg/dose)
Added when there is symptomatic heart failure, beneficial in the long-term	Aldactone	0–10 kg—6.25 mg Q12h 11–20 kg—12.5 mg Q12H 21–40 kg—25 mg Q12H >40 kg—25 mg Q8H

Contd...

Treatment

Contd...

Drug class and indication	*Drug*	*Dose*
ACE inhibitors Left ventricular dysfunction	Enalapril	0.1 mg/kg/dose, Q12H Maximum 2.5 mg/dose Increase over 2 weeks if required to maximum 0.5 mg/kg (adult 5–20 mg) Q12H (tablet available as 2.5 mg, 5 mg, and 10 mg)
Beta-blocker Added when there is symptomatic heart failure May be considered for ventricular ectopy	Carvedilol	0.1 mg/kg Q12H Maximum dose 3.125 mg/dose Increase every week by 0.1 mg/kg Maximum adult 25 mg Q12H (tablet available as 3.125 mg and 6.25 mg)
Inotropes	Adrenaline	0.1–2 µg/kg/min 0.3 mg/kg in 50 mL NS (1 mL/h = 0.1 µg/kg/min)
	Dobutamine	5–20 µg/kg/min 15 mg/kg in 50 mL NS (1 mL/h = 5 µg/kg/min
	Calcium gluconate 10%	0.1–0.4 mL/kg/h (undiluted calcium)
Phosphodiesterase III inhibitor (inodilator)	Milrinone	0.25–0.75 µg/kg/min
Calcium sensitizers	Levosimendan	0.2 µg/kg/min for 24 hours 0.3 mg/kg in 50 mL NS 1 mL/h = 0.1 µg/kg/min
Immunomodulatory No recommendation for the routine use in myocarditis	IV immunoglobulin	1–2 g/kg × 2 days 1 g/kg infusion over 12 hours

(ACE: angiotensin-converting enzyme; IV: intravenous)
Source: Shann F. Drug Doses, 17 edition. Parkville, Victoria: Collective Pty. Ltd., 2017.

Follow-up

- ☑ Regular cardiology follow-up incorporating ECG, echocardiography, and laboratory tests are essential.
- ☑ Discontinuation of reverse remodeling medications can be considered if all diagnostic testing is normal.
- ☑ Since children are active and many will recover functional capacity, exercise and activity restrictions demand special consideration, especially while active inflammation is present.

Indian Academy of Pediatrics (IAP)

STANDARD TREATMENT GUIDELINES 2022

Scalds and Burns

Lead Author

Sujata Sarabahi

Co-Authors

Palash Ranjan Gogoi, Balachandar D

Under the Auspices of the IAP Action Plan 2022

Remesh Kumar R
IAP President 2022

Upendra Kinjawadekar
IAP President-Elect 2022

Piyush Gupta
IAP President 2021

Vineet Saxena
IAP HSG 2022–2023

© Indian Academy of Pediatrics

IAP Standard Treatment Guidelines Committee

Chairperson

Remesh Kumar R

IAP Coordinator

Vineet Saxena

National Coordinators

SS Kamath, Vinod H Ratageri

Member Secretaries

Krishna Mohan R, Vishnu Mohan PT

Members

Santanu Deb, Surender Singh Bisht, Prashant Kariya, Narmada Ashok, Pawan Kalyan

Scalds and Burns

77

Introduction

- ☑ Burn is a leading cause of unintentional injury in children, second only to motor vehicle accidents.
- ☑ The leading cause of burns in the majority is scalds (70–85%) followed by flame burns, electrical, and chemical burns.

Important Issues Specific to Pediatric Burns

The following essential points must be considered while dealing with burn injuries in children:

- ☑ Children have a different local and systemic response to burn injury compared to adults
- ☑ Children have relatively thinner and sensitive skin
- ☑ They have larger surface area relative to body mass
- ☑ Their temperature regulatory mechanism is different
- ☑ There is a greater risk of hypothermia
- ☑ They have increased fluid requirements
- ☑ Burns may be the result of child abuse and neglect.