Antenatally Detected Hydronephrosis

91

Introduction

Hydronephrosis is reported 1–5% of antenatal scans and is one of the most commonly reported anomalies. Antenatal hydronephrosis (ANH) is present if renal pelvic anteroposterior diameter (RPAPD) is ≥4 mm (second trimester) or 7 mm (third trimester). The clinical approach to ANH includes a careful interpretation of the ultrasonography report for significant findings and grading of severity **(Box 1 and Table 1)**, counseling of parents, follow-up imaging during pregnancy **(Flowchart 1)** and after birth **(Flowchart 2)**, as well as management of specific causes.

BOX 1: What to look for in the ultrasonography report?

- ☑ Renal pelvic anteroposterior diameter (RPAPD)
- ☑ *Calyceal dilatation:* Central or peripheral
- ☑ Renal parenchymal thinning
- ☑ *Renal parenchymal abnormalities:* Poor corticomedullary differentiation, increased renal echogenicity, renal cysts, and perinephric urinoma
- ☑ Ureteral dilatation
- ☑ *Bladder abnormalities:* Bladder wall thickness and keyhole sign
- ☑ Oligohydramnios
- ☑ Major extrarenal anomalies—cardiovascular, neurological, gastrointestinal, and skeletal malformations
- ☑ Extrarenal soft signs—increased nuchal translucency, absent nasal bone, echogenic bowel, echogenic focus in heart, shortened long bones, choroid plexus cyst, and ventriculomegaly

The grading of severity of ANH is performed using many systems of classification. The most commonly used systems are the RPAPD and the Society for Fetal Urology (SFU) classifications; however, the more recent and comprehensive urinary tract dilatation (UTD) classification has been validated.

TABLE 1: Assessment of severity of antenatally detected hydronephrosis.

Based on pelvic APD			***SFU classification***		***UTD classification***	
	Second trimester	Third trimester	SFU1	Urine barely split pelvis	UTDA1	Central or no calyceal dilatation
Mild	4–6 mm	7–9 mm	SFU2	Moderate renal pelvis splitting confined to renal border with dilated major calyces		
Moderate	7–10 mm	10–15 mm	SFU3	Pelvis distended beyond renal border, major and minor calyces dilated, and parenchyma spared	UTDA2-3	Any one of the following: Peripheral calyceal dilatation, abnormal parenchymal thickness/appearance, ureters abnormal, bladder abnormal, unexplained hydramnios
Severe	>10 mm	>15 mm	SFU4	Parenchyma thinned		

(APD: anteroposterior diameter; SFU: Society for Fetal Urology; UTD: urinary tract dilatation)

The most common causes of ANH are transient hydronephrosis (50–70%), pelviureteric junction obstruction (PUJO) (10–50%), vesicoureteral reflux (VUR) (10–40%), ureterovesical junction obstruction or megaureter (5–15%), multicystic dysplastic kidney (2–5%), and posterior urethral valves (PUVs) (1–5%). The vast majority of the causes are relatively innocuous, especially if ANH is mild. However, the uncommon but ominous conditions with lower urinary tract obstruction (LUTO) should be detected and treated as soon as possible after birth.

Flowchart 1: Antenatal management.

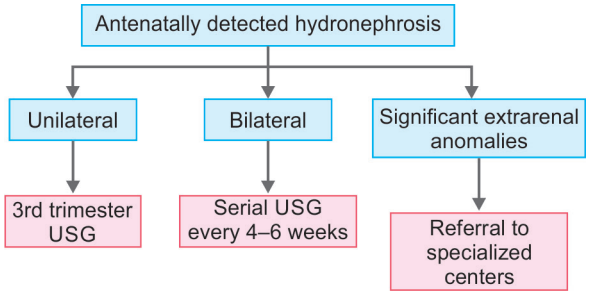

(USG: ultrasonography)

Ultrasonography after birth should be delayed till adequate hydration is ensured. Micturating cystourethrography should be performed at 4–6 weeks of life. Imaging should be more rapid if LUTO is suspected. Diuretic renography should be delayed until renal function is adequately mature to excrete tracer.

Flowchart 2: Postnatal management.

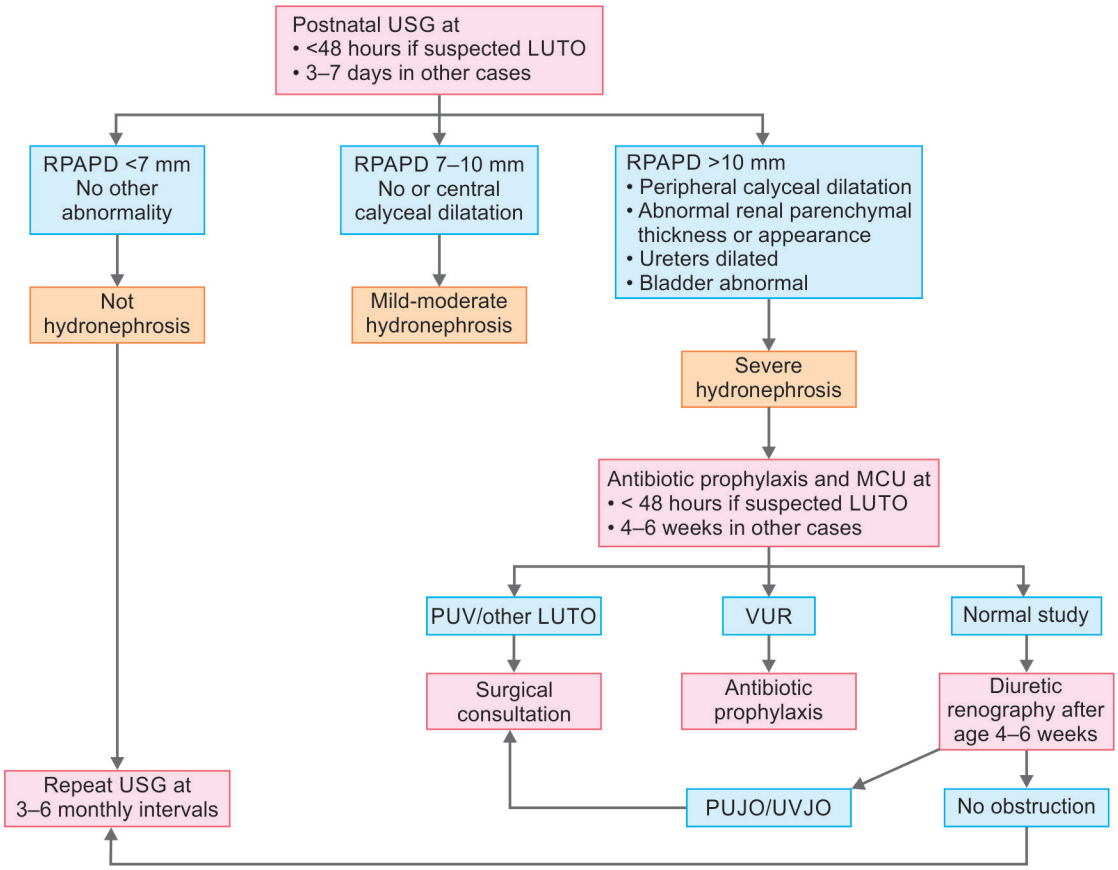

(LUTO: lower urinary tract obstruction; MCU: micturating cystourethrography; PUJO: pelviureteric junction obstruction; PUV: posterior urethral valve; RPAPD: renal pelvic anteroposterior diameter; USG: ultrasonography; UVJO: ureterovesicular junction obstruction; VUR: vesicoureteral reflux)

- ☑ While awaiting evaluation after birth, infants with severe ANH should be administered antibiotic prophylaxis (cephalexin 10 mg/kg/day, single dose).
- ☑ Boys with PUV require immediate catheterization, correction of fluid and electrolyte abnormalities, cystoscopic ablation of valves, and follow-up management of the valve–bladder syndrome.
- ☑ Infants with VUR should be treated with antibiotic prophylaxis using cephalexin (10 mg/kg/day) till age of 3–6 months followed by cotrimoxazole (trimethoprim 1–2 mg/kg/day) and surgical reimplantation in case of breakthrough febrile urinary tract infection (UTI).
- ☑ Pyeloplasty may be considered in PUJO if there in case of (1) high RPAPD or parenchymal thinning on ultrasonography or (2) obstructive pattern of drainage curves, long t1/2 (>20 minutes), and low or deteriorating relative renal function on diuretic renography.

Further Reading

- ☑ Fernbach SK, Maizels M, Conway JJ. Ultrasound grading of hydronephrosis: introduction to the system used by the Society for Fetal Urology. Pediatr Radiol. 1993;23:478-80.
- ☑ Indian Society of Pediatric Nephrology, Vijayakumar M, Kanitkar M, Nammalwar BR, Bagga A. Revised statement on management of urinary tract infections. Indian Pediatr. 2011;48:709-17.
- ☑ Nguyen HT, Benson CB, Bromley B, Campbell JB, Chow J, Coleman B, et al. Multidisciplinary consensus on the classification of prenatal and postnatal urinary tract dilation (UTD classification system). J Pediatr Urol. 2014;10:982-98.
- ☑ Sarin YK. Is it always necessary to treat an asymptomatic hydronephrosis due to ureteropelvic junction obstruction? Indian J Pediatr. 2017;84:531-9.
- ☑ Sinha A, Bagga A, Krishna A, Bajpai M, Srinivas M, Uppal R, et al. Revised guidelines on management of antenatal hydronephrosis. Indian J Nephrol. 2013;23(2):83-97.

Indian Academy of Pediatrics (IAP)

STANDARD TREATMENT GUIDELINES 2022

Gastroesophageal Reflux Disease

Lead Author

Ramesh Srinivasan

Co-Authors

Jaswinder Kaur, Jubin Kamar

Under the Auspices of the IAP Action Plan 2022

Remesh Kumar R
IAP President 2022

Upendra Kinjawadekar
IAP President-Elect 2022

Piyush Gupta
IAP President 2021

Vineet Saxena
IAP HSG 2022–2023

© Indian Academy of Pediatrics

IAP Standard Treatment Guidelines Committee

Chairperson

Remesh Kumar R

IAP Coordinator

Vineet Saxena

National Coordinators

SS Kamath, Vinod H Ratageri

Member Secretaries

Krishna Mohan R, Vishnu Mohan PT

Members

Santanu Deb, Surender Singh Bisht, Prashant Kariya, Narmada Ashok, Pawan Kalyan