Neurocysticercosis

99

Introduction

- ☑ Neurocysticercosis (NCC) is an easily treatable entity if diagnosed in time and appropriate management is done.
- ☑ A recent study from North India showed that the prevalence of NCC was 4.5% in children presenting with the first episode of seizure or acute focal neurological deficit without fever.

Clinical Features

- ☑ Neurocysticercosis can present with one or more of the following clinical features:
  - Seizures (focal/generalized/unknown onset)
  - *Features of increased intracranial pressure:* Headache, vomiting, and diplopia/blurring of vision/squint
- ☑ Absence of fever/short duration of symptoms/no history of tuberculosis (TB) contact are some clinical features that may favor a diagnosis of NCC over tuberculoma.

Diagnosis

Neuroimaging

- ☑ Plain computed tomography (CT) and contrast-enhanced CT of the brain show nodular calcification, cystic or ring-enhancing lesions (RELs), and scolex with edema.
- ☑ If the imaging features are unclear or to differentiate from other REL, then contrast-enhanced magnetic resonance imaging (MRI) brain and other sequences such as susceptibility weighted imaging (SWI), three-dimensional (3D) constructive interference in steady state (CISS)/fast imaging employing steady-state acquisition (FIESTA)/magnetic resonance sialography (MRS) can be considered.
- ☑ Imaging features favoring tuberculoma are T2 hypointense core, large size (>2 cm), thick and irregular walls, marked perilesional edema with mass effect, and associated basal meningitis.
- ☑ Serological tests are not recommended for diagnosis and management of children with NCC.
- ☑ Routine screening of family members of children with NCC is not recommended.

Various stages of neurocysticercosis are presented in **Table 1**.

TABLE 1: Stages of neurocysticercosis.

Stage	***CT findings***	***MRI findings***
Noncystic	Often invisible	Often invisible
Vesicular	10–20 mm cyst with little or no or minimal pericystic edema or contrast enhancement, scolex visible (hole with a dot appearance)	Cyst signal intensity same as cerebrospinal fluid (CSF), little or no contrast enhancement, scolex visible
Colloidal vesicular	The cyst may be hyperattenuating, and pericystic enhancement present	Cyst contents hyperintense on T1 and T2, the wall is thick and hypointense, pericystic enhancement present
Granular nodular	Similar to colloidal vesicular with thicker ring enhancement and more edema	Similar to colloidal vesicular with thicker ring enhancement and more edema
Calcified nodular	Hyperattenuating calcific nodule, no edema, and no enhancement	Hypointense nodule, no edema, no enhancement

Management of NCC is described in **Flowchart 1**.

Flowchart 1: Management of NCC.

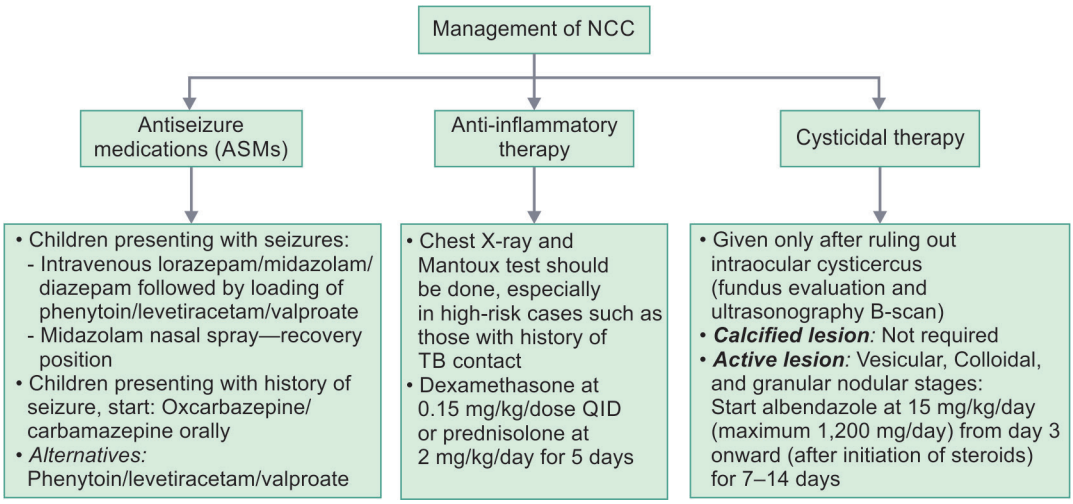

- ☑ Albendazole (15 mg/kg/day) may be combined with praziquantel (50 mg/kg/day) for 10–14 days for more than two viable cysts.
- ☑ Antihelminthics are not recommended in more than five viable cysts and/or cysticercal encephalitis ["starry-sky" appearance in contrast-enhanced computed tomography (CECT)/ MRI brain], to avoid worsening of perilesional edema leading to raised intracranial pressure.
- ☑ Intravenous steroids are the mainstay of therapy in children with cysticercal encephalitis. Injectable dexamethasone (0.6 mg/kg/day, maximum 16 mg/day) or pulse methylprednisolone (30 mg/kg/day, maximum 1,000 mg/day) for 3–5 days followed by tapering may be used.
- ☑ There is no role of routine prophylaxis with antiseizure medications (ASMs) in children with NCC who do not present with seizures.
- ☑ Adequate food, water, and hand-hygiene measures should be explained to the patient and family to prevent a recurrence.

Follow-up

- ☑ Repeat CECT/CE-MRI should be done after 6 months of the first scan.
- ☑ If follow-up scan is suggestive of resolution of lesion, then ASMs can be tapered and stopped.
- ☑ If the lesion is calcified, then continue ASMs for 2 years seizure-free interval.
- ☑ If there is the persistence of lesion, then retreatment with albendazole or a combination of albendazole and praziquantel can be used.

Further Reading

- ☑ García HH, Evans CA, Nash TE, Jain AP. Current consensus guidelines for the treatment of neurocysticercosis. Clin Microbiol Rev. 2002;15(4):747-56.
- ☑ Kimura-Hayama ET, Higuera JA, Corona-Cedillo R, Chávez-Macías L, Perochena A, Quiroz-Rojas LY, et al. Neurocysticercosis: Radiologic-Pathologic Correlation. Radiographics. 2010;30:1705-19.
- ☑ Kumar A, Mandal A, Sinha S, Singh A, Das RR. Prevalence, response to cysticidal therapy, and risk factors for persistent seizure in Indian children with neurocysticercosis. Int J Pediatr. 2017;2017: 8983958.
- ☑ Sankhyan N, Kadwa RA, Kamate M, Kannan L, Kumar A, Passi GR, et al. Management of Neurocysticercosis in children: Association of Child Neurology Consensus Guidelines. Indian Pediatr. 2021;58(9):871-80.
- ☑ White AC Jr, Coyle CM, Rajshekhar V, Singh G, Hauser WA, Mohanty A, et al. Diagnosis and treatment of neurocysticercosis: 2017 Clinical Practice Guidelines by the Infectious Diseases Society of America (IDSA) and the American Society of Tropical Medicine and Hygiene (ASTMH). Am J Trop Med Hyg. 2018;98(4):945-66.

Indian Academy of Pediatrics (IAP)

STANDARD TREATMENT GUIDELINES 2022

Attention Deficit Hyperactivity Disorder

Lead Author

Jeeson C Unni

Co-Authors

Leena Deshpande, Ajay Srivastava

Under the Auspices of the IAP Action Plan 2022

Remesh Kumar R
IAP President 2022

Upendra Kinjawadekar
IAP President-Elect 2022

Piyush Gupta
IAP President 2021

Vineet Saxena
IAP HSG 2022–2023

© Indian Academy of Pediatrics

IAP Standard Treatment Guidelines Committee

Chairperson

Remesh Kumar R

IAP Coordinator

Vineet Saxena

National Coordinators

SS Kamath, Vinod H Ratageri

Member Secretaries

Krishna Mohan R, Vishnu Mohan PT

Members

Santanu Deb, Surender Singh Bisht, Prashant Kariya, Narmada Ashok, Pawan Kalyan