Snakebite

102

Introduction

Snakebite is an acute life-threatening time limiting and preventable medical emergency faced by mainly rural population in India. Most deaths due to venomous snakebites in India are caused by four species—common cobra, common krait, Russell's viper, and saw-scaled viper.

Clinical Assessment

- ☑ Witnessed snakebite or not?
- ☑ History of local pain, diplopia, drooling, breathing difficulty, bleeding, abdominal pain, and vomiting
- ☑ *Local examination*: Fang marks, swelling, tenderness, necrosis, blisters, and regional lymphadenopathy
- ☑ *Neurological examination*: Six Ds (diplopia, dysarthria, dysphonia, dyspnea, and dysphagia) and two Ps (ptosis and paralysis of limbs and respiratory muscle). Ptosis and wrinkling of forehead is the earliest sign. Inability to lift the neck when lying down indicates impending respiratory failure. Breathing difficulty (paradoxical breathing, single breath count in older child, and weak cough/cry in infant).
- ☑ *Occult snakebite*: Krait bites often present early in the morning with paralysis that can be mistaken for a stroke. Sometimes history of sleeping outdoors/indoors with open doors in villages with early morning awakening followed by abdominal pain, vomiting, and descending paralysis may be the presentation of krait bite. There will be no local swelling/bleeding. Clotting time will be normal.

Bedside Investigations

20-minute Whole Blood Clotting Test

A few mL of fresh venous blood is placed in a new, clean, and dry glass vessel (such as a test tube) and left at ambient temperature for 20 minutes and then gently tilted, not shaken. If the blood is still liquid, then the patient has incoagulable blood.

Repeat 20-minute Whole Blood Clotting Test

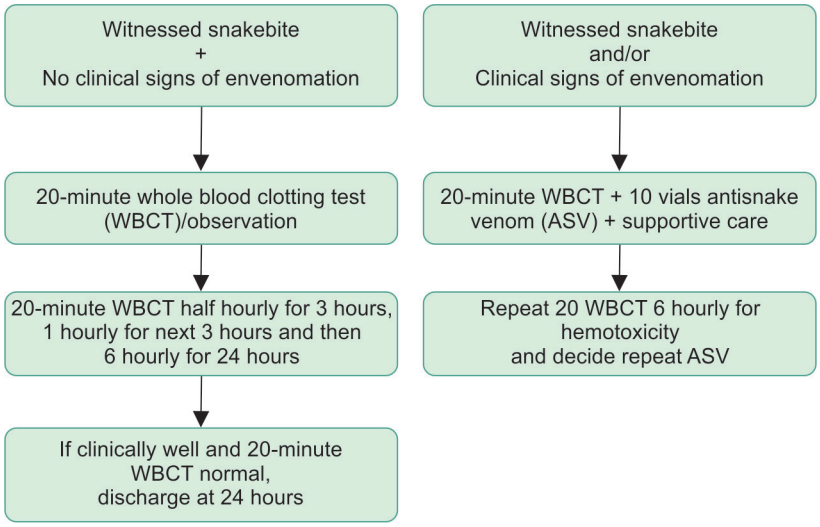

TABLE 1: Summary of clinical features of different snakebites.

Feature	*Cobra*	*Common krait*	*Russell's viper*	*Saw-scaled viper*	*Hump-nosed viper*
Local pain/tissue damage	Yes	No	Yes	Yes	Yes
Ptosis/neurotoxicity	Yes	Yes	Yes	No	No
Response to neostigmine	Yes	No	No	No	No
Hemotoxicity	No	No	Yes	Yes	Yes
Renal complications	No	No	Yes	No	Yes
Response to antisnake venom (ASV)	Yes	Yes	Yes	Yes	No

First Aid Protocol—Use "Do it RIGHT" Mnemonic (Table 2)

TABLE 2: First Aid Protocol—"Do it RIGHT".

Reassure	70% snakebites nonvenomous; 50% of venomous snakebites are dry bites
Immobilize the limb	☑ As you would do for fractured limb **(Fig. 1)**; should not move the bitten limb; to prevent systemic spread of venom ☑ If it will take >30 minutes to reach hospital, pressure immobilization method (PIM) **(Figs. 2A to F)** can be done for suspected neurotoxic snakebite, by trained person using crepe bandage
GH	Get to hospital immediately using best available transport (victim should not walk in lower limb bites) [for assessment and early administration of antisnake venom (ASV)]
Tell the doctor of systemic symptoms	For early identification of envenomation and early ASV administration
Don'ts	
Tie a tight tourniquet—can cause gangrene	
Cut the bite area and suck out blood—harmful	
Use herbs, ice packs, and snake stones—useless and delays ASV	

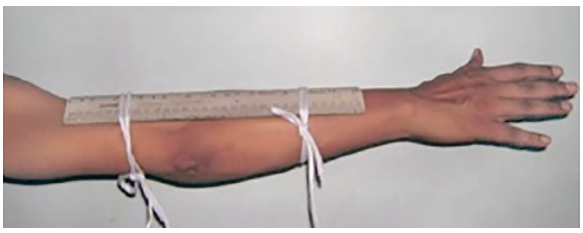

Fig. 1: Technique of immobilization of bitten limb.
Source: Ministry of Health and Family Welfare. Standard Treatment Guidelines—Management of Snake Bite. Government of India: Ministry of Health and Family Welfare; 2016.

Pressure immobilization method

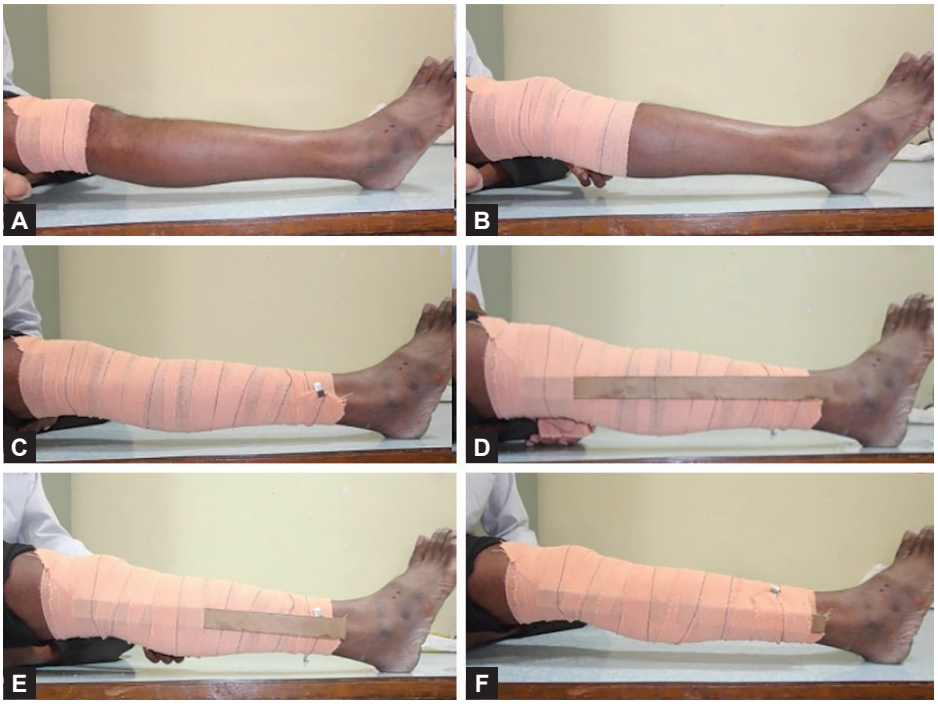

Figs. 2A to F: Pressure immobilization method (PIM) (Sunderland method).
Source: Ministry of Health and Family Welfare. Standard Treatment Guidelines—Management of Snake Bite. Government of India: Ministry of Health and Family Welfare; 2016.

Pressure immobilization method involves bandaging the bitten limb, up to the proximal major joint using a bandage or pressure pad, similar to the one applied for a sprain (50–70 mm Hg pressure). PIM obstructs lymphatic and venous drainage, preventing the absorption of large molecule neurotoxins into the systemic circulation. Make sure that the distal pulses are well palpable. The limb must be splinted as movement will increase systemic absorption.

The foremost priority in the management of snakebite in the emergency room is to support the patient with life-threatening respiratory depression, cardiac failure, or shock.

Handling Tourniquets or Pressure Immobilization Method (If had been Applied)

Sudden removal can lead to a massive surge of venom leading to neurological paralysis, hypotension due to vasodilation, etc. Be prepared to handle the complications and to start ASV. If the tourniquet has occluded the distal pulse, then a blood pressure cuff can be applied to reduce the pressure slowly.

Antisnake Venom

Antisnake venom remains the cornerstone in the management of snakebite envenomation. The currently available ASV in India is polyvalent, containing equine immunoglobulins to the four common snake venoms—Russell's viper, saw-scaled viper, common cobra, and common krait. The immunoglobulins attach to the venom molecule making it unable to bind to the target tissue.

Antisnake venom is produced in both lyophilized form (less rigid cold chain and longer shelf life) and liquid form (less preferable as cold chain is crucial).

Antisnake venom should not be used in asymptomatic bites with normal WBCT but must wait for signs of envenomation.

Indications for Antisnake Venom

☑ *Systemic envenomation*:

- *Evidence of coagulopathy*: Primarily detected by 20-minute WBCT or visible spontaneous systemic bleeding, gums, etc.
- *Evidence of neurotoxicity*: Ptosis, external ophthalmoplegia, muscle paralysis, inability to lift the head, etc.

☑ *Local envenomation*: Severe current, local swelling involving more than half of the bitten limb (in the absence of a tourniquet). In the case of severe swelling after bites on the digits (toes and especially fingers).
(Purely a local swelling, even if accompanied by a bite mark from an apparently venomous snake, is not grounds for administering ASV).

Antisnake Venom Test dose Need not be Administered

Test doses have been shown to have no predictive value in detecting anaphylactoid or late serum reactions.

Antisnake venom administration: *Dosage*—it is of 10 vials. Each vial is dissolved in 10 mL saline. Total dose is diluted in 10 mL/kg 0.9% saline or 5% dextrose and given as an infusion over 1 hour. The patient should be closely monitored. Keep injection adrenaline 1:1,000; 0.01 mg/kg ready.

Response to ASV: If an adequate dose of appropriate antivenom has been administered, the following responses occur:

- ☑ Spontaneous systemic bleeding usually stops within 15 minutes.
- ☑ Blood coagulability is usually restored in 6 hours.
- ☑ Postsynaptic neurotoxic envenoming such as the cobra may begin to improve as early as 30 minutes, but can take several hours. Presynaptic neurotoxic envenoming such as the krait usually takes a considerable time to improve.

Repeat doses: Antihemostatic:

- ☑ After 6 hours, WBCT is repeated and a further dose 5–10 vials should be administered over 1 hour, if WBCT abnormal.
- ☑ This 6 hourly pattern (time for liver to replace clotting factors) is repeated until the coagulation is restored.
- ☑ If 30 vials have been administered and there is no improvement, fresh-frozen plasma (FFP) or factors can be considered. Further ASV should not be given.

Repeat doses: Neurotoxic:

- ☑ If the initial dose has been unsuccessful in reducing the symptoms, then a further dose of 10 vials should be administered, after 1–2 hours.
- ☑ Once the patient is in respiratory failure, has received 20 vials of ASV, and is supported on a ventilator, ASV therapy should be stopped.

Antisnake Venom in Special Situations

Newborn and small infants: ASV dose is same and independent of weight. But total volume is restricted to 5 mL/kg and given more slowly to prevent fluid overload.

Antisnake Venom dosage in victims requiring lifesaving surgery: Before surgery, coagulation must be restored to avoid catastrophic bleeding with higher initial dose of ASV of 25 vials.

Victims who arrive late: If coagulopathy is present, administer ASV. In case of neurotoxic envenomation with respiratory failure on ventilator, administer 8–10 vials of ASV to ensure that no unbound venom is present. No need of ASV for ptosis alone persisting without progression.

Adverse Antisnake Venom Reactions

Adverse ASV reactions are of three types **(Table 3)**.

TABLE 3: Adverse antisnake venom (ASV) reactions.

Early anaphylactic reaction: ☑ Usually occurs 10 minutes to 6 hours post-ASV ☑ Starts with urticaria, irritability, abdomen pain, and tachycardia ☑ Often progresses to cause hypotension, angioedema, and shock	☑ No need of routine prophylactic medication before ASV ☑ At the first sign of a reaction, stop ASV ☑ Immediately administer adrenaline 0.01 mg/kg (1 in 1,000 dilutions) intramuscularly ☑ Repeat every 5–10 minutes if symptoms persist ☑ Pheniramine maleate (0.5 mg/kg IV) and hydrocortisone (2–5 mg/kg IV) can be added ☑ ASV should be restarted slowly after clinical stabilization and rate increased to normal ☑ *Persistent shock*: Normal saline bolus and adrenaline infusions can be given
Pyrogenic reaction: ☑ Usually 1–2 hours after ASV ☑ Includes fever, chills, and rigors ☑ Caused by pyrogen contamination during ASV manufacturing	☑ Paracetamol and other cooling procedures (tepid sponging and fanning) ☑ No need of stopping ASV
Late (serum sickness like) reactions: ☑ Develops 1–12 days post ASV ☑ Fever, vomiting, recurring urticaria, arthralgia, myalgia, lymphadenopathy, and nephritis	☑ Prednisolone (0.7 mg/kg/day) for 5–7 days, with or without oral chlorpheniramine maleate (0.25 mg/kg/day)

Antisnake Venom

Neurotoxicity Management

- ☑ Snake venoms can cause neurotoxicity by blocking either presynaptic (kraits) or postsynaptic (cobras) neuromuscular junction (NMJ). Those which produce postsynaptic NMJ blockade, experience improvement with the use of anticholinesterase drugs.
- ☑ Thus all children with neurotoxic envenomation are given a trial of anticholinesterase (AN challenge test).
- ☑ Injection atropine (0.05 mg/kg, IV), followed by neostigmine (0.04 mg/kg, IV) and dose of 0.01 mg/kg repeated at 30-minute interval for five doses. Those who respond have 50% improvement in ptosis within three doses. The responders are continued on atropine with neostigmine, at 1 hour, 2 hours, 6 hours, 12 hours, and 24 hours.
- ☑ If child presents with respiratory failure, intubation and ventilation is the priority followed by ASV infusion.

In-hospital Management

Local Swelling

- ☑ Paracetamol/tramadol for pain. Avoid nonsteroidal anti-inflammatory drugs (NSAIDs).
- ☑ Injection ceftriaxone/amoxicillin/clavulanate + metronidazole administered for 7 days or more.
- ☑ Close monitoring for features of necrosis/compartment syndrome.

Complications of Snakebite (Table 4)

These complications are ideally managed in a tertiary referral hospital with pediatric intensive care unit (PICU) facility. Early identification and timely referral can be lifesaving.

TABLE 4: Clinical presentation and management of snakebite.

Clinical presentation	***Management***
Locked-in syndrome (LIS): ☑ Occurs in krait/cobra bite due to neuromuscular blockade ☑ Patient will be conscious but unable to communicate, open eyes, or move any limb. ☑ Respiratory paralysis ☑ Pupils will be fixed and dilated ☑ If there was respiratory arrest, may be confused with brain death	☑ High index of suspicion is needed. EEG will show normal electrical activity. ☑ Ventilation and PICU care ☑ Spontaneous recovery after synthesis of new neuromuscular junction and vesicle happens after few days. ☑ Duration can vary from 30 hours to 6 days (krait takes longer to recover)
Compartment syndrome: ☑ Occurs in viper/sometimes cobra bite due to progressive local swelling and cellulitis ☑ May be aggravated by tourniquet ☑ Diagnosed by 5Ps—pain (severe), pallor, paraesthesia, pulselessness, and paralysis/weakness of compartment muscle	☑ Intracompartmental pressure > 40 mm Hg ☑ Vascular Doppler showing absent distal flow ☑ Fasciotomy after correction of coagulopathy (ASV and blood products)
Venom-induced consumption coagulopathy: ☑ Occurs in viper bite due to procoagulant toxins in venom causing microthrombi and consumption coagulopathy ☑ Local and systemic bleeding	☑ PT, aPTT, INR, platelet count, FDP, and D-dimer ☑ Adequate ASV ☑ Blood products (packed cells, FFP, cryoprecipitate, and platelets) for clinical bleeding/planned invasive procedure

Contd…

Complications of Snakebite (Table 4)

Contd…

Clinical presentation	*Management*
Snakebite-induced thrombotic microangiopathy: ☑ Syndrome of microangiopathic hemolytic anemia, thrombocytopenia, and acute renal failure	☑ CBC, peripheral smear, reticulocyte count, LDH, and serum creatinine ☑ Supportive care—blood products for bleeding, dialysis if needed for AKI ☑ Plasmapheresis is unproven
Acute kidney injury: ☑ Viper bites cause microthrombi in renal vessels due to hemotoxins ☑ Myotoxic sea snakes and viper bite with significant cellulitis/compartment syndrome cause rhabdomyolysis, myoglobinuria, and AKI	☑ Serial monitoring of BP, urine output, and RFT ☑ Timely and adequate amount of ASV ☑ Conservative management—fluids, electrolytes, and antihypertensives ☑ Hemodialysis/peritoneal dialysis, if conservative management fails ☑ Blood products to correct coagulopathy before dialysis catheter insertion

(AKI: acute kidney injury; aPTT: activated partial thromboplastin time; ASV: antisnake venom; BP: blood pressure; CBC: complete blood count; EEG: electroencephalogram; FFP: fresh frozen plasma; INR: international normalized ratio; LDH: lactate dehydrogenase; PICU: pediatric intensive care unit; PT: prothrombin time; RFT: renal function test)

Further Reading

- ☑ Ministry of Health and Family Welfare. Standard Treatment Guidelines—Management of Snake Bite. Government of India: Ministry of Health and Family Welfare; 2016.
- ☑ Pugh RN, Theakston RD. Fatality following use of a tourniquet after viper bite envenoming. Ann Trop Med Parasitol. 1987;81:77-8.
- ☑ Simpson ID. The Pediatric Management of Snakebite: The National Protocol. Indian Pediatr. 2007;44:173-6.
- ☑ Sutherland SK, Coulter AR, Harris RD. Rationalisation of first-aid methods for elapid snakebites. Lancet. 1979;1:183-5.
- ☑ Warrell DA. Guideline for Management of Snakebite. Geneva, Switzerland: World Health Organization; 2010.

Indian Academy of Pediatrics (IAP)

STANDARD TREATMENT GUIDELINES 2022

Neonatal Cholestasis

Lead Author

Surender Kumar Yachha

Co-Authors

Sushil Choudhary, Mohit Sahni

Under the Auspices of the IAP Action Plan 2022

Remesh Kumar R
IAP President 2022

Upendra Kinjawadekar
IAP President-Elect 2022

Piyush Gupta
IAP President 2021

Vineet Saxena
IAP HSG 2022–2023

© Indian Academy of Pediatrics

IAP Standard Treatment Guidelines Committee

Chairperson

Remesh Kumar R

IAP Coordinator

Vineet Saxena

National Coordinators

SS Kamath, Vinod H Ratageri

Member Secretaries

Krishna Mohan R, Vishnu Mohan PT

Members

Santanu Deb, Surender Singh Bisht, Prashant Kariya, Narmada Ashok, Pawan Kalyan

Neonatal Cholestasis

103

Definition

Neonatal cholestasis (NC) is defined as conjugated bilirubin >1 mg/dL (if total <5 mg/dL) or >20% of total serum bilirubin (if total >5 mg/dL) with passage of dark-colored urine staining the diapers with or without acholic stools.

Causes of Neonatal Cholestasis in India

Disease groups (N = 1,008)	***Causes in each subgroup***
A. *Hepatocellular 53% (n = 533)*	
Neonatal hepatitis 47% (n = 468)	☑ Idiopathic giant cell hepatitis ☑ TORCH infections ☑ Sepsis ☑ Other causes such as malaria and urinary tract infection (UTI)
Metabolic 4% (n = 43)	Galactosemia, alpha-1-antitrypsin (α1AT) deficiency (suspected), total parental nutrition (TPN) related, tyrosinemia, storage disorders, and hemochromatosis
Other causes 2% (n = 22)	Inspissated bile plug syndrome, progressive familial intrahepatic cholestasis (PFIC), hypothyroidism, associated Down's syndrome; and rare causes such as polycystic disease, post-intestinal surgery, and immunodeficiency
B. *Obstructive 38% (n = 383)*	Biliary atresia and choledochal cyst
C. *Ductal paucity 3% (n = 29)*	Syndromic variety (Alagille syndrome and nonsyndromic variety)
D. *Unknown 6%*	
Other causes of NC not listed above may be due to other conditions such as bile acid synthetic disorders, Coombs-positive giant cell hepatitis, and neonatal sclerosing cholangitis. A number of new subtypes are being diagnosed now in India like bile acid transporter defects formerly called PFIC. With newer disorders the proportion of idiopathic group of NC is now shrinking.	