CTEV and Flat Foot

107

FLATFOOT

Introduction

- ☑ Flatfoot is also known as "pes planus" or "pes planovalgus".
- ☑ Flatfoot is defined as a foot where there is a decrease/collapse of the medial longitudinal arch with heel in valgus and forefoot in an abducted position. These three components are interconnected.

Physiological Flatfoot

- ☑ All children are born with flatfoot due to normal joint hypermobility and normal infant fat pad at the medial longitudinal arch. Between 3 and 5 years of age, most children develop the normal longitudinal arch. Sometimes, the arch takes even longer time to develop and develops in the first decade of life.
- ☑ "Tip-toe walking" helps to differentiate flexible flatfoot from the rigid flatfoot. In a flexible flatfoot, even though the medial longitudinal arch is collapsed during the stance phase; on tip-toeing, the arch is formed and the heel swings into varus. If not, it is a rigid flatfoot.

Etiology

TABLE 1: Etiology of flexible flatfoot and rigid flatfoot.

Flexible flatfoot	*Rigid flatfoot*
☑ Generalized ligamentous laxity (e.g., Down syndrome)	☑ Congenital vertical talus (Rocker bottom foot with equines heel)
☑ Contracture of gastrocsoleus (e.g., cerebral palsy)	☑ Tarsal coalition (peroneal spastic flatfoot)
☑ Isolated paralysis/laceration of tibialis posterior tendon (e.g., diabetes mellitus)	☑ Accessory navicular bone
	☑ Inflammatory arthritis of the subtalar joint

Flowchart 1: Classification and management of flatfoot.

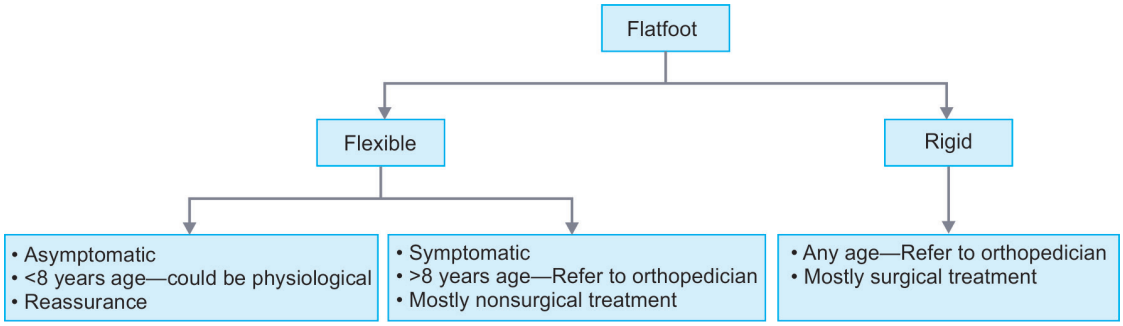

Common Complaints

- ☑ Cosmetic—abnormal appearance of the foot
- ☑ Foot and ankle pain, repeated ankle sprains
- ☑ Shoe wears out faster on the medial side of the sole

Seek orthopedic consultation for:

- ☑ Feet which are painful, stiff, weak, or numb
- ☑ Repeated feet or ankle injuries
- ☑ Problems with walking or balance
- ☑ A patient who did not have flatfeet before
- ☑ When only one foot is flat (unilateral)

Treatment

- ☑ Asymptomatic flexible flatfoot does not require treatment.
- ☑ Symptomatic flexible flatfeet is managed nonsurgically, with orthotics and exercises.
- ☑ Rigid flatfoot is always pathological and require surgical intervention (osteotomy and fusion).

Things to Remember

- ☑ Barefoot walking facilitates the development of the medial arch.
- ☑ The majority of the children with flatfoot are asymptomatic and function quite normally. They present to the clinic due to the misconception that all flatfeet are pathological and do not function normally in later life. Asymptomatic flexible flatfoot is considered a variant of a normal foot. Reassurance of parents is all that needs to be done.
- ☑ Shoe inserts can be compared with corrective spectacles. The arch collapses when it is removed. However, they prevent abnormal shoe wear out on the medial side of the sole.
- ☑ Rigid flatfoot is always pathological and needs further evaluation. The most common cause of rigid flatfoot is tarsal coalition.

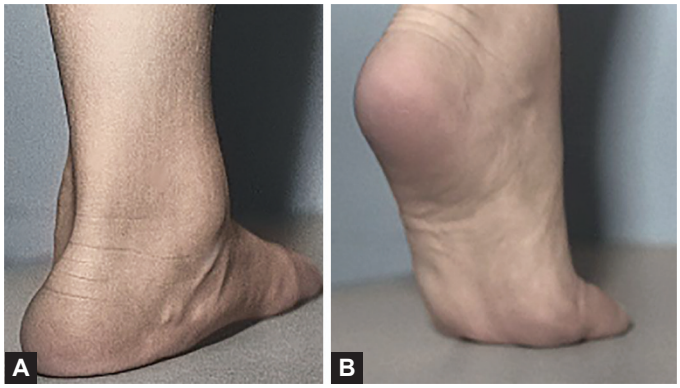

Figs. 1A and B: The arch disappears when standing (A) and reappears when the child is on tiptoes (B).

Source: Reproduced with permission from Sullivan JA. Pediatric Flatfoot: Evaluation and Management. J Am Acad Orthop Surg. 1999;7:44-53.

CONGENITAL TALIPES EQUINOVARUS

Introduction

- ☑ Incidence: 1–2/1,000 live births
- ☑ Males:females::2:1
- ☑ 50% bilateral
- ☑ Right > left
- ☑ 80% are idiopathic.

Classification

Flowchart 1: Classification of clubfoot.

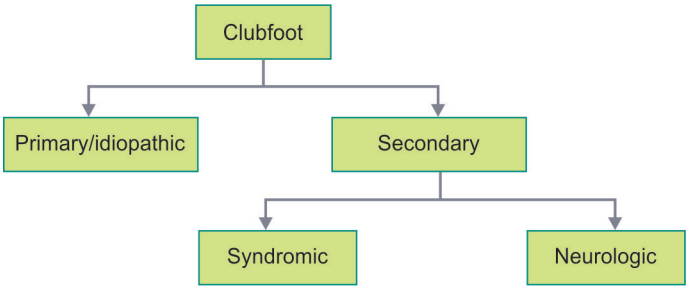

- ☑ Primary/idiopathic congenital talipes equinovarus (CTEV) is most common and is easily treated by Ponseti casting
- ☑ Secondary CTEV can be:
  - *Syndromic:* Associated with syndromes such as arthrogryposis multiplex congenita, Freeman–Sheldon syndrome, and Pierre Robin sequence
  - *Neurologic:* Associated with spina bifida occulta, meningomyelocele, and tethered cord syndrome.

Secondary CTEV are less common, more rigid to treat by Ponseti casting and need additional surgical procedures.

Differential Diagnosis

- ☑ *Postural/positional clubfoot:*
  - Less severe and flexible
  - No equinus deformity
  - Easily correctible
  - Can be treated by stretching or sometimes may require few casts
- ☑ *Metatarsus adductus:*
  - Forefoot adducted with curved lateral border
  - No heel equinus or varus
  - Treatment involves observation or sometimes may need few casts.

Prenatal Diagnosis

- ☑ Clubfoot deformity may be discovered during prenatal ultrasonography.
- ☑ Clubfoot can be detected at 13 weeks of gestation using transvaginal ultrasonography and at 16 weeks of gestation using transabdominal ultrasonography. No prenatal treatment is available for clubfoot; however, appropriate prenatal counseling is important.
- ☑ It is very helpful for the parents to have their pediatrician or obstetrician recommend a clinician who is experienced with the Ponseti technique.

- ☑ Do good general examination to determine overall health and development.
- ☑ Exclude syndromes and neurologic conditions (e.g., spina bifida, arthrogryposis, and limb development anomalies).
- ☑ Do focused examination of the foot and limb. Examination of all joints for range of motion and stability, including the hips is important, as is examination of lower extremities for equal length and symmetry. The severity of newborn foot deformity is determined more by the foot's flexibility than by its appearance. Newborn foot deformities that can be easily manipulated into an overcorrected position are considered positional rather than true clubfoot deformities. These resolve with minimal or no treatment. Unless a limb deficiency such as fibular hemimelia, tibial hemimelia, or congenital short femur is noted, radiography is not necessary. Several syndromes are known to be associated with clubfoot, including classic arthrogryposis, multiple pterygium syndrome, distal arthrogryposis, amniotic band syndrome, and Freeman–Sheldon syndrome. Geneticists can help to evaluate when there is suspicion of a syndrome. Neurologic causes include myelomeningocele, lipomeningocele, tethered cord syndrome, diastematomyelia, and sacral agenesis. A careful examination of the spine is needed to detect the sometimes subtle findings associated with tethered cord such as sacral dimple or hair patch.
- ☑ An infant with an isolated idiopathic clubfoot has a completely normal physical examination except for the involved foot and leg.
- ☑ The deformity has four key components that can be remembered by the acronym *CAVE* **(Fig. 1)**:
  - i. The midfoot has a high arch (*C*avus)
  - ii. The forefoot is turned in (*A*dductus)
  - iii. The heel is turned in (*V*arus)
  - iv. The hind foot is pointed down (*E*quinus).

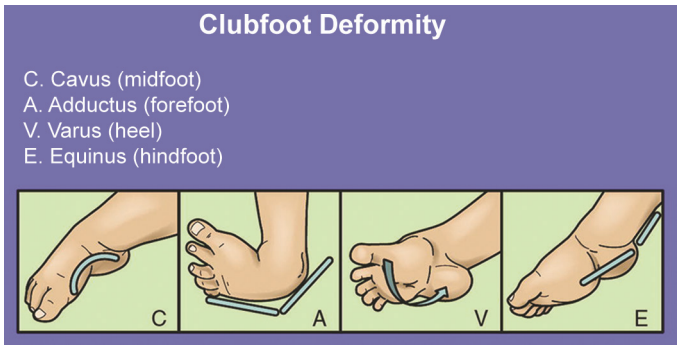

Fig. 1: Clubfoot deformity.
Source: Cady R, Hennessey TA. Diagnosis and Treatment of Idiopathic Congenital Clubfoot. Pediatrics. 2022;149(2):e2021055555.

- ☑ The deformity is quite stiff (not easily correctable with gentle manipulation), and the foot and calf may be slightly smaller than the opposite normal side. The untreated or relapsed clubfoot deformity results in the child walking on the lateral side or dorsum of the foot **(Fig. 2)**. Older children and adults with untreated clubfoot are unable to wear standard shoes and are limited in sports and employment.

Fig. 2: Child walking on the lateral side or dorsum of the foot.
Source: Cady R, Hennessey TA. Diagnosis and Treatment of Idiopathic Congenital Clubfoot. Pediatrics. 2022;149(2):e2021055555.

The Ponseti Treatment Method

The method consists of three phases of treatment:

1. Manipulation and casting
2. Tenotomy
3. Bracing

The first phase involves manipulation and weekly serial above-knee casting performed by an individual trained in the technique. This phase typically lasts for five to eight casts. Treatment can start anytime in the neonatal period, ideally the first 1–3 weeks.

In the second phase, after all of the elements of the deformity except equinus have been corrected, a percutaneous Achilles tenotomy is performed under local anesthesia by a surgeon in the clinic. A final cast is placed immediately after the tenotomy and worn for 3 weeks. About 90% of infants with clubfoot require a tenotomy.

The third and most important phase is the bracing phase, which starts immediately after removal of the post tenotomy cast. The brace is a foot abduction orthosis that consists of two shoes or splints connected by a bar, which holds the feet shoulder width apart. During the first 3 months, the brace is worn 23 hours per day, allowing the brace to come off for dressing and bathing only. After the first 3 months, the brace is worn at night time and nap time only, with a goal of 12–14 hours of brace wear, until the child is 4–5 years old.

Adherence by the parents with the bracing phase of treatment has been shown to be the most important factor in the prevention of recurrent deformity and the ultimate success of the Ponseti method. It is not easy to keep a child in a brace all night, every night, for 4 years; thus, the ability of the pediatrician and orthopedic surgeon to motivate and support the parents to complete the bracing program is as important as the initial correction of the deformity.

Recurrences occur in only 6% of families who are compliant in completing the bracing phase but in up to 80% of families who are unable to complete the bracing phase.

Adherence with bracing has many factors but is not believed to be related to family education, culture, or income level. Adherence can be improved with culturally sensitive education, a positive communication approach, and greater family awareness of the importance of bracing developed an intoeing or adducted gait, the recurrence is quite advanced. If left untreated, the dynamic, flexible deformity gradually becomes more fixed.

Flatfoot

- ☑ Dare D, Dowell E. Paediatric flatfoot: cause, epidemiology, assessment and treatment. Curr Opin Pediatr. 2014;26(1):93-100.
- ☑ Joseph B. Planovalgus deformity. In: Loder RT, Torode I, Joseph B, Nayagam S (Eds). Paediatric Orthopaedics: A System of Decision Making, 1st edition. United Kingdom: Hodder Arnold; 2009.
- ☑ Kim H, Weinstein S. Flatfoot in children: differential diagnosis and management. Curr Orthopaed. 2000;14(6):144-7.
- ☑ OrthoInfo. Flexible Flatfoot in Children. [online] Available from https://orthoinfo.aaos.org/en/diseases--conditions/flexible-flatfoot-in-children/. [Last accessed October, 2022].

Congenital Talipes Equinovarus

- ☑ Bakalis S, Sairam S, Homfray T, Harrington K, Nicolaides K, Thilaganathan B. Outcome of antenatally diagnosed talipes equinovarus in an unselected obstetric population. Ultrasound Obstet Gynecol. 2002;20:226-9.
- ☑ Bensahel H, Catterall A, Dimeglio A. Practical applications in idiopathic clubfoot: a retrospective multicentric study in EPOS. J Pediatr Orthop. 1990;10:186-8.
- ☑ Dobbs MB, Morcuende JA, Gurnett CA, Ponseti IV. Treatment of idiopathic clubfoot: an historical review. Iowa Orthop J. 2000;20:59-64.
- ☑ Grimes CE, Holmer H, Maraka J, Ayana B, Hansen L, Lavy CBD. Cost-effectiveness of clubfoot treatment in low-income and middle-income countries by the Ponseti method. BMJ Global Health. 2016;1:e000023.
- ☑ Ponseti IV. Treatment of congenital club foot. J Bone Joint Surg Am. 1992;74:448-54.

Indian Academy of Pediatrics (IAP)

STANDARD TREATMENT GUIDELINES 2022

Teen Depression and Suicide Prevention

Lead Author
Preeti Galagali

Co-Authors
KVS Saiprasad, Swati Ghate

Under the Auspices of the IAP Action Plan 2022

Remesh Kumar R
IAP President 2022

Upendra Kinjawadekar
IAP President-Elect 2022

Piyush Gupta
IAP President 2021

Vineet Saxena
IAP HSG 2022–2023

© Indian Academy of Pediatrics

IAP Standard Treatment Guidelines Committee

Chairperson

Remesh Kumar R

IAP Coordinator

Vineet Saxena

National Coordinators

SS Kamath, Vinod H Ratageri

Member Secretaries

Krishna Mohan R, Vishnu Mohan PT

Members

Santanu Deb, Surender Singh Bisht, Prashant Kariya, Narmada Ashok