Epidemiology

- ☑ 2–5% of full term and 25–30% of preterm male infants are born with undescended testes
- ☑ 1% at 1 year of age
- ☑ Bilateral in 10–30% of cases
- ☑ 80% of undescended testes are palpable
- ☑ *Associated conditions*: Prune belly syndrome, neural tube defects, etc.

Clinical Evaluation

Examination

- ☑ With warmed hands, supine, frog leg position with both legs free
- ☑ Scrotum observed for hypoplasia
- ☑ Inguinal region examined before scrotum to prevent activation of cremasteric reflex
- ☑ If testes is not found in normal path of descent, possible ectopic locations have to be examined
- ☑ Common ectopic locations: Inguinal region, perineum, femoral canal, penopubic area
- ☑ Contralateral testes can show compensatory hypertrophy.

Imaging

- ☑ There is no role for routine imaging in undescended testes
- ☑ Ultrasound lacks the efficacy to detect or definitively say there is no intra-abdominal testes
- ☑ Magnetic resonance imaging is rarely used in cases of disorder of sexual differentiation (DSD) to look for Müllerian structures along with the testes.

Management

Timing

Undescended testes rarely descends after 6–10 months, hence orchidopexy should be performed as early as possible after **10 months** of age to prevent progressive loss of germ cells. UDT can undergo torsion at any age and emergency surgery is warranted in case of acute pain with redness.

Orchidopexy

- ☑ Open orchidopexy is the standard of treatment for palpable UDT.
- ☑ Diagnostic laparoscopy is recommended for all nonpalpable UDT.
- ☑ For nonpalpable UDT, sometimes the testes can become palpable under general anesthesia and surgical approach can be changed to standard inguinal orchidopexy
- ☑ Diagnostic laparoscopy can reveal absent, dysplastic or atrophic testes, which is excised and sent for biopsy.
- ☑ If intra-abdominal testes are identified, either a single stage laparoscopic orchidopexy or staged Stephen Fowler (FS) procedure is done, based on the length of the vessels.
- ☑ First stage of FS orchidopexy involves clipping and division of spermatic vessels. Collaterals developed from cremasteric and vassal vessels. Testes mobilized and fixed in scrotum in second stage.
- ☑ Late presenters: Current recommendation is to try preserving the testes irrespective of the age of presentation. The main aim of surgery in these patients is to make it palpable for early detection of malignancy and preserve hormonal function.

Follow-up and Long-term Prognosis

- ☑ Boys with undescended testes may suffer from lower fertility rates
- ☑ Age at intervention and laterality is an important predictive factor
- ☑ 2–8 fold increase in risk of malignancy. Close follow-up warranted after puberty.

ACUTE SCROTUM IN CHILDREN–TESTICULAR TORSION

Introduction

- ☑ Acute scrotal pain can happen in boys of any age.
- ☑ Testicular torsion contributes to around 40% of acute scrotum in children.
- ☑ It is defined as the twisting of testes and spermatic cord resulting in vascular compromise and is one the most common pediatric surgical emergency.
- ☑ The twist happens within the tunica vaginalis—"intravaginal torsion".
- ☑ "Bell clapper deformity"—Abnormal fixation of testes and epididymis within the tunica makes it hang freely and susceptible to twisting **(Fig. 1)**.
- ☑ Incidence of bell clapper deformity in general population is ~10% and is usually bilateral.
- ☑ Bimodal age distribution is seen with most cases reported in early infancy and during puberty.
- ☑ Higher incidence is noted in winter probably due to increased cremasteric action in colder atmosphere.

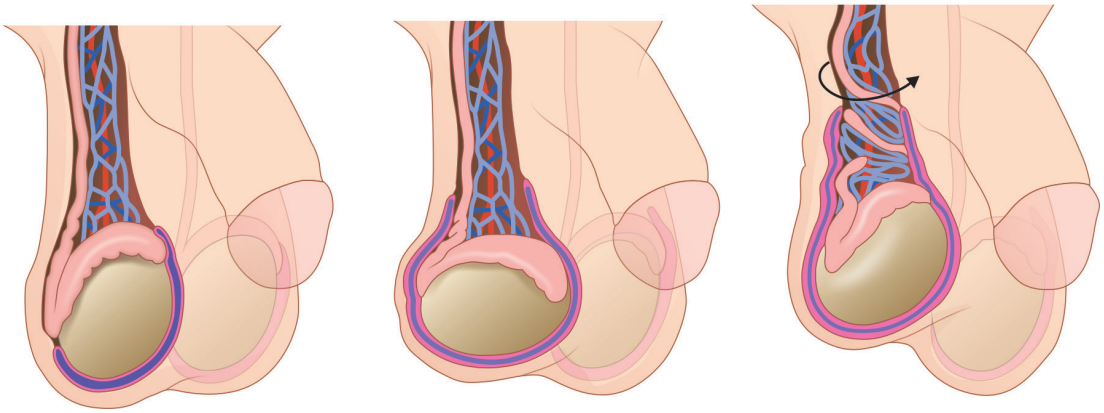

Fig. 1: Bell clapper deformity.
Source: Sharp VJ, Kieran K, Arlen AM. Testicular torsion: diagnosis, evaluation, and management. Am Fam Physician. 2013;88(12):835-40.

Clinical Evaluation

History

- ☑ Most common presentation is abrupt onset of testicular or scrotal pain.
- ☑ The pain is typically constant, severe, and may radiate to lower abdomen.
- ☑ However, some children can present with isolated inguinal or lower abdominal pain also.
- ☑ Nausea and vomiting is associated in up to 90% of these patients.
- ☑ History of trauma should be elicited.

Examination

- ☑ The scrotum can look indurated, edematous, and erythematous. Tenderness is present on palpation.
- ☑ Abdomen has to be examined in all cases, because some conditions like perforated appendicitis can also present with scrotal swelling and pain.
- ☑ Cremasteric reflex (elevation of the testes in response to stroking of the upper inner thigh), is absent in nearly all cases.
- ☑ The following clinical signs have been described to aid in the diagnosis. While helpful, it is usually difficult to elicit them in small children:
  - *Prehn's sign*: Elevation of scrotum reduces the pain in epididymitis while it persists in torsion.
  - *Angel's sign*: High riding testes due to shortening of spermatic cord.
  - *Demings's sign*: Horizontal or transverse lie of testes.
  - *Blue dot sign*: Bluish discoloration of scrotal skin near the upper pole of testis, seen in torsion of appendix of testes. It has been described in white-skinned children and is usually difficult to demonstrate in Indian children.
- ☑ Clinical scoring systems (e.g., testicular workup for ischemia and suspected torsion (TWIST) score) have also been described to determine the probability of testicular torsion.
- ☑ Epididymo-orchitis is one of the most common differentials which can be managed conservatively. It is usually seen in association with a urinary tract infection or underlying urogenital abnormality.

Clinical Evaluation

Imaging

- ☑ Imaging studies are not mandatory and can result in undue delay in scrotal exploration.
- ☑ Doppler sonography is used to check for torsion and assess viability.
- ☑ Demonstration of decreased testicular perfusion or twisting of the spermatic cord is consistent with testicular torsion.
- ☑ Use of doppler, when available on site, may reduce the incidence of negative scrotal exploration.
- ☑ Diagnostic accuracy of doppler ranges from 69 to 100%, hence a child should be assessed by a surgeon even if imaging is not suggestive of torsion.

Differential Diagnosis

Table 1 summarizes the differential diagnosis of acute scrotum with diagnostic features.

TABLE 1

Diagnosis	***Clinical clues***
Testicular torsion	Sudden and severe pain, nausea and vomiting, high riding testes, and absent doppler flow
Torsion of appendix of testes	No systemic symptoms and blue dot sign
Epididymo-orchitis	Thickened cord, normal doppler flow, reactive hydrocele, and recent viral illness
Acute hydrocele	Transilluminant and normal doppler
Trauma	History, hemorrhage, and ecchymosis
Idiopathic scrotal edema	No systemic symptoms, skin is edematous with soft underlying testis
Hematological disorders (HSP, etc.)	Systemic signs and altered blood parameters

(HSP: Henoch–Schönlein purpura)

Management

Timing

- ☑ Golden window is 4–8 hours from onset of symptoms. Salvage rates are very low after 12 hours.
- ☑ In developed countries, >70% present within 12 hours and salvage rates are around 50%. In India, salvage rates are poor due to late referrals and delayed exploration.

Manual Detorsion

- ☑ It is recommended when emergency operative facility is not immediately available.
- ☑ It is best performed under appropriate sedation and analgesia with the testes rotated anticlockwise till there is relief in pain.

Emergency Exploration

- ☑ Emergency scrotal exploration is offered for all patients presenting within 24 hours.
- ☑ If testis is viable after detorsion, a three point fixation or a subdartos sutureless fixation is done to prevent retorsion.
- ☑ In cases of doubtful viability, circulation can be assessed by change in color after applying warm packs. A fasciotomy by a longitudinal incision on convex border of testes from upper-to-lower pole can be done and checked for fresh bleeding.
- ☑ If testes are unviable, then orchidectomy is done. Contralateral testis is fixed routinely to prevent torsion **(Fig. 2)**.

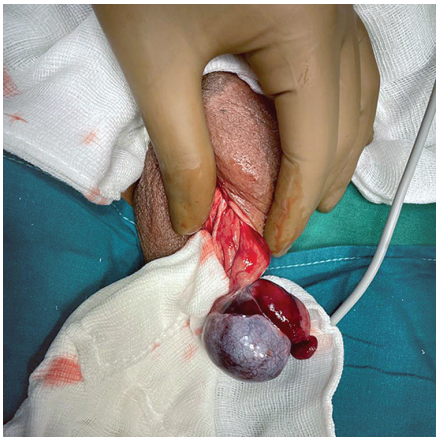

Fig. 2: Testicular torsion with necrosis.
Source: Self. Original.

Management

Follow-up and Long-term Prognosis

- ☑ Partial or total atrophy can occur in preserved testes on long-term follow up.
- ☑ Endocrine functions remain normal in the long-term.
- ☑ Subfertility has been reported in one-third of patients.

Special Conditions

Perinatal Torsion

- ☑ Perinatal torsion encompasses any event which occurred prenatally, during delivery or postpartum.
- ☑ It is "extravaginal" type of torsion, with the entire cord getting twisted.
- ☑ It is typically asymptomatic or an incidental finding characterized by hard painless testes fixed to the overlying dark scrotal skin.
- ☑ Testis is not salvageable.
- ☑ Orchidectomy of the affected side with early fixation of the contralateral testis is recommended.

Intermittent Torsion

- ☑ Intermittent testicular pain is common in adolescence.
- ☑ It can be due to intermittent torsion with spontaneous detorsion and may indicate an underlying bell clapper deformity.
- ☑ Parents can be counseled for bilateral testicular fixation, if the attacks are frequent.

Torsion of Appendix of Testes or Epididymis

- ☑ Appendix of testes and epididymis are vestigial structures on anterosuperior aspect of testis and head of epididymis.
- ☑ Torsion of these structures can result in acute scrotal pain similar to testicular torsion, however, the intensity is less **(Fig. 3)**.
- ☑ Preserved cremasteric reflex, blue dot sign and normal doppler flow of testis aid in the diagnosis.
- ☑ Conservative management can be attempted.

Fig. 3: Torsion of appendix of testes.
Source: Self. Original.

Testicular Reperfusion Injury

Detorsion and fixation can occasionally result in testicular edema under the tunica vaginalis causing chronic pain and testicular atrophy.

Further Reading

Undescended Testes

- ☑ Echeverría Sepúlveda MP, Yankovic Barceló F, López Egaña PJ. The undescended testis in children and adolescents part 2: evaluation and therapeutic approach. Pediatr Surg Int. 2022;38(6):789-99.
- ☑ Elder JS. Surgical Management of the Undescended Testis: Recent Advances and Controversies. Eur J Pediatr Surg. 2016;26(5):418-26.
- ☑ Sepúlveda X, Egaña PL. Current management of non-palpable testes: a literature review and clinical results. Transl Pediatr. 2016;5(4):233-9.
- ☑ Vikraman J, Hutson JM, Li R, Thorup J. The undescended testis: Clinical management and scientific advances. Semin Pediatr Surg. 2016;25(4):241-8.

Acute Scrotum in Children–Testicular Torsion

- ☑ DaJusta DG, Granberg CF, Villanueva C, Baker LA. Contemporary review of testicular torsion: new concepts, emerging technologies and potential therapeutics. J Pediatr Urol. 2013;9(6 Pt A):723-30.
- ☑ Gatti JM, Patrick Murphy J. Current management of the acute scrotum. Semin Pediatr Surg. 2007;16(1):58-63.
- ☑ Gordetsky J, Rabinowitz R, Hulbert WC Jr., Mevorach RA. Acute Scrotum. In: Palmer JS (Ed). Current clinical urology, 1st edition. NJ: Humana Press; 2011. pp. 217-30.
- ☑ McDowall J, Adam A, Gerber L, Enyuma COA, Aigbodion SJ, Buchanan S, et al. The ultrasonographic "whirlpool sign" in testicular torsion: valuable tool or waste of valuable time? A systematic review and meta-analysis. Emerg Radiol. 2018;25(3):281-92.
- ☑ Nguyen HT, Rossini G. "Hernia, Hydrocele, Testicular Torsion, and Varicocele". In: Docimo SG, Canning D, Khoury A, Salle JLP (Eds). The Kelalis–King–Belman Textbook of Clinical Pediatric Urology, 6th Edition. US: CRC Press; 2018. pp. 1313-34.

Indian Academy of Pediatrics (IAP)

STANDARD TREATMENT GUIDELINES 2022

Pertussis in Children

Lead Author
Jayant G Joshi

Co-Authors
Arun Manglik, Durgappa H

Under the Auspices of the IAP Action Plan 2022

Remesh Kumar R
IAP President 2022

Upendra Kinjawadekar
IAP President-Elect 2022

Piyush Gupta
IAP President 2021

Vineet Saxena
IAP HSG 2022–2023

© Indian Academy of Pediatrics

IAP Standard Treatment Guidelines Committee

Chairperson

Remesh Kumar R

IAP Coordinator

Vineet Saxena

National Coordinators

SS Kamath, Vinod H Ratageri

Member Secretaries

Krishna Mohan R, Vishnu Mohan PT

Members

Santanu Deb, Surender Singh Bisht, Prashant Kariya, Narmada Ashok