Pulled Elbow

114

Introduction

Pulled elbow is otherwise commonly known as a nursemaid's elbow. It commonly affects children under 5 years of age. It is a benign condition that usually passes uncomplicated.

Mechanism of Injury

- ☑ Pulled elbow is usually caused by a traction injury when force is applied longitudinally to a pronated extended elbow.
- ☑ It occurs typically when children are picked up abruptly from the floor or when they are suddenly pulled back by their hand as they are falling down.

Clinical Presentation

- ☑ The typical presentation is a child who has suddenly cried out with pain and refused to use their arm after a pulling incident.
- ☑ The arm is held flexed at the elbow and the child complains of pain either in the elbow or the wrist. The child will allow passive flexion and extension of the elbow but will resist rotations. This is a form of pseudoparalysis. Externally there will be no signs of inflammation around the elbow.

Pathology

- ☑ One important difference is that the annular ligament attachments are thicker, and therefore, stronger in adults than in children. The radial head is ovoid and about 30% larger in diameter than the radial shaft.
- ☑ The exact pathology of a pulled elbow is still not clear. The theories range from radial head subluxation to annular ligament displacement and an annular ligament tear.
- ☑ The most probable pathology is that the radial head sublimates under axial traction with the forearm pronated, and becomes trapped distal to the annular ligament, which is interposed **(Fig. 1)**.

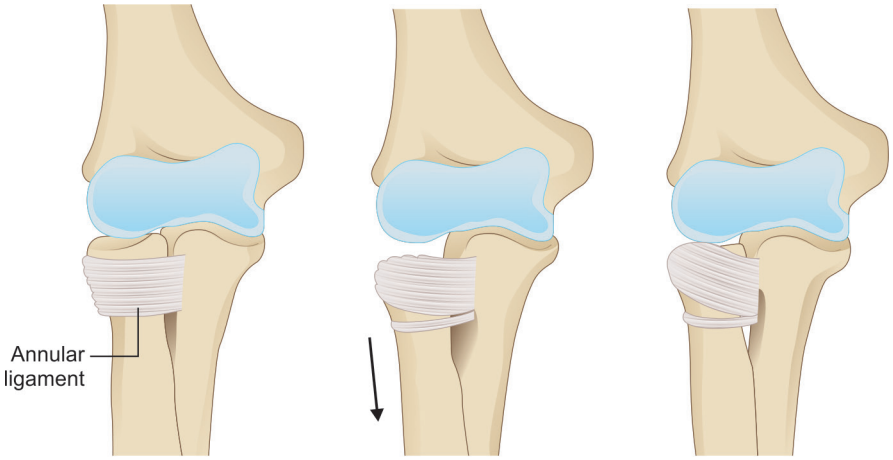

Fig. 1: Nursemaid's elbow—tricks.

Investigations

- ☑ Radiographs are typically normal and hence are never done unless the diagnosis is in doubt.
- ☑ Ultrasonography has been done to show a widened radiocapitellar interval and a torn annular ligament. Ultrasound too is not done routinely when the diagnosis is clear.

The purpose of all manipulative interventions is to reposition both the radial head and the annular ligament, thereby restoring the function of the arm and relieving the pain. Two maneuvers are commonly done. One is supination of the forearm along with flexion of the elbow. The other method is pronation of the forearm.

Rotation of the radial head is sufficient to reposition the annular ligament to the radial head.

Once reduced there will be a dramatic relief of pain and restoration of function of the elbow. This is due to the release of the annular ligament from its pinched position and a return to its normal position.

Usually the flexion supination maneuver causes a little more pain during reduction as opposed to the pronation method **(Figs. 2 and 3)**.

Post reduction there is no need of immobilization as the child will actively use the upper limb.

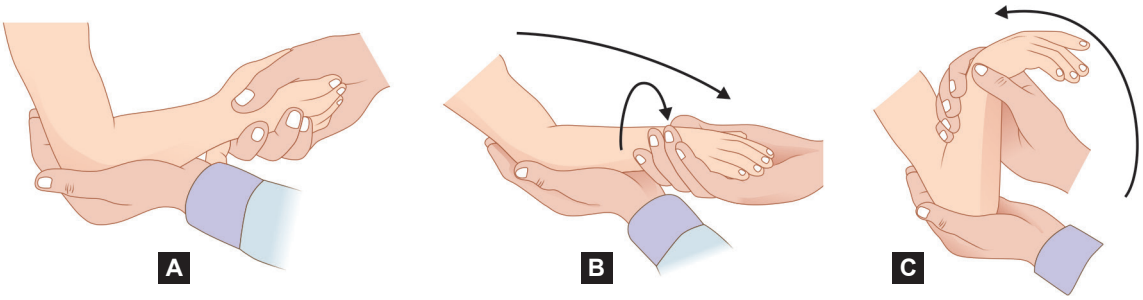

Figs. 2A to C: The pronation maneuver. (A) Position of the elbow before reduction; (B) Simultaneous pronation of the forearm and extension of the elbow; (C): Flexion of the elbow with the forearm pronated.

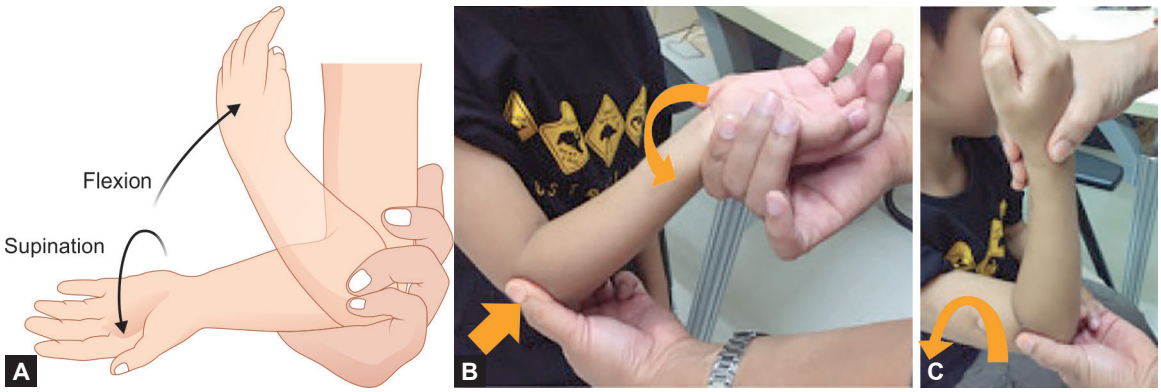

Figs. 3A to C: The flexion supination maneuver. (A) The forearm is supinated; (B) Elbow is hyperflexed with pressure on the radial head; (C) The radial head will reduce with a click usually.

Recurrence

Studies have shown recurrence rates between 26.7 and 39%. We usually tell parents that once this has occurred then it can recur up to the age of 5 years. If it recurs then they should take the child to the emergency room where it will be reduced.

Prevention

Parents are counseled not to grab the child by the arm or hand. They are taught to pick up the child by lifting under the axilla instead.

Further Reading

- ☑ Diab HS, Hamed MM, Allam Y. Obscure pathology of pulled elbow: dynamic high-resolution ultrasound-assisted classification. J Child Orthop. 2010;4(6):539-43.
- ☑ Krul M, van der Wouden JC, Kruithof EJ, van Suijlekom-Smit LW, Koes BW. Manipulative interventions for reducing pulled elbow in young children. Cochrane Database Syst Rev. 2017;7(7):CD007759.
- ☑ Macias CG, Bothner J, Wiebe R. A comparison of supination/flexion to hyperpronation in the reduction of radial head subluxations. Pediatrics. 1998;102(1):e10.
- ☑ McDonald J, Whitelaw C, Goldsmith LJ. Radial head subluxation: comparing two methods of reduction. Acad Emerg Med. 1999;6(7):715-8.

Indian Academy of Pediatrics (IAP)

STANDARD TREATMENT GUIDELINES 2022

Dental Caries

Lead Author
Rajesh Chokhani

Co-Authors
Ajay Gupta, Chandra Mohan

Under the Auspices of the IAP Action Plan 2022

Remesh Kumar R
IAP President 2022

Upendra Kinjawadekar
IAP President-Elect 2022

Piyush Gupta
IAP President 2021

Vineet Saxena
IAP HSG 2022–2023

© Indian Academy of Pediatrics

IAP Standard Treatment Guidelines Committee

Chairperson

Remesh Kumar R

IAP Coordinator

Vineet Saxena

National Coordinators

SS Kamath, Vinod H Ratageri

Member Secretaries

Krishna Mohan R, Vishnu Mohan PT

Members

Santanu Deb, Surender Singh Bisht, Prashant Kariya, Narmada Ashok, Pawan Kalyan