Tropical Pulmonary Eosinophilia

125

Introduction

Tropical pulmonary eosinophilia (TPE) is a hyper-responsive pulmonary syndrome in response to trapped microfilariae within the lung tissue. TPE is a clinical manifestation of lymphatic filariasis caused by filarial nematodes, common in the filarial endemic region.

The onset of TPE is slow, and the major symptoms are fever, nocturnal cough, dyspnea, and wheezing.

Pulmonary eosinophilic syndromes can be classified as extrinsic or intrinsic on the basis of causative factors **(Table 1)**.

TABLE 1: Pulmonary eosinophilic syndromes classification.

Extrinsic causes	☑ Medications (sulfonamides, phenytoin, phenobarbital, and carbamazepine)
Intrinsic causes	☑ Churg–Strauss syndrome ☑ Eosinophilic granuloma ☑ Chronic eosinophilic pneumonia ☑ Idiopathic hypereosinophilic syndrome

Tropical pulmonary eosinophilia comes under extrinsic causes.

Etiology

- ☑ TPE is a *type 1 hypersensitivity* reaction to the microfilariae trapped within the lung parenchyma, lymphatic system, and bloodstream of humans which spreads from person to person by mosquito bites, which serve as a vector.
- ☑ The species causing filariasis in humans are *Wuchereria bancrofti, Brugia malayi*, and *Brugia timori*.
- ☑ The vectors of *W. bancrofti* are *Culex*, *Anopheles*, and *Aedes* mosquitoes.

Epidemiology

- ☑ Tropical pulmonary eosinophilia occurs in any tropical area but most commonly found in filarial endemic regions such as the Indian subcontinent, South East Asia, South America, and Africa.
- ☑ Tropical pulmonary eosinophilia is more likely to occur in nonimmune individuals (persons who travelled to the endemic regions) than in the individuals permanently residing in endemic regions due to immunity developed against the filarial infections.

Pathophysiology

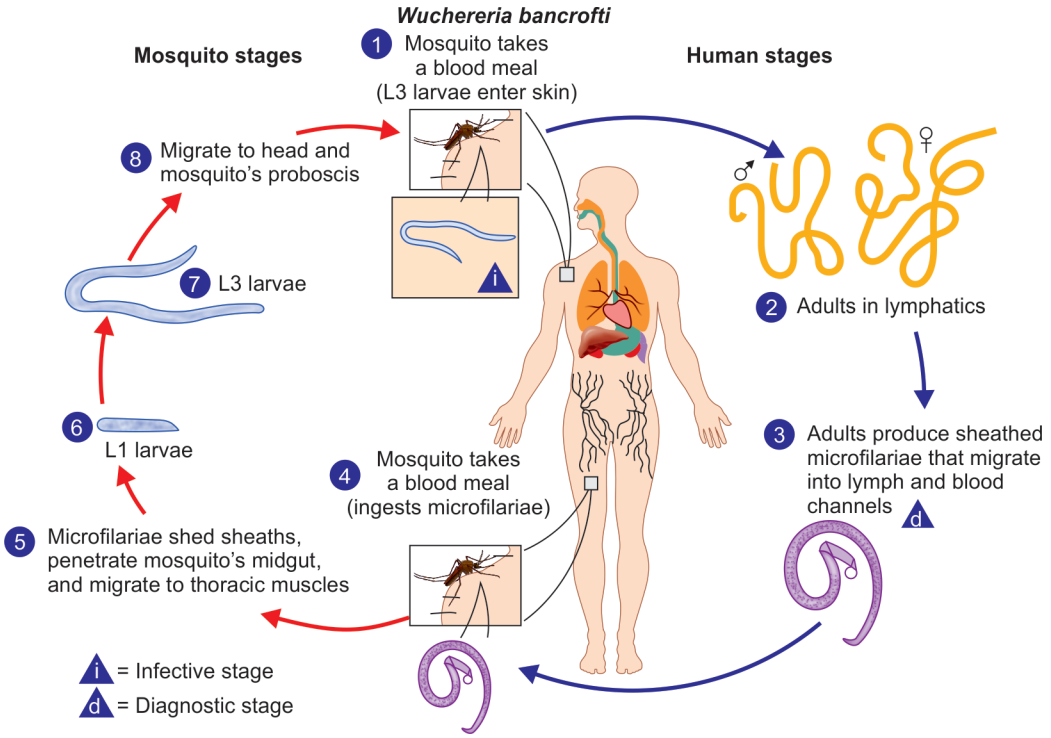

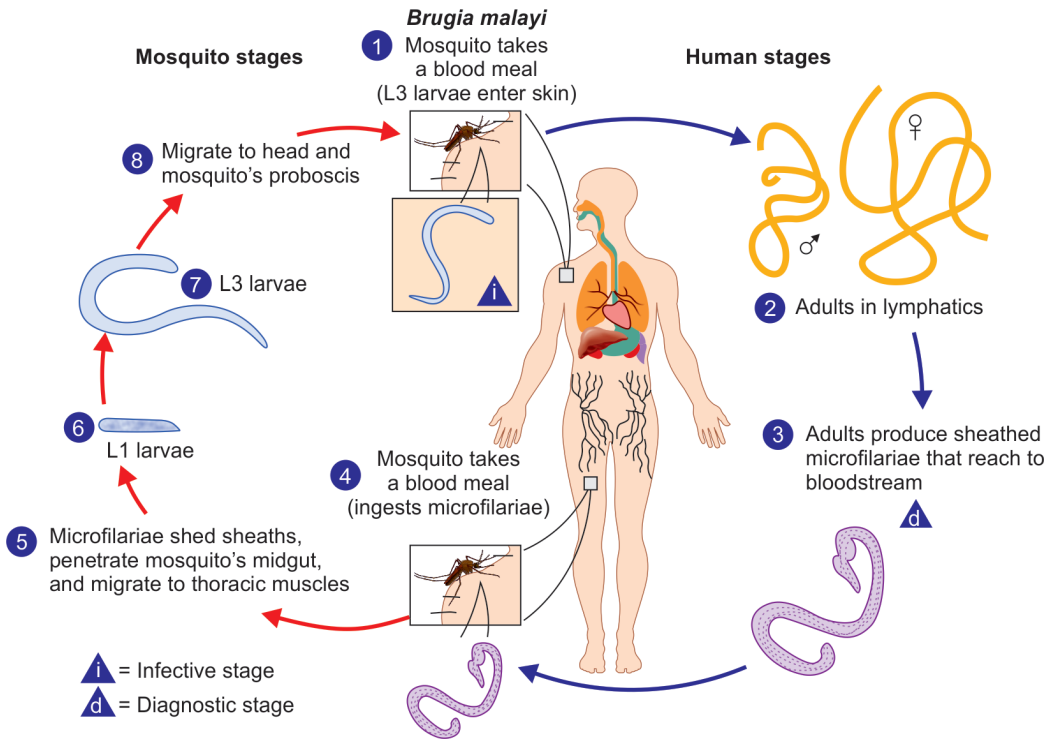

Eosinophils play a central role in the pathogenesis of TPE.

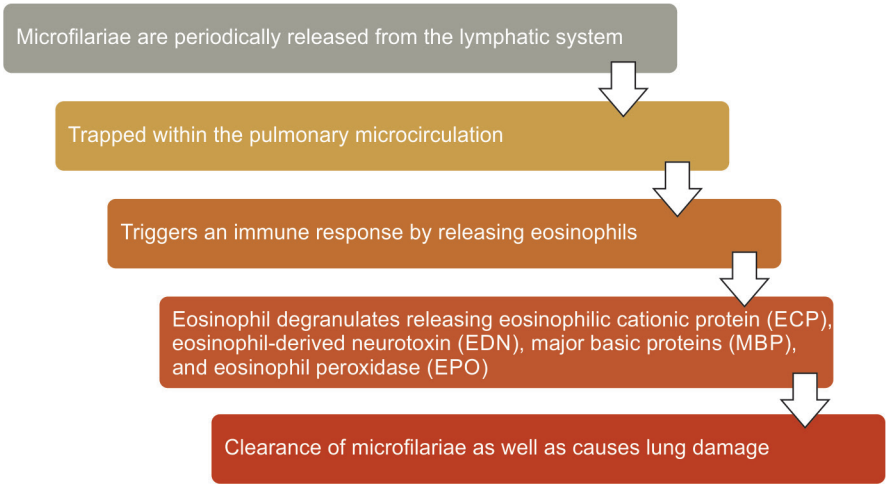

Pathophysiology

Complement activation and opsonization by antifilarial antibodies also help in microfilariae clearance.

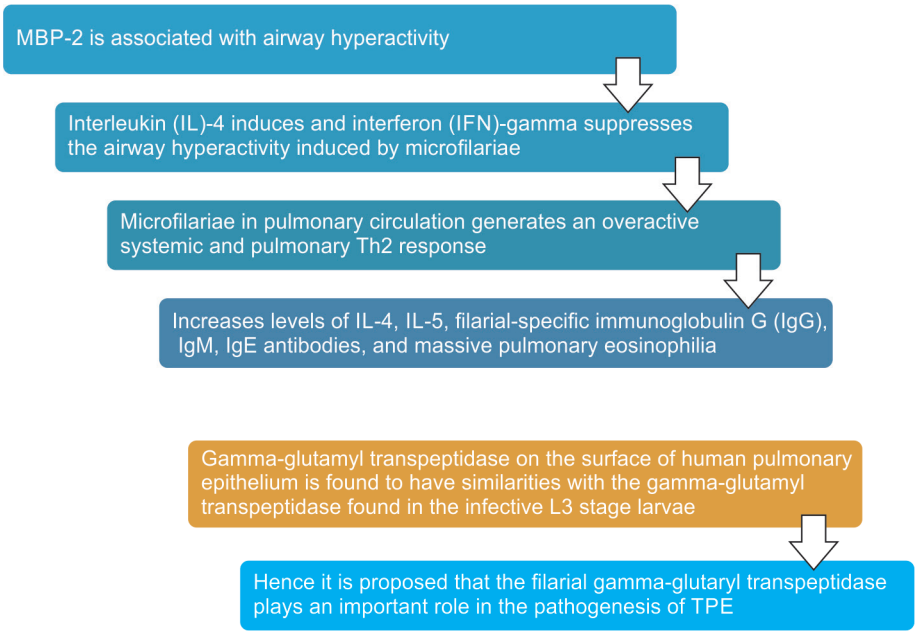

Histopathology

- ☑ Histiocyte infiltration in the lung parenchyma is the earliest finding resulting in symptoms such as cough, dyspnea, and wheezing.
- ☑ Eosinophilic interstitial infiltration occurs shortly after histiocyte infiltration, which may further progress to eosinophilic abscesses, eosinophilic granulomas, or eosinophilic bronchopneumonia.
- ☑ At 6 months to 2 years from onset, mixed cell reaction is seen (histiocytes, eosinophils, epithelioid cells, and lymphocytes).
- ☑ If still untreated, the patient may show pulmonary fibrosis.

Clinical Features

Symptoms of TPE include:

- ☑ Dry cough, which is paroxysmal and nocturnal
- ☑ Cough associated with dyspnea
- ☑ Systemic manifestations such as fever, malaise, anorexia, and weight loss
- ☑ Peripheral blood eosinophilia >3,000/mm^3
- ☑ Extrapulmonary manifestations such as lymphadenopathy and hepatosplenomegaly may be seen in a few cases

Physical Findings

- ☑ Chest auscultation may reveal wheezing and crepitations
- ☑ Organomegaly on abdominal palpation in a few cases
- ☑ Enlarged lymph nodes

Evaluation

- ☑ *Complete blood count:* Leukocytosis with eosinophilia >3,000/mm^3 is the cardinal finding in a patient with TPE.
- ☑ *Stool examination:* To rule out other parasites causing the pulmonary eosinophilia syndrome.
- ☑ *Quantitative serum immunoglobulin test:* Elevated immunoglobulin E level is frequently seen in a patient with TPE.
- ☑ *Indirect enzyme-linked immunosorbent assay (ELISA) test:* Diagnosis is confirmed by a rise in filarial antibody titers.
- ☑ *Chest X-ray:* May show reticulonodular opacities or miliary mottling in the middle or lower lung zones. About 20–30% of patients with TPE may have normal lungs. Fibrosis may be seen in advanced disease.
- ☑ *Chest CT scan:* May show bronchiectasis, lymphadenopathy, and pleural effusion. It is done in cases where the diagnosis is not established.
- ☑ *Pulmonary function tests (PFTs):* Typically shows a mixed pattern with a predominant restrictive and mild-to-moderate obstructive pattern.

Diagnostic Criteria for Tropical Pulmonary Eosinophilia

- ☑ History of residence or travel to a filarial endemic region
- ☑ Paroxysmal and nocturnal cough with dyspnea
- ☑ Leukocytosis with peripheral blood eosinophilia >3,000/mm^3
- ☑ Elevated serum IgE and filarial antibody titers
- ☑ Pulmonary infiltrations in chest X-ray
- ☑ Clinical improvement with diethylcarbamazine (DEC)

Management

- ☑ The confirmed case of TPE is treated with DEC 6 mg/kg for 21 days.
- ☑ Concomitant therapy with corticosteroids reduces inflammation of airways in a chronic setting.
- ☑ Other agents used for treatment include ivermectin (acts on microfilariae) and albendazole (acts on adult worms).

Complications

Tropical pulmonary eosinophilia, if treated late or left untreated, can lead to:

- ☑ Pulmonary fibrosis
- ☑ Chronic bronchitis with chronic respiratory failure
- ☑ Pulmonary hypertension leading to cor pulmonale may be seen in a few patients due to embolization of destructed microfilariae into lung capillaries

Differential Diagnosis

- ☑ Pulmonary eosinophilia due to other infectious cause—*Strongyloides*, *Toxocara*, and *Ascariasis*
- ☑ Bronchial asthma
- ☑ Allergic bronchopulmonary aspergillosis
- ☑ Allergic rhinitis
- ☑ Acute and chronic eosinophilic pneumonia
- ☑ Fungal pneumonia
- ☑ Churg–Strauss syndrome
- ☑ Drug reaction with eosinophilia and systemic symptoms (DRESS) syndrome
- ☑ Miliary tuberculosis

Further Reading

- ☑ Madan M, Gupta P, Mittal R, Chhabra SK. Tropical pulmonary eosinophilia: effect of addition of corticosteroids after failure of diethylcarbamazine therapy. Adv Respir Med. 2017;85(1):51-4.
- ☑ Mullerpattan JB, Udwadia ZF, Udwadia FE. Tropical pulmonary eosinophilia—a review. Indian J Med Res. 2013;138(3):295-302.
- ☑ O'Connell EM, Nutman TB. Eosinophilia in infectious diseases. Immunol Allergy Clin North Am. 2015; 35(3):493-522.
- ☑ Tsanglao WR, Nandan D, Chandelia S, Arya NK, Sharma A. Filarial tropical pulmonary eosinophilia: a condition masquerading asthma, a series of 12 cases. J Asthma. 2019;56(7):791-8.

Indian Academy of Pediatrics (IAP)

STANDARD TREATMENT GUIDELINES 2022

Coping with Stress in Adolescents

Lead Author

Swati Y Bhave

Co-Authors

Jayshree, Sandeep Kavade

Under the Auspices of the IAP Action Plan 2022

Remesh Kumar R
IAP President 2022

Upendra Kinjawadekar
IAP President-Elect 2022

Piyush Gupta
IAP President 2021

Vineet Saxena
IAP HSG 2022–2023

© Indian Academy of Pediatrics

IAP Standard Treatment Guidelines Committee

Chairperson

Remesh Kumar R

IAP Coordinator

Vineet Saxena

National Coordinators

SS Kamath, Vinod H Ratageri

Member Secretaries

Krishna Mohan R, Vishnu Mohan PT

Members

Santanu Deb, Surender Singh Bisht, Prashant Kariya, Narmada Ashok, Pawan Kalyan