# Hyperpigmented Lesions in Children

122

## Introduction

Hyperpigmentation is defined as perceptible darkness in skin color, which is usually due to increased melanin content in skin. There are multiple causes of increase in pigmentation, and therefore a thorough history and examination, and where needed, investigations may be helpful in coming to a conclusive diagnosis. With limited scope of this document, a basic algorithm to categorize the causes and few pertinent points of some common disorders are presented in **Flowchart 1**.

**Flowchart 1:** Causes of hyperpigmented lesions.

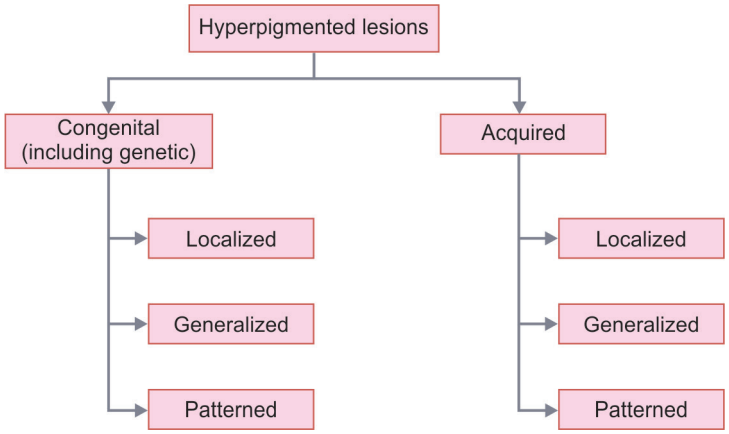


Broadly, the disorders of hyperpigmentation can be divided into two broad categories:

1. Congenital (including Genetic)
2. Acquired

Further on, to narrow down the differential diagnosis, these disorders can be divided on the basis of whether they affect a limited or a large surface area of the body as:

- ☑ Localized
- ☑ Generalized
- ☑ Patterned

The algorithm **(Flowchart 1)** forms the basis of narrowing down the differential. Elaborating on the entire differential is out of scope of this document; therefore, only the common diagnoses are discussed briefly here.

## Congenital Localized Disorders of Hyperpigmentation

- ☑ *Café-au-lait macules (CALMs):* Can be single or multiple. May be associated with various syndromes including neurofibromatosis (some types), tuberous sclerosis, and McCune Albright syndrome. Few café-au-lait spots may be seen in normal individuals but more than five in number or associated abnormalities may point toward an underlying disorder.
- ☑ *Lentigines:* Macular, tan colored with striking irregular borders. Pigmentation is more uniform and does not tend to show seasonal variation. Can be localized, generalized, or segmental. Can be associated with syndromes like LEOPARD syndrome.
- ☑ *Peutz–Jeghers syndrome:* Intra- and perioral lentigines. Associated with gastrointestinal polyps that may lead to intussusception and bleeding.
- ☑ *Mongolian spots:* Presence of dermal melanocytes, therefore appearing as bluish gray spots usually on lumbar area and buttocks but can be more extensive. May fade away by late childhood.

## Congenital Generalized Disorders of Pigmentation

- ☑ *Familial progressive hyperpigmentation:* Autosomal dominant; pigmentation starts early and gradually becomes generalized.
- ☑ *Adrenoleukodystrophy:* Pigmentation mimics idiopathic Addison's disease.

## Congenital Patterned Disorders of Hyperpigmentation

- ☑ *Incontinentia pigmenti (blaschkoid pattern):* X-linked dominant condition usually affecting males. Presents initially with vesicular lesions, which then turn warty and flattening out to leave hyperpigmentation. This eventually fades leaving hypopigmented atrophic steaks. Systemic involvement may occur.
- ☑ *Linear whorled and nevoid hypermelanosis (blaschkoid pattern):* Presenting as streaks of hyperpigmentation which appear within the first few weeks of life, progressing over first couple of years before stabilizing. Usually they persist, though some fading may be seen in few patients. Extracutaneous features may be present.
- ☑ *Dyskeratosis congenita:* Reticulate pigmentation on neck and upper body. May later on lead to bone marrow failure.

## Acquired Localized Disorders of Pigmentation

- ☑ *Postinflammatory hyperpigmentation:* This follows inflammation, such as following lichen planus, insect bites, drug reactions, and trauma. Usually tends to settle spontaneously over time, though time period may be variable depending on the cause.
- ☑ *Chikungunya:* Usually pigmentation affects centrofacial area. Self resolves in few months.
- ☑ *Fixed drug eruption:* Appears as sudden appearance of itchy dark reddish purple patch(es) following a drug exposure. The reaction usually occurs on the same site upon re-exposure to the incriminating drug. Resolution of pigmentation may take a few months to few years.
- ☑ *Freckles:* Light brown macules seen in sun-exposed areas. Pigmentation waxes and wanes across the year, becoming more prominent in summers. Progressive, widespread freckling may be feature of xeroderma pigmentosum.
- ☑ *Becker's nevus:* Pigmented nevus with overlying coarse hairs; usually becomes prominent around puberty. It mostly affects males, presenting commonly on shoulder and chest area unilaterally.
- ☑ *Acanthosis nigricans:* Bilaterally symmetrical velvety dark skin usually affecting neck, axillae, and groin. Marker of insulin resistance.

## Acquired Generalized Disorders of Hyperpigmentation

- ☑ *Addison's disease:* Congenital, familial, and acquired forms.
- ☑ Vitamin $B_{12}$ deficiency.
- ☑ *Chikungunya:* Usually fades over few months.
- ☑ *Drugs:* Many drugs can be causative including hydroxychloroquine, clofazimine, and minocycline. Color usually normalizes over months to years after drug withdrawal.
- ☑ *Lichen planus pigmentosus:* Inflammatory disorder causing dark pigmentation, which may settle over few years.
- ☑ *Idiopathic eruptive macular pigmentation:* Pigmentation affects face, trunk and proximal extremities, and fades over few months to few years.
- ☑ *Progressive systemic sclerosis:* Gradual diffuse pigmentation mixed with areas of depigmentation giving salt and pepper appearance.
- ☑ *Bronze baby syndrome:* Pigmentation following phototherapy, which slowly settles spontaneously.

Treatment

| | |
|---|---|
| ***Congenital Localised Disorders of Hyperpigmentation*** | |
| Café-au-lait macules (CALMs) | ☑ Mostly benign, treated with laser therapy for cosmetic purposes<br>☑ (Q switched Nd: YAG, Q switched alexandrite laser, Q-switched ruby laser, copper vapor laser, pigmented lesion dye laser) |
| Lentigines | ☑ Usually benign, treatment not necessary<br>☑ Topical – sunscreen, hydroquinone preparations, retinoids, vitamin C, azelaic acid, chemical peels<br>☑ Physical – cryotherapy, pigment lasers, Intense pulsed light |
| Peutz–Jeghers syndrome | ☑ Lasers, electrodesiccation, cryosurgery, dermabrasion, surgical excision |
| Mongolian spots | ☑ Usually resolve by early childhood, no treatment is generally needed.<br>☑ For cosmesis – Q switched ruby, Nd:YAG and alexandrite lasers<br>☑ cosmetic camouflage |
| Familial progressive hyperpigmentation | ☑ Treatment solely based on cosmetic purposes. Depigmentation procedure can be carried out |
| Adrenoleukodystrophy | ☑ Diet restricted to saturated fatty acids combined with the use of Lorenzo's oil<br>☑ Treatment of adrenal insufficiency and neurological symptoms |
| ***Congential Patterned Disorders of Hyperpigmentation*** | |
| Incontinentia pigmenti (blaschkoid pattern) | ☑ Hyperpigmentation eventually fades leaving hypopigmented atrophic steaks. |
| Linear whorled and nevoid hypermelanosis (blaschkoid pattern) | ☑ Pigmentation gradually fades with age.<br>☑ Treatment is unsatisfactory, and treatment strategies have not been clearly defined. |
| Dyskeratosis congenita | ☑ *Retinoids:* Cause regression of leukoplakia<br>☑ Topical steroids for oral lesions<br>☑ Definitive cure for bone marrow failure : allogenic hematopoietic stem cell transplantation |
| ***Acquired Generalized Disorders of Hyperpigmentation*** | |
| Post inflammatory hyperpigmentation | ☑ Topical agent that inhibits tyrosinase (e.g hydroquinone, arbutin, kojic acid, azelaic acid, aloesin)<br>☑ Topical agent that enhances epidermal turnover (retinoic acid, glycolic acid) |
| Chikungunya | ☑ No specific treatment. Self resolves in few months.<br>☑ Can be treated with – sunscreens & topical steroids |
| Fixed drug eruption | ☑ Localised lesions - Topical steroids & oral antihistamines<br>☑ Generalized lesions – systemic steroids |
| Freckles | ☑ Sunprotection, topical depigmenting agents<br>☑ *Lasers:* Fractional CO2 laser |
| Becker's nevus | ☑ *Q-switched lasers or erbium:* YAG lasers |

## Treatment

| *Acquired Generalized Disorders of Hyperpigmentation* | |
|---|---|
| Acanthosis nigricans | ☑ Weight reduction, diet modification, topical retinoids, topical vit D analogs, chemical peels, oral retinoids, oral anti diabetic drugs<br>☑ Alexandrite laser |
| Addison's disease | ☑ Mineralocorticoids & glucocorticoids replacements |
| Vitamine B12 deficiency | ☑ Vit B12 replacement<br>☑ IM inj Vit B12 (1000MG) daily for 10days, then weekly for 1 month, then monthly for 2 months<br>☑ Hyperpigmentation resolves in 3 months after initiation of treatment |
| Drugs | ☑ Reduce or stop the offending drug & limit sun exposure<br>☑ Q-switched laser treatment |
| Lichen planus pigmentosus | ☑ Topical steroids, calcineurin inhibitors, topical retinoids, azelaic acid, chemical peels or lasers<br>☑ Low dose isotretinoin (0.3 mg/kg) + sunscreens |
| Idiopathic eruptive macular pigmentation | ☑ Self limiting, disappear in months to years |
| Progressive systemic sclerosis | ☑ Raynaud's phenomenon – calcium channel blockers, Angiotensin receptor blockers, PDE-5 inhibitors, protanoids<br>☑ Immunosuppressants, antihistamines<br>☑ IPL and pulse dye laser for telengiectasias |
| Bronze baby syndrome | ☑ No treatment is required as it slowly disappear after stopping phototherapy |
| Melanocytic nevi | ☑ Surgical excision<br>☑ *Lasers:* Q-switched Nd:YAG, CO2, erbium:YAG |
| Urticaria pigmentosa (mastocytosis) | ☑ Topical calcineurin inhibitors and topical corticosteroids<br>☑ Phototherapy, antihistamines, pulsed dye light<br>☑ Surgical excision, cytoreductive therapy |

## Miscellaneous

- ☑ Melanocytic nevi.
- ☑ *Urticaria pigmentosa (mastocytosis):* Lesions can present at birth or later; can be few to many in number. Stroking the lesion may lead to localized wheal formation termed as Darier's sign. Usually settles over many years.

## Further Reading


- ☑ Cohen BA. Pediatric Dermatology, 4th edition. Amsterdam, Netherlands: Saunders, Elsevier; 2013.
- ☑ Kinsler V, Yan AC, Hoeger PH, Harper J, Oranje AP, Bodemer C, et al. Harper's Textbook of Pediatric Dermatology, 4th edition. United Kingdom: Wiley; 2019.
- ☑ Palit A, Ragunatha S, Inamadar AC. Textbook of Pediatric Dermatology, 2nd edition. New Delhi: Jaypee Brothers Medical Publishers (P) Lid.; 2014.

Indian Academy of Pediatrics (IAP)

# STANDARD TREATMENT GUIDELINES 2022

# Early Detection and Early Intervention of a High-risk Neonate

*Lead Author*
**Zafar Mahmood Meenai**

*Co-Authors*
**MKC Nair, Anjan Bhattacharya**

**Under the Auspices of the IAP Action Plan 2022**

**Remesh Kumar R**
IAP President 2022

**Upendra Kinjawadekar**
IAP President-Elect 2022

**Piyush Gupta**
IAP President 2021

**Vineet Saxena**
IAP HSG 2022–2023

© Indian Academy of Pediatrics

## IAP Standard Treatment Guidelines Committee

***Chairperson***

**Remesh Kumar R**

***IAP Coordinator***

**Vineet Saxena**

***National Coordinators***

**SS Kamath, Vinod H Ratageri**

***Member Secretaries***

**Krishna Mohan R, Vishnu Mohan PT**

***Members***

**Santanu Deb, Surender Singh Bisht, Prashant Kariya, Narmada Ashok, Pawan Kalyan**