Phimosis

133

Introduction

- ☑ At birth the foreskin is adherent to the glans penis. These adhesions separate spontaneously with time, allowing the foreskin to become retractile.
- ☑ At 1 year of age about 50% of boys have a nonretractile foreskin.
- ☑ By 4 years of age this declined to 10% and by 16 years to just 1%
- ☑ Ballooning of the normal nonretractile foreskin may occur with micturition.
- ☑ Gentle retraction of the foreskin at bath time helps to maintain hygiene but forcible retraction should never be attempted.
- ☑ The presence of preputial adhesions when the foreskin remains partially adherent to the glans is normal and resolves spontaneously.
- ☑ Physiological adhesions between the foreskin and the glans penis may persist until 6 years of age or more, giving impression that the prepuce will not retract.
- ☑ Rolling back the prepuce causes its inner lining to pout and the meatus comes into the view
- ☑ Phimosis is overdiagnosed
- ☑ This condition should not be confused with true phimosis in boys with scarring of the prepuce, which will not retract without fissuring.
- ☑ In these cases, the aperture in the prepuce may be so tight as to cause urinary obstruction.
- ☑ Urinary difficulty with residual urine and back pressure changes on the ureters and kidneys is far more commonly caused by meatal stenosis, which may be masked by prepuce.
- ☑ Phimosis occurs as a result of balanitis xerotica obliterans (BXO), a curious condition in which the normally pliant foreskin becomes thickened and will not retract.
- ☑ It is difficult to keep the penis clean and there is both a problem with hygiene and in later life an increased susceptibility to carcinoma.
- ☑ Treatment is *circumcision*.

Management

- ☑ Circumcision is one of the earliest recorded operations and remains an important tradition in some cultures.
- ☑ Routine neonatal circumcision is performed in some western societies but the practice has been increasingly criticized.
- ☑ Proponents point out that circumcision reduces the incidence of urinary tract infection in infant boy; however circumcision is not without risk of significant morbidity.

Flowchart 1: Phimosis algorithm.

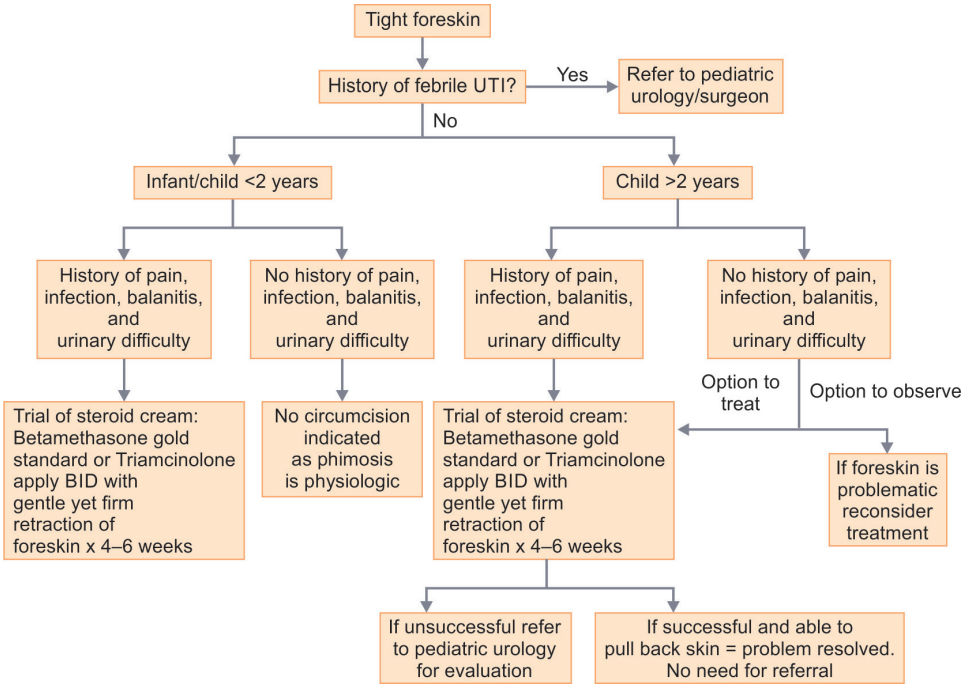

Indications

- ☑ Cultural reasons—most commonly performed
  - In infants and young boys, circumcision is most usually performed at the request of the parents
- ☑ True phimosis (BXO)
  - Rare under the age of 5 years
- ☑ Recurrent attacks of balanoposthitis
- ☑ Recurrent urinary tract infections with an abnormal upper urinary tract
- ☑ Circumcision is best performed under general anesthesia. A long-acting local anesthetic regional block can be given to reduce postoperative pain
- ☑ It is highly imperative that the urethral meatus position is checked and hypospadias is ruled out before surgery as preputial skin may be required for urethroplasty
- ☑ Circumcision is not a trivial operation. Complications such as bleeding and infection are well recognized and more serious hazards such as injury to the glans, may occur if procedure is not carried out by adequately trained personnel.

Flowchart 2: Medical management of phimosis in children.

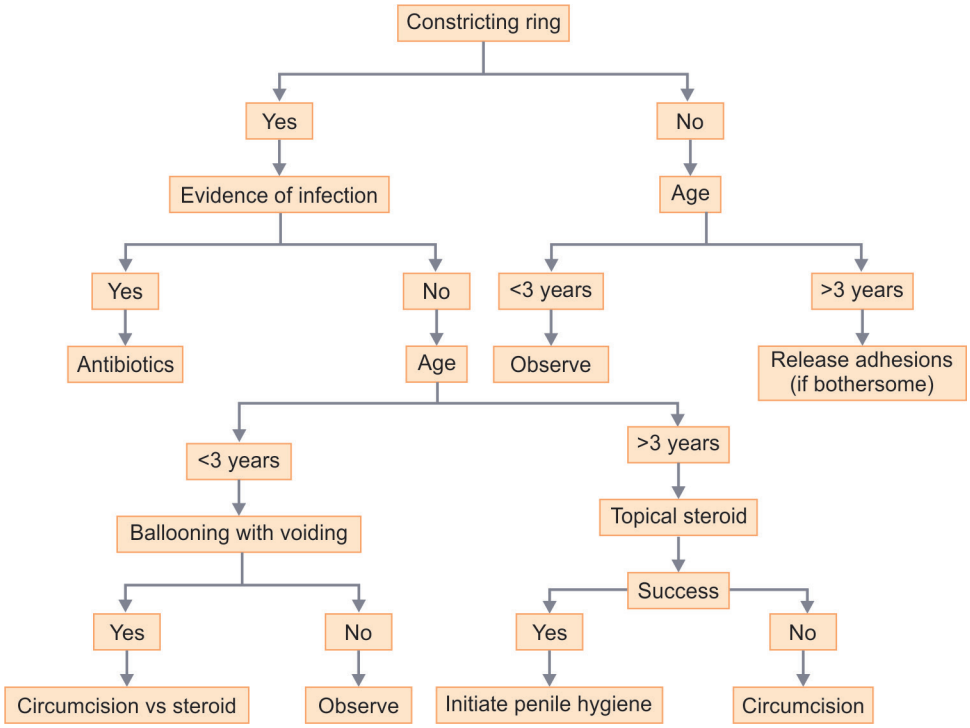

Indian Academy of Pediatrics (IAP)

STANDARD TREATMENT GUIDELINES 2022

Influenza in Children

Lead Author
Rohit Agrawal

Co-Authors
Mithila Amin

Under the Auspices of the IAP Action Plan 2022

Remesh Kumar R
IAP President 2022

Upendra Kinjawadekar
IAP President-Elect 2022

Piyush Gupta
IAP President 2021

Vineet Saxena
IAP HSG 2022–2023

© Indian Academy of Pediatrics

IAP Standard Treatment Guidelines Committee

Chairperson

Remesh Kumar R

IAP Coordinator

Vineet Saxena

National Coordinators

SS Kamath, Vinod H Ratageri

Member Secretaries

Krishna Mohan R, Vishnu Mohan PT

Members

Santanu Deb, Surender Singh Bisht, Prashant Kariya, Narmada Ashok, Pawan Kalyan