Retinopathy of Prematurity

144

Definition

Retinopathy of prematurity (ROP) is a disorder of retina, predominantly in preterm and low birth weight neonates, and is characterized by new vessel formation (neovascularization) and may progress to retinal detachment and blindness.

Risk Factors

The stimulus for new vessel formation, and hence ROP may be precipitated by presence of one or more of the following risk factors:

- ☑ Prematurity
- ☑ Low birth weight
- ☑ High exposure to oxygen for prolonged period and fluctuating hypoxia and hyperoxia
- ☑ Apnea
- ☑ Sepsis
- ☑ Anemia
- ☑ Cardiac defects
- ☑ Multiple blood transfusion
- ☑ Respiratory distress syndrome

Infants with very low birth weight are at significantly higher risk of developing severe ROP that requires treatment. Similarly, the severity of ROP is inversely proportional to gestational age.

The **Figures 1A to D** depict the recent classification of severity of ROP (ICROP, 3rd edition)

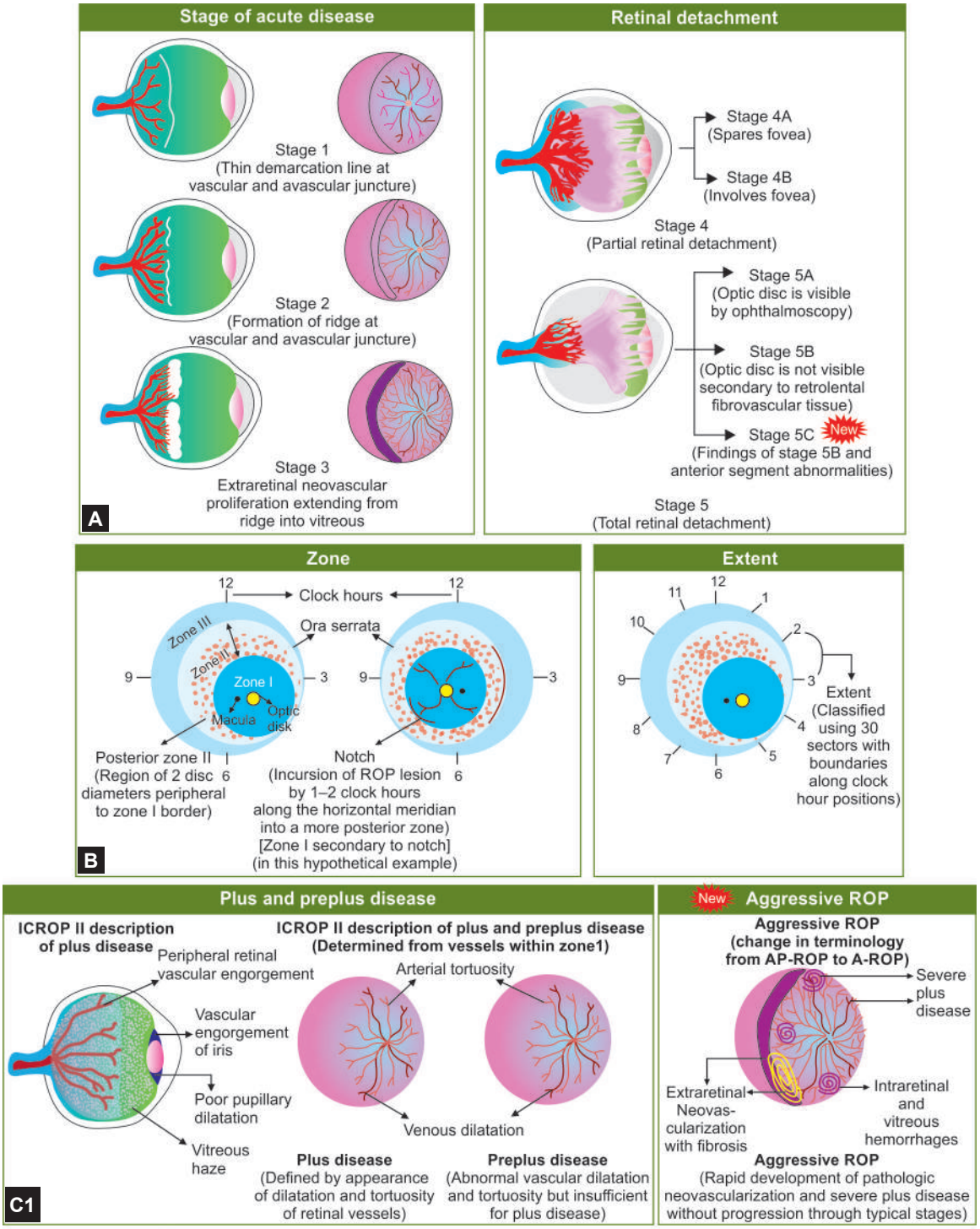

Figs. 1A to C1

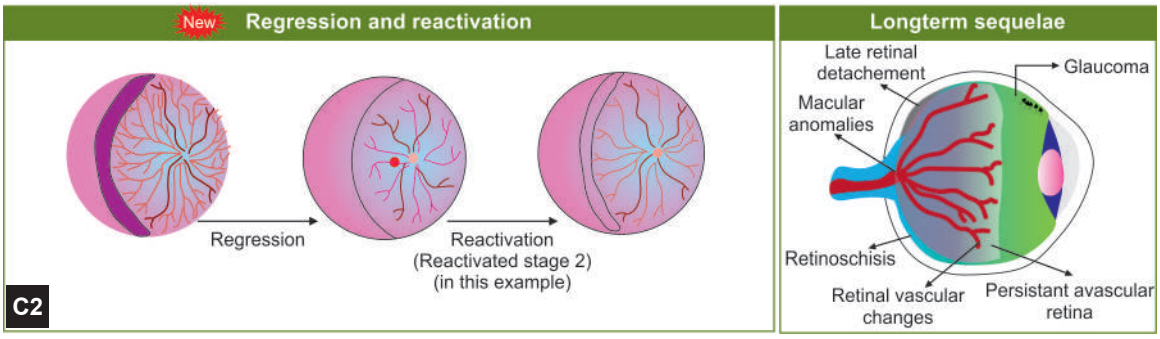

Whom to screen?	When to screen?
☑ Birth weight <2,000 g OR ☑ Gestational age <34 weeks OR ☑ Gestational age between 34 and 36 weeks but with risk factors such as: (a) Cardiorespiratory support, (b) Prolonged oxygen therapy, (c) Respiratory distress syndrome, (d) Chronic lung disease, (e) Fetal hemorrhage, (f) Blood transfusion, (g) Neonatal sepsis, (h) Exchange transfusion, (i) Intraventricular hemorrhage, (j) Apneas, and (k) Poor postnatal weight gain. ☑ Infants with an unstable clinical course who are at high risk (as determined by the neonatologist or pediatrician). *Source:* Rashtriya Bal Suraksha Karyakram (RBSK). National Neonatology Forum Clinical Practice Guidelines (CPG) 2020.	☑ First screening for retinopathy of prematurity (ROP) should be performed at 4 weeks postnatal age (PNA). ☑ In neonates <28 weeks of gestation (up to 27^{+6} weeks) or with birth weight <1,200 g if gestation at birth is not confirmed conclusively, the first examination for ROP should be preponed to 2–3 weeks PNA. *Source:* National Neonatology Forum Clinical Practice Guidelines (CPG) 2020.

D

Figs. C2 and D

Figs. 1A to D: Stages of retinopathy of prematurity (ROP) from stage 1 to stage 5C. Zones and the extent as measured by clock hours. Aggressive posterior ROP replaced by term aggressive ROP in the ICROP3 classification. "Regression" and "reactivation" are new terminologies as per ICROP3.

(ICROP3: International Classification of Retinopathy of Prematurity, Third Edition; ROP: retinopathy of prematurity)

How to Prepare for Screening?

Identification of Eligible Neonates for ROP Screening in the Unit

- ☑ There should be strict unit protocol to identify the at-risk neonates, who are eligible for ROP screening.
- ☑ Timely screening is essential to identify the disease at an early stage, and hence prevent blindness.

Color coded placards, red/pink sticker/dot on the eligible neonates for ROP screening may aid in timely ROP screening in the unit.

Dilatation of Eyes for Direct Ophthalmoscopy for ROP Screening

Commonly Used Eye Drops

- ☑ Combination of phenylephrine (5%), tropicamide (0.8%): This should be diluted 1: 1 with pharmaceutically available methyl cellulose eye drops, so that the final drop has 2.5% phenylephrine and 0.4% tropicamide.
- ☑ Phenylephrine (5%) should be diluted 1:1 with pharmaceutically available methyl cellulose eye drops to obtain final concentration of 2.5%. It can be used in combination with tropicamide 0.5% or 0.5% cyclopentolate.
- ☑ *Tropicamide eye drops:* 0.5% with phenylephrine 2.5% or cyclopentolate 0.5% with phenylephrine 2.5% eye drops. Need to dilute commercially available combination dilator (tropicamide 0.8% with phenylephrine 5%) drop with methyl cellulose eye drops or distilled water.

  One drop three times at 10 minutes interval. Pupil usually dilates in 30 minutes time and it persists for 30–45 minutes.

Practice Tip

- ☑ To avoid excessive absorption and toxicity wipe the excess drops from medial canthus after putting the drop in the infants' eye especially when baby is lying in supine position either on the mother's lap or on the bed.
- ☑ If the pupils are not dilating despite administration of adequate mydriatic drops, severe, or advanced ROP should be suspected.

Developmentally supportive care (DSC), pain relief, asepsis, and continuous monitoring of neonate for vitals, are essential components of ROP screening process.

How to Prepare for Screening?

Pain Relief during ROP Screening

A combination of topical anesthetic (TA) eye drops (0.5% proparacaine) 30 seconds prior to examination combined with oral 24% sucrose or 25% dextrose in the dose of 0.5 mL/kg just before the insertion of eye speculum should be used for prevention of pain during screening for ROP.

Equipment Checklist for ROP Screening

Indirect ophthalmoscope	***Sterile cotton and gloves***
20, 28 OR 30D lens	ROP documentation sheet
Pediatric speculum (Alfonso speculum)	Nesting and swaddling of the baby
Infant scleral depressor	Nonpharmacological measures for pain relief
Eye drops for dilating the pupils	
Topical anesthetic eye drops	
Topical antibiotic eye drops	

Next Screening Visit

No Signs of ROP

Follow-up examination for infants at risk should be done 2–3 weeks intervals until the retina is fully vascularized.

If ROP is Present

Follow-up examinations are normally required every 1–2 weeks depending upon ROP staging and as recommended by the examining ophthalmologist, however, a broad guide for the interval of follow up for other stages of ROP are as follows:

Zone of retinal findings	***Stage***	***Follow-up interval***
Zone 1	Immature vasculature	1–2 weeks
Zone 1	Stage 1 or 2 or 3	1 week or less
Zone 1	Regressing ROP	1–2 weeks
Zone 2	Immature vasculature	2–3 weeks
Zone 2	Stage 1	2 weeks
Zone 2	Stage 2	1–2 weeks
Zone 2	Stage 3	1 week or less
Zone 2	Regressing ROP	1–2 weeks
Zone 3	Stage 1 or 2	2–3 weeks
Zone 3	Regressing ROP	2–3 weeks

*If there is preplus disease, baby should be screened at 3–4 days interval.
ROP screening can be terminated once there is complete vascularization of retina without any ROP, or if the ROP has shown complete regression. This normally happens at around 40–44 weeks of postmenstrual age (PMA).

Practice Tip

- ☑ If the eligible neonate is planned for discharge before the scheduled ROP screening, ensure that the exact follow-up date and precise location for reporting for ROP screening is mentioned on the discharge slip.
- ☑ A printed discharge template mentioning the ROP follow-up visit can help in strengthening the ROP screening postdischarge.

Management

For management, ROP is classified as type 1 ROP, which needs treatment and type 2 ROP, which needs close follow-up.

Type 1 ROP (needs treatment)

- ☑ Zone I, any stage ROP with plus disease
- ☑ Zone I, stage 3 ROP without plus disease
- ☑ Zone II, stage 2 or 3 ROP with plus disease

Aggressive ROP in any zone is also included in treatment needing ROP

Type 2 ROP (needs close follow-up)

- ☑ Zone I, stage 1 or 2 ROP without plus disease (excluding aggressive ROP)
- ☑ Zone II, stage 3 ROP without plus disease (excluding aggressive ROP)

Treatment Modalities

Laser Ablation

Laser ablation is the standard of treatment for type 1 ROP and aggressive ROP but may not be able to preserve the peripheral field of vision. An alternative modality of treatment of zone 1 ROP is anti-VEGF (antivascular endothelial growth factor) therapy.

Anti-VEGF

- ☑ Intravitreal bevacizumab may be used for treatment of type 1 ROP involving zone 1.
- ☑ Intravitreal bevacizumab should not be used for treatment of zone 2 ROP, due to higher incidence of need of retreatment and lack of evidence on possible harmful effects.
- ☑ At present, evidence is not sufficient for use of anti-VEGF drugs other than bevacizumab.

Counseling

Counseling of the parents is essential depending on the severity of the disease.

- ☑ *Parents of all babies at risk:* Written general information should be provided.
- ☑ *Parents of infants with severe ROP:* The ophthalmologist should personally discuss about the disease and availability of management with the parents. Written informed consent must be obtained for use of anti-VEGF drugs, including off-label use.
- ☑ *Parents of infants with advanced cicatricial ROP and with visual impairment:* It is important to ensure that children with visual impairment have access to all services, registration with relevant associations of the blind and vocational guidance centers.

Long-term Follow-up

Postscreening

Assessment of vision should be carried out in all preterm infants throughout the first year of life to detect associated disorders such as neurological abnormalities and amblyopia.

Infants Treated for ROP

- ☑ Follow-up examinations should be tailored individually.
- ☑ If adequate laser/cryotherapy treatment has been given, and the disease has fully regressed, a follow-up examination should be carried out at 3 months.
- ☑ Cycloplegic refraction should be performed at 6 months.
- ☑ Follow-up should be annually. Sometimes more frequent follow-up is necessary if indicated.

Long-term follow-up of retinal examinations including retinal periphery are needed till at least 65 weeks PMA after use of anti-VEGF drugs, as there is definite risk of recurrence with or without additional laser ablation, and supplemental LASER may be needed.

Post-treatment follow-up should be carried out for all infants till they reach preschool years, to monitor the development of vision, refractive status, and strabismus.

Infants with Complications of ROP

- ☑ Ophthalmologist must ensure that the child gains early access to the services for the visually impaired. The social and educational services provide much needed support to these children.

Remember that the incidence of interventional ROP in a unit is a measure of quality of care. Following best practices in neonatal care is crucial to prevent sight-threatening ROP.

Further Reading

- ☑ Chiang MF, Quinn GE, Fielder AR, Ostmo SR, Paul Chan RV, Berrocal A, et al International Classification of Retinopathy of Prematurity, Third Edition. Ophthalmology. 2021;128(10): e51-e68.
- ☑ National Neonatology Forum, India. (2020). Clinical Practice Guidelines: Screening and Management of Retinopathy of Prematurity. [online]. Available from http://www.nnfi.org/assests/pdf/cpg-guidelines/ropp.pdf [Last accessed December, 2022].
- ☑ Rashtriya Bal Swasthya Karyakram, Ministry of Health and Family Welfare, Government of India. (2017). Guidelines for Universal Eye Screening in Newborns Including Retinopathy of Prematurity. [online]. Available from https://nhm.gov.in/images/pdf/programmes/RBSK/Resource_Documents/Revised_ROP_Guidelines-Web_Optimized.pdf [Last accessed December, 2022].
- ☑ Shukla R, Murthy GVS, Gilbert C, Vidyadhar B, Mukpalkar S. Operational guidelines for ROP in India: A summary. Indian J Ophthalmol. 2020;68(Suppl 1):S108-S114.

Indian Academy of Pediatrics (IAP)

STANDARD TREATMENT GUIDELINES 2022

Temper Tantrums

Lead Author
Tilak Chandra

Co-Authors
Hrishikesh, Arpita Gupta

Under the Auspices of the IAP Action Plan 2022

Remesh Kumar R
IAP President 2022

Upendra Kinjawadekar
IAP President-Elect 2022

Piyush Gupta
IAP President 2021

Vineet Saxena
IAP HSG 2022–2023

© Indian Academy of Pediatrics

IAP Standard Treatment Guidelines Committee

Chairperson

Remesh Kumar R

IAP Coordinator

Vineet Saxena

National Coordinators

SS Kamath, Vinod H Ratageri

Member Secretaries

Krishna Mohan R, Vishnu Mohan PT

Members

Santanu Deb, Surender Singh Bisht, Prashant Kariya, Narmada Ashok, Pawan Kalyan