TORCH Infections

148

Introduction

Congenital infections are traditionally referred as TORCH infection and are significant cause of fetal and neonatal morbidity and mortality. The TORCH mnemonic comprises of toxoplasmosis, rubella, cytomegalovirus (CMV), and herpesvirus. The "O" acronym has been variably included for syphilis, varicella zoster, parvovirus B19, hepatitis B, Zika, and other.

Transmission of the pathogens may occur prenatally, perinatally, and postnatally through transplacental passage of organisms, from contact with blood and vaginal secretions, or from exposure to breast milk for CMV, human immunodeficiency virus (HIV), and herpes simplex virus (HSV).

Evidence of infection may be seen at:

- ☑ Birth
- ☑ In infancy
- ☑ In childhood

BOX 1: When to screen for TORCH infection?

Antenatal

- ☑ Routine screening for syphilis and hepatitis B is done antenatally
- ☑ Routine "TORCH panel" is not recommended in low risk asymptomatic pregnant women. It is unhelpful in recurrent miscarriages
- ☑ TORCH screening is indicated in presence of fetal hydrops, unexplained intrauterine growth restriction (IUGR), sonographic markers of fetal infections
- ☑ Unexplained fetal anemia should be screened for parvovirus B19

Neonate

- ☑ Intrauterine infection may be suspected in newborns with certain clinical manifestations or combinations of clinical manifestations including (but not limited to) to following:
  - Hydrops fetalis
  - Microcephaly
  - Cataract
  - Hearing loss
  - Rash and IUGR
  - Hepatosplenomegaly and conjugated jaundice
  - Congenital heart disease with above combination
  - *Case-to-case basis:* Seizures, thrombocytopenia, and jaundice

BOX 2: Initial evaluation in case of suspected TORCH infection.

- ☑ *Maternal history:* Evidence of rubella immunity, syphilis serology, history of herpes simplex virus (HSV), exposure to cats, etc.
- ☑ Antenatal scan details in unexplained intrauterine growth restriction (IUGR) including from when the fetus was noticed to be IUGR, fetal hydrops or brain abnormalities, abnormal Doppler flow suggestive of fetal anemia for parvovirus B19
- ☑ *Physical assessment:*
  - Head—microcephaly
  - Eyes—cataract, chorioretinitis, and microphthalmia
  - Pallor
  - Growth restriction
  - Lung—pneumonitis
  - Cardiac—cardiomegaly and patent ductus arteriosus (PDA)
  - Hepatomegaly, jaundice, and hepatitis
  - Splenomegaly
  - Skin—blueberry muffin rash, petechial, and scar
  - Bone abnormalities
- ☑ *Investigation:*
  - Complete blood count and platelet count—anemia, neutropenia, and thrombocytopenia
  - Liver function tests (particularly important in HSV infection)
  - Radiographs of long bones
  - Ophthalmologic evaluation
  - Audiologic evaluation
  - Neuroimaging
  - Lumbar puncture (if neurological signs)
  - Urine for cytomegalovirus (CMV)

TABLE 1: TORCH infection—classical findings.

Congenital toxoplasmosis	*Congenital rubella*	*Congenital CMV*	*HSV—perinatal*	*Congenital syphilis*	*Congenital varicella*
☑ Intracranial calcifications (diffuse) ☑ Hydrocephalus ☑ Chorioretinitis ☑ Otherwise unexplained mononuclear CSF pleocytosis or elevated CSF protein	☑ Cataracts, congenital glaucoma, and pigmentary retinopathy ☑ Congenital heart disease (PDA and peripheral PS) ☑ Radiolucent bone disease ☑ Sensorineural hearing loss	☑ Periventricular intracranial calcifications ☑ Microcephaly ☑ Hepato-splenomegaly ☑ Thrombo-cytopenia ☑ Sensorineural hearing loss	☑ Mucocutaneous vesicles ☑ CSF pleocytosis ☑ Thrombo-cytopenia and elevated liver transaminases ☑ Conjunctivitis or kerato-conjunctivitis	☑ Skeletal abnormalities (osteochondritis and periostitis) ☑ Pseudoparalysis ☑ Persistent rhinitis ☑ Maculopapular rash (particularly on palms and soles or in diaper area)	☑ Cicatricial or vesicular skin lesions ☑ Micro-cephaly

(CSF: cerebrospinal fluid; HSV: herpes simplex virus; PDA: patent ductus arteriosus; PS: pulmonary stenosis)

Flowchart 1: Approach to congenital CMV infection.

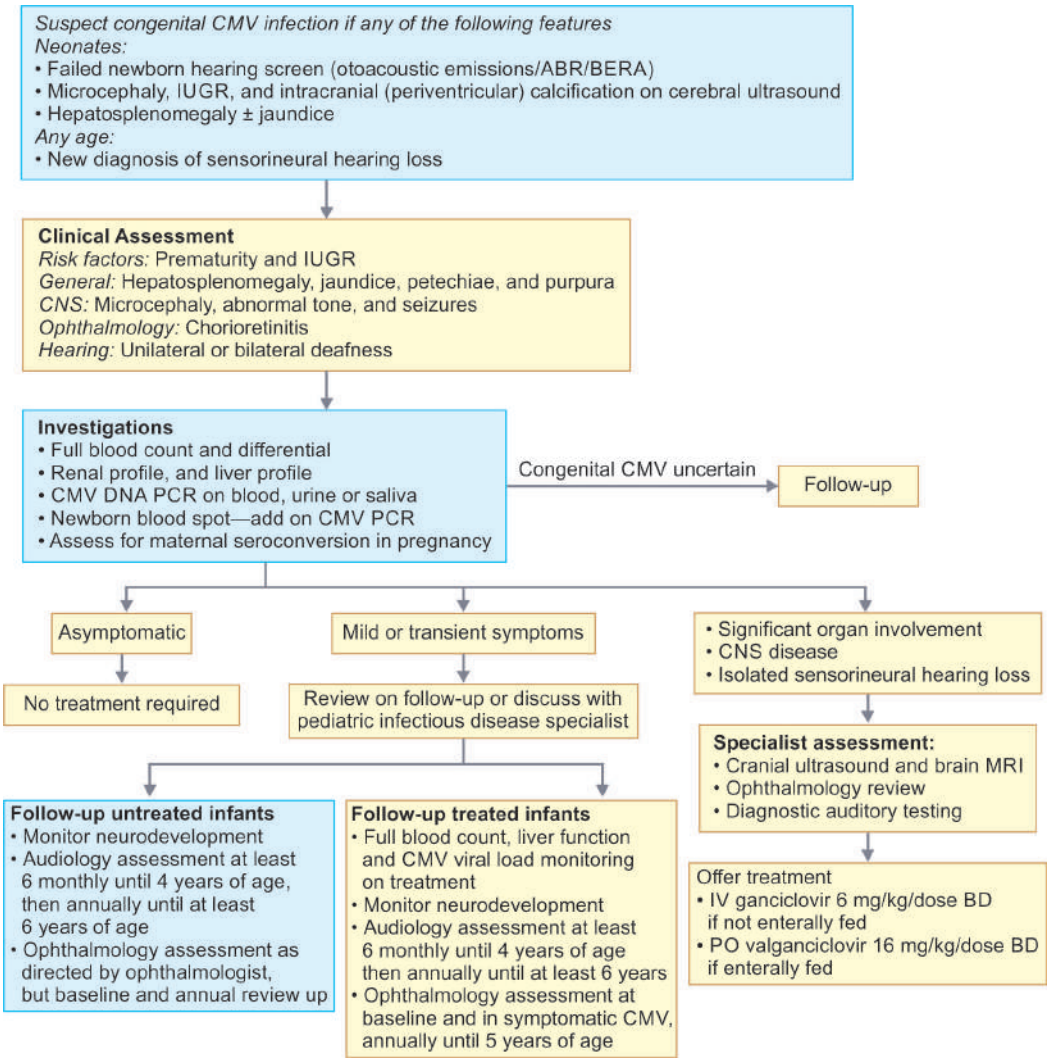

(ABR: auditory brainstem response; BERA: brainstem evoked response audiometry; CMV: cytomegalovirus; CNS: central nervous system; DNA: deoxyribonucleic acid; IUGR: intrauterine growth restriction; IV: intravenous; PCR: polymerase chain reaction)

Flowchart 2: Approach to neonate with perinatal herpes.

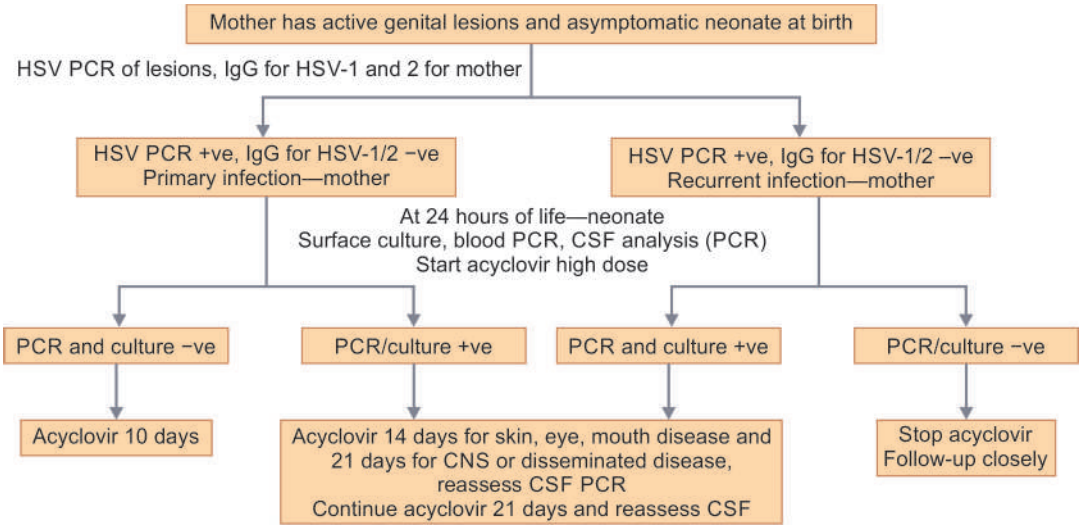

(CNS: central nervous system; CSF: cerebrospinal fluid; HSV: herpes simplex virus; IgG: immunoglobulin G; PCR: polymerase chain reaction)

Flowchart 3: Approach to a neonate born to HBsAg positive mother.

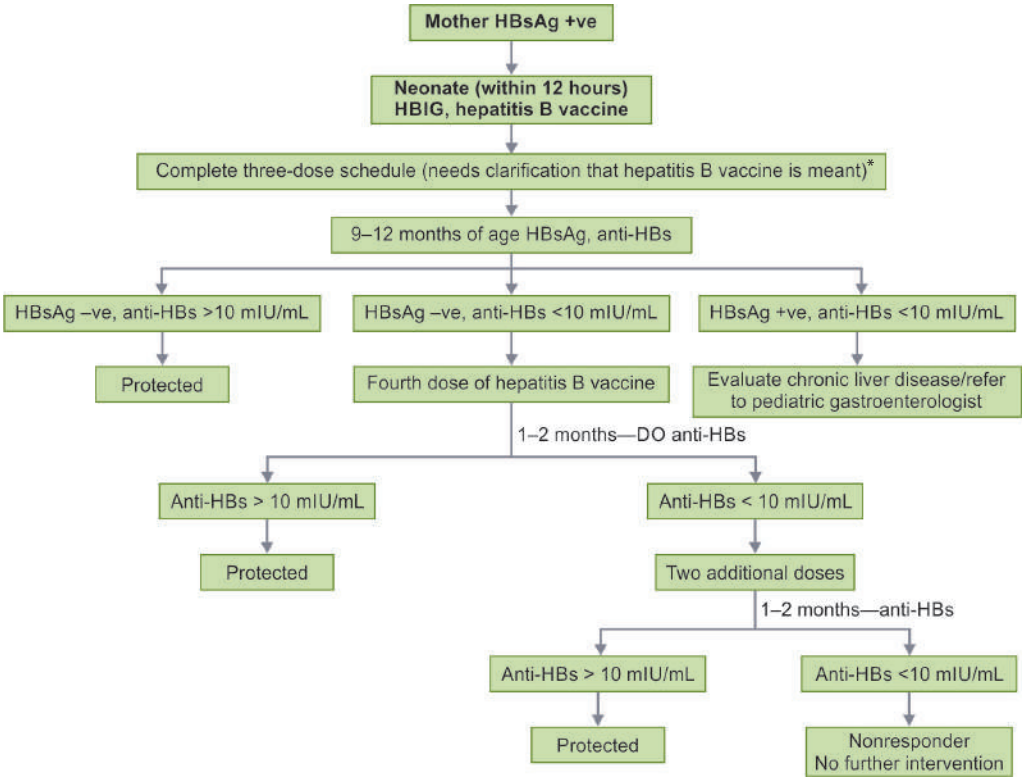

*For doses in preterm—four doses should be given
(HBIG: hepatitis B immunoglobulin; HBsAg: hepatitis B surface antigen)

TABLE 2: Approach to congenital rubella, varicella, and syphilis.

Disease	*Clinical examination*	*Diagnosis*	*Treatment*
Congenital rubella syndrome	☑ *Eye:* Cataract ☑ Microcephaly ☑ Congenital heart Disease—PDA, peripheral PS ☑ Sensorineural deafness ☑ Blueberry muffin rash ☑ Hepatosplenomegaly, jaundice	☑ Serum IgM (up to 3 months) ☑ Urine/salive—PCR (before 3 months)	☑ No medical treatment ☑ Cardiac evaluation and treatment ☑ Hearing assessment and aids ☑ Neurorehabilitation
Congenital varicella	☑ Congenital (mother infected 8–20 weeks of gestational age)—skin lesion, cataracts, chorioretinitis, hypoplastic limbs ☑ Cortical atrophy and seizures ☑ Perinatal—mother develops chickenpox 5 days before or 2 days after birth	☑ Clinical findings and maternal history ☑ Serology ☑ PCR of lesion	☑ Congenital—no treatment, rehabilitation ☑ Perinatal—IV acyclovir 60 mg/kg/day in three divided doses ☑ Zoster immunoglobulin (ZIG) ☑ If ZIG not available than IVIG 400 mg/kg can be administered
Congenital syphilis	☑ Stillbirth, hydrops fetalis, prematurity ☑ Many asymptomatic at birth ☑ *Early:* Osteochondritis, periostitis, snuffles, hemorragic rhinitis, HS megaly, jaundice, IUGR, hydrops	☑ VDRL, RPR ☑ FTA-ABS ☑ TP-PA	☑ Definitive/highly probable/probable or possible disease—IV aqueous crystalline penicillin G for total of 10–14 days—50,000 unitis/kg/dose every 12 hours ☑ Unlikely—mother received treatment, serology and symptoms negative—give one dose of benzathine penicillin
Congenital parvovirus B19	☑ Fetal anemia ☑ Fetal hydrops	☑ Serum IgM for parvovirus B19	☑ Antenatal monitoring for fetal anemia—middle cerebral artery blood flow ☑ 18–32 weeks of gestation age—intrauterine transfusion

(FTA-ABS: fluorescent treponemal antibody absorption; HS: hereditary spherocytosis; IgM: immunoglobulin M; IUGR: intrauterine growth restriction; IVIG: intravenous immunoglobulin; PCR: polymerase chain reaction; PDA: patent ductus arteriosus; PS: pulmonic stenosis; RPR: rapid plasma reagin; TP-PA: *Treponema pallidum* particle agglutination; VDRL: venereal disease research laboratory)

Flowchart 4: Approach to congenital toxoplasmosis infection.

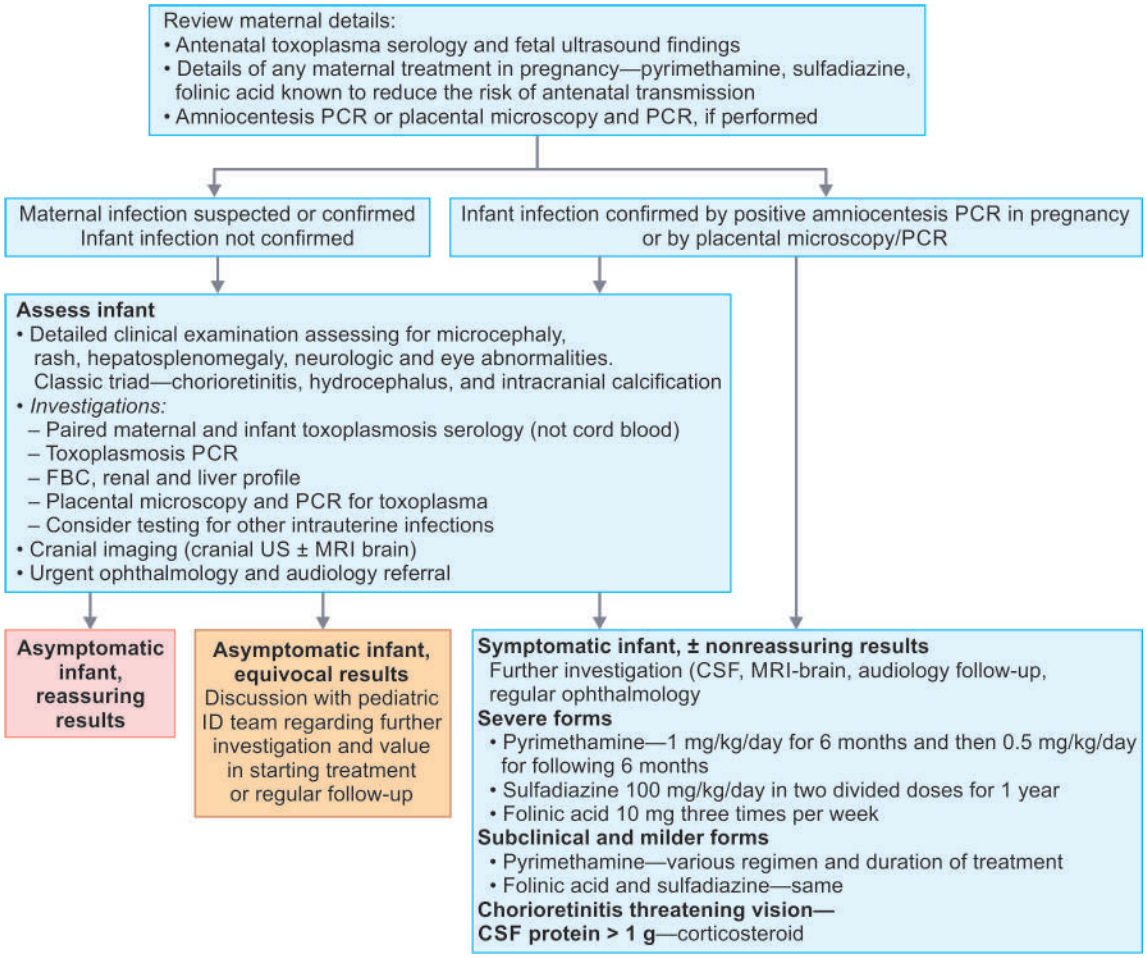

Further Reading

- ☑ Natalie Neu, Duchon J, Zachariah P. TORCH infections. Clin Perinatol. 2015;42(1):77-103.
- ☑ Pejawar R, Thakre R. Textbook of Clinical Neonatology, 1st edition. New Delhi: Jaypee Brothers Medical Publishers (P) Ltd.; 2021.
- ☑ Remington J, Klein J, Wilson C, Maldonado Y, Nizet V. Infectious Diseases of the Fetus and Newborn Infant, 7th edition. Philadelphia: Elsevier, Saunders; 2011.

Indian Academy of Pediatrics (IAP)

STANDARD TREATMENT GUIDELINES 2022

Diagnosis and Management of Childhood Tuberculosis

Lead Author

Varinder Singh

Co-Authors

Ankit Parakh, Sushant Mane

Under the Auspices of the IAP Action Plan 2022

Remesh Kumar R
IAP President 2022

Upendra Kinjawadekar
IAP President-Elect 2022

Piyush Gupta
IAP President 2021

Vineet Saxena
IAP HSG 2022–2023

© Indian Academy of Pediatrics

IAP Standard Treatment Guidelines Committee

Chairperson

Remesh Kumar R

IAP Coordinator

Vineet Saxena

National Coordinators

SS Kamath, Vinod H Ratageri

Member Secretaries

Krishna Mohan R, Vishnu Mohan PT

Members

Santanu Deb, Surender Singh Bisht, Prashant Kariya, Narmada Ashok, Pawan Kalyan