AI-Assisted Clinical Decision Support System
CHEST X-RAY SUGGESTIVE DIAGNOSIS REPORT

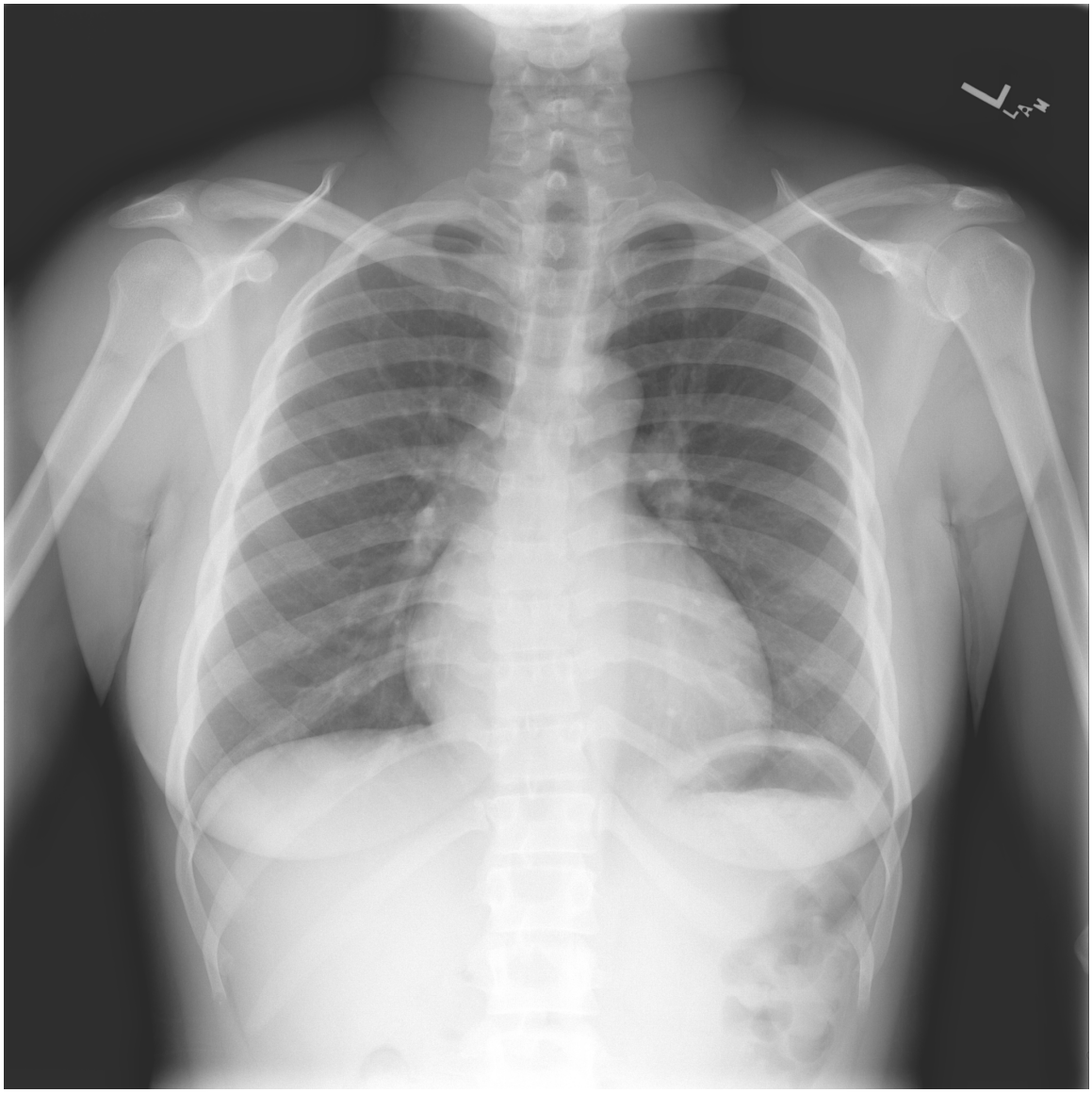

Patient Name: Mary Jane
Age: 68

IMPRESSION:
No acute cardiopulmonary abnormality identified. Findings are compatible with prior granulomatous disease. No focal consolidation, large pleural effusion, or pneumothorax is identified. Evidence of prior granulomatous disease. No acute cardiopulmonary abnormality.

Generated by: Visaul RAG System

This report is AI-assisted and intended for research purposes only.