# AI-Assisted Clinical Decision Support System
# CHEST X-RAY SUGGESTIVE DIAGNOSIS REPORT

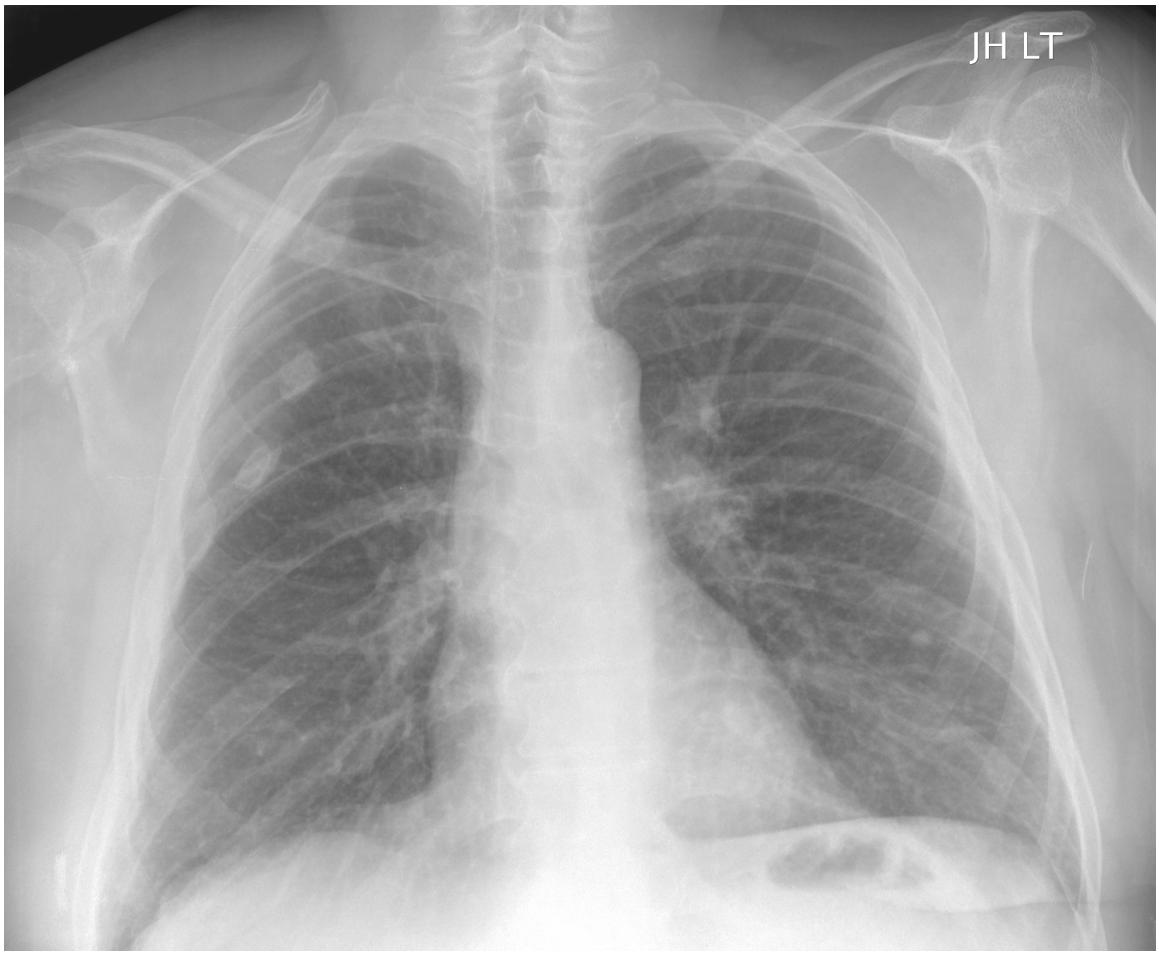


Patient Name: John Doe
Age: 54

IMPRESSION:
No acute cardiopulmonary abnormality. The cardiomediastinal silhouette is normal in size and configuration. The lungs are clear and well aerated without focal airspace consolidation, pneumothorax, or large pleural effusion.

Generated by: Visaul RAG System

---

This report is AI-assisted and intended for research purposes only.