PHÒNG KHÁM THÚ Y SUNVET

Test Report of Hematological Morphological Analysis

Pet Name: coco
Gender: Male
Case No.: 2602020001

Owner Tel.:
Species: Canine
Test Time: 2026-02-02 13:13

Owner Name:
Age: 2Month

Test Results

	Test Item	Test Result		Reference Range
01.	WBC	83.54 10^9/L	↑	5.05-16.76
	NEU#	75.26 10^9/L	↑	2.95-11.64
	NST#	1.46 10^9/L	↑	0.00-0.80
	NSG#	72.81 10^9/L	↑	2.50-11.30
	NSH#	0.99 10^9/L	↑	0.00-0.40
	LYM#	4.44 10^9/L		1.05-5.10
	MON#	3.79 10^9/L	↑	0.16-1.12
	EOS#	0.01 10^9/L	↓	0.06-1.23
	BAS#	0.04 10^9/L		0.00-0.10
	NEU%	90.08 %	↑	52.00-78.00
	NST/WBC%	1.74 %		0.00-10.00
	NST/NEU%	1.94 %		0.00-20.00
	NSG%	87.15 %	↑	50.00-75.00
	NSH/WBC%	1.19 %		0.00-5.00
	NSH/NEU%	1.32 %		0.00-7.00
	LYM%	5.32 %	↓	16.00-41.50
	MON%	4.54 %		1.00-13.00
	EOS%	0.01 %	↓	0.50-11.85
	BAS%	0.05 %		0.00-0.90
02.	RBC	2.5 10^12/L	↓	5.65-8.87
	HGB	51.38 g/L	↓	131.00-205.00
	HCT	16.2 %	↓	37.30-61.70
	MCV	64.86 fL		61.60-73.50
	MCH	20.58 pg	↓	21.20-25.90
	MCHC	317.23 g/L	↓	320.00-379.00
	RDW-CV	11.9 %		11.20-17.10
	RDW-SD	29.0 fL		25.60-41.60
	HDW-CV	13.25 %		7.00-20.00
	HDW-SD	2.73 g/L		2.00-8.00
	RET#	29.23 10^9/L		3.00-110.00
	RET%	1.17 %		0.00-1.50
	ETG#	0.0 10^12/L		0.00-0.05
	ETG%	0.0 %		0.00-1.65
	SPH#	0.31 10^9/L		0.00-130.10
	SPH%	0.01 %		0.00-1.54
03.	PLT	590.31 10^9/L	↑	148.00-484.00
	MPV	12.95 fL		8.70-13.20
	PDW	10.91 fL		9.10-19.40
	PCT	0.76 %	↑	0.14-0.46
	APLT#	0.0 10^9/L		0.00-0.15

SUN VET

NEOVET DX

This test result is valid for this sample and is only used as a diagnostic reference for clinicians.

PHÒNG KHÁM THÚ Y SUNVET

Test Report of Hematological Morphological Analysis

Pet Name: coco **Case No.:** 2602020001 **Test Time:** 2026-02-02 13:13

Test Item	Test Result	Reference Range	Low	Normal	High
P-LCC	39.06 10^9/L	0.00-66.00			
P-LCR	6.62 %	0.00-25.00			

White Blood Cell Distribution Image (WBC)

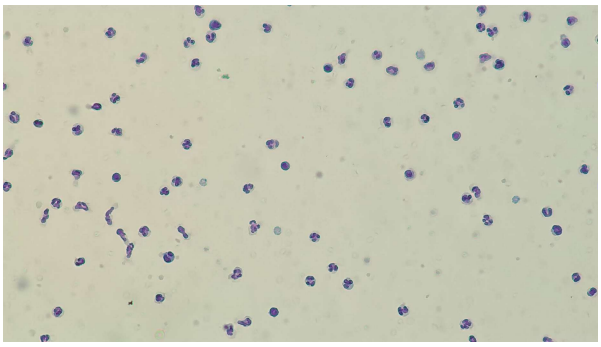

Red Blood Cell & Platelet Distribution Image (RBC&PLT)

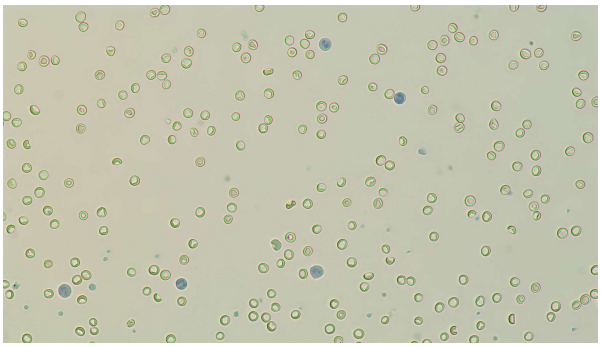

WBC Histogram

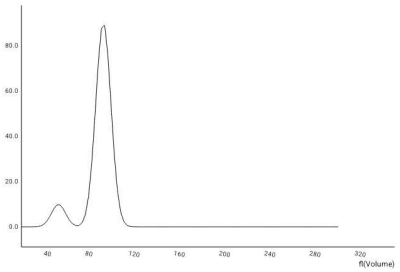

RBC Histogram

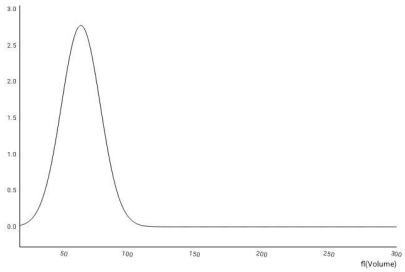

Platelet Histogram

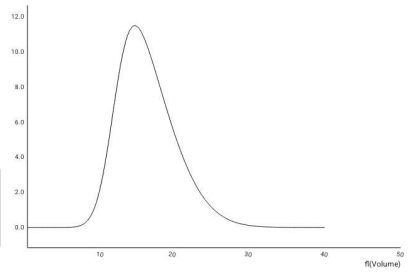

This test result is valid for this sample and is only used as a diagnostic reference for clinicians.

PHÒNG KHÁM THÚ Y SUNVET

Test Report of Hematological Morphological Analysis

Pet Name: coco **Case No.:** 2602020001 **Test Time:** 2026-02-02 13:13

NST

Number: 151 sheets/143 images/754 images | Concentration: 1.46 10^9/L

NSG

Number: 7762 sheets/143 images/754 images | Concentration: 72.81 10^9/L

NSH

Number: 101 sheets/143 images/754 images | Concentration: 0.99 10^9/L

LYM

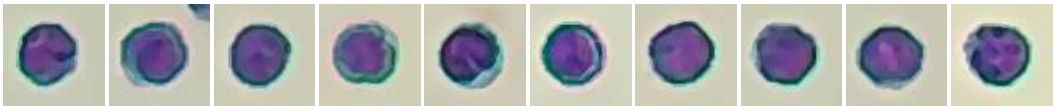

Number: 478 sheets/143 images/754 images | Concentration: 4.44 10^9/L

MON

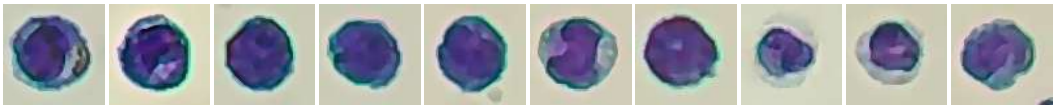

Number: 405 sheets/143 images/754 images | Concentration: 3.79 10^9/L

EOS

Number: 1 sheets/143 images/754 images | Concentration: 0.01 10^9/L

This test result is valid for this sample and is only used as a diagnostic reference for clinicians.

PHÒNG KHÁM THÚ Y SUNVET

Test Report of Hematological Morphological Analysis

Pet Name: coco **Case No.:** 2602020001 **Test Time:** 2026-02-02 13:13

BAS

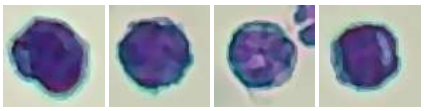

Number: 4 sheets/143 images/754 images | Concentration: 0.04 10^9/L

RET

Number: 305 sheets/143 images/754 images | Concentration: 29.23 10^9/L

ETG

Number: 1 sheets/143 images/754 images | Concentration: 0.0 10^12/L

SPH

Number: 1 sheets/143 images/754 images | Concentration: 0.31 10^9/L

P-LCC



Number: 2387 sheets/575 images/754 images | Concentration: 39.06 10^9/L

本检测结果对该样本负责，仅作为临床医生诊断参考

PHÒNG KHÁM THÚ Y SUNVET

Test Report of Hematological Morphological Analysis

Pet Name: coco **Case No.:** 2602020001 **Test Time:** 2026-02-02 13:13

Clinical Significance

Individual Diagnosis

I. [WBC]

1. [WBC>16.76] It is common in cases of inflammation, blood diseases, malignant tumors, stress, infections (viral, bacterial, parasitic, etc.), tissue necrosis, poisoning, etc.
2. [NEU#>11.64] It is common in cases of bacterial infections, poisoning, post-operation, stress, acute inflammation, chronic inflammatory bleeding/hemolysis, etc.
3. [NST#>0.8] It indicates that the neutrophil nucleus has shifted to the left.
4. [NSG#>11.30] It indicates that the neutrophil nucleus has shifted to the right. It is common in cases of infectious inflammation, poisoning, post-operation, stress hemogram, etc.
5. [NSH#>0.40] It is indicated that there is a stress - induced blood profile, chronic inflammation, a disease recovery phase, glucocorticoid therapy, hyperadrenocorticism, long - term exposure to EDTA, etc.
6. [MON#>1.12] It is common in cases of stress, acute (late stage infections) and chronic inflammation, recovery from disease, suppurative inflammation, use of glucocorticoid drugs, etc.

II. [RBC]

1. [RBC<5.65] It is common in cases of infections, acute/chronic hemorrhagic anemia, hemolytic anemia, deficiency anemia, aplastic anemia, etc.
2. [HGB<131] It is common in cases of infections, severe hypochromic anemia, acute/chronic hemorrhagic anemia, hemolytic anemia, deficiency anemia, aplastic anemia, etc.
3. [HCT<37.3] It is common in cases of anemia or bleeding from various causes.
4. [MCH<21.20] Such decrease is common in cases of microcytic anemia
5. [MCHC<320.00] Such decrease is common in cases of chronic hemorrhagic anemia

III. [PLT]

1. [PLT>484] It is common in cases of inflammation, tumors, iron deficiency, post-splenectomy, myeloproliferative disorders, drug induction, etc.
2. [PCT>0.46] It indicates an increase in platelets or macroplatelets.

Combined Diagnosis

1. [RBC<5.65HGB<131] It indicates a normocytic anemia, which is common in cases of aplastic anemia, acute blood loss within 40 h, hemolysis within 40 h, decreased hematopoiesis, leukemia, etc.
2. [HGB<131MCHC<320] It indicates a hypochromic anemia, which is common in cases of iron deficiency anemia, chronic hemolysis, thalassemia, sideroblastic anemia, etc.
3. [HCT<37.3RET#<110] It indicates a non-regenerative anemia
4. [WBC>16.76NST#>0.8NSG#>11.3] It indicates an acute inflammation, which is common in cases of localized/systemic acute/suppurative diseases (e.g., nephritis, uterine inflammation, pyometra, pleurisy, pneumonia, endocarditis, leptospirosis, and severe pyoderma).

Testing Physician: **Chief Physician:** **Hospital Tel.:** **Report Date:** 2026-02-02

Hospital Address: 126 Nguyen Chi Thanh, P. Vuon Lai, Tp. HCM

This test result is valid for this sample and is only used as a diagnostic reference for clinicians.