PHÒNG KHÁM THÚ Y SUNVET

Test Report of Hematological Morphological Analysis

Pet Name: Map
Gender: Male
Case No.: 2601260003

Owner Tel.:
Species: Feline
Test Time: 2026-01-26 11:20

Owner Name:
Age:

Test Results

	Test Item	Test Result		Reference Range
01.	WBC	15.03 10^9/L		2.87-17.02
	NEU#	11.57 10^9/L	↑	2.30-10.29
	NST#	0.07 10^9/L		0.00-0.80
	NSG#	11.29 10^9/L		2.30-12.50
	NSH#	0.22 10^9/L		0.00-0.30
	LYM#	1.62 10^9/L		0.92-6.88
	MON#	0.5 10^9/L		0.05-0.67
	EOS#	1.34 10^9/L		0.17-1.57
	BAS#	0.0 10^9/L		0.00-0.26
	NEU%	77.02 %		38.00-80.00
	NST/WBC%	0.46 %		0.00-10.00
	NST/NEU%	0.6 %		0.00-15.00
	NSG%	75.1 %	↑	35.00-75.00
	NSH/WBC%	1.46 %		0.00-3.00
	NSH/NEU%	1.9 %		0.00-4.00
	LYM%	10.76 %	↓	16.00-47.50
	MON%	3.31 %		1.00-7.60
	EOS%	8.92 %		1.00-11.10
	BAS%	0.0 %		0.00-0.70
02.	RBC	5.7 10^12/L	↓	6.54-12.20
	HGB	98.21 g/L		98.00-162.00
	HCT	25.33 %	↓	30.30-52.30
	MCV	44.41 fL		35.90-53.10
	MCH	17.22 pg		11.80-17.30
	MCHC	387.73 g/L	↑	281.00-358.00
	RDW-CV	20.71 %	↓	20.90-33.60
	RDW-SD	15.74 fL	↓	16.00-27.40
	HDW-CV	14.94 %		7.00-30.00
	HDW-SD	2.57 g/L		2.00-8.00
	RET#	6.24 10^9/L		3.00-50.00
	RET%	0.11 %		0.00-1.00
	ETG#	0.27 10^12/L	↑	0.00-0.06
	ETG%	4.73 %	↑	0.00-2.50
	SPH#	190.69 10^9/L		0.00-193.66
	SPH%	3.34 %	↑	0.00-2.71
03.	PLT	184.92 10^9/L		151.00-600.00
	MPV	16.06 fL		11.40-21.60
	PDW	12.23 fL		9.10-19.40
	PCT	0.3 %		0.17-0.86
	APLT#	0.0 10^9/L		0.00-0.15

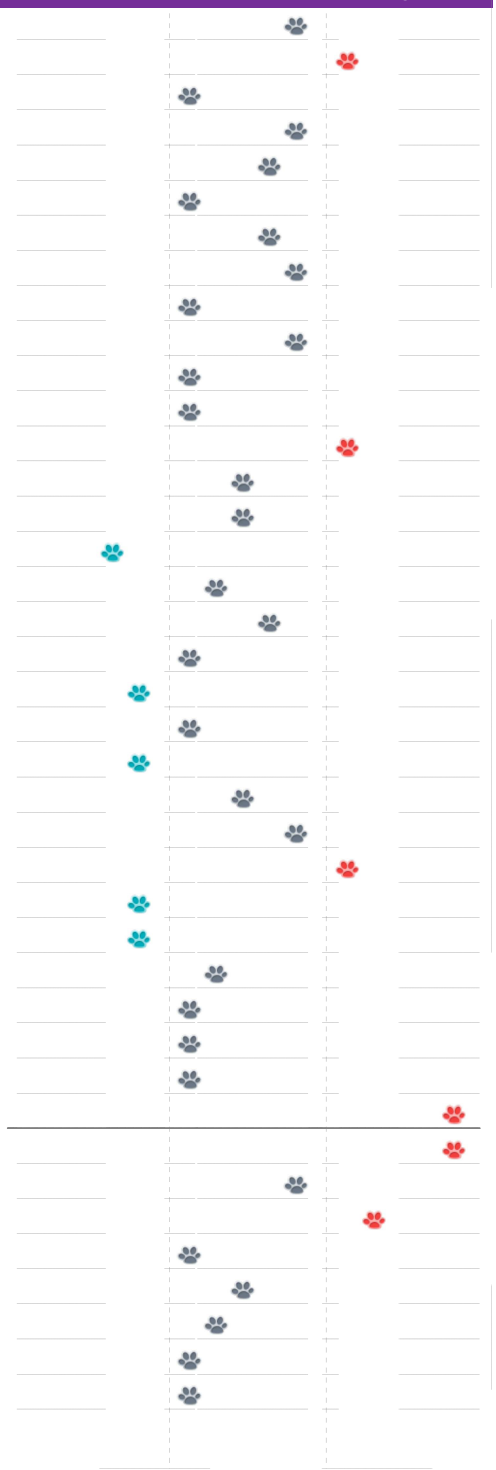

This test result is valid for this sample and is only used as a diagnostic reference for clinicians.

PHÒNG KHÁM THÚ Y SUNVET

Test Report of Hematological Morphological Analysis

Pet Name: Map **Case No.:** 2601260003 **Test Time:** 2026-01-26 11:20

Test Item	Test Result	Reference Range	Low	Normal	High
P-LCC	12.32 10^9/L	0.00-103.00			
P-LCR	6.66 %	0.00-30.00			

White Blood Cell Distribution Image (WBC)

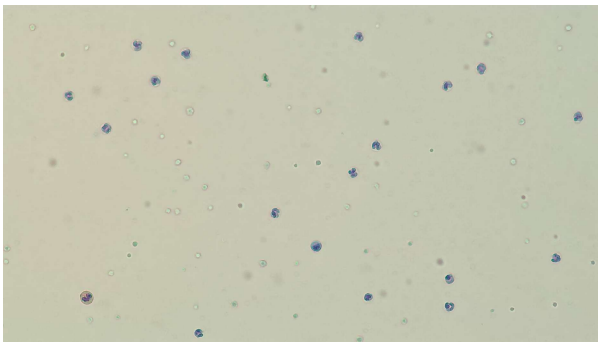

Red Blood Cell & Platelet Distribution Image (RBC&PLT)

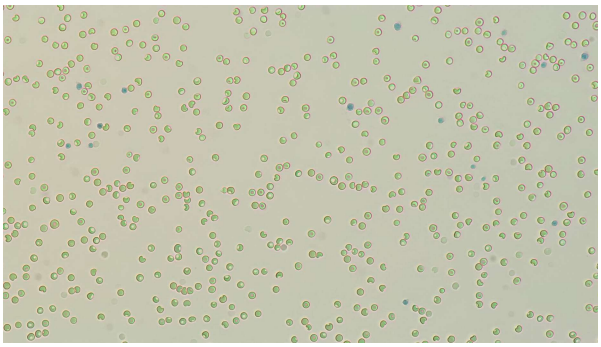

WBC Histogram

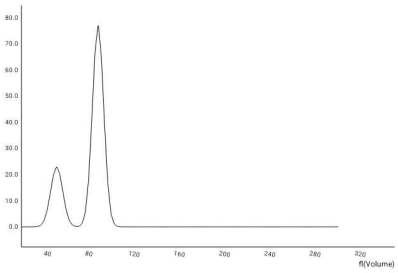

RBC Histogram

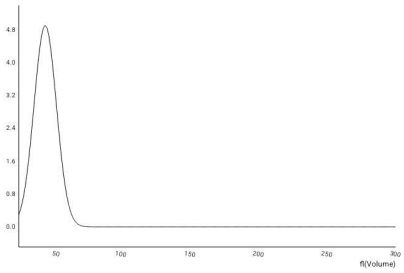

Platelet Histogram

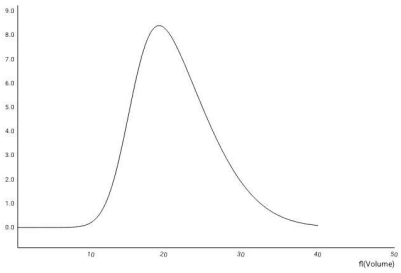

This test result is valid for this sample and is only used as a diagnostic reference for clinicians.

PHÒNG KHÁM THÚ Y SUNVET

Test Report of Hematological Morphological Analysis

Pet Name: Map **Case No.:** 2601260003 **Test Time:** 2026-01-26 11:20

NST

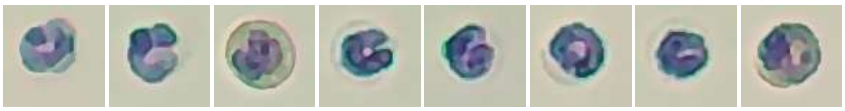

Number: 8 sheets/143 images/754 images | Concentration: 0.07 10^9/L

NSG

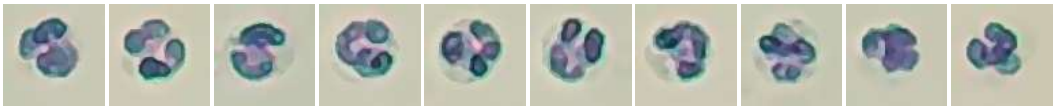

Number: 1238 sheets/143 images/754 images | Concentration: 11.29 10^9/L

NSH

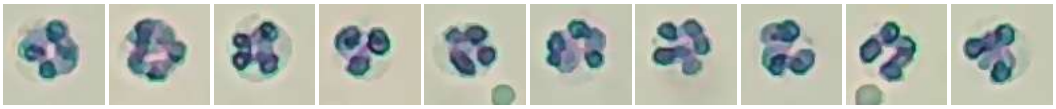

Number: 28 sheets/143 images/754 images | Concentration: 0.22 10^9/L

LYM

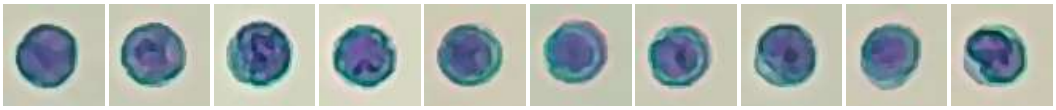

Number: 173 sheets/143 images/754 images | Concentration: 1.62 10^9/L

MON

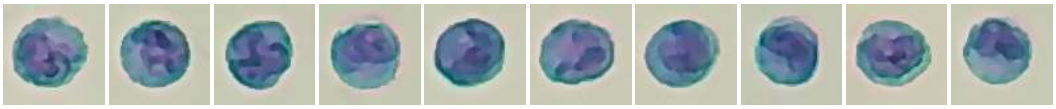

Number: 48 sheets/143 images/754 images | Concentration: 0.5 10^9/L

EOS

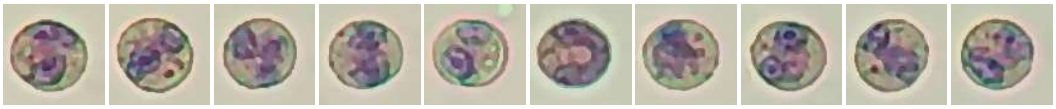

Number: 135 sheets/143 images/754 images | Concentration: 1.34 10^9/L

This test result is valid for this sample and is only used as a diagnostic reference for clinicians.

PHÒNG KHÁM THÚ Y SUNVET

Test Report of Hematological Morphological Analysis

Pet Name: Map **Case No.:** 2601260003 **Test Time:** 2026-01-26 11:20

RET

Number: 69 sheets/143 images/754 images | Concentration: 6.24 10^9/L

ETG

Number: 855 sheets/143 images/754 images | Concentration: 0.27 10^12/L

SPH



Number: 590 sheets/143 images/754 images | Concentration: 190.69 10^9/L

P-LCC

Number: 813 sheets/575 images/754 images | Concentration: 12.32 10^9/L

Clinical Significance

Individual Diagnosis

I. [WBC]

1. [NEU#>10.29] It is common in cases of bacterial infections, poisoning, post-operation, stress, acute inflammation, chronic inflammatory bleeding/hemolysis, etc.

II. [RBC]

1. [RBC<6.54] It is common in cases of infections, acute/chronic hemorrhagic anemia, hemolytic anemia, deficiency anemia, aplastic anemia, etc.
2. [HCT<30.3] It is common in cases of anemia or bleeding from various causes.
3. [MCHC>358] Such increase is common in cases of immune-mediated anemia and hemolysis
4. [ETG%>0.25] It is indicated that RBC hemolysis is present, commonly seen in immune-mediated hemolytic diseases, intravascular hemolytic lesions, etc.
5. [SPH%>2.71] It is common in cases of various hemolytic diseases, including autoimmune hemolytic anemia,

This test result is valid for this sample and is only used as a diagnostic reference for clinicians.

Clinical Significance

neonatal hemolytic anemia, and may also be seen in splenomegaly, hypophosphatemia, zinc poisoning, etc.

Combined Diagnosis

1. [HCT<30.3RET#<50] It indicates a non-regenerative anemia