[Downloaded free from http://www.kjophthal.com on Thursday, June 13, 2019, IP: 139.167.31.161]

Photo Essay

Focal choroidal excavation on spectral domain-optical coherence tomography

ABSTRACT

We report the imaging characteristics of focal choroidal excavation (FCE) and associated choroidal neovascular membrane (CNVM) and interpret the probable etiopathogenesis of FCE through findings detected by multimodal imaging. FCE was found as an acquired entity in our case subsequent to the treatment of CNVM. In addition, the association of FCE with pachychoroid spectrum is reaffirmed through this case.

Keywords: Antivascular endothelial growth factor, choroidal neovascular membrane, focal choroidal excavation, pachychoroid, spectral domain-optical coherence tomography

INTRODUCTION

Focal choroidal excavation (FCE) is a concavity in the choroid of unknown etiology, occurring without any adjacent scleral abnormality or ectasia, and characterized by good visual acuity and shows minimal changes over time. It was first described with time-domain optical coherence tomography (OCT) by Jampol *et al*. in 2006.[1] In 2011, Margolis *et al*. named this entity "focal choroidal excavation" in a report of 12 patients including one with bilateral involvement.[2]

FCE is believed by most authors to be a congenital condition, though its etiopathogenesis is yet unclear. FCE is detected primarily as an OCT finding. FCE is frequently associated with pachychoroid diseases, including central serous chorioretinopathy (CSCR), choroidal neovascularization (CNV), and polypoidal choroidal vasculopathy. Although FCE is classically thought to be congenital, acquired FCE forms possibly exist.[3]

To the best of our knowledge, the only known report of acquired FCE is by Lee *et al*., where they found that, in only 1 out of 38 cases, a small choroidal excavation developed during CNV scarring changes in age-related macular degeneration during a 45-month long-term follow-up.[3]

Hereby, we report multimodal imaging of a case of acquired FCE post treatment of CNV membrane (CNVM), which later increased in size over follow-up period after treatment of CNVM.

METHODS

This is an observational case study. Complete medical records of this case showing CNVM with FCE were reviewed. Multimodal imaging findings including color photography, fluorescein angiography (FA), spectral-domain OCT (SD-OCT), enhanced depth imaging (EDI), and OCT angiography (OCTA) were performed with the Heidelberg Retinal Angiography and Optical Coherence Tomography System (Spectralis, HRA-OCT; Heidelberg Engineering, Heidelberg, Germany) and were analyzed. Measurements of the various dimensions of the FCEs were performed using the caliper feature on the macular line scan of SD-OCT. The greatest linear dimension

Anubhav Goyal, Anatharaman Giridhar, Mahesh Gopalakrishnan

Department of Vitreo-Retina, Giridhar Eye Institute, Kochi, Kerala, India

Address for correspondence: Dr. Anubhav Goyal, Department of Vitreo-Retina, Giridhar Eye Institute, Ponneth Temple Road, Kadavanthra, Kochi - 682 020, Kerala, India. E-mail: dranubhavgoyal@gmail.com

Access this article online	
Website: www.kjophthal.com	Quick Response Code
DOI: 10.4103/kjo.kjo_23_19	

This is an open access journal, and articles are distributed under the terms of the Creative Commons Attribution-NonCommercial-ShareAlike 4.0 License, which allows others to remix, tweak, and build upon the work non-commercially, as long as appropriate credit is given and the new creations are licensed under the identical terms.

For reprints contact: reprints@medknow.com

How to cite this article: Goyal A, Giridhar A, Gopalakrishnan M. Focal choroidal excavation on spectral domain-optical coherence tomography. Kerala J Ophthalmol 2019;31:60-3.

[Downloaded free from http://www.kjophthal.com on Thursday, June 13, 2019, IP: 139.167.31.161]

of the FCE was measured as the maximal vertical distance measured from a horizontal line drawn between the two points, from the retinal pigment epithelium (RPE) horizontally to its lower bulge inferiorly, using a cross-sectional line scan directly across the FCE. The choroidal thickness under the excavation was defined as the distance between the outer border of the RPE and the inner scleral border, using the EDI mode of SD-OCT. Morphologically, FCEs could be classified on the basis of the relationship between the outer retina and the choroid. In the conforming type, the outer retina conforms to the choroidal excavation with preservation of the junction between the photoreceptor tips and the RPE. The nonconforming type corresponds to FCEs with a separation between the photoreceptor tips and RPE, forming a subretinal space.[4]

CASE

A 48-year-old female presented to us with blurring and distortion of vision in the oculus sinister (OS) for 2 weeks. Her best-corrected visual acuity was 6/6; N6 in the oculus dexter (OD) and 6/24 N10 in the OS at presentation. Fundus examination showed subretinal hemorrhage with a grayish lesion suggestive of an extrafoveal CNVM. Based on multimodal imaging such as SD-OCT and fundus FA, the patient was diagnosed to have extrafoveal type 2 CNVM with subfoveal choroidal thickness of 505 µm. She was also treated with anti-vascular endothelial growth factor (VEGF) monotherapy on pro re nata (PRN) basis and had multiple recurrences over a period of 5 years with preservation of the fovea and restoration of final visual acuity to 6/7.5; N6 in the treated eye. Interestingly, she developed FCE at the site of resolved CNVM scar, during 23 months of treatment, which progressively increased from 85 to 154 µm in depth over the subsequent follow-ups. Hereby, we report this as a case of acquired FCE secondary to CNVM. This case also documents the conversion of nonconforming type into conforming type of FCE over the follow-up period.

Color fundus photography

Figure 1 shows irregular RPE defects in the area of FCE. Associated CNVM lesion showed an initial grayish lesion with circumferential subretinal hemorrhage juxtafoveally, which resolved after anti-VEGF treatment during the follow-up period [Figure 1].

Fundus autofluorescence

Fundus autofluorescence showed hypofluorescence in the area of FCE [Figure 1].

Fluorescein angiography

FA showed irregular hyperfluorescence at the area of FCE suggestive of window defects till late phase. Leak was seen only in cases associated with CNVM [Figure 1].

Spectral-domain-optical coherence tomography

FCE is usually seen as choroidal thinning with, cone-shaped or broad irregular excavation of choroid at the level of RPE,

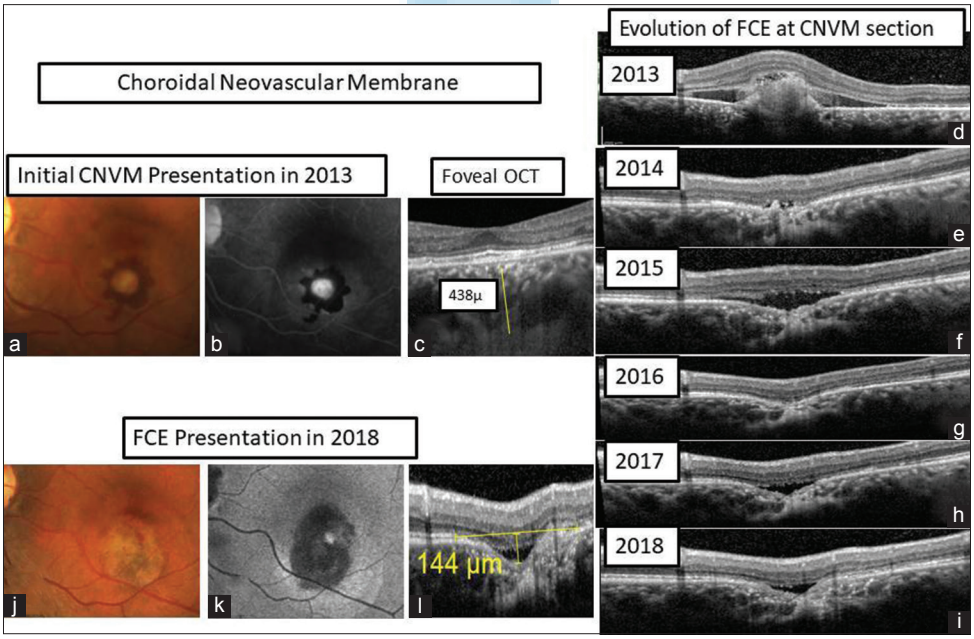

Figure 1: (a) Colour fundus photograph showing greyish membrane surrounded by hemorrhage. (b) Fundus fluorescein angiography showing hyperfluorescence. (c) SD-OCT of foveal section showing pachychoroid, (d) SD-OCT at presentation showing active CNVM features of sub-retinal fluid and hyper-reflectivity without FCE. (e-i) Serial SD-OCT images showing evolution of acquired FCE during treatment course. (j) colour fundus photo showing yellowish-grey colour in area of FCE, (k) fundus autofluorescence showing hypofluorescence surrounded by hyperfluorescence in the area of FCE, (l) SDOCT showing manual maximum vertical measurement of FCE at final follow-up visit

[Downloaded free from http://www.kjophthal.com on Thursday, June 13, 2019, IP: 139.167.31.161]

either in or outside the macula with near-normal overlying retinal architecture [Figure 1].

Optical coherence tomography angiography

OCTA showed a network with flow signals at the site of active CNVM which resolves after treatment with anti-VEGF. OCTA taken at the level of FCE showed dark flow signal absent area surrounded by hyperperfused areas in the default choriocapillaris slab of OCTA, and a hyporeflective plaque in the corresponding en-face structural OCT. B-scan OCT beneath the FCE showed hyperreflective tissue with intensive flow signals in the choroid segment of OCTA and a hyperreflective plaque in the corresponding en-face structural OCT [Figure 2].

DISCUSSION

Several authors have postulated that FCE lesions are congenital choroidal abnormalities related to developmental defects or some other type of focal structural defect within the choroid.[1,3,5,6]

Ellabban *et al*. suggested,[5] the OCT finding of focal loss of choroidal vessels in the area of FCE and an "unusual hyper-reflective tissue" beneath the FCE lesion could suggest that mechanical changes in the RPE/Bruch membrane in the FCE or scarring of choroidal connective tissue resulting from previous inflammation or ischemia. Presumably, scar contraction could draw the choroid and RPE toward the sclera producing FCE. Our cases support the above alternative etiopathogenesis leading to an acquired subtype of FCE, apart from the known congenital form of FCE complicated secondarily by CNVM/CSCR.

FCE can be classified into two types: conforming and nonconforming. Factors contributing to the formation of FCEs into conforming or nonconforming morphologies are uncertain. Initially, the elasticity of the retina allowed the photoreceptors to remain attached to the RPE. With time, eyes with conforming FCE progressed to nonconforming lesions as stress on the outer retina resulted in separation of the photoreceptor tips from the apical surface of the RPE, so nonconforming type seemed to be more advanced than the conforming type.[4] In our case, after successful treatment of CNVM, conforming-type FCE converted to nonconforming-type FCE over the follow-up period.

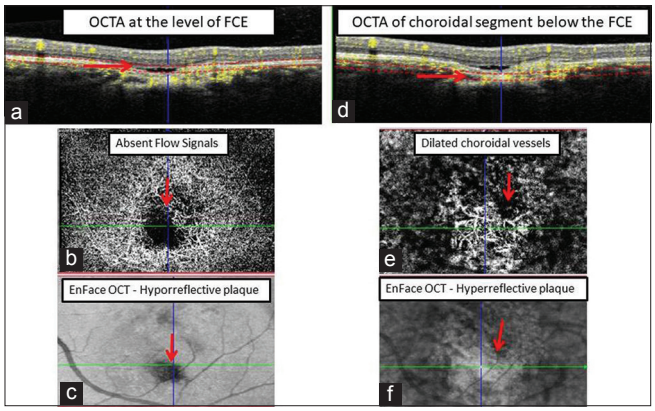

Figure 2: (a) OCTA section through FCE (b) shows absent flow signals in area of FCE, (c) hyporeflective plaque on en-face OCT, (d) shows hyperreflective flow signals in choroid below FCE, (e) dilated choroidal vessels in choroid beneath FCE, (f) hyperreflective plaque on en-face OCT

The occurrence of FCE in eyes with increased choroidal thickness has been noted by several investigators.[2,7] Our case also had increased choroidal thickness with pachyvessel/s adjacent to the excavation, reaffirming the fact that FCE is associated with the pachychoroid spectrum.

CONCLUSION

FCE is an OCT-based diagnosis. FCE is known to be associated with pachychoroid spectrum of diseases, with known associations being CSCR and CNVM. The origin of FCE can be of two types: congenital and acquired. The significance of the acquired variety remains unknown until more such cases are reported. Periodic monitoring of such cases is of importance to detect and treat any of the known associations. Against the common understanding of FCE being a stable lesion, we reported multimodal imaging of a case of acquired FCE post treatment of CNVM, which later increased in size over a follow-up period of 5 years after treatment of CNVM.

Declaration of patient consent

The authors certify that they have obtained all appropriate patient consent forms. In the form the patient(s) has/have given his/her/their consent for his/her/their images and other clinical information to be reported in the journal. The patients understand that their names and initials will not be published and due efforts will be made to conceal their identity, but anonymity cannot be guaranteed.

Financial support and sponsorship

Nil.

Conflicts of interest

There are no conflicts of interest.

REFERENCES

1. Jampol LM, Shankle J, Schroeder R, Tornambe P, Spaide RF, Hee MR, *et al*. Diagnostic and therapeutic challenges. Retina 2006;26:1072-6.

[Downloaded free from http://www.kjophthal.com on Thursday, June 13, 2019, IP: 139.167.31.161]

2. Margolis R, Mukkamala SK, Jampol LM, Spaide RF, Ober MD, Sorenson JA, *et al.* The expanded spectrum of focal choroidal excavation. Arch Ophthalmol 2011;129:1320-5.
3. Lee CS, Woo SJ, Kim YK, Hwang DJ, Kang HM, Kim H, *et al.* Clinical and spectral-domain optical coherence tomography findings in patients with focal choroidal excavation. Ophthalmology 2014;121:1029-35.
4. Wakabayashi Y, Nishimura A, Higashide T, Ijiri S, Sugiyama K. Unilateral choroidal excavation in the macula detected by spectral-domain optical coherence tomography. Acta Ophthalmol 2010;88:e87-91.
5. Ellabban AA, Tsujikawa A, Ooto S, Yamashiro K, Oishi A, Nakata I, *et al.* Focal choroidal excavation in eyes with central serous chorioretinopathy. Am J Ophthalmol 2013;156:673-83.
6. Shinojima A, Kawamura A, Mori R, Yuzawa M. Morphologic features of focal choroidal excavation on spectral domain optical coherence tomography with simultaneous angiography. Retina 2014;34:1407-14.
7. Chung H, Byeon SH, Freund KB. Focal choroidal excavation and its association with pachychoroid spectrum disorders: A review of the literature and multimodal imaging findings. Retina 2017;37:199-221.