[Downloaded free from http://www.kjophthal.com on Thursday, June 13, 2019, IP: 139.167.31.161]

Original Article

Half-fluence photodynamic therapy in chronic central serous chorioretinopathy

ABSTRACT

Purpose: The aim of this study is to investigate the effect of half-fluence photodynamic therapy (PDT) in chronic central serous chorioretinopathy (CSC).

Materials and Methods: Forty-two eyes of 34 patients with chronic CSC and symptoms for at least 6 months were retrospectively reviewed. All eyes were treated with indocyanine green (ICG)-guided half-fluence PDT. The primary outcome measure was the proportion of eyes with complete resolution of subretinal fluid (SRF) on spectral domain-optical coherence tomography (SD-OCT). The secondary outcome measure was change in best corrected visual acuity (BCVA). SPSS v. 16 software was used for statistical analysis.

Results: The mean follow-up period was 12.5 ± 4.3 months. Twenty six (78.78%) eyes showed complete resolution of SRF ($P < 0.01$). BCVA increased by a mean of 0.43 to 0.42 log MAR ($P < 0.31$) at 12-month follow-up. Serous macular detachment height reduced from a mean of 166 μ to 40 μ ($P < 0.01$), and BCVA improvement of 1 line was seen in 16 eyes at 12 month follow-up visit. Ellipsoid line improvement was seen in 12 (36.36%) eyes compared to 5 (15.15%) eyes at the baseline visit ($P = 0.01$). Eyes with SD-OCT features of idiopathic serous-pigment epithelial detachment showed improvement of 0.12 logMAR in BCVA, as compared to irregular retinal pigment epithelium (0.01 logMAR) in 12 months duration.

Conclusion: Half-fluence PDT is an effective and safe method in the treatment of chronic CSC with stabilization or improvement of anatomical and functional outcomes.

Keywords: Best corrected visual acuity, chronic central serous retinopathy, half fluence photodynamic therapy, idiopathic serous pigment epithelial detachment, indocyanine green angiograpy, spectral domain optical coherence tomography

INTRODUCTION

Central serous chorioretinopathy (CSC) is characterized by neurosensory retinal detachment caused by accumulation of serous fluid between photoreceptor outer segments and retinal pigment epithelium (RPE) in combination with pathological changes in RPE.[1] The disease often resolves spontaneously, however occasionally, the neurosensory detachment persists and leads to damage to the RPE and photoreceptors, along with visual impairment.[2] Chronic central serous chorioretinopathy (cCSC) is defined as persistence of this pathology for more than 6 months. The characteristic diffuse or multifocal leakage through the RPE on fluorescein angiography (FA) caused by defective or decompensated RPE was deemed responsible for detachment of the neurosensory retina.[3] Unlike acute CSC, chronic CSC may lead to further complications, such as diffuse RPE decompensation,[4] subretinal precipitates,[5] descending atrophic tracts,[6] cystoid macular degeneration,[7] secondary choroidal neovascularization (CNV),[8] and fibrous scarring,[2] which leads to poor visual prognosis. The increased use

Anubhav Goyal, Ananthraman Giridhar, Mahesh Gopalakrishnan

Department of Vitreo-Retina, Giridhar Eye Institute, Ponneth Temple Road, Kadavanthara, Kochi, Kerala, India

Address for correspondence: Dr. Anubhav Goyal, Department of Vitreo-Retina, Giridhar Eye Institute, Ponneth Temple Road, Kadavanthra, Kochi - 682 020, Kerala, India. E-mail: dranubhavgoyal@gmail.com

Access this article online	
Website: www.kjophthal.com	Quick Response Code
DOI: 10.4103/kjo.kjo_6_17	

This is an open access article distributed under the terms of the Creative Commons Attribution-NonCommercial-ShareAlike 3.0 License, which allows others to remix, tweak, and build upon the work non-commercially, as long as the author is credited and the new creations are licensed under the identical terms.

For reprints contact: reprints@medknow.com

How to cite this article: Goyal A, Giridhar A, Gopalakrishnan M. Half-fluence photodynamic therapy in chronic central serous chorioretinopathy. Kerala J Ophthalmol 2016;28:125-30.

[Downloaded free from http://www.kjophthal.com on Thursday, June 13, 2019, IP: 139.167.31.161]

of indocyanine green angiography (ICGA) in chronic CSC had demonstrated that, in addition to RPE degeneration, choroidal circulation is primarily affected resulting in choroidal vascular hyperfluorescence.[9]

Various treatment modalities such as observation, medical therapy,[9,10] laser photocoagulation,[11,12] intravitreal bevacizumab injection,[13-15] and photodynamic therapy[16,17] have been attempted for the treatment of cCSC. Although bevacizumab improves the symptoms of cCSC through direct inhibition of vascular endothelial growth factor, a representative promoter of vascular permeability, due to high recurrence of cCSC, repeated injections are reported.[13]

PDT for the treatment of cCSC has been reported to be efficacious in improving visual acuity, reducing subretinal fluid (SRF), and decreasing recurrence rate in most patients by reducing choroidal exudation and inducing choriocapillary remodeling.[16,17] In long standing cCSC with foveal atrophy, modified PDT protocols, in terms of verteporfin dosage, fluence rate, the time course of delivery, or a combination thereof, may be more appropriate. We recently observed functional improvement without significant retinal or choroidal damage by reducing the fluence rate of PDT. In the present study, we investigated the efficacy and the rate of side effects of PDT therapy with a half-fluence rate for the treatment of cCSC.[18-20]

MATERIALS AND METHODS

We prospectively studied 33 eyes of 28 patients with symptomatic cCSC for at least 6 months. Patients studied between March 2010 and December 2014 were included in the study. Some of the inclusion criteria were (1) persistent symptoms for at least 6 months; (2) presence of SRF in the foveal region with or without pigment epithelial detachment (PED) on optical coherence tomography (OCT); (3) Presence of angiographic leakage on FA; (4) Abnormal dilated choroidal vasculature and choroidal vascular hyperpermeability or hypopermeability with an area of active leakage on ICGA corresponding to the leaking area on fundus fluorescein angiography (FFA). Patients who received any previous treatment, including PDT or focal thermal laser photocoagulation for CSC, or who had FA or ICGA findings of CNV, polyploidal choroidal vasculopathy (PCV), or other maculopathy on clinical examination were excluded. All patients were evaluated by one retina specialist. Diagnosis of CSC was based on clinical findings and ancillary tests such as ICGA, FFA, and spectral domain optical coherence tomography (SD-OCT). Distance visual acuity was assessed using the Snellens chart which was later converted to LogMAR by conversion tables. Macular SD-OCT, ICGA, and FFA (Heidelberg Engineering, Heidelberg, Germany) were performed in all patients prior to the treatment. Treatment with PDT was initiated once a complete ophthalmic assessment was done. The spot size of treatment was measured by comparing both ICGA and FFA images. The delivered laser energy, which was used during treatment sessions, was half of the standard dose (half-fluence PDT), i.e., 25 mJ/cm^2 over 83 s. Intravenous verteporfin was given at a dose of 6 mg/m^2 over 10 min, as recommended by the FDA. All patients were admitted to the hospital for the treatment and instructed to avoid sun exposure for 3 days posttreatment. Chart review of electronic medical records for these patients was done to collect appropriate data. Follow-up visits were at months 1, 3, 6, and 12 post treatment. OCT was done for all patients in all follow-up visits. The primary outcome measure was the proportion of eyes with complete resolution of SRF on SD-OCT. Secondary outcome measures were the changes in best corrected visual acuity (BCVA) and serous macular detachment (SMD) height, and the proportion of eyes that showed an increase of 1 line improvement in BCVA at the last visit. FFA and ICG were not done posttreatment because they showed improvement clinically and by OCT in all follow-up visits. Statistical analysis was performed using SPSS version 16.0 (SPSS, Inc., Chicago, IL, USA). P value ≤ 0.05 was considered statistically significant.

RESULTS

We retrospectively analyzed 33 eyes of 28 patients diagnosed to have cCSC on ICGA and FFA. The mean follow-up period

Table 1: Baseline Patient Demographics and Clinical Characteristics

Age (years)	
Mean	48
Range	38-69
Sex, *n* (%)	
Male	27 (81.8%)
Female	6 (18.18%)
Laterality (patients)	
Bilateral	5
Unilateral	23
ICGA pattern, *n* (%)	
Diffuse hyperflorescence	27 (81.81%)
Discrete hypoflorescence	6 (18.18%)
FFA pattern, *n* (%)	
Diffuse hyperfluorescence	20 (60.6%)
Multiple leak hyperfluorescence	13 (39.39%)
RPE pattern on SD-OCT, *n* (%)	
Irregular RPE	24 (72.72%)
Idiopathic serous PED (IS-PED)	9 (27.27%)
BCVA (logMAR)	
Mean±SD	0.43±0.39
SRF height (microns)	
Mean±SD	166.42±52.02

[Downloaded free from http://www.kjophthal.com on Thursday, June 13, 2019, IP: 139.167.31.161]

Table 2: Frequency distribution of changes in BCVA and SRF height in 12 months followup

	Baseline	1 month	3 month	6 month	12 month	*P*
BCVA (logMAR)	0.43	0.43	0.40	0.38	0.39	0.31
SRF height (μm)	166.42	24.55	21.21	23.94	17.42	<0.001

*Wilcoxon signed rank test

Table 3:-Change in parameters in 12 months duration

Complete resolution of subretinal fluid on SD-OCT, *n* (%)	26 (78.78%)
BCVA change from baseline, *n*(%)	
Improvement >0.2 logMAR	13 (39.39%)
Improvement <0.2 logMAR	11 (33.33%)
Worsening	9 (27.27%)

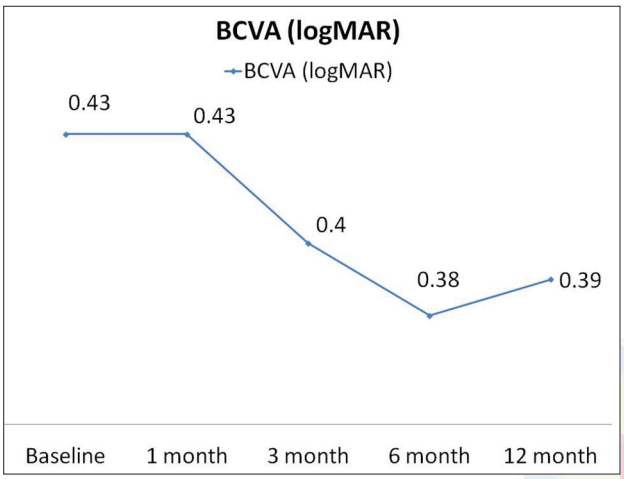

Figure 1: Change in best corrected visual acuity (logMAR) over 12 months duration

was 12.5 ± 4.3 months. Follow-up was done based on change on SD-OCT. Five (17.85%) patients had bilateral involvement. We treated all eyes with half fluence PDT.

Baseline demographics and clinical characteristics are shown in Table 1. BCVA improved from pretreatment a mean visual acuity of 0.43 to 0.39 log MAR ($P = 0.31$) at the final follow-up visit was not statistically significant [Table 2 and Figure 1]. Statistically significant complete resolution of SRF on SD-OCT was seen in 26 (78.78%) eyes ($P < 0.01$) at final follow-up visit and BCVA improvement of ≥1 line was seen in 16 eyes at 12-month follow-up visit. Worsening of BCVA was seen in 9 (27.27%) eyes at the final follow-up visit [Table 3].

SRF height showed statistically significant reduction in height from the pretreatment mean of 166 μ to 40 μ ($P < 0.01$) at the final follow-up visit [Figure 2 and Table 2]. Twenty-six (78.78%) eyes showed complete resolution of fluid at final follow-up visit. These eyes showed a complete resolution of the cCSC within 1 month of therapy, whereas mean BCVA improvement was delayed by more than 1 month of therapy.

At the site of the macular detachment, ellipsoid line on SD-OCT was preserved in only 5 eyes at the baseline visit. Restoration of ellipsoid line at the site previous macular detachment was seen in 7 out of remaining 28 eyes at final follow-up visit. Indiscriminate presence of SRF and posterior retinal cystoid degenerations were present in 6 (18.18%) eyes at the final follow-up visit. Recurrence of cCSC was seen in 1 eye after 24 months of follow-up. No other adverse event was in our study.

DISCUSSION

CSC is a common acquired maculopathy. Acute CSC usually resolves spontaneously with very good visual acuity.[21] However, cCSC may need treatment since vision can be permanently affected.[22]

Initially, Maumenee[23] in 1965 described a leak at the level of RPE and subsequently Gass[24] provided detailed description of the FA findings of the disease. Guyer *et al*.[8] suggested choroidal vascular hyperpermeability on ICGA with or without associated RPE active leaks, and that the neurosensory retina is only secondarily affected.

Laser photocoagulation was used for decades before the era of PDT. However, laser photocoagulation may not accelerate resolution and does not reduce the recurrence rate. In addition, it can be used only in acute CSR leak and may result in permanent visual defects.[11,12,26]

Recently, half fluence PDT with vertiporfin has been used widely for the treatment of cCSC, and studies have demonstrated beneficial outcomes in most patients.[20,25,28-34] Regarding the mechanism of PDT treatment for cCSC, it is hypothesized that PDT induces selective and transient occlusion of choriocapillaries, which is the main source of exudation.[30] Still, true pathophysiology of cCSC is not completely understood.[31]

To improve PDT safety, we found that half fluence PDT is a safe and effective treatment alternative for patients with cCSC, as anatomical success of half-fluence PDT is 79–91% with minimal side effects or catastrophic visual loss.[33] In our study, 78.78% of the eyes showed significantly complete resolution of SRF at 1 month follow-up after the treatment, which is comparative to other studies which showed

[Downloaded free from http://www.kjophthal.com on Thursday, June 13, 2019, IP: 139.167.31.161]

80%[28,30,32] to 100%[20,27,31,33,34] results of complete resolution of SRF.

ICGA for cCSC showed disturbance of choroidal perfusion and suggested that choroidal hyperpermeability might be the origin of cCSC.[22] Yannuzzi *et al*.[35] introduced ICGA-guided PDT as the TAP study on areas of visible hyperpermeability on ICGA. Most studies documented complete resolution of SRF inintense hyperfluorescence as compared to weak hyperfluorescence group,[20,30-32] however, none had documented presence of hypofluorescence on ICGA. On the contrary, we found 2 patterns of ICGA—diffuse hyperfluorescence in 81.81% [Figure 3] and discrete hypofluorescence in 18.18% cases [Figure 4]. Both diffuse hyperfluorescence and discrete hypofluorescence groups had shown nearly the same percentage (77% and 83%, respectively) of complete resolution of SRF at the last follow-up visit, which is contrary to other studies which showed better results in the intense hyperfluorescence group.[20,32]

Reibaldi *et al*.[31] studied standard fluence versus low-fluence PDT and showed significant comparative improvement in BCVA of 0.19 and 0.3, respectively, in these groups. Lim *et al*.[20] showed BCVA improvement of 0.21 on half-fluence PDT. In the study done by Nicolo *et al*.[32] on half dose PDT and Rosenthal *et al*.[31] on comparison between half-dose vs. half-fluence PDT, there was no significant change in final BCVA. Thus, from these studies we conclude that improvement in BCVA is better in half-dose or half-fluence PDT compared to that with standard-dose treatment, which can be attributed to more severe choriocapillary hypoperfusion, choroidal neovascularization, and foveal atrophy due to standard-fluence PDT.[25] In our study also, though there was no significant change of 0.04 in BCVA at the 12-month follow-up visit, yet stabilization or worsening was seen in 9 (27.27%) eyes only, which can be attributed to prolonged duration of CSC of more than 2 years which might result in permanent damage to photoreceptors, and hence, permanent visual loss.[25]

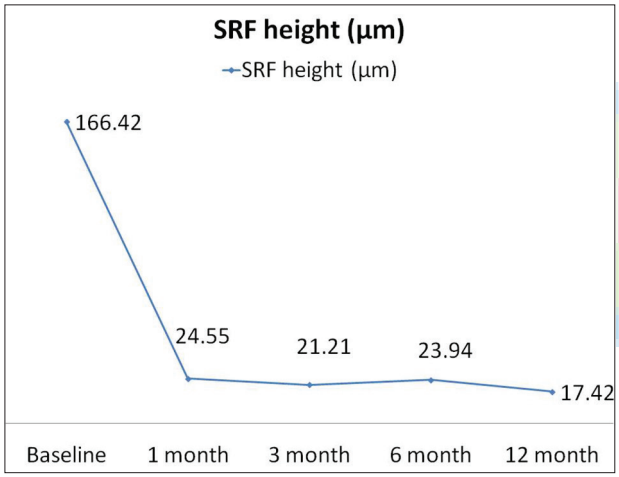

Figure 2: Change in subretinal fluid height (µm) over 12 months duration

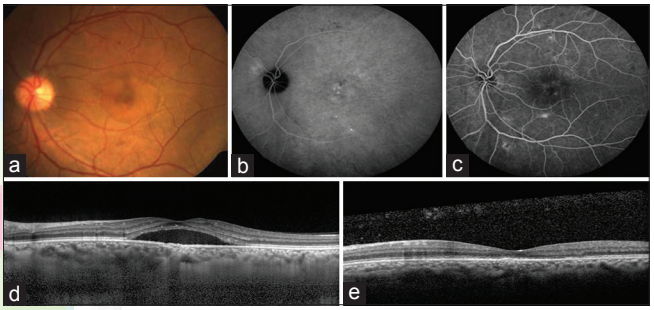

Figure 3: Case of chronic CSR before and after half-fluence PDT – (a) Clinical picture with coin shaped hypopigmented lesion in macula, (b) ICGA with central macular diffuse hyperfluorescence, (c) FFA with diffuse hyperfluorescence in area corresponding to ICGA, (d) SD-OCT showing subretinal fluid before half fluence PDT, (e) SD-OCT after 12 months of half fluence PDT showing complete resolution of SRF with persisting loss of ellipsoid line in macula

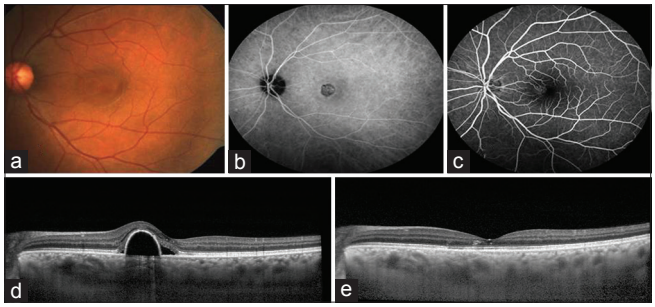

Figure 4: Case of chronic CSC showing (a) clinical picture with circular hypopigmented lesion in macula, (b) ICGA with area discrete hypofluorescence in macula, (c) FFA with area of diffuse hyperfluorescence corresponding to ICG hypofluorescent area, (d) SD-OCT before half fluence PDT with large idiopathic serous pigment epithelial detachment (IS-PED) in area corresponding to hypofluorescent area on ICGA with presence of SRF, (e) SD-OCT after 12 months of half fluence PDT showing complete resolution of IS-PED with restoration of ellipsoid line

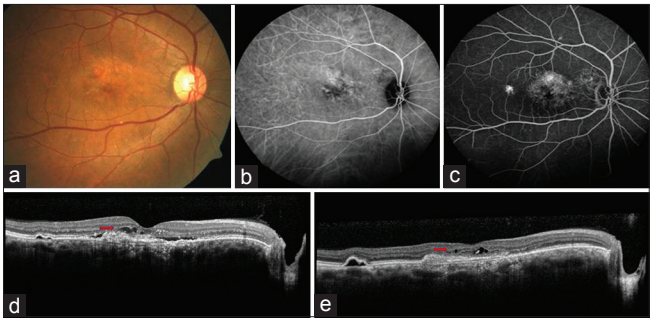

Figure 5: Case of chronic CSC showing (a) Clinical picture with orange color lesion superior to fovea, (b) ICGA showing diffuse hyperfluorescence superior to fovea, (c) FFA with diffuse hyperfluorescence corresponding to ICGA lesion, (d) SD-OCT before half-fluence PDT with posterior cystoid retinal degeneration (arrow), subretinal fluid, long standing RPE decompensation in fovea and IS-PED in temporal macula, (e) after half fluence PDT with persisting posterior cystoid retinal degeneration (arrow), RPE defect and IS-PED, though SRF is completely resolved

[Downloaded free from http://www.kjophthal.com on Thursday, June 13, 2019, IP: 139.167.31.161]

Out of 6 eyes with posterior cystoid retinal degeneration [Figure 5], only 3 showed dry macula at 12-month follow-up. All eyes with posterior cystoid retinal degeneration were seen to have diffuse hyperfluorescence on ICGA. Nicolo *et al*.[32] suggested that posterior cystoid retinal degeneration originates from chorioretinal adherent lesions derived from long-standing RPE decompensation as well as choroidal hyperpermeability. We observed 1 recurrence in diffuse hyperfluorescence group, which was also commonly seen in other studies.[20]

In our study, we did not find any complication such as CNVM, which is known to be a rare complication secondary to cCSC,[30] and also reported after standard PDT related to secondary hypoxic damage and RPE changes.[36-38] The main limitation of our study is its retrospective nature, small follow-up, lack of randomization, and lack of comparative study design, which might have led to overestimating or underestimating the outcome of the treatment. Therefore, further investigation is needed to determine whether there could be difference in treatment outcomes, complications, and recurrence rates in long-term follow-up after half fluence PDT according to the degree of varied choroidal florescence on ICGA.

CONCLUSION

In conclusion, resolution of SRF might be expected in eyes with cCSC, regardless of the intensity of choroidal florescence after half fluence PDT. Half-fluence PDT is an effective and safe method in the treatment of cCSC with stabilization or improvement of anatomical and functional outcomes. We should, however, be aware of persistence or recurrence of disease in eyes with posterior cystoid retinal degeneration.

Financial support and sponsorship

Nil.

Conflicts of interest

There are no conflicts of interest.

REFERENCES

1. Wang M, Munch IC, Hasler PW, Prünte C, Larsen M. Central serous chorioretinopathy. Acta Ophthalmol 2008;86:126-45.
2. Ober MD, Yannuzzi LA, Do DV, Spaide RF, Bressler NM, Jampol LM, *et al*. Photodynamic therapy for focal retinal pigment epithelial leaks secondary to central serous chorioretinopathy. Ophthalmology 2005;112:2088-94.
3. Spitznas M. Pathogenesis of central serous retinopathy: A new working hypothesis. Graefes Arch Clin Exp Ophthalmol 1986;224:321-4.
4. Jalkh AE, Jabbour N, Avila MP, Trempe CL, Schepens CL. Retinal pigment epithelium decompensation. I. Clinical features and natural course. Ophthalmology 1984;91:1544-8.
5. Ie D, Yannuzzi LA, Spaide RF, Rabb MF, Blair NP, Daily MJ. Subretinal exudative deposits in central serous chorioretinopathy. Br J Ophthalmol 1993;77:349-53.
6. Yannuzzi LA, Shakin JL, Fisher YL, Altomonte MA. Peripheral retinal detachments and retinal pigment epithelial atrophic tracts secondary to central serous pigment epitheliopathy. Ophthalmology 1984;91:1554-72.
7. Iida T, Yannuzzi LA, Spaide RF, Borodoker N, Carvalho CA, Negrao S. Cystoid macular degeneration in chronic central serous chorioretinopathy. Retina 2003;23:1-7.
8. Guyer DR, Yannuzzi LA, Slakter JS, Sorenson JA, Ho A, Orlock D. Digital indocyanine green videoangiography of central serous chorioretinopathy. Arch Ophthalmol 1994;112:1057-62.
9. Pikkel J, Beiran I, Ophir A, Miller B. Acetazolamide for central serous retinopathy. Ophthalmology 2002;109:1723-5.
10. Fabianovà J, Porubskà M, Cepilovà Z. Central serous chorioretinopathy—treatment with beta blockers [in Slovak]. Cesk Slov Oftalmol 1998;54:401-4.
11. Burumcek E, Mudun A, Karacorlu S, Arslan MO. Laser photocoagulation for persistent central serous retinopathy: Results of long-term follow-up. Ophthalmology 1997;104:616-22.
12. Yannuzzi LA, Slakter JS, Kaufman SR, Gupta K. Laser treatment of diffuse retinal pigment epitheliopathy. Eur J Ophthalmol 1992;2:103-14.
13. Lim SJ, Roh MI, Kwon OW. Intravitreal bevacizumab injection for central serous chorioretinopathy. Retina 2010;30:100-6.
14. Schaal KB, Hoeh AE, Scheuerle A, Schuett F, Dithmar S. Intravitreal bevacizumab for treatment of chronic central serous chorioretinopathy. Eur J Ophthalmol 2009;19:613-7.
15. Huang WC, Chen WL, Tsai YY, Chiang CC, Lin JM. Intravitreal bevacizumab for treatment of chronic central serous chorioretinopathy. Eye 2009;23:488-9.
16. Cardillo Piccolino F, Eandi CM, Ventre L, Rigault de la Longrais RC, Grignolo FM. Photodynamic therapy for chronic central serous chorioretinopathy. Retina 2003;23:752-63.
17. Chan WM, Lam DS, Lai TY, Tam BS, Liu DT, Chan CK. Choroidal vascular remodelling in central serous chorioretinopathy after indocyanine green guided photodynamic therapy with verteporfin: A novel treatment at the primary disease level. Br J Ophthalmol 2003;87:1453-8.
18. Stewart JM. Half dose verteporfin PDT for central serous chorioretinopathy. Br J Ophthalmol 2006;90:805-6.
19. Reibaldi M, Boscia F, Avitabile T, Russo A, Cannemi V, Uva MG, *et al*. Low-fluence photodynamic therapy in long-standing chronic central serous chorioretinopathy with foveal and gravitational atrophy. Eur J Ophthalmol 2009;19:154-8.
20. Lim SH, Chang W, Sagong M. Efficacy of half-fluence phototdynamic therapy depending on the degree of choroidal hyperpermeability in chronic central serous chorioretinopathy. Eye 2013;27:353-62.
21. Marcuson J, Riley T. Central serous chorioretinopathy. Optometry 2008;79:241-51.
22. Otsuka S, Ohba N, Nakao K. A long-term follow-up study of severe variant of central serous chorioretinopathy. Retina 2002;22:25-32.
23. Maumenee AE. Macular diseases: Clinical manifestations. Trans Am Acad Ophthalmol Otolaryngol 1965;69:605-13.
24. Gass JD. Pathogenesis of disciform detachment of the neuroepithelium. Am J Ophthalmol 1967;63(Suppl):1-139.
25. Ahmed S Al-hinai and Al-Abri MS. Half-fluence photodynamic therapy to treat chronic central serous chorioretinopathy: A case series. Oman J Ophthalmol 2011;4:63-6.
26. Verma L, Sinha R, Venkatesh P, Tewari HK. Comparative evaluation of diode laser versus argon laser photocoagulation in patients with central serous retinopathy: A pilot, randomized controlled trial. BMC Ophthalmol 2004;4:15.
27. Ratanasukon M, Thongthong K. Photoreceptor disruption in central serous chorioretinopathy treated by half-dose photodynamic therapy. Clin Ophthalmol 2013;7:87-92.

[Downloaded free from http://www.kjophthal.com on Thursday, June 13, 2019, IP: 139.167.31.161]

28. Lai TY, Chan WM, Li H, Lai RY, Liu DT, Lam DS. Safety enhanced photodynamic therapy with half dose verteporfin for chronic central serous chorioretinopathy: A short term pilot study. Br J Ophthalmol 2006;90:869-74.
29. Karakus SH1, Basarir B, Pinarci EY, Kirandi EU, Demirok A. Long term results of half-dose photodynamic therapy for chronic central serous retinopathy with contrast sensitivity changes. Eye 2013;27:612-20.
30. Reibaldi M, Cardascia N, Longo A, Furino C, Avitabile T, Faro S, *et al*. Standard-fluence versus low-fluence photodynamic therapy in chronic central serous chorioretinopathy: A nonrandomized clinical trial. Am J Ophthalmol 2010;149:307-15.
31. Rosenthal JM, Flaxel CJ. Half-dose and half-fluence photodynamic therapy for central serous chorioretinopathy. J Eye Ophthalmol. 2014;1:2. http://dx.doi.org/10.7243/2055-2408-1-2.
32. Nicolò M, Zoli D, Musolino M, Traverso CE. Association between the efficacy of half-dose photodynamic therapy with indocyanine green angiography and optical coherence tomography findings in the treatment of central serous chorioretinopathy. Am J Ophthalmol 2012;153:474-80.
33. Rouvas A, Stavrakas P, Theodossiadis PG, Stamatiou P, Milia M, Giannakaki E, *et al*. Long-term results of half-fluence photodynamic therapy for chronic central serous chorioretinopathy. Eur J Ophthalmol 2012;22:417-22.
34. Smretschnig E, Ansari-Shahrezaei S, Hagen S, Glittenberg C, Krebs I, Binder S. Half-fluence photodynamic therapy in central serous chorioretinopathy. Retina 2013;33:316-23.
35. Yannuzzi LA, Slakter JS, Gross NE, Spaide RF, Costa DL, Huang SJ, *et al*. Indocyanine green angiography guided photodynamic therapy for treatment of chronic central serous chorioretinopathy: A pilot study. Retina 2003;23:288-98.
36. Colucciello M. Choroidal neovascularization complicating photodynamic therapy for central serous retinopathy. Retina 2006;26:239 –242.
37. Yaman A, Arikan G, Saatci AO, Cingil G. Choroidal neovascularization following photodynamic therapy in a patient with chronic central serous chorioretinopathy. Bull Soc Belge Ophtalmol 2007;303:69-73.
38. Treatment of age-related macular degeneration with photodynamic therapy (TAP) Study Group. Photodynamic therapy of subfoveal choroidal neovascularization in age-related macular degeneration with verteporfin: One-year results of 2 randomized clinical trials–TAP report. Arch Ophthalmol 1999;117:1329-45.