doi:10.1093/brain/aww258 BRAIN 2017: 140; 527–546 | 527

BRAIN
A JOURNAL OF NEUROLOGY

REVIEW ARTICLE

Progressive multiple sclerosis: from pathogenic mechanisms to treatment

Jorge Correale, María I. Gaitán, María C. Ysrraelit and Marcela P. Fiol

During the past decades, better understanding of relapsing-remitting multiple sclerosis disease mechanisms have led to the development of several disease-modifying therapies, reducing relapse rates and severity, through immune system modulation or suppression. In contrast, current therapeutic options for progressive multiple sclerosis remain comparatively disappointing and challenging. One possible explanation is a lack of understanding of pathogenic mechanisms driving progressive multiple sclerosis. Furthermore, diagnosis is usually retrospective, based on history of gradual neurological worsening with or without occasional relapses, minor remissions or plateaus. In addition, imaging methods as well as biomarkers are not well established. Magnetic resonance imaging studies in progressive multiple sclerosis show decreased blood–brain barrier permeability, probably reflecting compartmentalization of inflammation behind a relatively intact blood–brain barrier. Interestingly, a spectrum of inflammatory cell types infiltrates the leptomeninges during subpial cortical demyelination. Indeed, recent magnetic resonance imaging studies show leptomeningeal contrast enhancement in subjects with progressive multiple sclerosis, possibly representing an *in vivo* marker of inflammation associated to subpial demyelination. Treatments for progressive disease depend on underlying mechanisms causing central nervous system damage. Immunity sheltered behind an intact blood–brain barrier, energy failure, and membrane channel dysfunction may be key processes in progressive disease. Interfering with these mechanisms may provide neuroprotection and prevent disability progression, while potentially restoring activity and conduction along damaged axons by repairing myelin. Although most previous clinical trials in progressive multiple sclerosis have yielded disappointing results, important lessons have been learnt, improving the design of novel ones. This review discusses mechanisms involved in progressive multiple sclerosis, correlations between histopathology and magnetic resonance imaging studies, along with possible new therapeutic approaches.

Department of Neurology, Raúl Carrea Institute for Neurological Research (FLENI), Buenos Aires, Argentina

Correspondence to: Jorge Correale,
Raúl Carrea Institute for Neurological Research, FLENI.
Montañeses 2325, Buenos Aires (1428), Argentina
E-mail: jcorreale@fleni.org.ar or jorge.correale@gmail.com

Keywords: multiple sclerosis; primary progressive multiple sclerosis; secondary progressive multiple sclerosis; neurodegeneration; axonal loss

Abbreviations: EAE = experimental autoimmune encephalomyelitis; EBV = Epstein-Barr virus; EDSS = Expanded Disability Status Scale; FLAIR = fluid-attenuated inversion recovery; IFN = interferon; IL = interleukin; MTR = magnetization transfer ratio; NAA = *N*-acetylaspartate; NAWM = normal-appearing white matter; PPMS = primary progressive multiple sclerosis; ROS = reactive oxygen species; RRMS = relapsing remitting multiple sclerosis; SPMS = secondary progressive multiple sclerosis; TNF-α = tumor necrosis factor-α

Introduction

Multiple sclerosis is a chronic inflammatory disease of the CNS leading to demyelination and neurodegeneration. Although its aetiology remains elusive it is now known that environmental factors and susceptible genes are involved in disease pathogenesis. Results from immunological, genetic and histopathology studies of patients with

Received February 16, 2016. Revised August 18, 2016. Accepted August 18, 2016. Advance Access publication October 28, 2016
© The Author (2016). Published by Oxford University Press on behalf of the Guarantors of Brain. All rights reserved.
For Permissions, please email: journals.permissions@oup.com

Downloaded from https://academic.oup.com/brain/article/140/3/527/2447880 by guest on 26 April 2026

multiple sclerosis support the concept that autoimmunity plays a major role in disease pathogenesis (McFarland and Martin, 2007). However, it is also well accepted that multiple sclerosis is not only an inflammatory disease, but also a neurodegenerative condition (Trapp *et al.*, 1998).

The course of multiple sclerosis is highly variable; nevertheless in most patients, multiple sclerosis is characterized by the onset of recurring clinical symptoms followed by total or partial recovery, namely, the classic relapsing-remitting form of multiple sclerosis (RRMS). After 10–15 years of disease, this pattern becomes progressive in up to 50% of untreated patients, during which time clinical symptoms slowly cause progressive deterioration over a period of many years, a disease stage defined as secondary progressive multiple sclerosis (SPMS). In about 15% of patients with multiple sclerosis however, disease progression is relentless from onset [primary progressive multiple sclerosis (PPMS)] (Lublin and Reingold, 1996).

In recent decades, better understanding of mechanisms underlying RRMS has led to development of different disease-modifying therapies, reducing both severity and frequency of new relapses by altering or suppressing the immune system (Cohen and Rudick, 2011). In contrast, therapeutic options available for progressive multiple sclerosis are comparatively disappointing, and remain a challenge. One possible reason behind this is a lack of understanding of pathogenic mechanisms driving progressive multiple sclerosis. Due to the indolent nature of symptom progression, recent disease criteria used to characterize the course of disease (Lublin *et al.*, 2014) indicate diagnosis is usually retrospective and based on history of gradual worsening. Clearly, diagnosis is based on clinical judgement, as there is no fully reliable diagnostic test (Ontaneda *et al.*, 2015). Imaging parameters and biomarkers are not well established, delaying diagnosis of progression and ultimately impacting patient care. This review discusses present knowledge on progressive multiple sclerosis, its pathophysiology, diagnostic challenges arising during progression, correlation between histopathology and MRI, as well as potential neuroprotective therapies that could slow down worsening of disability, or restore signalling along damaged axons through myelin repair.

New concepts in progressive multiple sclerosis pathophysiology

Different theories have been put forward to explain how progressive multiple sclerosis is triggered. One suggests that brain damage is driven by inflammatory processes similar to those observed during RRMS; but that during progressive disease stages, a microenvironment is created within the CNS favouring homing and retention of inflammatory cells, ultimately causing disease-modifying therapies to become largely ineffective (Frischer *et al.*, 2009). A second possibility is that multiple sclerosis starts out as an inflammatory disease, but after several years, a neurodegenerative process independent of inflammatory responses becomes the key mechanism responsible for disease progression (Meuth *et al.*, 2008). Finally, multiple sclerosis could primarily be a neurodegenerative disease, with inflammation occurring as a secondary response, amplifying progressive states (Barnett and Prineas, 2004; Kassmann *et al.*, 2007). Clearly these different mechanisms are not mutually exclusive and could act together.

Immune effector mechanisms

Although brain and spinal cord inflammation are present in RRMS, SPMS, and PPMS its extent declines with age and disease duration. Findings from animal models and immunological studies in patients with multiple sclerosis that peripheral immune responses targeting the CNS drive disease during early phases, whereas immune reactions within the CNS dominate progressive phases. Among potential candidates driving inflammation during progressive multiple sclerosis, the role of B cells appears to be prominent, particularly in the context of meningeal inflammation (Magliozzi *et al.*, 2007). B cell functions that could be of relevance in progressive multiple sclerosis include: antibody production, cytokine secretion, antigen presentation and ectopic formation of follicle-like structures, a pathological feature shared with other chronic inflammatory diseases (Aloisi and Pujol-Borrell, 2006). Furthermore, increased secretion of pro-inflammatory cytokines such as lymphotoxin, tumour necrosis factor α (TNF-α), and interleukin (IL)-6, or deficient production of regulatory cytokines including IL-10 or IL-35 may impact complement activation and T cell function (Bar-Or *et al.*, 2010). Although B cells with clonally-related VH sequences are recovered on both sides of the blood–brain barrier, as the disease progresses, CNS B cells may eventually form a compartmentalized population, independent of the peripheral B cell pool (Frischer *et al.*, 2009). Thus, this compartmental CNS B cell immune response may be able to drive CNS injury independent of peripheral immune activity (Lovato *et al.*, 2011). Follicle-like structures have recently been found in the subarachnoid space of leptomeninges, close to inflamed blood vessels. Composition of these infiltrates included: proliferating B lymphocytes, plasma cells, helper T lymphocytes and a network of follicular dendritic cells (Serafini *et al.*, 2004; Magliozzi *et al.*, 2007). The structures co-localized with underlying grey matter lesions and parenchyma infiltrates (Lovato *et al.*, 2011), and presented different stages of development, ranging from simple T and B cell clusters to highly organized follicles resembling germinal centres encapsulated by reticulin lining (Howell *et al.*, 2011). Follicular dendritic cells within follicle-like structure produce CXCL13, which is important for recruitment, as well as maturation and antigenic selection of B cells (Corsiero *et al.*, 2012). Follicle-like structures have been found in 40–70% of SPMS cases, but not in PPMS;

Downloaded from https://academic.oup.com/brain/article/140/3/527/2447880 by guest on 26 April 2026

in RRMS, few patients have been studied (Serafini *et al.*, 2004; Magliozzi *et al.*, 2007). However, clonally-restricted B cells have been found in CSF from patients with RRMS (Kuenz *et al.*, 2008) indicating intrathecal clonal expansion of B cells. Follicle-like structure presence is uncommon in PPMS compared to SPMS, although diffuse meningeal inflammation is a feature of the pathology. It has been suggested that follicle-like structure formation may occur during the relapsing remitting phase of the disease, as a result of repeated inflammatory activity, which is not a feature found in PPMS (Choi *et al.*, 2012). Notably, follicle-like structures are probably able to sustain a high level of humoral response, as well as other autoimmune mechanisms within the CNS, in a manner independent of peripheral inflammation. This is of particular relevance during progressive multiple sclerosis, where the blood–brain barrier is intact and contribution to disease from entry of peripheral immune cells into the brain is negligible. In multiple sclerosis, cortical demyelination, neurodegeneration and atrophy show positive correlation with diffuse inflammatory infiltrates and lymphoid follicle-like structure in leptomeninges, indicating immune activation in this compartment contributes to cortical pathology in multiple sclerosis (Lassmann *et al.*, 2007; Magliozzi *et al.*, 2007, 2010). Moreover, in SPMS meningeal inflammation is associated with damage to the glia limitants, and a gradient of neuronal loss is observed that is greater in superficial cortical layers nearer the pial surface than in inner cortical layers (Magliozzi *et al.*, 2010). These findings suggest cytotoxic factors diffusing from the infiltrated meninges may play a major role in subpial cortical lesion development. Indeed, presence of follicle-like structure in patients with SPMS has been associated with lower age at disease onset, more severe disability and higher death rates (Magliozzi *et al.*, 2007, 2010; Howell *et al.*, 2011). Nevertheless, some studies have not reported substantial perivascular infiltration in pure intracortical lesions found post-mortem, in brains from patients with longstanding progressive multiple sclerosis (Peterson *et al.*, 2001; Bo *et al.*, 2003*b*). This could be a matter of reduced sample size or of insufficient inflammatory activity in the brain tissue analysed. Absence of follicle-like structures in PPMS raises doubts over a fundamental difference between PPMS and SPMS pathology. Likewise, significantly more perivascular cuffing and higher lesion cellularity have been found in chronic active SPMS lesions compared to PPMS ones, pointing to a less inflammatory milieu in these patients (Revesz *et al.*, 1994). In contrast, no significant differences have been observed between SPMS and PPMS in either normal-appearing white matter (NAWM) cortical demyelination or axonal damage (Kutzelnigg *et al.*, 2005; Antel *et al.*, 2012). Thus, questions remain as to the immunological and neurodegenerative mechanisms underlying PPMS and SPMS pathology. In both cases, diffuse meningeal inflammation and cortical neuronal pathology may be significant contributors to clinical progression, suggesting similar pathogenic mechanisms, irrespective of a prior relapsing-remitting course or the presence of follicle-like structures (Choi *et al.*, 2012). Differences observed between the two forms of disease are more quantitative than qualitative in nature (Bramow *et al.*, 2010; Antel *et al.*, 2012).

Because serological and epidemiological studies have found an association between B-lymphotropic Epstein-Barr virus (EBV) infection and multiple sclerosis (Ascherio and Munger, 2010), it has been hypothesized that EBV infection of CNS-infiltrating B cells may drive multiple sclerosis pathology (Warner and Carp, 1981). However, this remains a controversial issue as some groups report absence of EBV infection in multiple sclerosis brain (Willis *et al.*, 2009; Magliozzi *et al.*, 2013). Colonization of cortical lesions has been associated with presence of EBER-positive cells. Furthermore, expression of EBV lytic proteins BZLF1 and BERF1 was found to be restricted to plasma cells located in active cortical lesions (Magliozzi *et al.*, 2013). It is interesting to note that early lytic EBV antigens elicited CD8-mediated immune responses, triggering strong cytotoxic effects on brain tissue (Hislop *et al.*, 2007). Indeed, the most active cortical multiple sclerosis lesions are crowded with CD8+ T cells and contain few B cells or plasma cells, suggesting cortical inflammation might correlate with reduction in EBV-infected B/plasma cells numbers (Magliozzi *et al.*, 2013). These findings suggest EBV reactivation combined with the ensuing cytotoxic antiviral response may drive acute inflammation in both white and grey matter, as well as in the meningeal compartment. CD8+ cytotoxic T lymphocytes can also recognize antigens presented by oligodendrocytes and neurons. Once activated, they may be partly responsible for demyelination and axonal/neuronal damage found in multiple sclerosis (Bitsch *et al.*, 2000; Medana *et al.*, 2000; Meuth *et al.*, 2009). However, there is still controversy over underlying molecular mechanisms through which cytotoxic T lymphocytes harm axons and neurons in multiple sclerosis. Cytotoxic T lymphocytes release pro-inflammatory cytokines such as TNF-α and interferon (IFN)-γ, as well as perforin, and granzymes A and B, among others (Huse *et al.*, 2008; Mizuno *et al.*, 2008; Meuth *et al.*, 2009). TNF-α for instance, can trigger cell death via the p55 receptor on neurons (Venters *et al.*, 2000). IFN-γ on the other hand, increases glutamate neurotoxicity and calcium influx into neurons through modulating the IFN-γ/AMPA GluR1 complex (Mizuno *et al.*, 2008). Perforin and granzyme directly damage the membrane, causing sodium and calcium influx that ultimately leads to energy breakdown within the cell (see below). Furthermore, interaction of Fas antigen on cytotoxic T lymphocyte with Fas ligand on neurons is an additional mechanism activating the intracellular caspase cascade causing axonal/neuronal damage (Medana *et al.*, 2000; Giuliani *et al.*, 2003).

Active demyelination and neurodegeneration have also been linked to microglial activation in early lesions with accumulation of macrophages in injured tissues (Lassmann, 2014). Under normal circumstances, inactive microglia contributes to neuronal compartment

Downloaded from https://academic.oup.com/brain/article/140/3/527/2447880 by guest on 26 April 2026

homeostasis. However, it also plays a central role in autoimmune disorders as it can sustain ongoing inflammation once activated (Correale, 2014). Microglia activation is not restricted to lesions, but is also diffusely present in normal-appearing white and grey matter (Kutzelnigg *et al.*, 2005). In NAWM for example, clustering of activated microglia, so-called microglia nodules, are abundant in areas adjacent to plaques, particularly in patients with progressive multiple sclerosis (De Groot *et al.*, 2001). Activation of this type, occurring outside established lesions, may in part reflect anterograde or retrograde neurodegeneration in normal brain tissue due to distant destructive lesions. In multiple sclerosis, activated microglia damage oligodendrocytes through different mechanisms including: secretion of pro-inflammatory cytokines such as IL-1, IL-6, TNF-α, and IFN-γ, phagocytic activity, and presentation of antigens via MHC Class II to CD4+ T cells (Correale, 2014). In addition, direct damage to neurons occurs through reactive oxygen and nitrogen species (ROS/NRS) produced by microglia, inducing mitochondrial dysfunction (see below) (Nikic *et al.*, 2011). Interestingly, in chronic progressive multiple sclerosis cortical demyelinated lesions are less inflammatory than white matter lesions and lack inflammatory lymphocyte and macrophage infiltrates and complement deposition. Most phagocytic cells present ramified microglia morphology and appear in close apposition to neurites and neuronal cell bodies (Peterson *et al.*, 2001). It is interesting to note that activated microglia possess a puzzling array of neuroprotective functions as well, including debris phagocytosis and clearance, elaboration of growth factors and neuronal circuit-shaping (Arnett *et al.*, 2001; Kotter *et al.*, 2001; Correale, 2014). Distinguishing neuroprotective from pro-inflammatory phenotypes remains a challenge when interpreting microglial function. Laquinimod, an emerging oral medication for multiple sclerosis (see below) with significant CNS impact, reduces astrocyte activation (Bruck *et al.*, 2012), and inhibits microglial activation in human brain cell cultures. It reduces both pro- and anti-inflammatory cytokine levels, while growth factor secretion remains high. Furthermore, a reduction in microglial/macrophage density has been observed in experimental autoimmune encephalomyelitis (EAE) animals treated with laquinimod, ultimately preventing axonal injury and demyelination progression (Mishra *et al.*, 2014).

In addition to microglial cells, activation and proliferation of astrocytes within demyelinating lesions suggests these local CNS cells might also play a critical role in both oligodendrocyte injury and axonal degeneration (Correale and Farez, 2015). Recent investigations have demonstrated that in chronic phases of EAE, astrocyte depletion ameliorates disease severity, a deleterious effects mediated by preferential expression of 4-galactosyltransferase 5 and 6 (B4GALT5 and B4GALT6; Mayo *et al.*, 2014). Notably, in human multiple sclerosis lesions BAGALT6 is expressed by reactive astrocytes. These enzymes synthesize the signalling molecule lactosylceramide (LacCer), which is significantly increased in the CNS during progressive phases of EAE. LacCer promotes astrocyte activation, leading to granulocyte-macrophage colony-stimulating factor (GM-CSF, encoded by *CSF2*) and *CCL2* gene induction, consequently activating microglia and causing infiltration of monocytes from the peripheral blood. Remarkably, inhibition of *B4galt6* in mice suppresses disease progression and neurodegeneration in EAE (Mayo *et al.*, 2014).

Mechanisms of neurodegeneration and axonal dysfunction

Advances in imaging and neuropathology have shown that both axonal degeneration and neuronal death in active multiple sclerosis lesions are present from disease onset. Progression is likely to occur when axonal loss exceeds CNS compensatory capacity, resulting in irreversible neurological disability (Trapp *et al.*, 1998). Whether inflammation and neurodegeneration are primary or secondary processes, and how they might interact during the course of disease, remains unclear (Hutchinson, 2015; Louapre and Lubetzki, 2015). Evidence from both imaging and pathology suggest that the inflammatory demyelinating process in early multiple sclerosis drives a pathogenic cascade of events causing neurodegeneration, which in turn is further amplified by brain ageing, microglial activation and accumulated disease burden (Popescu and Lucchinetti, 2012; Mahad *et al.*, 2015). Because pathology findings and number of transected axons correlate with degree of inflammation in acute multiple sclerosis lesions (Trapp *et al.*, 1998; Frischer *et al.*, 2009), great interest has been focused on neurotoxic products released by innate immune cells, particularly ROS, RNS and nitric oxide (NO) produced by macrophages, microglia, and astrocytes, both in multiple sclerosis and in EAE (Haider *et al.*, 2011).

NO has been shown to cause irreversible conduction blockade in axons and to drive spinal cord degeneration in rats (Smith *et al.*, 2001). In turn, scavengers reducing ROS and RNS levels in EAE were able to attenuate focal axonal degeneration without altering the number of immune cells is EAE lesions.

Both mitochondria and mitochondrial DNA (mtDNA) are highly susceptible to oxidative injury. ROS and RNS affect mitochondrial chain complexes, generating enzyme deficiencies that can be either reversible or irreversible. In multiple sclerosis, highly active white matter lesions show diffuse mitochondrial injury. Energy failure would therefore be the main mechanism of both functional impairment and structural damage (Mahad *et al.*, 2009). During later progressive disease phases, another type of mitochondrial injury emerges in grey matter. Neuronal cell bodies in deeper layers of the cortex show evidence of impaired functional activity of mitochondrial respiratory chain complexes (Campbell *et al.*, 2011), as well as alterations in motor proteins (encoded by nuclear DNA) responsible for the movement of the mitochondria from cell body to axons

Downloaded from https://academic.oup.com/brain/article/140/3/527/2447880 by guest on 26 April 2026

(Campbell *et al.*, 2014). In progressive multiple sclerosis, neurons in deeper cortical layers also present mitochondria with mtDNA deletions, indicative of an accelerated ageing phenotype (Campbell *et al.*, 2014). The consequences of mitochondrial injury are 2-fold. First, mitochondrial dysfunction results in energy deficiency, which in mild forms will induce functional disturbances in the absence of structural damage. However, when mitochondrial injury surpasses a certain threshold, energy deficiency will lead to axonal degeneration and cell death (Friese *et al.*, 2014). Second, mitochondrial injury may amplify oxidative stress through release of oxygen radicals generated as a result of impaired respiratory chain function, thus establishing a vicious cycle of tissue destruction (Murphy, 2009). In addition, non-toxic ferric iron is released into the extracellular space from damaged oligodendrocytes in multiple sclerosis lesions, where it undergoes transformation to the divalent ferrous form, further increasing ROS toxicity (Hametner *et al.*, 2013).

Both energy imbalance and demyelination occurring during chronic CNS inflammation lead to activation, dysfunction and anomalous distribution of several ion channels. Following demyelization, Na^+ channels are diffusely distributed along the denuded axolemma from nodes of Ranvier. If axonal Na^+ rises above its nominal concentration, the Na^+/Ca^{2+} exchanger, normally exchanging axoplasmic Ca^{2+} for extracellular Na^+, will operate in a reverse Ca^{2+} importing mode. With increasing electrical traffic, axoplasmic Ca^{2+} will rise and eventually a Ca^{2+}-mediated degenerative response will be initiated (Trapp and Stys, 2009). Excess of intra-axonal Ca^{2+} may stimulate a variety of Ca^{2+} dependent catabolic enzyme systems, including proteases, phospholipases and calpains, ultimately leading to progressive intra-axonal proteolytic degradation of cytoskeletal proteins and axonal degeneration (Stys, 2005). Moreover, intracellular Ca^{2+} increase results in changes in microtubules and neurofilament phosphorylation, ultimately causing cytoskeleton breakdown (Nicholls, 2004). Chronically demyelinated axons may be dysfunctional prior to degeneration because of lack of voltage-gated Na^+ channels (Black *et al.*, 2007) and/or NA^+/K^+ ATPase (Young *et al.*, 2008). Axons that lack Na^+/K^+ ATPase cannot exchange axoplasmic Na^+ for K^+ and are incapable of repolarizing the axolemma. Reduced exchange of axonal Na^+ for extracellular K^+ will also increase axonal Na^+ concentrations, which will in turn, reverse the Na^+/Ca^{2+} exchanger and contribute to Ca^{2+} mediated axonal degeneration as mentioned above. In addition to Na^+ channels, several ion channels show parallel adaptive changes to inflammatory stimuli by altering their distribution in neurons, as an initial compensatory process to preserve conductance and axonal integrity. However, in the long term these maladaptive changes accelerate neurodegeneration. Redistribution of voltage-gated Ca^{2+} channels, transient potential receptor melastatin 4 (TRPM4), and acid-sensing ion channel1 (ASIC1) induce neuroaxonal Ca^{2+} overload, eliciting deleterious effects on axons (Friese *et al.*, 2014). Notably, redistribution of additional ion channels co-localizes with axonal injury marker APP, both in EAE and multiple sclerosis lesions (Vergo *et al.*, 2011).

Different studies have demonstrated that peroxinitrite produced by astrocytes inactivates glutamate transporters, thus limiting uptake (Rossi *et al.*, 2014). Consequently, pathologically elevated levels of extracellular glutamate are found, which are directly toxic to oligodendrocytes, axons and neurons (Matute *et al.*, 1997). Excitotoxicity is caused mainly by sustained activation of glutamate receptors and subsequent massive influx of Ca^{2+} into viable neurons. Ca^{2+} enters the cells through various mechanisms, but the most important is access through ion channels coupled to NMDA receptors and AMPA/kainate glutamate receptors (Ouardouz *et al.*, 2009). Thus, astrocyte injury may amplify demyelination and neurodegeneration in active lesions. Furthermore, fibrillary gliosis is induced with lesion maturation, which is not only responsible for scar formation, but also inhibits remyelination (Correale and Farez, 2015).

For a long time, multiple sclerosis was considered a demyelinating disease affecting only CNS white matter. In recent years, however, different studies have demonstrated cortical and deep matter demyelination may also be present (Bo *et al.*, 2003*a*). Importantly, deep grey matter nuclei are affected not only by demyelination, but also by diffuse neuronal loss in the absence of demyelinated lesions (Vercellino *et al.*, 2009). Cortical lesions present in early multiple sclerosis are associated with important inflammation (Popescu and Lucchinetti, 2012). Different subtypes of cortical lesions have been described: cortico-subcortical, small intracortical, and subpial (Bo *et al.*, 2003*b*). Subpial cortical demyelination appears to be specific to multiple sclerosis, as it is not present in any other inflammatory, neurodegenerative or metabolic disease affecting the cortex and meninges (Fischer *et al.*, 2013). No correlation has been observed between subpial and white matter lesion load (Bo *et al.*, 2003*b*), suggesting subpial demyelination is independent of white matter demyelination. Based on autopsy studies, the general consensus now is that subpial lesions are abundant in progressive stages of multiple sclerosis (PPMS and SPMS) and rare in patients with acute or early stages of RRMS (Geurts and Barkhof, 2008; Trapp and Nave, 2008). Subpial cortical lesions lack many of the pathologic hallmarks found in white matter lesions such as: blood–brain barrier breakdown, immune cell infiltrates, perivascular cuffs, loss of oligodendrocyte progenitor cells or complement activation (Dutta and Trapp, 2014). Nevertheless, active tissue damage in the cortex is associated with microglial activation (Lucchinetti *et al.*, 2011). Alternatively, soluble factors produced in inflammatory infiltrates in the meninges could diffuse directly into the cortex inducing demyelination, or this could be the result of microglial activation (Choi *et al.*, 2012). Overall, neurodegeneration in multiple sclerosis and ultimately, progression of disease and chronic disability are

Downloaded from https://academic.oup.com/brain/article/140/3/527/2447880 by guest on 26 April 2026

triggered through several different molecular mechanisms, summarized in Table 1.

Diagnosis in progressive multiple sclerosis

The diagnosis of progressive multiple sclerosis still remains a matter of clinical judgement. The word 'progression' denotes continuous worsening of neurological impairment over at least 6–12 months. Diagnosis can be difficult to establish at disease onset (PPMS), and may go unrecognized by patients or physicians for some time. Exact date of progression onset is difficult to establish and is usually estimated retrospectively, once duration of continuous neurological worsening can be calculated (Rovaris *et al.*, 2006). Ambiguity in the condition of these patients is related only in part to incomplete validation of the term 'significant worsening'. Further difficulty has arisen from the fact that, on occasion, it is hard to determine whether serial relapses are associated with permanent relapse-related deficits or with actual progression. This is more difficult when relapse intervals are short, recovery is slow, and transient improvement or worsening is observed during symptomatic treatment (Kremenchutzky *et al.*, 2006). The relationship between relapsing and progressive multiple sclerosis has remained ambiguous. On one hand, relapses have been shown to produce measurable and sustained effects on disability progression in patients with RRMS (Lublin *et al.*, 2003). In contrast, observational studies on multiple sclerosis natural history (Confavreux and Vukusic, 2006; Kremenchutzky *et al.*, 2006) showed total relapses during relapsing-remitting phases did not influence disability progression. However, frequent relapses in the first 2 years were shown to be associated with later disability, as they increased probability of developing SPMS, and shortened the latency of its onset (Scalfari *et al.*, 2010). Recent studies challenge the concept that RRMS and SPMS are two different stages of the same disease, in which disability progression may result from neurodegeneration that is not linked to inflammation. Evidence indicates that disease progression in SPMS results from CNS-based inflammation trapped behind the blood–brain barrier, which causes widespread, low-grade, sustained demyelination and axonal injury (Kornek *et al.*, 2000; Kutzelnigg *et al.*, 2005).

Traditionally, PPMS is defined as 'a disease with gradual nearly continuously worsening from baseline, with minor fluctuations (variations in rate of progression) but no distinct relapses' (Lublin and Reingold, 1996), which commonly presents as a spastic paraparesis (Kremenchutzky *et al.*, 1999). Clinical presentation other than as progressive myelopathy can occur in PPMS, although less often (Rice *et al.*, 2013). Some patients experience a course dominated by progression, or suffer relapses superimposed on a progressive course. Although SPMS pathology is similar to that of PPMS, more efficient remyelination may occur in brain, but not spinal cord of patients with PPMS (Bramow *et al.*, 2010), thus explaining why patients with PPMS show less cognitive impairment, even in very motor disabled cases (Bergendal *et al.*, 2007). Nevertheless, it is worth noting that other studies have demonstrated no differences in cognitive performance between patients with PPMS and those with SPMS (Ukkonen *et al.*, 2009), besides that it had been previously found that patients with PPMS presented significant cognitive dysfunction when compared to individually matched healthy controls (Camp *et al.*, 1999).

Actual diagnosis of PPMS requires presence of clinical progression lasting at least 1 year, as well as two of the following three criteria: brain or spinal cord lesions on MRI indicating dissemination of disease, or positive CSF findings. Under current criteria, level of physiological dysfunction, increased immunoglobulin (Ig) synthesis or oligoclonal bands are not considered requisites (Polman *et al.*, 2011). Interestingly, PPMS exhibits only slight gender bias (1.1–1.3 to 1), unlike the overall 3:1 female to male predominance in multiple sclerosis (Cottrell *et al.*, 1999; Stevenson *et al.*, 1999). It remains puzzling that no gender distribution differences have been observed in patients with PPMS. MRI studies revealed more pronounced grey matter and central atrophy in males, and more advanced white matter atrophy in females (Antulov *et al.*, 2009). Advanced grey matter pathology may be caused initially by subpial lesions and neuronal damage resulting from retrograde Wallerian degeneration (Dutta and Trapp, 2007), the underlying molecular mechanisms of which remain unclear. Increased sex hormone levels in females may protect against grey matter atrophy (Cutter *et al.*, 2006). In contrast, testosterone was shown to amplify oligodendrocyte excitotoxicity, potentially limiting remyelination (Caruso *et al.*, 2004). Direct effects linked to the X chromosome and gender-specific epigenetic variations may also differentially impact remyelination and axonal ability to repair injury (Sbardella *et al.*, 2013). In the London Ontario cohort (Cottrell *et al.*, 1999), age of onset, gender or clinical presentation did not appear to influence progression rates. However, rate of initial decline (DSS 3) was of some value as a prognostic indicator, correlating with accelerated time to DSS 8. Notably, natural history of disability progression in PPMS appears virtually identical to that of SPMS, when compared from onset of the progressive phase (Kremenchutzky *et al.*, 2006), and both phenotypes are similar in most clinical features, genetics, as well as CSF and MRI findings (Rice *et al.*, 2013). Furthermore, albeit at low frequency, a proportion of patients with PPMS will suffer relapses at some stage of the disease. Analysis of prospective cohorts reported between 12.6% (Andersson *et al.*, 1999) and 27.8% (Kremenchutzky *et al.*, 1999) of patients with PPMS experienced relapses, with variability likely to be related to length and intensity of follow-up, as well as definition of relapses applied. Moreover, families including multiple members with multiple sclerosis, can present different phenotypes of disease (Rice *et al.*, 2013), and pathology studies show similar CNS alterations in RRMS, PPMS and SPMS (Lassmann *et al.*, 2007). Overall, these findings

Downloaded from https://academic.oup.com/brain/article/140/3/527/2447880 by guest on 26 April 2026

Table 1 Proposed mechanisms leading to progressive multiple sclerosis

Proposed mechanism	Effects
Immune effector mechanisms	
Clonal expansion of B cells	Antibody production, Antigen presentation, ectopic formation of FLS
	Induction of compartmentalized population driving CNS injury, independent of peripheral immune activity
	Secretion of IL6, TNFα, IL10, and IL35: complement activation and T cell functions
Ectopic formation of FLS	Secretion of CXCL13: recruitment, maturation and antigenic selection of B cells
	Secretion of cytototxic factors
EBV-infected B cells	Induce CD8-mediated immune responses against brain tissue
CD8+ cytotoxic T lymphocytes	Release of TNFα: neuronal cell death via p55 receptor; IFN-γ: increased glutamate neurotoxicity and Ca^{2+} influx; secretion of perforin and granzyme: cellular membrane damage, associated to Na^{+} and Ca^{2+} influx
Microglia activation[a]	Decreased expression of immune-suppressive factors: fractalkine-CX3CR1, and CD200-CD200R
	Secretion of pro-inflammatory cytokines: IL1, IL6, TNF-α, IFN-γ
	Ag presentation of CD4+ T cells via MHC Class II
	Oxidative burst: production of ROS and RNS
	Acquisition of aging phenotype: expression of AGE and RAGE
Astrocyte activation[a]	Secretion of pro-inflammatory cytokines: IL1, IL6, TNF-α
	Secretion of chemokines: CCL2, CCL5, IP10, CXCL12, IL8
	BBB breakthrough: action on endothelial cells and tight junctions
	Production of BAFF: driving B cell autoimmunity
	Activation of microglia: secretion of CXCL-10/CXXR3, GM-CSF, M-CSF and TGF-β
	Production of LacCer: induces secretion of CCL2 and GM-CSF causing activation of microglia and monocytes infiltration
	Production of ROS, RNS, NO and ONOO-
Mechanisms of neurodegeneration and axonal dysfunction	
Mitochondrial injury	Impaired activity of respiratory chain complexes (I, III and IV)
	Alterations in mitochondrial molecular motors
	mtDNA deletions
	Energy deficiency: failure of Na^{+}/K^{+} ATPase, reverse activity of NCX, and excess of intra-axonal Ca^{2+}
	Amplify oxidative stress
	Histotoxic hypoxia, which amplifies energy deficiency
Release of Fe^{3+} from damaged OGD	Amplifies oxidative injury
Anomalous distribution of ion channels	Redistribution of Na^{+} channels (Na, 1.2, 1.6 and 1.8) along the denuded axon: increased energy demand
	Activation of VGCC, ASIC1 and TRPM4 contributes to excess of intra-axonal Ca^{2+}
Astrocyte activation[a]	Production of ONOO- limited glutamate transporters, increasing glutamate excitotoxicity
	Reactive astrogliosis: inhibition of remyelination and axonal regeneration by over-secretion of FGF-2, CSPGs and EPH
	Upregulation of purinergic receptors: increased responsiveness to ATP, formation of membrane pores and increased Ca^{2+} influx
	Cellular senescence: low level of chronic inflammation, altered Ca^{2+} homeostasis
Glutamate excitotoxicty	Massive influx of Ca^{2+} into neurons
Excess of intra-axonal Ca^{2+}	Stimulates catabolic enzyme systems: proteases, calpain, and phospholipases, leading to proteolitic degradation of cytoskeletal proteins
Loss of myelin-derived trophic support	Alteration of a single myelin protein (PLP, MGA, or CNP) can cause axonal dysfunction
Deficit in axonal transport	Reduced expression of kinesins (anterograde transport)
	Reduced expression of dyneins (retrograde transport)

[a]Only deleterious mechanisms are presented.

AGE = advanced glycation end products; ASIC1 = acid-sensing ion channel; BAFF = B-cell-activating factor; CNP = 2',3',cyclic nucleotide3'-phosphodiesterase; CSPGs = chondroitin sulphate proteoglycans; EPH = ephrins; FGF-2 = fibroblast growth factor 2; FLS = follicle-like structures; GM-CSF = granulocyte-macrophage colony stimulating factor; MAG = myelin-associated glycoprotein; M-CSF = macrophage-colony stimulating factor; mtDNA = mitochondrial DNA; NCX = sodium calcium exchanger; NO = nitric oxide; OGD = oligodendrocytes; ONOO- = peroxinitrite; PLP = proteolipid protein; RAGE = AGE receptor; TRPM4 = transient potential receptor melastatin 4; VGCC = voltage gated Ca^{2+} channel.

suggest multiple sclerosis is a single disease entity with several distinct clinical phenotypes. PPMS does not present different pathophysiological features from relapsing forms that have entered progressive stages (SPMS). Supporting this notion, a 12% prevalence of PPMS was observed recently in a large cohort of radiologic isolated syndrome (RIS), in patients with high load of spinal cord disease, in addition to brain lesions fulfilling criteria for multiple sclerosis (Kantarci

Downloaded from https://academic.oup.com/brain/article/140/3/527/2447880 by guest on 26 April 2026

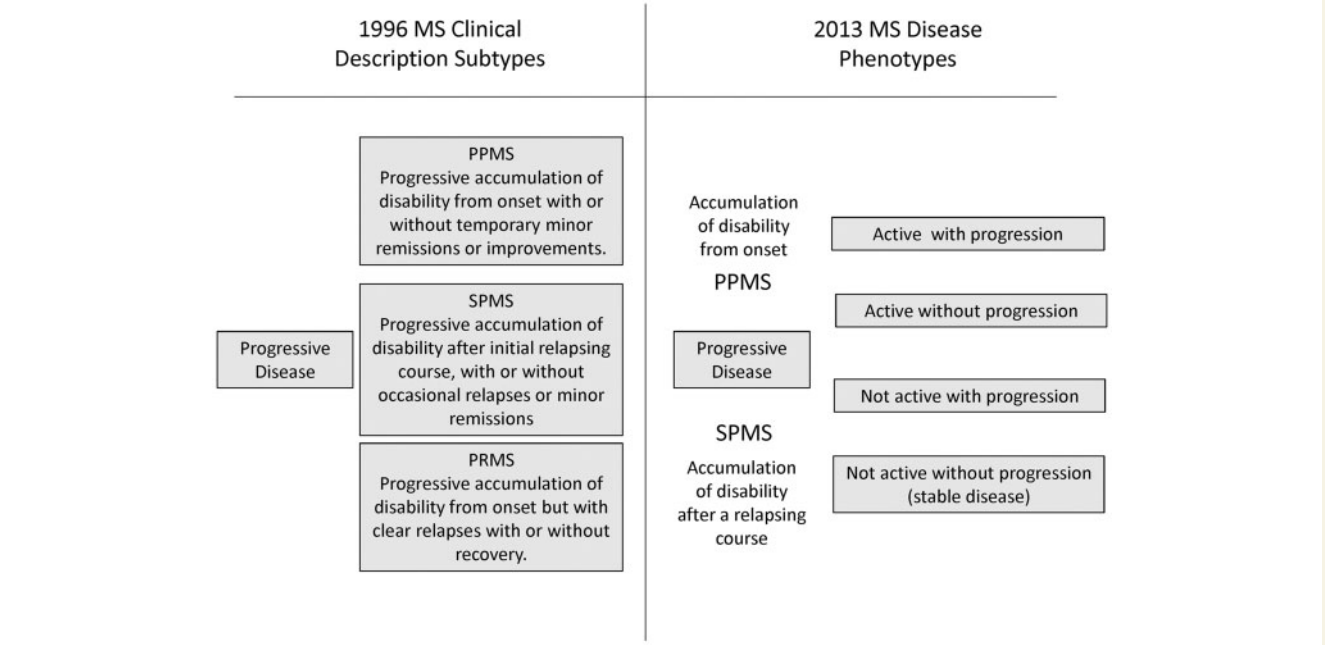

Figure 1 1996 versus 2013 multiple sclerosis phenotype descriptions for progressive disease (modified from Lublin *et al.*, 2014). If assessments are not available, activity and progression are 'indeterminate.' MS = multiple sclerosis.

et al., 2016). Interestingly, PPMS prevalence in this RIS cohort, as well as age at PPMS onset, were both strikingly similar to those observed in large clinical studies in multiple sclerosis.

MRI is already well established as a useful tool for multiple sclerosis diagnosis, helping to exclude other causes of neurological symptoms whilst demonstrating disease spread of typical multiple sclerosis lesions in time and space. However, no reliable MRI techniques exist today to predict rate of progression in SPMS or PPMS (see below). MRI features that best correlate with current disability may change as the disease advances, and optimal combinations of measures may also differ between multiple sclerosis subtypes (Fisniku et al., 2008). As imaging methods are weak predictors of progressive multiple sclerosis in individual patients and biological and other surrogate markers are not well established or standardized, diagnosis of progressive forms continues to be challenging and can result in delays, with a variety of implications related to patient care and clinical trial development. In a recent study, 70% of patients generated diagnostic uncertainty related to clinical phenotype, so that they were characterized as possible, but not definitive progression after outpatient examination. Mean duration of uncertainty regarding transition from RRMS to SPMS was 2.9 ± 0.8 years, and time elapsed until first visit in which SPMS was diagnosed was 4.3 ± 0.8 years, at which time 70% had EDSS $\geqslant 6$ points (Katz Sand *et al.*, 2014)

Recent changes to the multiple sclerosis classification were proposed by an international panel of experts to further characterize the clinical course of progressive multiple sclerosis (Lublin *et al.*, 2014). These changes include: categorization of disease course in progressive multiple sclerosis as having 'active', or not having active ('not active') inflammation, based on presence of clinical relapses or MRI findings (gadolinium-enhancing lesions, or new or unequivocally enlarging T_2 lesions). Experts also recommended classifying progressive multiple sclerosis on the basis of presence or absence of clinical disease progression. Imaging methods for progression are not well established, therefore no MRI parameters were included in this classification. A patient with progressive multiple sclerosis who has an acute attack (thus fulfilling prior criteria for progressive relapsing multiple sclerosis) would be considered to be from progressive or active multiple sclerosis. Progressive multiple sclerosis phenotypes are summarized in Fig. 1. Furthermore, because neurological dysfunction may still improve (especially during active disease) even if progression is confirmed over 6–12 months, use of the term confirmed rather that sustained is recommended.

These changes in multiple sclerosis classification tend to facilitate patient prognosis and treatment selection in different clinical settings. Furthermore, adding presence of active disease and measures of progression should enhance clinical trial design, recruitment and execution. In such studies, attention should be paid to stratifying enrolment and to conducting study analysis according to disease subtype.

Investigators suggested that continued refinement of clinical multiple sclerosis phenotypes should be a research priority, as better understanding of multiple sclerosis—and particularly of progressive multiple sclerosis—will only be

Downloaded from https://academic.oup.com/brain/article/140/3/527/2447880 by guest on 26 April 2026

made possible by an accurate characterization of disease spectrum.

Correlation between histopathology and MRI studies

The introduction of MRI in multiple sclerosis has revolutionized our ability both to diagnose the disease and monitor treatment response. It has deepened and transformed our understanding of pathological processes involved in disease development and progression. MRI is about 5 to 10 times more sensitive to ongoing inflammatory demyelination than clinical assessment (Harris *et al.*, 1991) and is superior to any other imaging method for lesion detection. However, no pathognomonic MRI characteristic had been established for each type of multiple sclerosis. Histopathology studies have shown more grey matter involvement in progressive disease, as well as greater axonal loss, larger cortical demyelination, meningeal inflammatory aggregates and compartmentalization of inflammation. These heterogeneous pathological substrates might be targeted by potential therapeutic interventions. Current MRI techniques are elucidating the link between axonal degeneration and neuronal loss with increasing, previously difficult to define disability parameters (Hauser and Oksenberg, 2006).

Inflammation

MRI performed after intravenous injection of contrast agents can detect blood–brain barrier disruption, occurring during inflammatory lesion development (Grossman *et al.*, 1986). Multiple sclerosis lesions in progressive disease are rarely active; slowly expanding and inactive lesions are the most common findings (Frischer *et al.*, 2009), therefore, focal brain enhancement after contrast administration is not common. However, pathology studies have shown blood–brain barrier abnormalities in chronic lesions, such as serum proteins in plaques, disferlin expression in endothelial cells (Hochmeister *et al.*, 2006) and a strong correlation between inflammation and degeneration in progressive multiple sclerosis (Frischer *et al.*, 2009). These blood–brain barrier abnormalities are not visually detectable on MRI, contrast-leakage is usually not observed when standard dose of gadolinium (0.1 mmol/kg) is used (Filippi *et al.*, 1995). But when a quantitative approach with triple dose of contrast is applied, changes in intensity of non-visually-enhancing lesions are detected, suggesting blood–brain barrier impairment within chronic lesions (Silver *et al.*, 2001).

As previously mentioned, the presence of follicle-like structures correlates with irreversible disability and death in patients with SPMS (Magliozzi *et al.*, 2007). In a recent investigation, focal areas of leptomeningeal enhancement in fluid-attenuated inversion recovery (FLAIR) images post contrast were documented in 19% subjects with RRMS and 33% with SPMS. Interestingly, the enhancing area remained stable over time (up to 5 years follow-up). Notably, in two autopsied patients, pathology showed perivascular lymphocytic and mononuclear inflammation including T cells, B cells and macrophages in sulci where focal *in vivo* enhancement was previously detected (Absinta *et al.*, 2015). Thus, this non-invasive technique may turn into an *in vivo* marker of inflammation.

Demyelination

Chronic inactive T_2 lesions show no clear difference in RRMS compared to progressive multiple sclerosis, although some chronic lesions may show a hypointense ring on T_2* gradient-recalled echo (GRE) (Absinta *et al.*, 2013) that may correspond to increased activated microglia (Pitt *et al.*, 2010). Typically, multiple sclerosis lesions in PPMS are scarce, develop more slowly over time, and lesion load is lower in comparison to RRMS or SPMS (Thompson *et al.*, 1990*b*). In subjects with SPMS, lesions are usually larger and more confluent than in RRMS or PPMS (Thompson *et al.*, 1990*a*). Even though, discrimination case-by-case in clinical practice may be poor, and many times overlap occurs.

Magnetization transfer ratio (MTR) is a method used to detect demyelination not observable on conventional MRI. Decreased values have been shown to correlate with myelin loss in the mouse cuprizone model for demyelination (Tagge *et al.*, 2016), in which MTR is severely reduced in focally demyelinated multiple sclerosis lesions and partially reduced in NAWM. In patients with multiple sclerosis, MRI-pathology correlation studies show strong association between MTR and myelin content (Schmierer *et al.*, 2004). Interestingly, changes in white matter lesion MTR were reported as more pronounced in SPMS than RRMS (Agosta *et al.*, 2006).

Grey matter demyelination occurs more frequently in progressive multiple sclerosis than in RRMS (Kutzelnigg *et al.*, 2005); white matter lesions may extend into grey matter, including both cortex (leukocortical) and deep grey matter nuclei (Nielsen *et al.*, 2013; Harrison *et al.*, 2015). Most cortical lesions are subpial, and can involve all cortical layers. However, they are not visible on conventional MRI and are exceedingly difficult to detect even using non-conventional MRI techniques (Geurts *et al.*, 2005). Major reasons for poor MRI contrast between normal appearing grey matter and cortical lesions includes, partial volume effects, as well as lower amounts of free water. Double inversion recovery at 1.5- and 3-T scans has been widely used to detect multiple sclerosis cortical pathology (Geurts *et al.*, 2011). However, higher resolution sequences, such as phase sensitive inversion recovery (PSIR), have shown less false positive results (Sethi *et al.*, 2013). Cortical lesions are well depicted at high 7 T MRI; 7 T FLASH-T_2* had shown a strong correlation between leukocortical and subpial lesions to cognitive and

Downloaded from https://academic.oup.com/brain/article/140/3/527/2447880 by guest on 26 April 2026

neurologic status (Nielsen *et al.*, 2013). In this sense, Absinta *et al.* (2013) showed that focal areas of *in vivo* leptomeningeal enhancement were associated with flanking subpial cortical demyelination. Interestingly, a gradient of cortical pathology was also documented by *in vivo* 7 T imaging. In early disease, superficial cortical T_2* changes were observed, whereas in later disease stages, these changes involved deeper cortical layers. These T_2* changes are consistent with a gradient of myelin and iron loss. These radiological findings give *in vivo* evidence of a pathological cortical process driven from the pial surface (Mainero *et al.*, 2015). Despite all this evidence, and even after implementing optimized MRI techniques, very few cortical lesions are actually detected in clinical practice. Visualizing cortical demyelination on MRI in patients with multiple sclerosis is still challenging.

Diffuse damage

Brain atrophy

Brain atrophy accumulates in multiple sclerosis at a rate of ~0.5% per year, two to three times more rapidly than in healthy subjects, and is generally thought to reflect neurodegeneration underlying relentless accumulation of disability in progressive multiple sclerosis (De Stefano *et al.*, 2010). Brain atrophy reflects tissue loss and represents a global measure of both demyelination and axonal loss in multiple sclerosis (Inglese *et al.*, 2011). MRI scanning has enabled non-invasive and quantitative characterization of brain atrophy with image post-processing. Several brain segmentation techniques have been developed including SIENA, SIENAX, SPm and FreeSurfer. Quantitative atrophy estimation can detect progressive loss of brain volume and, in particular, grey matter atrophy, which appears to drive whole-brain atrophy most strongly (Fisher *et al.*, 2008). Some studies have demonstrated that cortical atrophy is more prominent in progressive multiple sclerosis, and correlates with the degree of disability (Pagani *et al.*, 2005).

Diffuse normal-appearing white matter changes

Different non-conventional MRI techniques have been used to characterize abnormalities in NAWM. Magnetic-resonance spectroscopy (MRS) allows measurement of *N*-acetylaspartate (NAA). Global NAA measured across the whole brain is abnormally low in multiple sclerosis. Because NAA is detected almost exclusively in neurons and their processes, decreased levels of this metabolite have been interpreted as evidence of axonal injury. Whole brain MRS has successfully shown significant reduction in both NAA and NAA/creatine (NAA/Cr) ratio, in clinically isolated syndrome and RRMS, compared to healthy controls. However, the changes did not correlate with EDSS. Intralesional NAA levels in PPMS and RRMS are similar, but they are lower in NAWM of PPMS and SPMS patients than in NAWM of patients with RRMS (Fu *et al.*, 1998; Suhy *et al.*, 2000). Despite these encouraging findings, it is worth noting that sometimes NAA levels are restored in the lesion core and NAWM. NAA and NAA/Cr might represent a marker of neuro-axonal energy dysfunction, and consequently its pathological relevance as a predictive biomarker remains unclear.

High resolution diffusion tensor imaging (DTI) has been used to elucidate the link between axonal degeneration and disability parameters (Sbardella *et al.*, 2013). Increased mean diffusivity and decreased anisotropy, reflecting axonal and myelin loss were detected in NAWM (Filippi *et al.*, 2001). These changes were more profound in patients with SPMS compared to those with RRMS (Preziosa *et al.*, 2011). Moreover, these changes were also found in grey matter of patients with multiple sclerosis where axonal degeneration is prominent, and to a greater degree in SPMS, compared to other multiple sclerosis phenotypes (Preziosa *et al.*, 2011). Attempts have been made to correlate diffusion alterations with EDSS; however, results remain controversial.

As mentioned above, MTR is heterogeneously reduced in both multiple sclerosis lesions and NAWM of patients with multiple sclerosis and is also linked to disability (Traboulsee et *al.*, 2003). Interestingly, a post-mortem study performed in SPMS subjects revealed that, in NAWM in close proximity to white matter lesions, MTR changes can be attributed to axonal degeneration and microglial activation. In contrast, subtle MTR abnormalities in NAWM far from lesions were associated with marked microglial activation, but not with axonal pathology (Moll *et al.*, 2011).

Spinal cord atrophy

As in RRMS, in progressive multiple sclerosis spinal cord lesions are typically posterior and lateral, multifocal, and asymmetrically distributed. They develop mostly in the cervical spinal cord, in the periphery of white matter, are for the most part limited to no more than two vertebral segments, and occupy less than half the cross-sectional area of the cord (Lycklama *et al.*, 2003), although confluent lesions are frequently observed. There has recently been a resurgence of interest in spinal cord atrophy, with the recognition that it may have an important, and at least partly independent role to play in determining long-term disability (Bonati *et al.*, 2011). Both cervical and thoracic lesion load is greater and more severe in progressive forms of multiple sclerosis (Schlaeger *et al.*, 2014, 2015) correlating with physical disability much more than other markers of degeneration (Kearney *et al.*, 2015). Spinal cord atrophy is usually assessed by measuring cord cross-sectional area rather than volume. However, imaging protocols should include both sagittal and axial views: axial imaging can improve identification of suspected lesions and indicate the implicated cord column (Kearney *et al.*, 2015). Notably, spinal cord grey matter atrophy seems to contribute more to patient disability than spinal cord white matter or brain grey matter atrophy (Schlaeger *et al.*, 2014).

Downloaded from https://academic.oup.com/brain/article/140/3/527/2447880 by guest on 26 April 2026

Possible treatments for progressive multiple sclerosis

A myriad of drugs are being developed aimed at different proposed pathogenic mechanisms of multiple sclerosis progression. Compounds might target: immune system dysfunction (B cells and microglia), glial cells or neurons, metabolic abnormalities associated with mitochondrial injury or different ion channels. Furthermore, several trials using neuroprotective therapies aiming to stop progression or reparative therapies aiming at least partly to reverse some aspects of neurological disability by repairing brain and spinal cord tissues, are currently ongoing.

Immunological targets

The success of the phase III randomized controlled trials (RCTs) on disease-modifying therapies in RRMS (Cohen and Rudick, 2011), naturally led to exploration of their efficacy in both SPMS and PPMS. Despite extensive efforts, with the exception of two RCTs using IFNβ1b and mitoxantrone in SPMS (European Study Group, 1998; Hartung *et al.*, 2002), primary endpoints in these trials were not achieved. Although some short-term effects were reported at 3 months on confirmed disability and relapse rate, overall effect on sustained progression after 6 months was not significant (Ontaneda *et al.*, 2015). However, some secondary endpoints, for instance markers of inflammatory disease, did demonstrate treatment effects. Nevertheless, important lessons can be drawn from these clinical trials, providing information on the natural history of progressive multiple sclerosis, and stimulating expert consensus and diagnostic criteria improvement.

The mitoxantrone in multiple sclerosis (MIMS) study was a double-blind phase II study of mitoxantrone in patients with SPMS with and without relapses (Hartung *et al.*, 2002). Based on the MIMS trial, the US FDA approved mitoxantrone (12 mg/m^2) administered every third month, for treatment of worsening RRMS, and SPMS. Although it was suggested that patients with SPMS without relapses might also benefit from treatment, results were controversial. Unfortunately, risk of serious side effects such as cardiomyopathy and treatment-related acute leukaemia has substantially limited indication in clinical practice (Goodin *et al.*, 2003).

Several phase III clinical trials using IFNβ1a and IFNβ1b in SPMS did not show permanent disability delay, but did reduce relapses risk (SPECTRIMS Study Group, 2001; Cohen *et al.*, 2002; Andersen *et al.*, 2004; Panitch *et al.*, 2004). Likewise, other immunosuppressive drugs (e.g. methotrexate, cyclophosphamide and azathioprine) have been tested in progressive multiple sclerosis. Although on occasion some therapeutic effects (in subgroups or as trends) have been observed, convincing effects on disability progression have not been shown (Lugaresi *et al.*, 2001; Schwartzman *et al.*, 2009).

In an exploratory study, 25 patients with SPMS were treated with alentuzumab 20 mg IV, daily for 5 days (Paolillo *et al.*, 1999). Significant effect of alentuzumab on suppression of mean relapse rate and Gd-enhancing lesions was observed. However, disability continued to deteriorate, in correlation with both cerebral and spinal cord atrophy. Remarkably, when patients were examined 7 years later, no new inflammatory events had occurred in the intervening years. However, there had been brain atrophy.

Natalizumab has been licensed for treatment of highly active RRMS. A phase III randomized, double-blind, placebo-controlled trial (ASCEND) began in 2011 to investigate whether natalizumab slows accumulation of disability not related to relapses, in people with SPMS. A total of 890 individuals with SPMS and no prior use of natalizumab were enrolled in the trial. The composite primary endpoint evaluated percentage of patients whose disability had progressed on one or more of three disability measures. Unfortunately, the sponsor behind the trial announced in October 2015 that results were unsuccessful. Natalizumab did show some positive effects on upper limb function, but did not slow down disability accumulation compared to rates observed in the placebo group (NCT01416181).

Two clinical trials using IFN-β were undertaken in PPMS. In the first, 50 patients with PPMS were included in an exploratory double-blind placebo controlled RCT, over a period of 2 years. Three treatment arms were analysed: IFNβ1a 30 μg weekly, IFNβ1a 60 μg weekly, and placebo (Leary *et al.*, 2003). No significant differences in disease progression between treatment arms and placebo were observed. Likewise, in a single centre, double-blind RCT, the Barcelona group examined efficacy of subcutaneous IFNβ1b 8 MIU (million international units) versus placebo, in PPMS over 2 years (Montalban *et al.*, 2009). This was also a negative study in relationship to primary outcome (EDSS progression). However, MSFC outcomes indicated a minor clinical effect during the second year, which was not sustained at 27 months.

The first fully powered phase III RCT of disease-modifying therapy in PPMS examined the utility of daily subcutaneous glatiramer acetate (GA) 20 mg versus placebo, in 943 patients (PROMISe study) (Wolinsky *et al.*, 2007). This study was prematurely stopped by the sponsor after a second interim analysis at 2 years; at the time, ~60% of the study population had received therapy for 2 years. Primary outcome was delay in disability progression, and did not differ significantly between treatment groups.

The OLYMPUS study was a double-blind, placebo-controlled RCT, which recruited 439 patients with PPMS in a 2:1 randomization of rituximab (a B cell depleting, chimeric anti-CD20 monoclonal antibody) to placebo, and had 96 weeks follow-up. Although the study did not meet primary outcome (time to confirmed progression of disability), a favourable trend was observed in a subgroup of young patients who had more active inflammation on baseline MRI (Hawker *et al.*, 2009; Castillo-Trivino *et al.*,

Downloaded from https://academic.oup.com/brain/article/140/3/527/2447880 by guest on 26 April 2026

2013). Based on the evidence that in progressive multiple sclerosis inflammatory cells are compartmentalized behind a closed blood–brain barrier, and therefore inaccessible to many therapeutic agents, ongoing trials using intrathecal rituximab are currently recruiting participants. Primary completion date is expected during the next 2 years (NCT01719159; NCT02253264; NCT01212094; NCT02545959).

Ocrelizumab is a fully humanized monoclonal antibody that depletes B cells via antibody-dependent cell-mediated toxicity, more than complement-dependent cytotoxicity, which could reduce infusion-related toxic side effects (Buttmann, 2010). ORATORIO was a phase III, randomized, double-blind, global multi-centre study evaluating efficacy and safety of ocrelizumab (600 mg administered by intravenous infusion every 6 months) compared to placebo, in 732 people with PPMS followed for 120 weeks. Ocrelizumab reduced risk of clinical disability progression by 24%, and also reduced time to walk 25 feet by 29%, as well as rate of whole-brain volume loss by 17.5%, compared to placebo. Thus, ocrelizumab becomes the first agent to have shown positive results in pivotal studies in PPMS (NCT 1194570).

Fingolimod also showed some efficacy in chronic EAE models (Di Pardo *et al.*, 2014), possibly in relation to the molecule's ability to reduce pathology, independent of lymphocyte infiltration (Farez and Correale, 2016). The INFORMS study was based on the knowledge that fingolimod enters the CNS and can interact with damage-causing cells residing in the CNS. This clinical trial was a phase III double-blind, randomized, multicentre, placebo-controlled parallel group study, comparing efficacy and safety of fingolimod versus placebo in 970 patients with PPMS. Patients were initially assigned to fingolimod 1.25 mg per day or placebo (Cohort 1); however, after a protocol amendment patients were switched to fingolimod 0.5 mg, whereas those on placebo continued on matching placebo. From then onwards, patients were assigned to receive fingolimod 0.5 (mg/day) or placebo (Cohort 2). Patients were evaluated using a novel primary composite endpoint based on change from baseline in EDSS, 25 Timed-Walk Test, or Nine-Hole Peg Test to assess time to 3-month confirmed disability progression in study participants treated for at least 3 years. Unfortunately, the study showed no treatment benefit on disability progression or brain volume loss, despite effects on some MRI (Lublin *et al.*, 2016).

A new selective sphingosine 1 phosphate modulator, named siponimod, is now being evaluated in a phase III multicentre trial in SPMS, and the first results are expected for 2016 (NCT01665144).

Targeting neurodegeneration and axonal dysfunction

Mitochondria-targeted therapies

Several studies have shown mitochondria as potential therapeutic targets. Recently, two studies reported protective properties of MitoQ, a specific inhibitor for mitochondrial ROS production, in EAE (Davies *et al.*, 2013). Because levels of inflammation were not affected by MitoQ, it is conceivable that increased mitochondrial protection against ROS is sufficient to reduce axonal damage.

The antioxidant idebenone was proven to be beneficial in Leber's hereditary optic neuropathy, a disorder caused by mitochondrial defects. However, in EAE, idebenone failed to affect disease incidence or onset when applied preventively, or to reduce disease severity when applied therapeutically. Histopathological examination of CNS tissue from idebenone-treated mice showed no improvement in inflammation, demyelination, or axonal damage. Nevertheless, two clinical trials are currently ongoing, designed to evaluate idebenone safety, therapeutic efficacy and mechanism of action, in PPMS. Final data are expected for 2018 and 2019, respectively (NCT00950248, NCT01854359).

Inhibition of ion channels

Inhibition of Na^+ channel and Ca^{2+}-mediated activators are logical therapeutics targets that may delay axonal degeneration and permanent disability in patients with multiple sclerosis (Waxman, 2006). In EAE systemic administration of flecainamide (Bechtold *et al.*, 2004), or Na^+ channel-blocking anticonvulsants (lamotrigine, phenytoin, carbamazepine) (Bechtold *et al.*, 2004, 2006) reduced neurological disability. However, clinical trials of lamotrigine in patients with progressive multiple sclerosis did not show advantages over placebo with respect to neuroprotection (Hayton *et al.*, 2012). Specific targeting of certain Na^+ channels subsets, or selective administration of the compound into inflamed tissue might represent future strategies (Al-Izki *et al.*, 2014). Activation of the ion channels ASIC1 and TRPM4 contributes to Na^+ influx. Blocking these ion channels with amiloride or glibenclamide, respectively could be a new approach, as they provided neuroprotection in EAE and decreased neuronal and oligodendrocyte damage (Friese *et al.*, 2007; Schattling *et al.*, 2012).

Excitotoxicity mediated by glutamate

Treatment with the AMPA/kainate glutamate receptor NBQX decreased neurological disability, increased oligodendrocyte survival and reduced axonal damage in EAE (Pitt *et al.*, 2000). It is possible that a combinatorial approach towards blocking both AMPA/kainate and NMDA class of receptors may be an effective target for protecting glia and axons (Trapp and Stys, 2009).

Neurotrophins for neuroprotection

Several lines of evidence suggest that myelin and oligodendrocyte-derived factors support axons, so that their loss contributes to axonal degeneration (Scolding and Franklin, 1998). This implies that remyelination and therapies inducing remyelination could themselves be neuroprotective. Therapeutic approaches are now being pursued based on this knowledge. GDNF (glial-cell-line derived

Downloaded from https://academic.oup.com/brain/article/140/3/527/2447880 by guest on 26 April 2026

neurotrophic factor), IGF1, and BDNF are implicated in trophic support provided for axons by oligodendrocytes (Wilkins *et al.*, 2003), which one would predict would be deficient in multiple sclerosis. These factors could therefore be therapeutically useful as axon-protecting agents. IGF1 has been explored in early phase clinical trials without success (Frank *et al.*, 2002). As neurotrophins have a short plasma half-life (Pradat *et al.*, 2001) they cannot be delivered systemically. Furthermore, neurotrophins do not cross the human blood–brain barrier, unless modified, for instance using chimeric brain-derived peptides as drug-targeting technology (Pardridge, 2002). As neurotrophins have different effects on different cell populations during oligodendrogenesis, it may be useful to test combinations of neurotrophins, while also taking into account the importance of administration timing. Neurotrophins bind with high affinity to tropomyosin-related kinase (trk) receptors and with low affinity to p75NTR receptors. Thus, other options worth exploring would be trk receptor agonists (Hohlfeld, 2008). Interestingly, some immunomodulatory agents used for multiple sclerosis, namely IFN-β and glatiramer acetate have been shown to increase serum or immune cell levels of BDNF in patients with multiple sclerosis, suggested as a possible mechanism of action for these therapies (Kalinowska-Lyszczarz and Losy, 2012).

Other compounds

Laquinimod induces a shift towards T-helper (Th) 2 and Th3 cytokines (Killestein *et al.*, 2011). However, other investigations have demonstrated that both pro- and anti-inflammatory cytokines are reduced, while growth factor secretion remains high (Mishra *et al.*, 2014). Also laquinimod has neuroprotective potential that may depend, at least in part, on its effects on astrocytes and microglia (Bruck *et al.*, 2012; Mishra *et al.*, 2014). A phase II study is currently underway to serve as proof of concept for treatment of patients with PPMS, examining two doses of laquinimiod in this population (NCT02284568). Estimated study completion is October 2017.

MN-166 (ibudilast) is a non-selective phosphodiesterase inhibitor that suppresses pro-inflammatory cytokines, promotes neurotrophic factors, and attenuates activated glial cell (Suzumura *et al.*, 2003; Feng *et al.*, 2004). SPRINT-MS is a phase II trial currently ongoing in patients with SPMS and PPMS designed to evaluate tolerability, safety and efficacy of MN-166 (NCT01982942).

Aside from presenting immunomodulatory properties, dimethylfumarate (DMF) also exerts antioxidant cytoprotective effects. It is known that DMF reduces oxidative stress related to neuronal death and myelin damage, via the Nrf2 pathway, making DMF a potential therapeutic option for progressive multiple sclerosis (Strassburger-Krogias *et al.*, 2014). INSPIRE was a phase III double-blind placebo controlled study (NCT02430532), designed to investigate whether DMF decreased progression of disability unrelated to relapses, in patients with SPMS. The sponsor has recently voluntarily terminated the study.

Masitinib is a selective tyrosine kinase inhibitor controlling mast cell degranulation, NO-mediated damage, and dendritic cell activity (Dubreuil *et al.*, 2009). An initial phase IIb clinical trial showed significant improvement in MSFC scores for patients with PPMS and SPMS compared to placebo. A randomized, double-blinded, placebo controlled phase IIb/III is under way in 600 patients with progressive forms of multiple sclerosis; it is expected to last 96 weeks, and to conclude in 2016 (NCT01433497).

Repairing tissue in progressive multiple sclerosis

Most of the hope for patients who have already suffered consequences of neurodegeneration rests on potential restorative therapies. LINGO1, a CNS-specific membrane glycoprotein that suppresses oligodendrocyte differentiation and myelination, is possibly involved in failure of remyelination and axonal repair in multiple sclerosis (Yong, 2009); blockade of this protein may therefore be effective in promoting remyelination in a clinical setting. In a preclinical study in EAE, LINGO1 blockade allowed activation of remyelination, and demonstrated significant axonal loss reduction (Mi *et al.*, 2007). BIIB033, a fully human monoclonal antibody that selectively antagonizes LINGO1, was found to be safe and well-tolerated in phase 1 studies (Tran *et al.*, 2014). RENEW (NCT01721161) is a randomized, double-blind, placebo-controlled, parallel-group study in healthy subjects with a first episode of unilateral acute optic neuritis. Although no changes were found on optical coherence tomography, the treated group showed improvement in optical nerve conduction latency at 24 weeks, compared to placebo, consistent with optical nerve remyelination (Cadavid *et al.*, 2016). A second phase II study (SYNERGY) is currently underway examining the effects of various doses of BIIB033 added to intramuscular IFNβ1a, versus placebo in RRMS and active SMPM patients. Data are expected for 2016 (NCT01244139; NCT01864148) (Tran *et al.*, 2014; Cadavid *et al.* 2015).

MD 1003 is an oral high-dose biotin formulation, currently under clinical development for progressive multiple sclerosis treatment. Preliminary data from an uncontrolled, non-blinded proof of concept study (Sedel *et al.*, 2015) suggest high doses of biotin may impact disability levels and progression. MS-SPI was a randomized, double blind, placebo-controlled trial of oral biotin (300 mg/day) in patients with SPMS and PPMS. Results at 12 months reported a fall in mean EDSS as well as stabilization of clinical global impression scale scores. The trial has been extended, currently switching the placebo group to active medication (Tourbah *et al.*, 2015, 2016). Results are expected before the end of the 2016.

The human monoclonal IgM antibody 22 (rHIgM22), usually present in serum of patients with multiple sclerosis,

Downloaded from https://academic.oup.com/brain/article/140/3/527/2447880 by guest on 26 April 2026

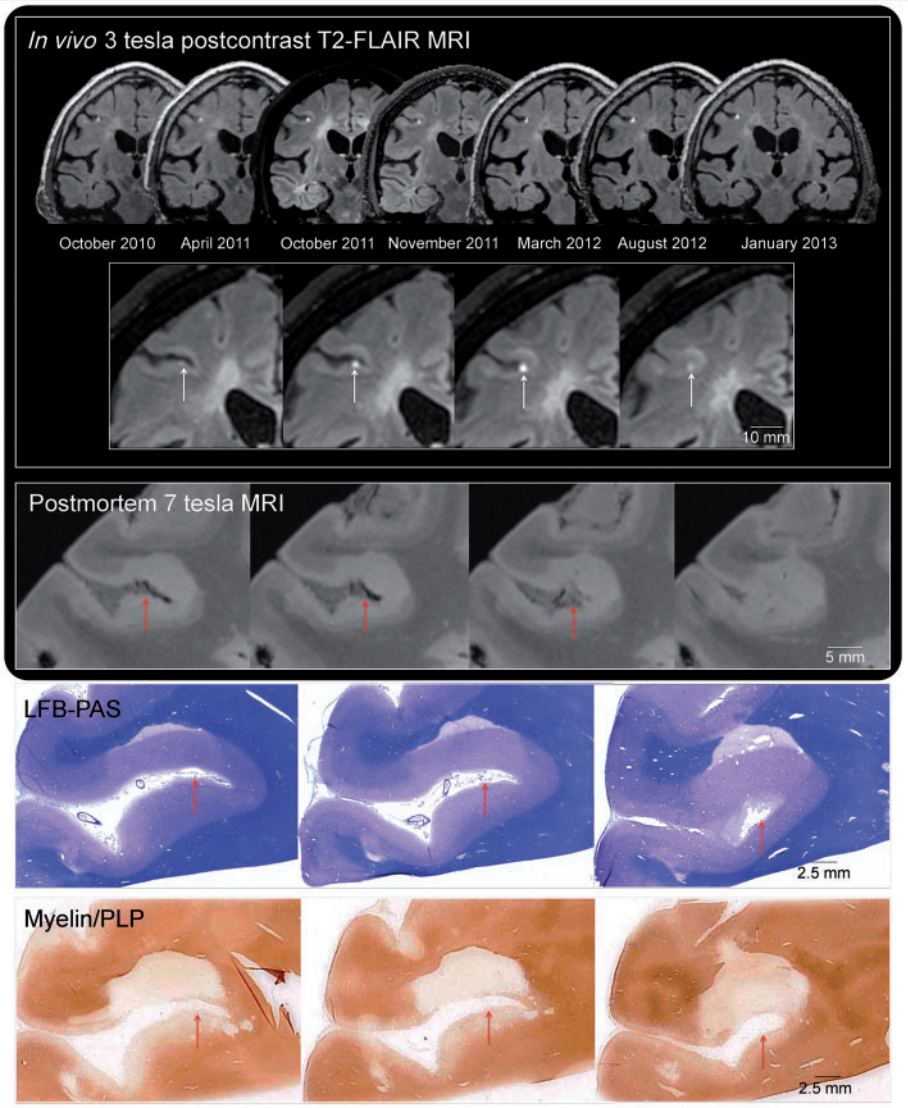

Figure 2 ***In vivo* 3 T post contrast T_2-FLAIR MRI.** The presence of stable focal leptomeningeal contrast enhancement in the right middle frontal sulcus is depicted in the seven available post-contrast T_2-FLAIR MRI scans (coronal reformations) acquired on different 3 T MRI scanners between 2010 and 2013. Leptomeningeal enhancement (white arrows) is located deep within the sulcus, adjacent to the cerebral cortex, and visible on four consecutive coronal 1-mm T_2-FLAIR sections (*inset*, representative scans from October 2011). The expected location of *in vivo* leptomeningeal enhancement is indicated with red arrows in the post-mortem MRI and histologic representative sections. Post-mortem 7 T MRI: extensive cortical and juxtacortical signal abnormality affects the brain parenchyma adjacent to the sulcus where leptomeningeal enhancement was detected *in vivo* [CISS (constructive interference in steady state) sequence, 150-mm isotropic voxel resolution, representative slices]. The cortical signal abnormality was not detected on *in vivo* MRI, although juxtacortical signal abnormality was noted. Myelin staining: *in vivo* and post-mortem MRI-guided histopathology allowed precise localization of the target area. Serial Luxol® fast blue-periodic acid-Schiff (LFB-PAS) staining and myelin/proteolipid protein (PLP) immunohistochemistry were performed every 100 mm (10-mm thick cryosections). Representative sections are well-matched to both *in vivo* and post-mortem MRI. Reproduced with permission from Absinta *et al.* (2015).

was able to induce spinal cord remyelination in different animal models of demyelination (Mitsunaga *et al.*, 2002). This effect is associated with anti-apoptotic signalling in oligodendrocyte precursor cells (Ciric *et al.*, 2004). Recently, data from the first phase I clinical trial were presented. Safety data showed it was well-tolerated at each of the five doses tested, supporting additional clinical development. Study tests also detected rHIgM22 in CFS, indicating the drug accesses the CNS.

Concluding remarks

Progressive multiple sclerosis is the greatest therapeutic challenge facing the multiple sclerosis community today. To develop new effective therapies for patients with multiple sclerosis, we need to elucidate and understand mechanisms involved in disease development, which may be multi-factorial. Unfortunately, incomplete understanding of pathogenesis of progressive multiple sclerosis, as well

Downloaded from https://academic.oup.com/brain/article/140/3/527/2447880 by guest on 26 April 2026

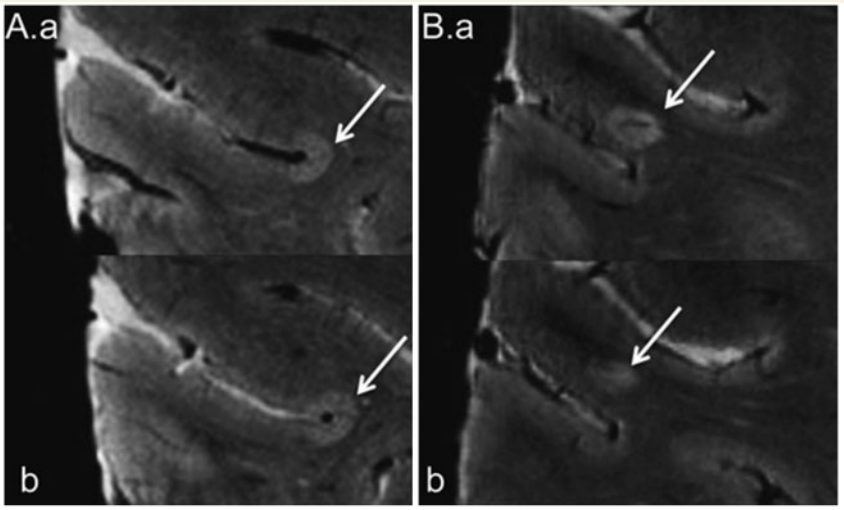

Figure 3 Axial FLASH-T_2* brain images at 7 T of a patient with multiple sclerosis. Consecutive slices demonstrate classic subpial (type III-IV; **A.a** and **b**) and leukocortical (type I; **B.a** and **b**) lesions (arrows). FLASH = fast low-angle shot. Reproduced with permission from Nielsen *et al.* (2013).

as absence of adequate animal models, make identification of potential target pathways and new treatment agents difficult. In patients with PPMS, modest slowing of disability progression is unlikely to be apparent, to patients or to their physicians, and outcomes of clinical trials would necessitate studying large numbers of patients over long periods of time. Additionally, patients with PPMS are older, and therefore more likely to present comorbidities typical of ageing, which can confound clinical measures, or directly affect disease course. Therefore, more sensitive methods of monitoring progressive multiple sclerosis are urgently needed. Clinical scales used in RRMS have unclear sensitivity in progressive multiple sclerosis, limiting their utility. In RRMS, phase II clinical trials rely on surrogate measures that are more sensitive to therapeutic effects than clinical measures. However, clear predictive surrogate markers do not exist in progressive multiple sclerosis. Potential options include novel MRI techniques, optical coherence tomography, and use of neurophysiology to measure conduction along multiple CNS pathways; all approaches that should be supplemented by CSF biomarkers. Use of surrogate disease indicators would increase clinical trial power, reduce duration and require less patients, all factors which would ultimately impact trial-related costs.

In this context, the most pragmatic use of data is prioritization of a known drug for repurposing—i.e. use for a purpose other than the one originally approved. Furthermore, because multiple mechanisms appear to trigger and sustain damage in progressive multiple sclerosis, combinatorial therapies may be required to put a stop to the various mechanisms causing damage and restore function to all systems. Overall, the use of more refined outcome measures and more efficient trial designs will increase possibilities of finding new therapeutic strategies for people suffering from progressive multiple sclerosis. Important goals for multiple sclerosis therapies also include reduction of symptom severity and improved quality of life. Therefore, a wide variety of symptomatic drugs and interventions, excellently reviewed elsewhere (Thompson *et al.*, 2010), can be of great benefit to patients with progressive multiple sclerosis. Finally, a new concept on treatment focus has been proposed: the management of modifiable factors. The presence of comorbidities was associated with an increased risk of disability progression in multiple sclerosis regardless of the time of diagnosis or disease course. For example, patients with multiple sclerosis with vascular comorbidities any time during their disease course progressed to an EDSS of 6 on average 6 years sooner than patients with multiple sclerosis who never had a vascular comorbidity (Marrie *et al.*, 2015). Thus, treatment of these comorbidities in patients with multiple sclerosis has the potential to improve disease course.

Note

While this article was in press, trial results expected from different studies to be reported in the near future were announced at the last ECTRIMS meeting (London, 14–17 September 2016): first, that the ORATORY study on ocrelizumab showed a 47% relative increase in no evidence of progression (NEP) compared to placebo. NEP is new composite endpoint to evaluate the proportion of PPMS patients with stable clinical disease. Second, data from Phase III of the EXPAND study indicated that siponimod delayed disability progression in patients with SPMS, reducing primary endpoint of time to confirmed disease progression (CDP) at 3 months by 21%, compared to placebo. Although analysis of several secondary endpoints is still ongoing, siponimod treatment reduced the risk of CDP at 6 months by 26%, the T_2 lesion volume by 79.1%, the annual relapse rate by 55%, and rate of whole brain volume loss by 23.4%, compared to placebo. The study

Downloaded from https://academic.oup.com/brain/article/140/3/527/2447880 by guest on 26 April 2026

showed no treatment benefit in an additional secondary endpoint, namely time to confirmed worsening of at least 20% from baseline in the timed 25-foot walk test. Finally, opicinumab (BIIB033), failed to meet primary or secondary endpoints in the phase II SYNERGY study.

Acknowledgement

The authors thank Dr Ismael Calandri for their collaboration in the design of the thumbnail image.

Funding

This work was supported by an internal grant from the Institute for Neurological Research Dr Raúl Carrea, FLENI (J.C.).

References

Absinta M, Sati P, Gaitan MI, Maggi P, Cortese IC, Filippi M, et al. Seven-tesla phase imaging of acute multiple sclerosis lesions: a new window into the inflammatory process. Ann Neurol 2013; 74: 669–78.

Absinta M, Vuolo L, Rao A, Nair G, Sati P, Cortese IC, et al. Gadolinium-based MRI characterization of leptomeningeal inflammation in multiple sclerosis. Neurology 2015; 85: 18–28.

Agosta F, Rovaris M, Pagani E, Sormani MP, Comi G, Filippi M. Magnetization transfer MRI metrics predict the accumulation of disability 8 years later in patients with multiple sclerosis. Brain 2006; 129 (Pt 10): 2620–7.

Al-Izki S, Pryce G, Hankey DJ, Lidster K, von Kutzleben SM, Browne L, et al. Lesional-targeting of neuroprotection to the inflammatory penumbra in experimental multiple sclerosis. Brain 2014; 137 (Pt 1): 92–108.

Aloisi F, Pujol-Borrell R. Lymphoid neogenesis in chronic inflammatory diseases. Nat Rev Immunol 2006; 6: 205–17.

Andersen O, Elovaara I, Färkkilä M, Hansen HJ, Mellgren SI, Myhr KM, et al. Multicentre, randomised, double blind, placebo controlled, phase III study of weekly, low dose, subcutaneous interferon beta-1a in secondary progressive multiple sclerosis. J Neurol Neurosurg Psychiatry 2004; 75:706–10.

Andersson PB, Waubant E, Gee L, Goodkin DE. Multiple sclerosis that is progressive from the time of onset: clinical characteristics and progression of disability. Ann Neurol 1999; 56: 1138–42.

Antel J, Antel S, Caramanos Z, Arnold DL, Kuhlmann T. Primary progressive multiple sclerosis: part of the MS disease spectrum or separate disease entity? Acta Neuropathol 2012; 123:627–38.

Antulov R, Weinstock-Guttman B, Cox JL, Hussein S, Durfee J, Caiola C, et al. Gender-related differences in MS: a study of conventional and nonconventional MRI measures. Mult Scler 2009; 15: 345–54.

Arnett HA, Mason J, Marino M, Suzuki K, Matsushima GK, Ting JP. TNF alpha promotes proliferation of oligodendrocyte progenitors and remyelination. Nat Neurosci 2001; 4: 1116–22.

Ascherio A, Munger KL. Epstein-barr virus infection and multiple sclerosis: a review. J Neuroimmune Pharmacol 2010; 5: 271–7.

Barnett MH, Prineas JW. Relapsing and remitting multiple sclerosis: pathology of the newly forming lesion. Ann Neurol 2004; 55: 458–68.

Bar-Or A, Fawaz L, Fan B, Darlington PJ, Rieger A, Ghorayeb C, et al. Abnormal B-cell cytokine responses a trigger of T-cell-mediated disease in MS? Ann Neurol 2010; 67: 452–61.

Bechtold DA, Kapoor R, Smith KJ. Axonal protection using flecainide in experimental autoimmune encephalomyelitis. Ann Neurol 2004; 55: 607–16.

Bechtold DA, Miller SJ, Dawson AC, Sun Y, Kapoor R, Berry D, et al. Axonal protection achieved in a model of multiple sclerosis using lamotrigine. J Neurol 2006; 253: 1542–51.

Bergendal G, Fredrikson S, Almkvist O. Selective decline in information processing in subgroups of multiple sclerosis: an 8-year longitudinal study. Eur Neurol 2007; 57:193–202.

Bitsch A, Schuchardt J, Bunkowski S, Kuhlmann T, Bruck W. Acute axonal injury in multiple sclerosis. Correlation with demyelination and inflammation. Brain 2000; 123 (Pt 6): 1174–83.

Black JA, Newcombe J, Trapp BD, Waxman SG. Sodium channel expression within chronic multiple sclerosis plaques. J Neuropathol Exp Neurol 2007; 66: 828–37.

Bo L, Vedeler CA, Nyland H, Trapp BD, Mork SJ. Intracortical multiple sclerosis lesions are not associated with increased lymphocyte infiltration. Mult Scler 2003a; 9: 323–31.

Bo L, Vedeler CA, Nyland HI, Trapp BD, Mork SJ. Subpial demyelination in the cerebral cortex of multiple sclerosis patients. J Neuropathol Exp Neurol 2003b; 62: 723–32.

Bonati U, Fisniku LK, Altmann DR, Yiannakas MC, Furby J, Thompson AJ, et al. Cervical cord and brain grey matter atrophy independently associate with long-term MS disability. J Neurol Neurosurg Psychiatry 2011; 82: 471–2.

Bramow S, Frischer JM, Lassmann H, Koch-Henriksen N, Lucchinetti CF, Sørensen PS, et al. Demyelination versus remyelination in progressive multiple sclerosis. Brain 2010; 133: 2983–98.

Bruck W, Pfortner R, Pham T, Zhang J, Hayardeny L, Piryatinsky V, et al. Reduced astrocytic NF-kappaB activation by laquinimod protects from cuprizone-induced demyelination. Acta Neuropathol 2012; 124: 411–24.

Buttmann M. Treating multiple sclerosis with monoclonal antibodies: a 2010 update. Expert Rev Neurother 2010; 10: 791–809.

Cadavid D, Keith E, Hupperts R, Drulovic J, Selmaj K, Naismith R, et al. BIIBo33, anti-LINGO treatment of relapsing-remitting Multiple Sclerosis: Basal data of the Phase 2 SYNERGY Trial. Neurology 2015; 84 (14 Suppl): P7204.

Cadavid D, Klistorner A, Leocani L, Aktas O, Butzkueven H, Ziemssen F, et al. Evidence that the Anti-Lingo-1 monoclonal antibody BIIBo33protects against multifocal visual evoked potential amplitud loss in the fellow eye of subjects with unilateral acute optic neuritis. Neurology 2016; 86 (16 Suppl): I10.009.

Camp SJ, Stevenson VL, Thompson AJ, Miller DH, Borras C, Auriacombe S, et al. Cognitive function in primary progressive and transitional progressive multiple sclerosis. A controlled study with MRI correlates. Brain 1999; 122:1341–8.

Campbell GR, Worrall JT, Mahad DJ. The central role of mitochondria in axonal degeneration in multiple sclerosis. Mult Scler 2014; 20: 1806–13.

Campbell GR, Ziabreva I, Reeve AK, Krishnan KJ, Reynolds R, Howell O, et al. Mitochondrial DNA deletions and neurodegeneration in multiple sclerosis. Ann Neurol 2011; 69: 481–92.

Caruso A, DiGiorgi Gerevini V, Castiglione M, Marinelli F, Tomassini V, Pozzilli C, et al. Testosterone amplifies excitotoxic damage of cultured oligodendrocytes. Neurochem 2004; 88: 1179–85.

Castillo-Trivino T, Braithwaite D, Bacchetti P, Waubant E. Rituximab in relapsing and progressive forms of multiple sclerosis: a systematic review. PloS One 2013; 8: e66308.

Choi SR, Howell OW, Carassiti D, Magliozzi R, Gveric D, Muraro PA, et al. Meningeal inflammation plays a role in the pathology of primary progressive multiple sclerosis. Brain 2012; 135 (Pt 10): 2925–37.

Ciric B, Van Keulen V, Paz Soldan M, Rodriguez M, Pease LR. Antibody-mediated remyelination operates through mechanism

Downloaded from https://academic.oup.com/brain/article/140/3/527/2447880 by guest on 26 April 2026

independent of immunomodulation. J Neuroimmunol 2004; 146: 153–61.
Cohen JA, Cutter GR, Fischer JS, Goodman AD, Heidenreich FR, Kooijmans MF, et al. Benefit of interferon beta-1a on MSFC progression in secondary progressive MS. Neurology 2002; 59: 679–87.
Cohen JA, Rudick RA. Multiple Sclerosis Therapeutics. Cambridge: Cambridge University Press; 2011.
Confavreux C, Vukusic S. Natural history of multiple sclerosis: a unifying concept. Brain 2006; 129 (Pt 3): 606–16.
Correale J. The role of microglial activation in disease progression. Mult Scler 2014; 20: 1288–95.
Correale J, Farez MF. The role of astrocytes in multiple sclerosis progression. Front Neurol 2015; 6: 180.
Corsiero E, Bombardieri M, Manzo A, Bugatti S, Uguccioni M, Pitzalis C. Role of lymphoid chemokines in the development of functional ectopic lymphoid structures in rheumatic autoimmune diseases. Immunol Lett 2012; 145: 62–7.
Cottrell DA, Kremenchutzky M, Rice GP, Koopman WJ, Hader W, Baskerville J, et al. The natural history of multiple sclerosis: a geographically based study. 5. The clinical features and natural history of primary progressive multiple sclerosis. Brain 1999; 122 (Pt 4): 625–39.
Cutter WJ, Daly EM, Robertson DM, Chitnis XA, van Amelsvoort TA, Simmons A,et al. Influence of X chromosome and hormones on human brain development: a magnetic resonance imaging and proton magnetic resonance spectroscopy study of Turner syndrome. Biol Psychiatry 2006; 59: 273–83.
Davies AL, Desai RA, Bloomfield PS, McIntosh PR, Chapple KJ, Linington C, et al. Neurological deficits caused by tissue hypoxia in neuroinflammatory disease. Ann Neurol 2013; 74: 815–25.
De Groot CJ, Bergers E, Kamphorst W, Ravid R, Polman CH, Barkhof F, et al. Post-mortem MRI-guided sampling of multiple sclerosis brain lesions: increased yield of active demyelinating and (p)reactive lesions. Brain 2001; 124 (Pt 8): 1635–45.
De Stefano N, Giorgio A, Battaglini M, Rovaris M, Sormani MP, Barkhof F, et al. Assessing brain atrophy rates in a large population of untreated multiple sclerosis subtypes. Neurology 2010; 74: 1868–76.
Di Pardo A, Amico E, Favellato M, Castrataro R, Fucile S, Squitieri F, et al. FTY720 (fingolimod) is a neuroprotective and disease-modifying agent in cellular and mouse models of Huntington disease. Hum Mol Genet 2014; 23: 2251–65.
Dubreuil P, Letard S, Ciufolini M, Gros L, Humbert M, Casteran N, et al. Masitinib (AB1010), a potent and selective tyrosine kinase inhibitor targeting KIT. PloS One 2009; 4: e7258.
Dutta R, Trapp BD. Pathogenesis of axonal and neuronal damage in multiple sclerosis. Neurology 2007; 68 (22 Suppl 3):S22–31
Dutta R, Trapp BD. Relapsing and progressive forms of multiple sclerosis: insights from pathology. Curr Opin Neurol 2014; 27: 271–8.
European Study Group on interferon-beta 1b in secondary porgressive MS. Placebo controlled multicenter randomized trial of interferon-beta 1b in treatment of secondary porgressive multiple sclerosis. Lancet 1998; 352:1491–97
Farez MF, Correale J. Sphingosine 1-phosphate signaling in astrocytes: implications for progressive multiple sclerosis. J Neurol Sci 2016; 361: 60–5.
Feng J, Misu T, Fujihara K, Sakoda S, Nakatsuji Y, Fukaura H, et al. Ibudilast, a nonselective phosphodiesterase inhibitor, regulates Th1/Th2 balance and NKT cell subset in multiple sclerosis. Mult Scler 2004; 10: 494–8.
Filippi M, Campi A, Martinelli V, Colombo B, Yousry T, Canal N, et al. Comparison of triple dose versus standard dose gadolinium-DTPA for detection of MRI enhancing lesions in patients with primary progressive multiple sclerosis. J Neurol Neurosurg Psychiatry 1995; 59: 540–4.
Filippi M, Cercignani M, Inglese M, Horsfield MA, Comi G. Diffusion tensor magnetic resonance imaging in multiple sclerosis. Neurology 2001; 56: 304–11.
Fischer MT, Wimmer I, Hoftberger R, Gerlach S, Haider L, Zrzavy T, et al. Disease-specific molecular events in cortical multiple sclerosis lesions. Brain 2013; 136(Pt 6): 1799–815.
Fisher E, Lee JC, Nakamura K, Rudick RA. Gray matter atrophy in multiple sclerosis: a longitudinal study. Ann Neurol 2008; 64: 255–65.
Fisniku LK, Chard DT, Jackson JS, Anderson VM, Altman DR, Miszkiel KA, et al. Gray matter atrophy is related to long-term disability in multiple sclerosis. Ann Neurol 2008; 64: 247–54.
Frank JA, Richert N, Lewis B, Bash C, Howard T, Civil R, et al. A pilot study of recombinant insulin-like growth factor-1 in seven multiple sderosis patients. Mult Scler 2002; 8: 24–9.
Friese MA, Craner MJ, Etzensperger R, Vergo S, Wemmie JA, Welsh MJ, et al. Acid-sensing ion channel-1 contributes to axonal degeneration in autoimmune inflammation of the central nervous system. Nat Med 2007; 13: 1483–9.
Friese MA, Schattling B, Fugger L. Mechanisms of neurodegeneration and axonal dysfunction in multiple sclerosis. Nat Rev Neurol 2014; 10: 225–38.
Frischer JM, Bramow S, Dal-Bianco A, Lucchinetti CF, Rauschka H, Schmidbauer M, et al. The relation between inflammation and neurodegeneration in multiple sclerosis brains. Brain 2009; 132(Pt 5): 1175–89.
Fu L, Matthews PM, De Stefano N, Worsley KJ, Narayanan S, Francis GS, et al. Imaging axonal damage of normal-appearing white matter in multiple sclerosis. Brain 1998; 121 (Pt 1): 103–13.
Geurts JJ, Barkhof F. Grey matter pathology in multiple sclerosis. Lancet Neurol 2008; 7: 841–51.
Geurts JJ, Bo L, Pouwels PJ, Castelijns JA, Polman CH, Barkhof F. Cortical lesions in multiple sclerosis: combined postmortem MR imaging and histopathology. AJNR Am J Neuroradiol 2005; 26: 572–7.
Geurts JJ, Roosendaal SD, Calabrese M, Ciccarelli O, Agosta F, Chard DT, et al. Consensus recommendations for MS cortical lesion scoring using double inversion recovery MRI. Neurology 2011; 76: 418–24.
Giuliani F, Goodyer CG, Antel JP, Yong VW. Vulnerability of human neurons to T cell-mediated cytotoxicity. J Immunol 2003; 171: 368–79.
Goodin DS, Arnason BG, Coyle PK, Frohman EM, Paty DW. The use of mitoxantrone (Novantrone) for the treatment of multiple sclerosis: report of the Therapeutics and Technology Assessment Subcommittee of the American Academy of Neurology. Neurology 2003; 61: 1332–8.
Grossman RI, Gonzalez-Scarano F, Atlas SW, Galetta S, Silberberg DH. Multiple sclerosis: gadolinium enhancement in MR imaging. Radiology 1986; 161: 721–5.
Haider L, Fischer MT, Frischer JM, Bauer J, Hoftberger R, Botond G, et al. Oxidative damage in multiple sclerosis lesions. Brain 2011; 134 (Pt 7): 1914–24.
Hametner S, Wimmer I, Haider L, Pfeifenbring S, Bruck W, Lassmann H. Iron and neurodegeneration in the multiple sclerosis brain. Ann Neurol 2013; 74: 848–61.
Harris JO, Frank JA, Patronas N, McFarlin DE, McFarland HF. Serial gadolinium-enhanced magnetic resonance imaging scans in patients with early, relapsing-remitting multiple sclerosis: implications for clinical trials and natural history. Ann Neurol 1991; 29: 548–55.
Harrison DM, Oh J, Roy S, Wood ET, Whetstone A, Seigo MA, et al. Thalamic lesions in multiple sclerosis by 7T MRI: clinical implications and relationship to cortical pathology. Mult Scler 2015; 21: 1139–50.
Hartung HP, Gonsette R, Konig N, Kwiecinski H, Guseo A, Morrissey SP, et al. Mitoxantrone in progressive multiple sclerosis: a placebo-controlled, double-blind, randomised, multicentre trial. Lancet 2002; 360: 2018–25.
Hauser SL, Oksenberg JR. The neurobiology of multiple sclerosis: genes, inflammation, and neurodegeneration. Neuron 2006; 52: 61–76.

Downloaded from https://academic.oup.com/brain/article/140/3/527/2447880 by guest on 26 April 2026

Hawker K, O'Connor P, Freedman MS, Calabresi PA, Antel J, Simon J, et al. Rituximab in patients with primary progressive multiple sclerosis: results of a randomized double-blind placebo-controlled multicenter trial. Ann Neurol 2009; 66: 460–71.

Hayton T, Furby J, Smith KJ, Altmann DR, Brenner R, Chataway J, et al. Longitudinal changes in magnetisation transfer ratio in secondary progressive multiple sclerosis: data from a randomised placebo controlled trial of lamotrigine. J Neurol 2012; 259: 505–14.

Hislop AD, Taylor GS, Sauce D, Rickinson AB. Cellular responses to viral infection in humans: lessons from Epstein-Barr virus. Annu Rev Immunol 2007; 25: 587–617.

Hochmeister S, Grundtner R, Bauer J, Engelhardt B, Lyck R, Gordon G, et al. Dysferlin is a new marker for leaky brain blood vessels in multiple sclerosis. J Neuropathol Exp Neurol 2006; 65: 855–65.

Hohlfeld R. Neurotrophic cross-talk between the nervous and immune systems: relevance for repair strategies in multiple sclerosis? J Neurol Sci 2008; 265: 93–6.

Howell OW, Reeves CA, Nicholas R, Carassiti D, Radotra B, Gentleman SM, et al. Meningeal inflammation is widespread and linked to cortical pathology in multiple sclerosis. Brain 2011; 134 (Pt 9): 2755–71.

Huse M, Quann EJ, Davis MM. Shouts, whispers and the kiss of death: directional secretion in T cells. Nat Immunol 2008; 9: 1105–11.

Hutchinson M. Neurodegeneration in multiple sclerosis is a process separate from inflammation: no. Mult Scler 2015; 21: 1628–31.

Inglese M, Oesingmann N, Casaccia P, Fleysher L. Progressive multiple sclerosis and gray matter pathology: an MRI perspective. Mt Sinai J Med 2011; 78: 258–67.

Kalinowska-Lyszczarz A, Losy J. The role of neurotrophins in multiple sclerosis-pathological and clinical implications. Int J Mol Sci 2012; 13: 13713–25.

Kantarci OH, Lebrun C, Siva A, Keegan MB, Azevedo CJ, Inglese M, et al. Primary progressive MS evolving from radiologically isolated syndrome. Ann Neurol 2016; 79: 288–94.

Kassmann CM, Lappe-Siefke C, Baes M, Brugger B, Mildner A, Werner HB, et al. Axonal loss and neuroinflammation caused by peroxisome-deficient oligodendrocytes. Nat Genet 2007; 39: 969–76.

Katz Sand I, Krieger S, Farrell C, Miller AE. Diagnostic uncertainty during the transition to secondary progressive multiple sclerosis. Mult Scler 2014; 20: 1654–7.

Kearney H, Altmann DR, Samson RS, Yiannakas MC, Wheeler-Kingshott CA, Ciccarelli O, et al. Cervical cord lesion load is associated with disability independently from atrophy in MS. Neurology 2015; 84: 367–73.

Killestein J, Rudick RA, Polman CH. Oral treatment for multiple sclerosis. Lancet Neurol 2011; 10: 1026–34.

Kornek B Storch MK, Weissert R, Wallstroem E, Stefferl A, Olsson T, et al. Multiple sclerosis and chronic autoimmune encephalomyelitis: a comparative quantitative study of axonal injury in active, inactive, and remyelinated lesions. Am J Pathol 2000; 157: 267–76.

Kotter MR, Setzu A, Sim FJ, Van Rooijen N, Franklin RJ. Macrophage depletion impairs oligodendrocyte remyelination following lysolecithin-induced demyelination. Glia 2001; 35: 204–12.

Kremenchutzky M, Cottrell D, Rice G, Hader W, Baskerville J, Koopman W, et al. The natural history of multiple sclerosis: a geographically based study. 7. Progressive-relapsing and relapsing-progressive multiple sclerosis: a re-evaluation. Brain 1999; 122 (Pt 10): 1941–50.

Kremenchutzky M, Rice GP, Baskerville J, Wingerchuk DM, Ebers GC. The natural history of multiple sclerosis: a geographically based study 9: observations on the progressive phase of the disease. Brain 2006; 129 (Pt 3): 584–94.

Kuenz B, Lutterotti A, Ehling R, Gneiss C, Haemmerle M, Rainer C, et al. Cerebrospinal fluid B cells correlate with early brain inflammation in multiple sclerosis. PloS One 2008; 3: e2559.

Kutzelnigg A, Lucchinetti CF, Stadelmann C, Bruck W, Rauschka H, Bergmann M, et al. Cortical demyelination and diffuse white matter injury in multiple sclerosis. Brain 2005; 128 (Pt 11): 2705–12.

Lassmann H. Multiple sclerosis: lessons from molecular neuropathology. Exp Neurol 2014; 262 (Pt A): 2–7.

Lassmann H, Bruck W, Lucchinetti CF. The immunopathology of multiple sclerosis: an overview. Brain Pathol 2007; 17: 210–8.

Leary SM, Miller DH, Stevenson VL, Brex PA, Chard DT, Thompson AJ. Interferon beta-1a in primary progressive MS: an exploratory, randomized, controlled trial. Neurology 2003; 60: 44–51.

Louapre C, Lubetzki C. Neurodegeneration in multiple sclerosis is a process separate from inflammation: yes. Mult Scler 2015; 21: 1626–8.

Lovato L, Willis SN, Rodig SJ, Caron T, Almendinger SE, Howell OW, et al. Related B cell clones populate the meninges and parenchyma of patients with multiple sclerosis. Brain 2011; 134 (Pt 2): 534–41.

Lublin F, Miller DH, Freedman MS, Cree BA, Wolinsky JS, Weiner H, et al. Oral fingolimod in primary progressive multiple sclerosis (INFORMS): a phase 3, randomised, double-blind, placebo-controlled trial. Lancet 2016; 387: 1075–84.

Lublin FD, Baier M, Cutter G. Effect of relapses on development of residual deficit in multiple sclerosis. Neurology 2003; 61: 1528–32.

Lublin FD, Reingold SC. Defining the clinical course of multiple sclerosis: results of an international survey. National Multiple Sclerosis Society (USA) Advisory Committee on Clinical Trials of New Agents in Multiple Sclerosis. Neurology 1996; 46: 907–11.

Lublin FD, Reingold SC, Cohen JA, Cutter GR, Sorensen PS, Thompson AJ, et al. Defining the clinical course of multiple sclerosis: the 2013 revisions. Neurology 2014; 83: 278–86.

Lucchinetti CF, Popescu BF, Bunyan RF, Moll NM, Roemer SF, Lassmann H, et al. Inflammatory cortical demyelination in early multiple sclerosis. N Engl J Med 2011; 365:2188–97.

Lugaresi A, Caporale C, Farina D, Marzoli F, Bonanni L, Muraro PA, et al. Low-dose oral methotrexate treatment in chronic progressive multiple sclerosis. Neurol Sci 2001; 22: 209–10.

Lycklama G, Thompson A, Filippi M, Miller D, Polman C, Fazekas F, et al. Spinal-cord MRI in multiple sclerosis. Lancet Neurol 2003; 2: 555–62.

Magliozzi R, Howell O, Vora A, Serafini B, Nicholas R, Puopolo M, et al. Meningeal B-cell follicles in secondary progressive multiple sclerosis associate with early onset of disease and severe cortical pathology. Brain 2007; 130 (Pt 4): 1089–104.

Magliozzi R, Howell OW, Reeves C, Roncaroli F, Nicholas R, Serafini B, et al. A Gradient of neuronal loss and meningeal inflammation in multiple sclerosis. Ann Neurol 2010; 68: 477–93.

Magliozzi R, Serafini B, Rosicarelli B, Chiappetta G, Veroni C, Reynolds R, et al. B-cell enrichment and Epstein-Barr virus infection in inflammatory cortical lesions in secondary progressive multiple sclerosis. J Neuropathol Exp Neurol 2013; 72: 29–41.

Mahad DJ, Ziabreva I, Campbell G, Lax N, White K, Hanson PS, et al. Mitochondrial changes within axons in multiple sclerosis. Brain 2009; 132 (Pt 5): 1161–74.

Mainero C, Louapre C, Govindarajan ST, Gianni C, Nielsen AS, Cohen-Adad J, et al. A gradient in cortical pathology in multiple sclerosis by *in vivo* quantitative 7 T imaging. Brain 2015; 138(Pt 4): 932–45.

Marrie RA, Reider N, Cohen J, Stuve O, Trojano M, Cutter G, et al. A systematic review of the incidence and prevalence of cardiac, cerebrovascular, and peripheral vascular disease in multiple sclerosis. Mult Scler 2015; 21: 318–31.

Matute C, Sanchez-Gomez MV, Martinez-Millan L, Miledi R. Glutamate receptor-mediated toxicity in optic nerve oligodendrocytes. Proc Natl Acad Sci USA 1997; 94: 8830–5.

Mayo L, Trauger SA, Blain M, Nadeau M, Patel B, Alvarez JI, et al. Regulation of astrocyte activation by glycolipids drives chronic CNS inflammation. Nat Med 2014; 20: 1147–56.

Downloaded from https://academic.oup.com/brain/article/140/3/527/2447880 by guest on 26 April 2026

McFarland HF, Martin R. Multiple sclerosis: a complicated picture of autoimmunity. Nat Immunol 2007; 8: 913–9.

Medana IM, Gallimore A, Oxenius A, Martinic MM, Wekerle H, Neumann H. MHC class I-restricted killing of neurons by virus-specific CD8+ T lymphocytes is effected through the Fas/FasL, but not the perforin pathway. Eur J Immunol 2000; 30: 3623–33.

Meuth SG, Herrmann AM, Simon OJ, Siffrin V, Melzer N, Bittner S, et al. Cytotoxic CD8+ T cell-neuron interactions: perforin-dependent electrical silencing precedes but is not causally linked to neuronal cell death. J Neurosci 2009; 29: 15397–409.

Meuth SG, Simon OJ, Grimm A, Melzer N, Herrmann AM, Spitzer P, et al. CNS inflammation and neuronal degeneration is aggravated by impaired CD200-CD200R-mediated macrophage silencing. J Neuroimmunol 2008; 194: 62–9.

Mi S, Hu B, Hahm K, Luo Y, Kam Hui ES, Yuan Q, et al. LINGO-1 antagonist promotes spinal cord remyelination and axonal integrity in MOG-induced experimental autoimmune encephalomyelitis. Nat Med 2007; 13: 1228–33.

Mishra MK, Wang J, Keough MB, Fan Y, Silva C, Sloka S, et al. Laquinimod reduces neuroaxonal injury through inhibiting microglial activation. Ann Clin Transl Neurol 2014; 1: 409–22.

Mitsunaga Y, Ciric B, Van Keulen V, Warrington AE, Paz Soldan M, Bieber AJ, et al. Direct evidence that a human antibody derived from patient serum can promote myelin repair in a mouse model of chronic-progressive demyelinating disease. FASEB J 2002; 16: 1325–7.

Mizuno T, Zhang G, Takeuchi H, Kawanokuchi J, Wang J, Sonobe Y, et al. Interferon-gamma directly induces neurotoxicity through a neuron specific, calcium-permeable complex of IFN-gamma receptor and AMPA GluR1 receptor. FASEB J 2008; 22: 1797–806.

Moll NM, Rietsch AM, Thomas S, Ransohoff AJ, Lee JC, Fox R, et al. Multiple sclerosis normal-appearing white matter: pathology-imaging correlations. Ann Neurol 2011; 70: 764–73.

Montalban X, Sastre-Garriga J, Tintore M, Brieva L, Aymerich FX, Rio J, et al. A single-center, randomized, double-blind, placebo-controlled study of interferon beta-1b on primary progressive and transitional multiple sclerosis. Mult Scler 2009; 15: 1195–205.

Murphy MP. How mitochondria produce reactive oxygen species. Biochem J 2009; 417: 1–13.

Nicholls DG. Mitochondrial dysfunction and glutamate excitotoxicity studied in primary neuronal cultures. Curr Mol Med 2004; 4: 149–77.

Nielsen AS, Kinkel RP, Madigan N, Tinelli E, Benner T, Mainero C. Contribution of cortical lesion subtypes at 7T MRI to physical and cognitive performance in MS. Neurology 2013; 81: 641–9.

Nikic I, Merkler D, Sorbara C, Brinkoetter M, Kreutzfeldt M, Bareyre FM, et al. A reversible form of axon damage in experimental autoimmune encephalomyelitis and multiple sclerosis. Nat Med 2011; 17: 495–9.

Ontaneda D, Fox RJ, Chataway J. Clinical trials in progressive multiple sclerosis: lessons learned and future perspectives. Lancet Neurol 2015; 14: 208–23.

Ouardouz M, Coderre E, Basak A, Chen A, Zamponi GW, Hameed S, et al. Glutamate receptors on myelinated spinal cord axons: I. GluR6 kainate receptors. Ann Neurol 2009; 65: 151–9.

Pagani E, Rocca MA, Gallo A, Rovaris M, Martinelli V, Comi G, et al. Regional brain atrophy evolves differently in patients with multiple sclerosis according to clinical phenotype. AJNR Am J Neuroradiol 2005; 26: 341–6.

Panitch H, Miller A, Paty D, Weinshenker B; North American Study Group onInterferon beta-1b in Secondary Progressive MS. Interferon beta-1b in secondary progressive MS: results from a 3-year controlled study. Neurology 2004; 63:1788–95.

Paolillo A, Coles AJ, Molyneux PD, Gawne-Cain M, MacManus D, Barker GJ, et al. Quantitative MRI in patients with secondary progressive MS treated with monoclonal antibody Campath 1H. Neurology 1999; 53: 751–7.

Pardridge WM. Neurotrophins, neuroprotection and the blood-brain barrier. Curr Opin Investig Drugs 2002; 3: 1753–7.

Peterson JW, Bo L, Mork S, Chang A, Trapp BD. Transected neurites, apoptotic neurons, and reduced inflammation in cortical multiple sclerosis lesions. Ann Neurol 2001; 50: 389–400.

Pitt D, Boster A, Pei W, Wohleb E, Jasne A, Zachariah CR, et al. Imaging cortical lesions in multiple sclerosis with ultra-high-field magnetic resonance imaging. Arch Neurol 2010; 67: 812–8.

Pitt D, Werner P, Raine CS. Glutamate excitotoxicity in a model of multiple sclerosis. Nat Med 2000; 6: 67–70.

Polman CH, Reingold SC, Banwell B, Clanet M, Cohen JA, Filippi M, et al. Diagnostic criteria for multiple sclerosis: 2010 revisions to the McDonald criteria. Ann Neurol 2011; 69: 292–302.

Popescu BF, Lucchinetti CF. Meningeal and cortical grey matter pathology in multiple sclerosis. BMC Neurol 2012; 12: 11.

Pradat PF, Kennel P, Naimi-Sadaoui S, Finiels F, Orsini C, Revah F, et al. Continuous delivery of neurotrophin 3 by gene therapy has a neuroprotective effect in experimental models of diabetic and acrylamide neuropathies. Hum Gene Ther 2001; 12: 2237–49.

Preziosa P, Rocca MA, Mesaros S, Pagani E, Stosic-Opincal T, Kacar K, et al. Intrinsic damage to the major white matter tracts in patients with different clinical phenotypes of multiple sclerosis: a voxelwise diffusion-tensor MR study. Radiology 2011; 260: 541–50.

Rice CM, Cottrell D, Wilkins A, Scolding NJ. Primary progressive multiple sclerosis: progress and challenges. J Neurol Neurosurg Psychiatry 2013; 84: 1100–6.

Revesz T, Kidd D, Thompson AJ, Barnard RO, McDonald WI. A comparison of the pathology of primary and secondary progressive multiple sclerosis. Brain 1994; 117 (Pt 4): 759–65.

Rossi S, Motta C, Studer V, Barbieri F, Buttari F, Bergami A, et al. Tumor necrosis factor is elevated in progressive multiple sclerosis and causes excitotoxic neurodegeneration. Mult Scler 2014; 20: 304–12.

Rovaris M, Confavreux C, Furlan R, Kappos L, Comi G, Filippi M. Secondary progressive multiple sclerosis: current knowledge and future challenges. Lancet Neurol 2006; 5: 343–54.

Sbardella E, Greco A, Stromillo ML, Prosperini L, Puopolo M, Cefaro LA, et al. Isoprostanes in clinically isolated syndrome and early multiple sclerosis as biomarkers of tissue damage and predictors of clinical course. Mult Scler 2013; 19: 411–7.

Scalfari A, Neuhaus A, Degenhardt A, Rice GP, Muraro PA, Daumer M, et al. The natural history of multiple sclerosis: a geographically based study 10: relapses and long-term disability. Brain 2010; 133 (Pt 7): 1914–29.

Schattling B, Steinbach K, Thies E, Kruse M, Menigoz A, Ufer F, et al. TRPM4 cation channel mediates axonal and neuronal degeneration in experimental autoimmune encephalomyelitis and multiple sclerosis. Nat Med 2012; 18: 1805–11.

Schlaeger R, Papinutto N, Panara V, Bevan C, Lobach IV, Bucci M, et al. Spinal cord gray matter atrophy correlates with multiple sclerosis disability. Ann Neurol 2014; 76: 568–80.

Schlaeger R, Papinutto N, Zhu AH, Lobach IV, Bevan CJ, Bucci M, et al. Association between thoracic spinal cord gray matter atrophy and disability in multiple sclerosis. JAMA Neurol 2015; 72: 897–904.

Schmierer K, Scaravilli F, Altmann DR, Barker GJ, Miller DH. Magnetization transfer ratio and myelin in postmortem multiple sclerosis brain. Ann Neurol 2004; 56: 407–15.

Schwartzman RJ, Simpkins N, Alexander GM, Reichenberger E, Ward K, Lindenberg N, et al. High-dose cyclophosphamide in the treatment of multiple sclerosis. CNS Neurosci Ther 2009; 15: 118–27.

Scolding N, Franklin R. Axon loss in multiple sclerosis. Lancet 1998; 352: 340–1.

Sedel F, Bernard D, Mock DM, Tourbah A. Targeting demyelination and virtual hypoxia with high-dose biotin as a treatment for progressive multiple sclerosis. Neuropharmacology 2015 Sep 5. doi:1016/j.neuropharm.2015.08.028 [Epub ahead of print].

Downloaded from https://academic.oup.com/brain/article/140/3/527/2447880 by guest on 26 April 2026

Serafini B, Rosicarelli B, Magliozzi R, Stigliano E, Aloisi F. Detection of ectopic B-cell follicles with germinal centers in the meninges of patients with secondary progressive multiple sclerosis. Brain Pathol 2004; 14: 164–74.

Sethi V, Muhlert N, Ron M, Golay X, Wheeler-Kingshott CA, Miller DH, et al. MS cortical lesions on DIR: not quite what they seem? PloS One 2013; 8: e78879.

Silver NC, Tofts PS, Symms MR, Barker GJ, Thompson AJ, Miller DH. Quantitative contrast-enhanced magnetic resonance imaging to evaluate blood-brain barrier integrity in multiple sclerosis: a preliminary study. Mult Scler 2001; 7: 75–82.

Smith KJ, Kapoor R, Hall SM, Davies M. Electrically active axons degenerate when exposed to nitric oxide. Ann Neurol 2001; 49: 470–6.

Secondary Progressive Efficacy Clinical Trial of Recombinant Interferon-Beta-1a in MS (SPECTRIMS) Study Group. Randomized controlled trial of interferon- beta-1a in secondary progressive MS: clinical results. Neurology 2001; 56: 1496–504.

Stevenson VL, Miller DH, Rovaris M, Barkhof F, Brochet B, Dousset V, et al. Primary and transitional progressive MS: a clinical and MRI cross-sectional study. Neurology 1999; 52: 839–45.

Strassburger-Krogias K, Ellrichmann G, Krogias C, Altmeyer P, Chan A, Gold R. Fumarate treatment in progressive forms of multiple sclerosis: first results of a single-center observational study. Ther Adv Neurol Disord 2014; 7: 232–8.

Stys PK. General mechanisms of axonal damage and its prevention. J Neurol Sci 2005; 233: 3–13.

Suhy J, Rooney WD, Goodkin DE, Capizzano AA, Soher BJ, Maudsley AA, et al. 1H MRSI comparison of white matter and lesions in primary progressive and relapsing-remitting MS. Mult Scler 2000; 6: 148–55.

Suzumura A, Ito A, Mizuno T. Phosphodiesterase inhibitors suppress IL-12 production with microglia and T helper 1 development. Mult Scler 2003; 9: 574–8.

Tagge I, O'Connor A, Chaudhary P, Pollaro J, Berlow Y, Chalupsky M, et al. Spatio-temporal patterns of demyelination and remyelination in the cuprizone mouse model. PLoS One 2016; 11:e0152480

Thompson AJ, Kermode AG, MacManus DG, Kendall BE, Kingsley DP, Moseley IF, et al. Patterns of disease activity in multiple sclerosis: clinical and magnetic resonance imaging study. BMJ 1990a; 300: 631–4.

Thompson AJ, Miller DH, MacManus DG, McDonald WI. Patterns of disease activity in multiple sclerosis. BMJ 1990b; 301: 44–5.

Thompson AJ, Toosy AT, Ciccarelli O. Pharmacological management of symptoms in multiple sclerosis: current approaches and future directions. Lancet Neurol 2010; 9: 1182–99.

Tourbah A, Lebrun-Frenay C, Edan G, Clanet M, Papex C, Vukusic S, et al. 233 MD1003 (high doses of biotin) in progressive multiple sclerosis: subgroup analyses of the MS-SPI trial. Mult Scler J 2015; 21: (S11) 784.

Tourbah A, Lebrun-Frenay C, Edan G, Clanet M, Papex C, Vukusic S, et al. 24-Month-treatment with-MD1003 (high doses of Biotin) in progressive multiple sclerosis: results of the MS-SPI trial extension phase. Neurology 2016; 86: Suppl S49.004

Traboulsee A, Dehmeshki J, Peters KR, Griffin CM, Brex PA, Silver N, et al. Disability in multiple sclerosis is related to normal appearing brain tissue MTR histogram abnormalities. Mult Scler 2003; 9: 566–73.

Tran JQ, Rana J, Barkhof F, Melamed I, Gevorkyan H, Wattjes MP, et al. Randomized phase I trials of the safety/tolerability of anti-LINGO-1 monoclonal antibody BIIB033. Neurol Neuroimmunol Neuroinflamm 2014; 1: e18.

Trapp BD, Nave KA. Multiple sclerosis: an immune or neurodegenerative disorder? Annu Rev Neurosci 2008; 31: 247–69.

Trapp BD, Peterson J, Ransohoff RM, Rudick R, Mork S, Bo L. Axonal transection in the lesions of multiple sclerosis. N Engl J Med 1998; 338: 278–85.

Trapp BD, Stys PK. Virtual hypoxia and chronic necrosis of demyelinated axons in multiple sclerosis. Lancet Neurol 2009; 8: 280–91.

Ukkonen M, Vahvelainen T, Hämäläinen P, Dastidar P, Elovaara I. Cognitive dysfunction in primary progressive multiple sclerosis: a neuropsychological and MRI study. Mult Scler 2009; 15: 1055–61.

Venters HD, Dantzer R, Kelley KW. A new concept in neurodegeneration: TNFalpha is a silencer of survival signals. Trends Neurosci 2000; 23: 175–80.

Vercellino M, Masera S, Lorenzatti M, Condello C, Merola A, Mattioda A, et al. Demyelination, inflammation, and neurodegeneration in multiple sclerosis deep gray matter. J Neuropathol Exp Neurol 2009; 68: 489–502.

Vergo S, Craner MJ, Etzensperger R, Attfield K, Friese MA, Newcombe J, et al. Acid-sensing ion channel 1 is involved in both axonal injury and demyelination in multiple sclerosis and its animal model. Brain 2011; 134(Pt 2): 571–84.

Warner HB, Carp RI. Multiple sclerosis and Epstein-Barr virus. Lancet 1981; 2: 1290.

Waxman SG. Axonal conduction and injury in multiple sclerosis: the role of sodium channels. Nat Rev Neurosci 2006; 7: 932–41.

Wilkins A, Majed H, Layfield R, Compston A, Chandran S. Oligodendrocytes promote neuronal survival and axonal length by distinct intracellular mechanisms: a novel role for oligodendrocyte-derived glial cell line-derived neurotrophic factor. J Neurosci 2003; 23: 4967–74.

Willis SN, Stadelmann C, Rodig SJ, Caron T, Gattenloehner S, Mallozzi SS, et al. Epstein-Barr virus infection is not a characteristic feature of multiple sclerosis brain. Brain 2009; 132(Pt 12): 3318–28.

Wolinsky JS, Narayana PA, O'Connor P, Coyle PK, Ford C, Johnson K, et al. Glatiramer acetate in primary progressive multiple sclerosis: results of a multinational, multicenter, double-blind, placebo-controlled trial. Ann Neurol 2007; 61: 14–24.

Yong VW. Prospects of repair in multiple sclerosis. J Neurol Sci 2009; 277 (Suppl 1): S16–8.

Young EA, Fowler CD, Kidd GJ, Chang A, Rudick R, Fisher E, et al. Imaging correlates of decreased axonal Na+/K+ ATPase in chronic multiple sclerosis lesions. Ann Neurol 2008; 63: 428–35.

Downloaded from https://academic.oup.com/brain/article/140/3/527/2447880 by guest on 26 April 2026