Diagnosis of multiple sclerosis: 2024 revisions of the McDonald criteria

Xavier Montalban, Christine Lebrun-Frénay, Jiwon Oh, Georgina Arrambide, Marcello Moccia, Maria Pia Amato, Lilyana Amezcua, Brenda Banwell, Amit Bar-Or, Frederik Barkhof, Helmut Butzkueven, Olga Ciccarelli, Jeremy Chataway, Jeffrey A Cohen, Giancarlo Comi, Jorge Correale, Florian Deisenhammer, Massimo Filippi, Julie Fiol, Mark S Freedman, Kazuo Fujihara, Cristina Granziera, Ari J Green, Hans-Peter Hartung, Kerstin Hellwig, Ludwig Kappos, Dorlan Kimbrough, Joep Killestein, Fred Lublin, Romain Marignier, Ruth Ann Marrie, Aaron Miller, Susana Otero-Romero, Daniel Ontaneda, Sudarshini Ramanathan, Daniel Reich, Maria A Rocca, Àlex Rovira, Shiv Saidha, Amber Salter, Jaume Sastre-Garriga, Deanna Saylor, Andrew J Solomon, Maria Pia Sormani, Bruno Stankoff, Mar Tintore, Helen Tremlett, Anneke Van der Walt, Shanthi Viswanathan, Heinz Wiendl, Brigitte Wildemann, Bassem Yamout, Paola Zaratin, Peter A Calabresi, Timothy Coetzee, Alan J Thompson

Lancet Neurol 2025; 24: 850–65

This online publication has been corrected. The first corrected version appeared at thelancet.com/neurology on September 23, 2025, the second corrected version appeared at thelancet.com/neurology on XXX, 2026

See Comment pages 807 and 808

See Personal View pages 866 and 880

Multiple Sclerosis Centre of Catalonia and Department of Neurology (Prof X Montalban MD, G Arrambide MD, S Otero-Romero MD, J Sastre-Garriga MD, Prof M Tintore MD) **and Section of Neuroradiology, Department of Radiology** (À Rovira MD)**, Hospital Universitari Vall d'Hebron, Universitat Autònoma de Barcelona, Barcelona, Spain; Universitat de Vic Central de Catalunya, Barcelona, Spain** (Prof X Montalban)**; Université Nice Cote d'Azur UMR2CA-URRIS; Centre Hospitalier Universitaire de Nice, Nice, France** (C Lebrun-Frénay MD)**; Division of Neurology, Department of Medicine, St. Michael's Hospital, University of Toronto, Toronto, ON, Canada** (J Oh MD)**; Department of Molecular Medicine and Medical Biotechnology, Federico II University of Naples, Naples, Italy** (M Moccia MD)**; Queen Square Multiple Sclerosis Centre, Department of Neuroinflammation, UCL Queen Square Institute of Neurology, Faculty of Brain Sciences** (M Moccia, Prof F Barkhof MD, Prof O Ciccarelli MD, Prof J Chataway MD,

Advances in the understanding of multiple sclerosis and the development of biomarkers of pathophysiology prompted a substantial revision of the 2017 McDonald diagnostic criteria. The new 2024 McDonald criteria provide a unified approach for diagnosing multiple sclerosis in individuals with relapsing or progressive courses throughout the lifespan (ie, from paediatric to late-life presentations). The optic nerve can now serve as a fifth anatomical location within the CNS for diagnosis. The central vein sign, paramagnetic rim lesions, and kappa free-light chain concentrations in CSF can be used, when available, to provide supportive evidence and confer specificity for a diagnosis of multiple sclerosis in specific situations. In certain cases, radiologically isolated syndrome or neurological symptoms that do not constitute a clear attack or progression of disability can fulfil the criteria for a multiple sclerosis diagnosis. We also provide guidance for the diagnosis of multiple sclerosis in older individuals (≥50 years) and those with comorbidities. The 2024 revised criteria should expedite the diagnosis of multiple sclerosis, while maintaining specificity.

Introduction

Diagnosing multiple sclerosis requires a balance between facilitating early recognition of disease and avoiding misdiagnosis. Historically, the diagnosis of multiple sclerosis was based on clinical symptoms.[1–5] However, the advent of MRI has enabled the identification of characteristic lesions in typical CNS regions suggestive of multiple sclerosis. Laboratory findings (eg, the presence of CSF-restricted oligoclonal bands) can now identify the existence of an inflammatory process within the CNS.[6] Within the past two decades, diagnostic criteria were revised to enable earlier diagnosis of multiple sclerosis by incorporating these MRI and CSF biomarkers. The evolution of the criteria has facilitated earlier initiation of disease-modifying therapy and improved clinical outcomes.[7–9]

The 2001 McDonald revisions incorporated detailed MRI assessment into the diagnostic criteria for the first time. Subsequent revisions of the criteria incorporated new evidence that progressively improved their performance. The 2001 McDonald criteria and its 2005 revision introduced and further refined the concept of clinical progression as a requirement for diagnosing progressive multiple sclerosis.[2,3] The 2010 criteria refined the definition of dissemination in space to include four anatomical locations within the CNS (ie, periventricular, juxtacortical, infratentorial, and spinal cord), and dissemination in time (ie, shown by the presence of new lesions on follow-up MRI or simultaneous gadolinium-enhancing and non-enhancing lesions on a single MRI).[4]

The 2017 revisions of the McDonald criteria further facilitated earlier diagnosis with the inclusion of CSF-oligoclonal bands as a substitute for dissemination in time (DIT) in patients fulfilling only criteria for dissemination in space (DIS). Cortical lesions and both symptomatic and asymptomatic MRI lesions can also show DIS and DIT.[5] The high sensitivity and specificity of the 2017 McDonald criteria are now well-established across a range of MRI field strengths, clinical settings, ages (eg, paediatric and late-onset cases), and ethnically diverse and geographically diverse populations.[10–16] Consequently, the time from the first clinical attack to multiple sclerosis diagnosis and treatment initiation has markedly decreased and could be one of several factors contributing to improved clinical outcomes.[7,9] With the 2024 McDonald criteria, we aim at expediting diagnosis even further, and diminish time to treatment initiation.

Rationale and methods for the 2024 revisions

Since the publication of the 2017 revision of the McDonald criteria, substantial progress has been made in several areas. First, evidence has shown added diagnostic sensitivity without losing specificity by including the optic nerve among the potential anatomical locations for diagnosing multiple sclerosis.[16–20]

Second, a typical clinical presentation is currently required to diagnose multiple sclerosis. However, clinicians might encounter individuals with radiologically isolated syndrome (appendix pp 1–3) or patients with neurological symptoms that do not constitute a clear typical attack or progression of disability (eg, paroxysmal symptoms or other non-specific neurological symptoms).[21] Recent studies suggest that some of these patients display MRI and CSF features similar to people

with established multiple sclerosis, and have the same risk for subsequent clinical or radiological activity.[22–25] The lack of initial typical clinical findings in radiologically isolated syndrome and in other non-specific presentations might reflect complex interactions between the locations of injury and compensatory mechanisms in the brain rather than the absence of biological disease. Other fields, such as research in Parkinson's disease and Alzheimer's disease, are moving toward biologically based diagnostic criteria.[26–28]

Third, multiple sclerosis is a diagnosis of exclusion and should be reassessed periodically, considering the harmful consequences of not only underdiagnosis, but also of misdiagnosis.[29] Previously, diagnosing multiple sclerosis was possible entirely on the basis of clinical grounds, according to the presence of at least two attacks with clinical or historical evidence in different anatomical locations and in the absence of a better explanation for the symptoms.[5] However, the typical clinical presentations of multiple sclerosis can overlap with those of other conditions. For instance, differentiation between multiple sclerosis, neuromyelitis optica spectrum disorder (NMOSD), and myelin oligodendrocyte glycoprotein antibody-associated disease (MOGAD) might only be possible with imaging and antibody testing.[30–32] Although the 2017 McDonald criteria allowed for the diagnosis of multiple sclerosis without an MRI if there were two or more clinical attacks, MRI was highly recommended because of the heightened risk of misdiagnosis.[5]

Fourth, although DIT enhances diagnostic specificity, it is not always required and could unnecessarily delay initiation of treatment to avoid further disease activity. The 2017 McDonald criteria already included CSF-oligoclonal bands as a substitute tool for DIT, with marked improvements in diagnostic accuracy. This development has prompted further consideration of the necessity of showing DIT for the diagnosis of multiple sclerosis.[10–16]

Fifth, evidence suggesting that the various clinical presentations of multiple sclerosis form part of a continuum, and that progressive-onset and relapsing-onset multiple sclerosis share similar disease mechanisms, challenge the need for continued use of separate diagnostic criteria for progressive-onset multiple sclerosis.[33]

Sixth, the potential for misdiagnosis exists in relation to comorbidities across the age spectrum, particularly with respect to paediatric demyelination, and the increased awareness of MOGAD as a dominant presentation in children with demyelination.[34] Besides advances in these six areas, substantial knowledge and evidence have also accumulated on disease mechanisms and related imaging and laboratory markers.[33,35–37] Collectively, these advances lay the foundation for the 2024 revision of the diagnostic criteria.

The International Advisory Committee on Clinical Trials, sponsored by the European Committee for Treatment and Research in Multiple Sclerosis (ECTRIMS) and the US National Multiple Sclerosis Society (NMSS), hereinafter the Committee, served as the convening body for the development of the 2017 McDonald criteria and continued in this role for the 2024 revisions. Four virtual meetings of the Committee were convened in 2022 and 2023, during which the invited experts reviewed evidence and provided their interpretation of the available evidence related to the six aforementioned topics.

A consensus conference (Nov 29–Dec 2, 2023, in Barcelona, Spain) brought together 56 contributors, with a broad representation of expertise in neurology, neuroradiology, neuro-ophthalmology, laboratory testing, clinical management, and epidemiology, and people with lived experience of multiple sclerosis. The conference included 32 members of the Committee and additional contributors from several countries with high-resource, mid-resource, or low-resource settings. The additional participants were selected by the steering committee (XM, PAC, TC, CLF, JO, and AJT). Particular attention was given to incorporating the opinions from experts working with populations or in geographic regions known to have an historically underappreciated yet epidemiologically significant burden of multiple sclerosis.

The conference used the modified-nominal group technique to make consensus recommendations.[38] 66 voting statements were developed by the conference steering committee on the basis of information presented in preparatory meetings (see the appendix pp 4–5 for the voting statements and results). After evidence related to individual topics was presented by an expert, all conference participants anonymously voted electronically on a series of general statements and recommendations using a five-point Likert scale (ie, strongly agree, agree, neither agree or disagree, disagree, or strongly disagree). Consensus was defined as 90% of conference participants recording a vote and if there was 80% agreement (ie, strongly agree and agree). Statements receiving approval of 70–79% of participants were eligible for further discussion and a revote. Of the 76 voting statements, four were considered for revote following further discussion during the same meeting. The revoted statements are noted in the appendix (p 6). Subsequently, the criteria were presented at various meetings, including at a plenary session at ECTRIMS 2024 in Copenhagen (Denmark), where they were circulated among all conference participants to generate further feedback before an agreed-upon final summary.

Participants of the consensus conference affirmed two general principles for the diagnosis of multiple sclerosis: (1) the worldwide applicability of the diagnostic criteria; and (2), the essential role of paraclinical tests in the diagnosis of multiple sclerosis (panel 1). These principles serve as the foundation for the 2024 revisions to the criteria.

Prof A J Thompson MD) **and Centre for Medical Image Computing** (Prof F Barkhof), **University College London, London, UK; Department NEUROFARBA, University of Florence; IRCCS Fondazione Don Carlo Gnocchi, Florence, Italy** (Prof M Pia Amato MD); **Department of Neurology, University of Southern California, Los Angeles, CA, USA** (L Amezcua MD); **Department of Pediatrics, Johns Hopkins University** (Prof B Banwell MD) **and Department of Neurology** (Prof S Saidha MD, Prof P A Calabresi MD), **Johns Hopkins University School of Medicine, Baltimore, MD, USA; The Center for Neuroinflammation and Experimental Therapeutics and the Department of Neurology, Perelman School of Medicine, University of Pennsylvania, Philadelphia, PA, USA** (Prof A Bar-Or MD); **Department of Radiology & Nuclear Medicine** (Prof F Barkhof) **and Department of Neurology, MS Center Amsterdam** (Prof J Killestein MD), **Amsterdam UMC, Vrije Universiteit, Amsterdam, Netherlands;** Department of Neuroscience, School for Translational Medicine, Monash University and Alfred Health, Melbourne, VIC, Australia (Prof H Butzkueven MD, A Van der Walt MD); **National Institute for Health and Care Research (NIHR) University College London Hospitals (UCLH) Biomedical Research Centre, London, UK** (Prof O Ciccarelli, Prof J Chataway); **Department of Neurology, Mellen Center for Multiple Sclerosis Treatment and Research, Neurological Institute, Cleveland Clinic, Cleveland, OH, USA** (J A Cohen MD, Prof D Ontaneda MD); **Vita-Salute San Raffaele University, Milan, Italy** (G Comi MD*, M A Rocca MD, Prof M Filippi MD); **Neurology Unit, Neurorehabilitation Unit, and Neurophysiology Service, and Neuroimaging Research Unit, Division of Neuroscience, IRCCS San Raffaele Scientific Institute, Milan, Italy** (Prof M Filippi); **Department of Neurology, Raúl Carrea Institute for Neurological Research (FLENI), Buenos Aires,**

Argentina (J Correale MD); **Department of Neurology, Innsbruck Medical University, Innsbruck, Austria** (Prof F Deisenhammer MD); **National Multiple Sclerosis Society, New York, NY, USA** (Julie Fiol, T Coetzee PhD); **University of Ottawa, Department of Medicine and the Ottawa Hospital Research Institute, Ottawa, ON, Canada** (Prof M S Freedman MD); **Department of Multiple Sclerosis Therapeutics, Fukushima Medical University School of Medicine, Fukushima, Japan** (Prof K Fujihara MD); **Multiple Sclerosis & Neuromyelitis Optica Center, Southern TOHOKU Research Institute for Neuroscience, Koriyama, Japan** (Prof K Fujihara); **Translational Imaging in Neurology (ThINK) Basel, Department of Biomedical Engineering, Faculty of Medicine** (Prof C Granziera MD, Prof L Kappos MD), **Department of Neurology** (Prof C Granziera, Prof L Kappos) **and Research Center for Clinical Neuroimmunology and Neuroscience Basel** (Prof C Granziera, Prof L Kappos), **University Hospital Basel and University of Basel, Basel, Switzerland; Department of Neurology, University of California San Francisco, San Francisco, CA, USA** (Prof A J Green MD); **Department of Neurology, Medical Faculty, Heinrich-Heine-University Düsseldorf, Düsseldorf, Germany** (Prof H-P Hartung MD); **Brain and Mind Center** (Prof H-P Hartung), **Translational Neuroimmunology Group** (S Ramanathan MD), **Sydney Medical School, Faculty of Medicine and Health, University of Sydney, Sydney, NSW, Australia; Department of Neurology, Palacky University in Olomouc, Olomouc, Czech Republic** (Prof H-P Hartung); **Department of Neurology, St. Josef Hospital, Ruhr University, Bochum, Germany** (Prof K Hellwig MD); **Department of Neurology, Duke University, Durham, NC, USA** (D Kimbrough MD); **Department of Neurology, Icahn School of Medicine at Mount Sinai, New York, NY, USA** (Prof F Lublin MD,

Panel 1: **The two fundamental principles for the diagnosis of multiple sclerosis**

Worldwide applicability of diagnostic criteria

A central tenet of our approach is that multiple sclerosis is a global disease. While multiple sclerosis prevalence differs across geographic regions and ethnicities, there are no substantial differences in clinical presentations or MRI or CSF findings that could affect the sensitivity and specificity of diagnosis, suggesting that the same set of criteria should be applied worldwide.[10–15,39–43] Conference participants recognised the challenges associated with restricted global access to MRI, laboratory testing, and treatments; and endeavoured to facilitate the application of the revised criteria by incorporating new and potentially more accessible paraclinical tools, while simplifying some requirements. Guidance related to global implementation in different settings of the 2024 criteria will be addressed in subsequent publications.

Essential role of paraclinical diagnostic tests

The diagnosis of multiple sclerosis is conventionally based on the presence of symptoms typical of demyelinating disease, objective evidence of CNS white matter lesions typical of multiple sclerosis, and no better explanation.[5,21,44] The definitions of symptoms and signs of demyelinating disease are based on accurate medical history, neurological examination, and exclusion of other diagnostic possibilities.[21] The exclusion of mimics has been the most challenging aspect across different sets of criteria. Presentations considered non-specific (eg, seizures) or typical symptoms of multiple sclerosis (eg, trigeminal neuralgia) in patients without a clear attack or objective progression is sometimes caused by focal demyelination, and multiple sclerosis can be discovered incidentally; for example, while investigating unspecific symptoms, such as headache.[45,46] In contrast, typical presentations, such as optic neuritis and myelitis, can be due to other CNS inflammatory diseases.[21] Some disorders that can present with multiple sclerosis-like symptoms, including neuromyelitis optica spectrum disorder and myelin oligodendrocyte glycoprotein antibody-associated disease, are diagnosed on the basis of paraclinical evidence of biological mechanisms (eg, MRI features and disease-specific antibodies).[30–32] Therefore, while clinical history and examination remain fundamental, the diagnosis of multiple sclerosis should be corroborated by paraclinical tests, with brain and spinal cord MRI being the most useful diagnostic paraclinical tools. Nonetheless, in exceptional circumstances, a pragmatic approach can be appropriate.

The optic nerve as a fifth anatomical location

Approximately 25% of people with multiple sclerosis present with optic neuritis as the initial manifestation, and most patients with multiple sclerosis exhibit optic nerve involvement postmortem.[47,48] Optic nerve involvement can be established from different structural (eg, MRI and optical coherence tomography [OCT]) or functional (eg, visual evoked potentials [VEPs]) modalities, as paraclinical adjuncts to careful and thorough neuro-ophthalmological examinations.

OCT is very sensitive and specific for the detection of retinal thinning following symptomatic optic neuritis (with maximal retinal thinning usually detectable at least 6 months post-optic neuritis) and detection of asymptomatic or subclinical remote demyelinating optic nerve injury.[17,18,49,50] Furthermore, OCT can detect optic nerve pathology whether it is unilateral or bilateral. Conservative and device-agnostic support for an abnormal OCT in identifying optic nerve involvement includes an inter-eye difference in the peripapillary retinal nerve fibre layer or composite macular ganglion cell inner plexiform layer thickness of 6 µm or more or 4 µm or more, respectively, with no better explanation. It is imperative that the OCT scan interpretation is done according to the quality control criteria and other parameters outlined in the accompanying companion paper focused on evaluation of the visual pathways for diagnosis of multiple sclerosis.[51]

An abnormal VEP for detection of optic nerve demyelinating injury is defined as a delayed latency (or asymmetric inter-ocular latencies) 2·5 standard deviations greater than the mean for both absolute peak P100 latency and inter-ocular latency, whose exact numerical measures depend on technical and methodological factors, and are also dependent on centre and device. For illustrative purposes only, absolute P100 latency of 118 ms and longer and of 115 ms and longer, and inter-ocular latency differences of 5 ms or longer and of 8 ms and longer are considered abnormal at the University of California San Francisco and Vall d'Hebron University Hospital laboratories, respectively. However, it is imperative that each centre determines its specific VEP cutoffs. As for OCT, it is paramount that quality standards are maintained when acquiring and interpreting VEPs. Abnormal VEPs can identify symptomatic and asymptomatic optic nerve lesions.

OCT and VEPs are widely available in many regions; thus, their inclusion in the new criteria could be applied immediately in diverse settings.[51] However, the OCT and VEP studies that supported the inclusion of the optic nerve in the diagnostic criteria were conducted in adult cohorts. The performance of these tests in children, in whom other conditions such as MOGAD are more prevalent, remains to be explored. Moreover, OCT inter-eye differences might be insensitive to bilateral optic nerve involvement, and caution should be exercised when interpreting bilateral VEP delays since both pre-chiasmal and retro-chiasmal lesions can contribute to bilateral VEP abnormalities. The accompanying paper provides further details.[51]

Although optic nerve lesions can also be seen on brain MRI scans, optic nerve MRI with fat saturation can better show symptomatic and asymptomatic T2-hyperintense lesions and could be included in the conventional diagnostic MRI work-up of multiple sclerosis.[52] Moreover,

Panel 2: Principles and recommendations regarding the optic nerve

- The optic nerve can serve as a fifth anatomical location to demonstrate dissemination in space (DIS) if no better explanation exists for optic nerve pathology
- Provided rigorous quality control is applied, optical coherence tomography-derived peripapillary retinal nerve fibre layer or macular ganglion cell inner plexiform layer inter-eye differences of 6 µm or more and 4 µm or more, respectively, support unilateral optic nerve involvement to demonstrate DIS
- Delayed visual evoked potential latency or asymmetric inter-ocular latencies (2·5 standard deviations greater than the mean for both absolute peak P100 latency and inter-ocular latency), the exact numerical measures of which depend on technical and methodological factors and are also centre and device dependent, support demyelinating optic nerve injury to demonstrate DIS
- One or more intrinsic optic nerve lesions with no better explanation (eg, without prominent chiasmal involvement, optic perineuritis, or longitudinally extensive lesion) identified by MRI might indicate optic nerve involvement to demonstrate DIS

optic nerve MRI can differentiate multiple sclerosis from other causes of optic neuropathy and, thus, might be necessary in the presence of clinical red flags, such as atypical visual symptoms, severe visual loss, or progressive course.[21,52,53] More information on optic nerve MRI is provided in the accompanying papers.[51,54]

Studies evaluating the inclusion of the optic nerve as an additional site for demonstration of DIS have consistently shown increased diagnostic sensitivity without notable loss of specificity.[18–20,55] Caution is always required when considering the differential diagnosis of optic neuritis and optic neuropathy, which includes more than 60 known aetiologies, and can be region specific and include regional infections.[21,53]

The consensus recommendations for incorporating the optic nerve into the 2024 McDonald criteria are listed in panel 2. Overall, our recommendations include that the optic nerve serves as a fifth anatomical location (ie, in addition to the periventricular, cortical or juxtacortical, infratentorial brain, and the spinal cord). Optic nerve involvement supporting a diagnosis of multiple sclerosis can be shown using OCT, VEPs, or MRI, provided no better aetiological explanation exists. Further details regarding the optic nerve as an additional site to show DIS can be found in the accompanying papers on the visual system and MRI.[51,54]

There was no consensus on the role of longitudinal changes in OCT, nor on VEP measures of optic nerve pathology for showing DIT, due to the absence of supporting data. The ability of the optic nerve to show DIT is recognised as an area warranting further study.

Panel 3: Dissemination in space

- Dissemination in space (DIS) is fulfilled when two of the five regions (ie, optic nerve, intracortical or juxtacortical, periventricular, infratentorial, and spinal cord) show typical lesions, regardless of whether these lesions are symptomatic
- In patients with progressive disease, two spinal cord lesions are enough to identify DIS
- Fulfilment of DIS and dissemination in time (DIT) are sufficient to diagnose multiple sclerosis, as per the 2017 McDonald criteria
- Fulfilment of DIS plus positive CSF (eg, oligoclonal bands or kappa free light chain index) is sufficient to diagnose multiple sclerosis
- In patients with typical clinical presentations, the presence of typical lesions in at least four anatomical locations is sufficient to diagnose multiple sclerosis
- In patients with typical clinical presentations and typical lesions in one region, a positive select 6 central vein sign or presence of one or more paramagnetic rim lesions plus DIT or CSF positivity is sufficient to diagnose multiple sclerosis

Modifications to the use of dissemination in space

With the inclusion of the optic nerve in the current revisions, the demonstration of DIS spans five possible anatomical locations.

Consensus recommendations for showing DIS in the 2024 criteria are listed in panel 3. DIS can be fulfilled when at least two of five regions (eg, juxtacortical or cortical, periventricular, infratentorial brain, spinal cord, and optic nerve) have typical lesions, regardless of whether these lesions are symptomatic. Multiple sclerosis can be diagnosed after showing DIS plus DIT on MRI or CSF-restricted oligoclonal bands or kappa free-light chains (kFLC).[5,6,11,43,56,57] Conference participants highlighted the importance of correctly identifying lesions typical of multiple sclerosis, as described in previous imaging and differential diagnosis publications.[5,21,58,59]

Several studies have shown a heightened risk of presenting with a second attack or new or enhancing MRI lesions with greater numbers of typical lesions in CNS regions.[45,60] In particular, having typical lesions in three or four CNS areas increases diagnostic sensitivity and has up to 100% specificity.[61] On the basis of current evidence, the conference participants agreed that multiple sclerosis can be diagnosed when at least four of the five anatomical locations are affected in patients who present with clinically isolated syndrome or with steadily increasing neurological disability independent of relapses (ie, progression) for at least 12 months, without any further requirements, provided there is no better explanation. If only one typical CNS site is affected by characteristic lesions, we advise the use of

Prof A Miller MD); **Service de Neurologie, Sclérose en Plaques, Pathologies de la Myéline et Neuroinflammation and Centre de Référence des Maladies Inflammatoires Rares du Cerveau et de la Moelle (MIRCEM), Hôpital Neurologique Pierre Wertheimer, Hospices Civils de Lyon, Bron, France** (Prof R Marignier MD); **Departments of Medicine and Community Health and Epidemiology, Faculty of Medicine, Dalhousie University, and Nova Scotia Health, Halifax, NS, Canada** (Prof R A Marrie MD); **Department of Neurology and Concord Clinical School, Concord Hospital, Sydney, NSW, Australia** (S Ramanathan); **Translational Neuroradiology Section, National Institute of Neurological Disorders and Stroke, National Institutes of Health, Bethesda, MD, USA** (Prof D Reich MD); **Department of Neurology, Section on Statistical Planning and Analysis, University of Texas Southwestern Medical Center, Dallas, TX, USA** (A Salter PhD); **Department of Neurology, University of North Carolina School of Medicine, Chapel Hill, NC, USA** (D Saylor MD); **University Teaching Hospital, Lusaka, Zambia** (D Saylor); **Department of Neurological Sciences, Larner College of Medicine at the University of Vermont, Burlington, VT, USA** (A J Solomon MD); **Department of Health Sciences (DISSAL), Biostatistics Unit, University of Genoa, Genoa, Italy** (Prof M P Sormani PhD); **Sorbonne University, Paris Brain Institute, Neurology Department, Pitié Salpetriere Hospital, APHP, Paris, France** (Prof B Stankoff MD); **Faculty of Medicine (Neurology), University of British Columbia, Vancouver, BC, Canada** (Prof H Tremlett PhD); **Department of Neurology, Kuala Lumpur Hospital, Kuala Lumpur, Malaysia** (S Viswanathan MD); **Department of Neurology, University Hospital Heidelberg, Heidelberg, Germany** (Prof B Wildemann MD); **Department of Neurology and Neurophysiology, University Freiburg, Freiburg, Germany** (Prof H Wiendl MD); **Harley Street Medical Center,**

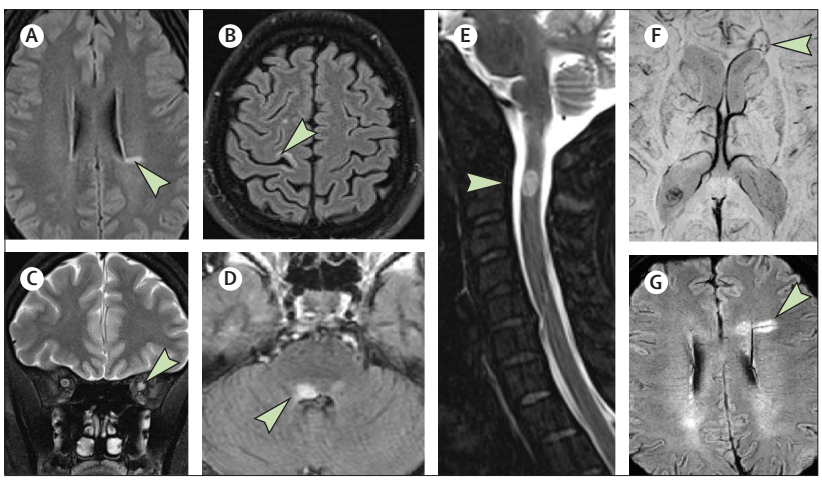

Figure 1: **Typical MRI appearance of multiple sclerosis lesions**
Characteristic anatomical locations of multiple sclerosis lesions identified on T2-weighted images, including (A) periventricular, (B) cortical or juxtacortical, (C) optic nerve, (D) infratentorial, and (E) spinal cord lesion (arrows). Novel MRI features identified on susceptibility-based images, including the (F) paramagnetic rim lesion and (G) central vein sign (arrows).

Abu Dhabi, United Arab Emirates (Prof B Yamout MD); **Italian MS Society and Foundation, Genoa, Italy** (P Zaratin PhD)

*Deceased

Correspondence to: Dr Xavier Montalban, Multiple Sclerosis Centre of Catalonia and Department of Neurology and Section of Neuroradiology, Department of Radiology, Hospital Universitari Vall d'Hebron, Universitat Autònoma de Barcelona, Barcelona 08034, Spain **xavier.montalban@cem-cat.org**

See **Online** for appendix

highly specific tools (in addition to DIT or oligoclonal bands).

Dissemination in time is no longer necessary

The concept of DIT was incorporated into previous diagnostic criteria to differentiate multiple sclerosis from other inflammatory syndromes, such as monophasic acute disseminated encephalomyelitis, isolated myelitis, or monophasic optic neuritis.[2–5,62–64] However, DIT is not as specific as first assumed. Some clinical trials and natural history studies show that most patients with clinically isolated syndrome and typical MRI lesions will develop clinical or radiological DIT.[65,66] Other reasons for reconsidering the use of DIT for the diagnosis of multiple sclerosis include that other diseases can also exhibit DIT and that technical issues or inter-rater variability can affect the assessment of new or enlarging lesions on MRI for radiological DIT.[21,67] In keeping with the notion that DIT is not as specific as once believed, the 2017 McDonald criteria already included CSF-oligoclonal bands as a substitute tool for DIT. Hereby, the presence of new or simultaneous gadolinium-enhancing and non-enhancing typical lesions on MRI increases the specificity of the diagnostic criteria and, together with relapses, should be retained in the diagnostic process of multiple sclerosis, but not as a mandatory additional requirement to DIS, as discussed earlier.[68,69] DIT is now considered not essential.

Central vein sign can be diagnostic

The formation of multiple sclerosis plaques around venules has been shown in pathological studies since the 19th century.[70] However, plaque detection inside multiple sclerosis lesions in vivo has only been possible since the development of non-conventional MRI techniques.[70,71] Demonstration of the central vein sign (CVS) by MRI (figure 1) can increase diagnostic specificity by differentiating multiple sclerosis from vascular or other CNS inflammatory conditions.[54]

The optimal method for assessing the CVS is to calculate the proportion of the total number of lesions that have a central vein.[72] However, this approach can be very labour intensive if there are many lesions. Several simplified rating methods for CVS, which take a short time to complete, have been evaluated in cross-sectional or prospective multicentre studies.[35,73,74] In general, these methods show excellent diagnostic performance using sequences, such as susceptibility-weighted imaging or T2*-weighted 3D segmented echo planar imaging, with the select 3 rating method having greater sensitivity and the select 6 rating method having greater specificity (sensitivity 62–93% *vs* 59–89%; specificity 63–92% *vs* 75–98%, respectively) for the diagnosis of multiple sclerosis. Given that select 6 has an optimal balance of sensitivity, specificity, and feasibility, conference participants agreed that, for people with clinically isolated syndrome or radiologically isolated syndrome with at least two regions affected, the presence of CVS using select 6 is sufficient for diagnosing multiple sclerosis, without any further requirements. The select 6 method is considered positive when six or more white matter lesions are CVS positive; if fewer than ten white matter lesions are detected on MRI, the number of CVS positive lesions should be the majority.[75]

Some studies have shown that the CVS and oligoclonal bands have similar diagnostic properties individually, and that the positive predictive value of having both oligoclonal bands and select 6 positivity approaches 100% (80–100%).[76–78] Conference participants agreed that in patients with clinically isolated syndrome and only one anatomical location affected, and either positive CSF or DIT on MRI, the presence of CVS with the select 6 method is sufficient for the diagnosis of multiple sclerosis.

Despite the high specificity of the CVS for differentiating multiple sclerosis from other diseases with white matter involvement, conference participants emphasised that CVS is not a mandatory tool for diagnosing multiple sclerosis (panel 4). The assessment of the CVS in clinical practice has potential limitations, including time constrains in MRI acquisition and reporting. The frequency of CVS in paediatric patients with multiple sclerosis is less well studied than in adults, although CVS lesions have also been reported in children.[79–82]

Although the CVS can be observed on images acquired with 1·5T MRI, the proportion of detected CVS is lower (56–58%) than with 3T (74 –79%) or 7T (79–82%). Therefore, on 1·5T scanners, optimised sequences or paramagnetic contrast administration can be required for adequate CVS detection. Although T2* 3D echo planar imaging sequences are most sensitive for CVS detection (82–84%), this and other imaging sequences might have limited utility as they might not be readily

available at all centres or they might not have received regulatory approval for use in some circumstances. Lastly, the prevalence of CVS is highest in periventricular (up to 94%) and deep white matter (up to 84%) lesions. There is little evidence on the proportion of lesions with CVS in the cortical or juxtacortical, infratentorial, and spinal cord regions.[72] Overall, identification of the CVS is not required to diagnose multiple sclerosis but can, when available, be helpful in some cases, such as in patients with white matter lesions due to vascular disease or migraine, by increasing specificity. Furthermore, CVS can discriminate 87% of people incorrectly diagnosed with multiple sclerosis.[83]

Paramagnetic rim lesions can be used

Chronic active multiple sclerosis lesions are characterised by an inactive core surrounded by activated iron-laden microglia.[36,84–87] Susceptibility sensitive images can identify such paramagnetic rim lesions (PRLs), which are present in many cases (even at the earliest stages of multiple sclerosis), by the presence of a characteristic rim that is typically rendered as hypointense or hyperintense on phase images and often appear as hypointense on T2*-weighted images.[36,84–89]

Many PRL studies have been done using 7T MRI scanners, which are not readily accessible in clinical practice.[88,90] However, numerous recent studies have shown that PRLs can also be detected at 3T and 1·5T using the appropriate susceptibility sensitive sequences.[57,88,91] At experienced centres, inter-rater agreement for PRL detection between 3T and 7T has been reported to be as high as 90%, and inter-rater agreement between 1.5T and 3T as high as 97%.[36,85] However, no evidence exists as to whether these reported agreements are valid in non-experienced centres.

Evidence supporting the specificity of PRLs in multiple sclerosis diagnosis is still preliminary but is accumulating rapidly. A recent systematic review and meta-analysis found that the composite specificity of PRLs for a diagnosis of multiple sclerosis was 98%, and sensitivity ranged from 10% to 92·3%.[88] In one prospective longitudinal study, specificity and sensitivity were 100% and 59%, respectively.[57] Importantly, PRLs are rarely found in other radiological mimics of multiple sclerosis.

Despite the general agreement that the presence of PRLs can help diagnose multiple sclerosis, the evidence concerning their added value and specifically in clinically isolated syndrome when only DIS is fulfilled, was considered insufficient. Only one longitudinal study in people with a clinically isolated syndrome evaluated the diagnostic properties of PRLs, and found that combining 2017 MRI DIS plus one or more PRL had a sensitivity of 59% and a specificity of 83% for multiple sclerosis diagnosis, outperforming DIS and oligoclonal bands.[57] Moreover, the reported prevalence of PRLs in clinically isolated syndrome varies substantially across studies, and PRLs are most often found in periventricular lesions, with limited data on PRLs in other locations.[57,86,91]

On the basis of the available evidence, conference participants agreed that identifying PRLs on MRI can increase the specificity of a diagnosis of multiple sclerosis. In people with clinically isolated syndrome and abnormal MRI showing typical lesions in only one anatomical location and who have either DIT on MRI or CSF-restricted oligoclonal bands, the presence of one or more PRL is sufficient to diagnose multiple sclerosis (panel 4). While the evidence that PRL could serve as a paraclinical tool for multiple sclerosis diagnosis is robust, conference participants agreed that identifying PRLs is not required to diagnose multiple sclerosis and might hold similar limitations to CVS. PRLs can also be recommended to reduce misdiagnosis in presentations with symptoms that are not specific for multiple sclerosis.[55]

kFLC index as an appropriate paraclinical diagnostic test

Demonstration of CSF-restricted oligoclonal bands is a valuable diagnostic tool;[6,92] however, their detection

Panel 4: General principles and recommendations related to the central vein sign, paramagnetic rim lesions, and kappa free light chains

Central vein sign (CVS)

- Demonstrating the CVS by MRI can be used to diagnose multiple sclerosis in specific situations
- Demonstrating the CVS by MRI can increase the specificity of the diagnosis
- Demonstration of the CVS is not required for diagnosis
- In patients with typical clinical presentations and dissemination in space, the presence of CVS is defined using select 6 and is sufficient for diagnosis
- In patients with typical clinical presentations and typical lesions in one region, the presence of the select 6 CVS plus dissemination in time or positive CSF is sufficient for diagnosis

Paramagnetic rim lesions (PRLs)

- Demonstrating one or more PRLs by MRI can be used to diagnose multiple sclerosis in specific situations
- Demonstrating one or more PRLs by MRI can increase the specificity of the diagnosis
- Demonstrating PRLs is not required for diagnosis
- In patients with typical symptoms and typical lesions in one region, the presence of one or more PRLs plus dissemination in time or positive CSF is sufficient for diagnosis

Kappa free-light chains (kFLC)

- The kFLC index is an appropriate paraclinical test for the diagnosis of multiple sclerosis
- The kFLC-index is interchangeable with oligoclonal bands and consequently can substitute for oligoclonal bands for diagnosis (ie, positive CSF)

Panel 5: **Recommendations related to radiologically isolated syndrome, paediatric multiple sclerosis, and primary progressive multiple sclerosis**

Radiologically isolated syndrome (RIS)

- RIS is identified by the incidental discovery of CNS white matter T2-weighted hyperintense foci on MRI, which are highly typical of multiple sclerosis in the absence of typical clinical symptoms related to inflammatory demyelination or findings on clinical examination
- In patients with RIS, fulfilling dissemination in space (DIS) and dissemination in time is sufficient for diagnosing multiple sclerosis
- In patients with RIS, fulfilling DIS and positive CSF is sufficient for diagnosing multiple sclerosis
- In patients with RIS fulfilling DIS, the presence of the select 6 central vein sign (CVS) is sufficient for diagnosing multiple sclerosis
- These recommendations can also apply to patients with other non-specific presentations

Paediatric multiple sclerosis

- Paediatric and adult-onset multiple sclerosis can be diagnosed using a single diagnostic criteria framework
- In patients with an acute disseminated encephalomyelitis (ADEM) presentation, a second clinical attack consistent with typical multiple sclerosis attacks or new T2 lesions in typical multiple sclerosis anatomical locations longer than 90 days post-ADEM onset is required before the multiple sclerosis diagnostic criteria can be applied
- In children and adolescents (younger than 18 years), the presence of CVS in more than 50% of T2 lesions strongly supports a diagnosis of multiple sclerosis
- Myelin oligodendrocyte glycoprotein (MOG)-IgG testing using a cell-based assay is strongly recommended in children with incident CNS demyelination younger than 12 years
- In people aged 12 years and older with an incident demyelinating event, MOG-IgG testing using a cell-based assay is recommended in presentations with symptoms not specific to multiple sclerosis or suggestive of myelin oligodendrocyte glycoprotein antibody-associated disease, but not for all people being investigated for multiple sclerosis

Primary progressive multiple sclerosis (PPMS)

- PPMS requires evidence of clinical progression extending at least 12 months
- A single, framework of diagnostic criteria should be used to diagnose relapsing and progressive multiple sclerosis
- Two or more spinal cord lesions are evidence of DIS in diagnosing primary progressive multiple sclerosis

method (eg, isoelectric focusing, followed by IgG immunodetection—mostly immunoblotting) is time-consuming and rater-dependent, limiting this assessment to laboratories with specialised expertise.[93] kFLC have emerged as another diagnostic biomarker. Multiple studies have reported increased intrathecal production of kFLC in people with multiple sclerosis compared with controls.[94,95] In contrast to oligoclonal bands, kFLC measurement can be conducted in hospitals and institutions with access to nephelometry or turbidimetry, which are cost-effective platforms that return objectively quantifiable and rater-independent results.[96] Intrathecal production of kFLC can be identified by different methods, such as the kFLC index, the percentage of intrathecal kFLC fraction, the CSF kFLC concentration, and the kFLC quotient. The most frequently investigated method is the kFLC index (ie, kFCL concentrations proportioned to albumin concentrations), which is more sensitive than isolated kFLC measurements in CSF if concentrations are low.[97,98] Patients with radiologically isolated syndrome and clinically isolated syndrome with a positive kFLC index are at increased risk of an attack or fulfilling the 2017 McDonald criteria.[99–101] The diagnostic accuracy of the kFLC index are similar to those of oligoclonal bands when assessed in clinically isolated syndrome cohorts, and, importantly, the concordance between oligoclonal bands and the kFLC index is about 87·0%.[100] In primary progressive multiple sclerosis, a retrospective multicentre study showed a concordance between oligoclonal bands and kFLC index of 90·0% when using a cutoff of 6·1.[102] An international expert panel had recommended the inclusion of the kFLC index as an additional diagnostic tool to show intrathecal antibody production.[103]

The IgG index, included in previous versions of the McDonald criteria as an alternative to oligoclonal bands to aid diagnosis, was not considered for voting, but was discussed.[1–4] Although specific, studies have shown a much lower sensitivity and accuracy of the IgG index compared with both oligoclonal bands and the kFLC index.[104,105] As such, only the kFLC index was considered as an equivalent tool to oligoclonal bands in the 2024 McDonald criteria (panel 4).

It is important to note that, as with oligoclonal bands, the kFLC index can identify intrathecal antibody production in other diseases, including MOGAD and NMOSD, albeit with considerably lower index values; the greatest overlap is between multiple sclerosis and NMOSD.[30,31,106,107] As always, the kFLC index should be interpreted in the context of clinical and MRI findings. kFLC index testing could be particularly helpful in centres where oligoclonal bands determinations are unavailable. Further details regarding oligoclonal bands and kFLC index will be published separately.[108]

Radiologically isolated syndrome

Radiologically isolated syndrome is characterised by incidental findings on MRI of T2-hyperintense lesions in the CNS white matter, in a pattern typical of multiple sclerosis, but in the absence of clinical symptoms suggestive of inflammatory demyelination.[22,109] Observational studies have shown that slightly more than half of individuals (51·2%) with radiologically isolated syndrome will develop clinical symptoms within 10 years of follow-up.[24] Risk factors for developing multiple sclerosis symptoms are similar to those observed in clinically isolated syndrome cohorts and include younger age (<37 years), infratentorial or spinal cord lesions, gadolinium-positive lesions, oligoclonal bands, or altered VEP consistent with demyelination. The more the risk factors, the greater and earlier risk of developing multiple sclerosis symptoms.[23,109,110] This evidence indicates that

radiologically isolated syndrome is part of the multiple sclerosis continuum and shares the same pathology.[33] As such, radiologically isolated syndrome should be included in the multiple sclerosis diagnostic criteria.

Additional characteristics highlighting the inflammatory nature of the lesions, including the presence of DIT or intrathecal antibody production by oligoclonal bands or kFLC, enhance the specificity of incidental T2 lesions fulfilling DIS.[24,110,111] Therefore, individuals with radiologically isolated syndrome or other non-specific presentations should have MRI lesions in at least two anatomical locations and at least one additional feature among DIT or positive CSF to be diagnosed with multiple sclerosis (panel 5).

CVS should be considered in patients with or without symptoms who have not had an attack or objective progression. In radiologically isolated syndrome, up to 75% of lesions have a CVS, with a median proportion of CVS per case of 87%. A larger proportion of CVS lesions corresponds to a higher risk of developing multiple sclerosis, and about 95% of people with radiologically isolated syndrome fulfill the select 6 criteria.[78,112] These findings, along with the previously described evidence in clinical multiple sclerosis, led the conference participants to agree on using the CVS select 6 rule in radiologically isolated syndrome cases with lesions in at least two anatomical locations to diagnose multiple sclerosis (figure 2). These criteria also apply to patients with other symptoms, such as paroxysmal symptoms, seizures, or other non-specific neurological symptoms that do not constitute a clear attack or progression of disability.

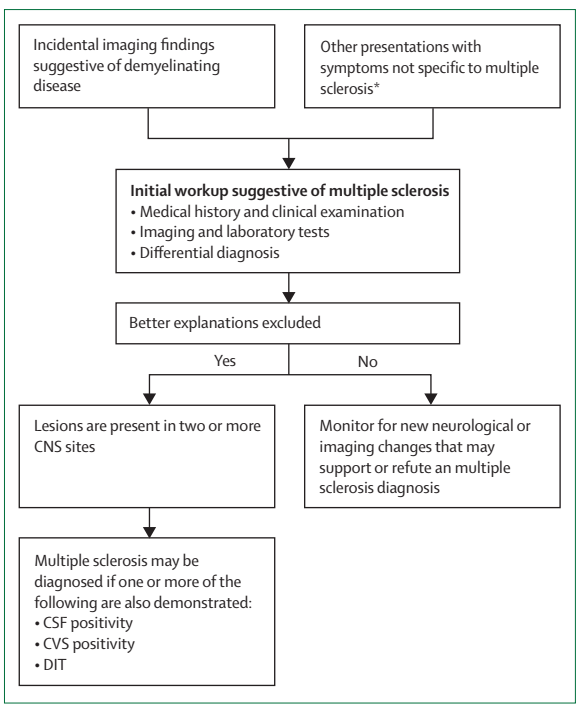

Figure 2: **Diagnostic algorithm for radiologically isolated syndrome and other non-specific presentations**
CVS=central vein sign. DIT=dissemination in time. *Presentations might include: (1) symptoms or signs overlapping those of multiple sclerosis but with no characteristic attack; or (2) paroxysmal symptoms (eg, trigeminal neuralgia), seizures, and other symptoms.

A single diagnostic criterion for paediatric-onset and adult-onset multiple sclerosis

Conference participants agreed that a single diagnostic criteria framework should be applied to adult-onset and paediatric-onset multiple sclerosis (onset younger than age 18 years). Specific considerations apply to differential diagnoses in children and adolescents with acquired demyelinating syndromes. MRI, CSF, and serum myelin oligodendrocyte glycoprotein (MOG) antibody serostatus are the most robust features to distinguish children with multiple sclerosis from those with non-multiple sclerosis diagnoses.[13,113]

Pediatric-onset multiple sclerosis (POMS) and adult-onset multiple sclerosis share similar pathobiological mechanisms, risk of clinical worsening, and MRI features.[114–117] However, POMS is characterised by a high inflammatory burden and by clinical and MRI features of active relapsing multiple sclerosis.[118,119] Optic nerve involvement in POMS is common, although formal analyses evaluating the contribution of the optic nerve as the fifth location need to be completed in large cohorts. While recovery from relapse-associated worsening is generally more complete in POMS, disability milestones might nevertheless be reached at a younger age than in adult-onset multiple sclerosis, thus requiring early identification and treatment.[116,120]

The periventricular, infratentorial, spinal cord, juxtacortical, and cortical lesions in POMS have features similar to those in adult-onset multiple sclerosis. CVS-positive lesions are common in POMS and can support differentiation from other conditions, including MOGAD.[81] However, considering the often-high lesion burden and the dearth of evidence evaluating select 6 CVS criteria in POMS, in individuals younger than age 18 years, CVS should be considered only when 50% or more of lesions show this sign. PRLs are less common than CVS lesions and their diagnostic value in POMS is yet to be established.[81,121] The diagnostic performance of the kFLC index in POMS was very similar to that in adults in a small but robust study, that included patients with NMOSD and MOGAD as controls.[122]

Just as in adults, criteria for diagnosing multiple sclerosis should be applied with care to children (younger than age 12 years) and adolescents with acquired demyelinating syndromes due to the risk of misdiagnosis. In particular, these criteria should not be applied to children presenting with acute disseminated encephalomyelitis, as this presentation might require additional work-up for differential diagnosis, such as anti-MOG testing and CSF examination.[123] If a follow-up MRI scan shows resolution or near-complete resolution

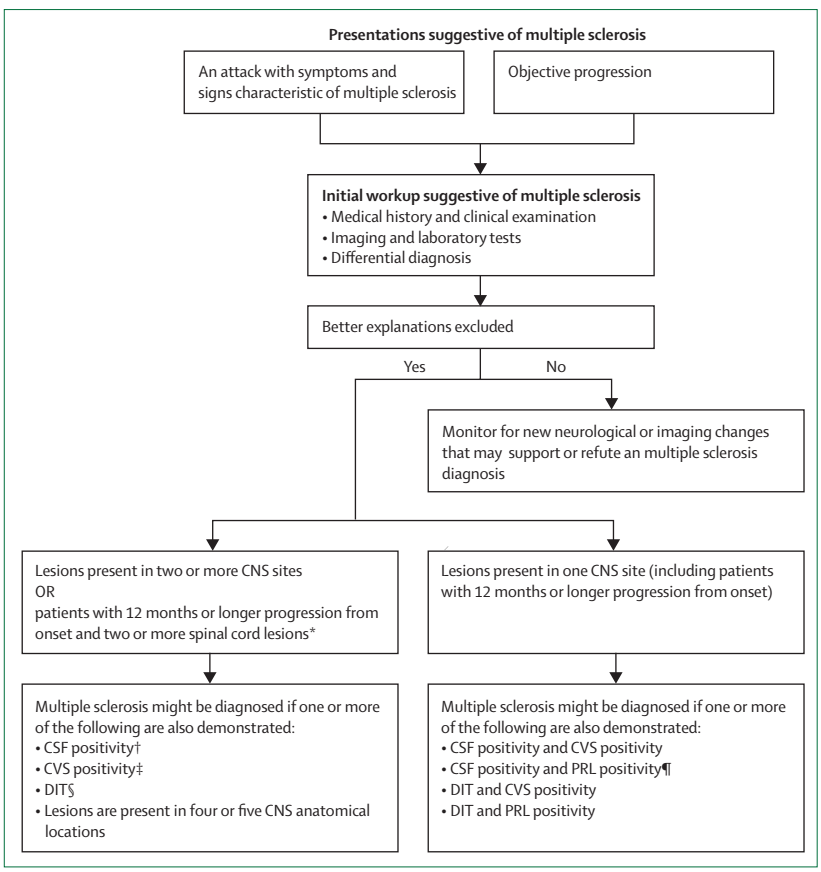

Figure 3: **Diagnostic algorithm for relapsing and progressive presentations of multiple sclerosis**
CVS=central vein sign. DIT=dissemination in time. PRL=paramagnetic rim lesion. *In patients presenting with 12 months or longer disease progression from symptom onset, the presence of two or more spinal cord lesions is considered evidence of dissemination in space and meets criteria for the presence of lesions in two CNS locations. †CSF positivity is demonstrated by presence of oligoclonal bands or kappa free-light chains. ‡CVS positivity is demonstrated by the presence of six or more lesions with CVS; if fewer than ten white matter lesions are seen on MRI, the number of CVS positive lesions should outnumber the CVS negative lesions. §DIT is demonstrated by the presence of one or more new T2 lesions or one or more gadolinium-positive lesions or a clinical attack. ¶PRL positivity is demonstrated by the presence of one or more PRL.

of all or most of the previous T2 lesions, these findings should prompt consideration of alternative diagnoses. In paediatric presentations, standard inclusion of serum MOG-IgG testing, using fixed or live cell assays, at the time of first attack can identify children with MOGAD and increase sensitivity and specificity of multiple sclerosis criteria.[13] As such, while the 2017 criteria showed excellent sensitivity and specificity in POMS, so-called no better explanation considerations should include MOG-IgG testing because of the higher relative incidence of MOGAD compared with multiple sclerosis in the (especially younger) paediatric population and their overlap in clinical and MRI presentations.[113,124,125] MOG-IgG testing using a cell-based assay is strongly recommended in all children younger than 12 years with an incident CNS demyelinating event (panel 5). MOG-IgG testing using a cell-based assay (where available) is advocated in the context of presentations with symptoms not specific to multiple sclerosis (eg, either at onset or based on clinical and MRI evolution) in children with a clinical or radiographic presentation suggestive of MOGAD. It is not advocated to routinely test for MOG-IgG in all patients aged 12 years or older with suspected demyelination and it is noted that low titre MOG-IgG can infrequently be present in POMS, just as in adult-onset multiple sclerosis.[30,106] While aquaporin 4-positive NMOSD is rare in paediatric patients, testing for aquaporin 4 antibodies might be warranted in some cases, depending on the clinical context.

A unified framework for the diagnosis of relapsing and progressive forms

Progressive-onset multiple sclerosis has conventionally had a separate set of diagnostic criteria, which have been minimally revised in years.[126] However, pathological and imaging studies have identified quantitative, not qualitative, differences between the various clinical forms, suggesting that the disease course should be considered as a continuum.[33,127–129] Hence, if diagnostic criteria are rooted in the biological mechanisms of multiple sclerosis, they could be applied equally to relapsing-onset and progressive-onset multiple sclerosis (figure 3).[130]

In a recent study by the MAGNIMS network, the 2017 McDonald criteria for relapsing-onset multiple sclerosis performed well for progressive-onset multiple sclerosis, also when including the optic nerve as an additional anatomical location.[61] The spinal cord is frequently affected in progressive-onset multiple sclerosis, and two or more spinal cord lesions might be sufficient to fulfil DIS criteria and provide increased diagnostic sensitivity.[61] Cautious interpretation of isolated spinal cord and CSF findings in progressive presentations is encouraged, since several progressive neurological disorders can present similarly.

A single diagnostic criteria framework should be applied to relapsing-onset and progressive-onset multiple sclerosis, including the five anatomical locations and additional paraclinical tools described earlier (panel 5). This framework would maintain high sensitivity and specificity while reducing complexity. With progressive-onset multiple sclerosis, the presence of a second spinal cord lesion can substitute for an additional brain anatomical location. Whether this approach could also be applied to relapsing-onset multiple sclerosis warrants exploration.

Diagnosis in individuals aged 50 years and older or with comorbidities

Comorbidity is common at multiple sclerosis symptom onset and diagnosis, and prevalence increases with age.[131] As such, an older age of onset and comorbidities associated with clinical or imaging features that overlap with those seen in multiple sclerosis increase the risk of misdiagnosis.[15,69,131–133] Diseases potentially producing

Panel 6: Recommendations related to older age and comorbidities in the diagnosis of multiple sclerosis

- In patients being considered for a diagnosis of multiple sclerosis presenting at age 50 years and older, multiple sclerosis is more likely to be misdiagnosed
- Small vessel ischaemic disease, psychiatric disorders, and some autoimmune diseases are associated with an increased risk of misdiagnosed multiple sclerosis
- Headache disorders, particularly migraine, are associated with periventricular lesions and an increased risk of misdiagnosis of multiple sclerosis
- In patients who are being considered for a diagnosis of multiple sclerosis presenting at age 50 years and older or with significant vascular risk factors (eg, hypertension, smoking, diabetes, hyperlipidaemia, or known macrovascular disease), additional features are strongly recommended to confirm the diagnosis:
  - A spinal cord lesion
  - CSF positivity by demonstration of intrathecal antibody production with oligoclonal bands or kappa free-light chain index
  - Central vein sign positivity

Panel 7: Revisions to the 2017 McDonald criteria in the 2024 McDonald Criteria

- The optic nerve might serve as a fifth anatomical location to demonstrate dissemination in space (DIS) if no better explanation exists for optic nerve pathology as detected by MRI, optical coherence tomography, or visual evoked potentials
- DIS is fulfilled when two of five anatomical locations (ie, optic nerve, intracortical or juxtacortical, periventricular, infratentorial, and spinal cord) show typical lesions, regardless of whether these lesions are symptomatic
- DIT is not mandatory for a diagnosis of multiple sclerosis in specific situations
- The demonstration of central vein sign positivity by MRI can be used to diagnose multiple sclerosis in specific situations
- The demonstration of paramagnetic rim lesions by MRI can be used to diagnose multiple sclerosis in specific situations
- The kappa free-light chain index is interchangeable with oligoclonal bands and consequently can replace oligoclonal bands for diagnosing multiple sclerosis
- Radiologically isolated syndrome and other presentations with non-specific symptoms are multiple sclerosis when specific criteria are fulfilled
- Paediatric-onset and adult-onset multiple sclerosis can be diagnosed using a single diagnostic criteria framework
- Progressive and relapsing multiple sclerosis represent a unified diagnosis and require unified diagnostic criteria
- Additional recommendations should be considered for confirming the diagnosis of multiple sclerosis in individuals aged 50 years and older with vascular comorbidities

MRI findings leading to misdiagnosis of multiple sclerosis include: vascular white matter changes (eg, small vessel disease); neurovascular pain syndromes (eg, migraine); and other inflammatory diseases (eg, Behçet's disease).[29,134]

Periventricular lesions are not specific to multiple sclerosis and can be seen in different conditions, including small-vessel ischaemia, migraine, infection, and metabolic disorders.[135] Increasing the threshold to three or more periventricular lesions helps to differentiate people with multiple sclerosis from those with migraine, but cannot distinguish multiple sclerosis from age-related changes and does not improve sensitivity and specificity in older patients.[69,136,137] Also, cortical or juxtacortical and periventricular regions are simultaneously affected in up to a third of individuals with migraine, thus only partly address the risk of misdiagnosis.[138,139] Similarly, infratentorial lesions can occur secondary to vascular disorders and non-multiple sclerosis inflammatory disorders.[140] Spinal cord lesions are generally not found in patients with cerebrovascular disease. Gadolinium-enhancing lesions or CSF oligoclonal bands or kFLCs can improve the likelihood of multiple sclerosis diagnosis across all age groups.[69] The CVS is specific for multiple sclerosis pathology and can support the differentiation of multiple sclerosis lesions from vascular disorders.[141,142] Older people and those with comorbidities (ie, including headache and vascular disorders) might define a subset of patients at a higher risk for misdiagnosis, requiring additional diagnostic tests.

Additional tests for a multiple sclerosis diagnosis are strongly recommended in individuals aged 50 years and older or with vascular risk factors (eg, including hypertension, smoking, diabetes, hyperlipidaemia, or known macrovascular disease; panel 6). Such additional test findings might include one or more spinal cord lesions or positive CSF or CVS-positive (select 6). These considerations apply to all our previous recommendations, including those for radiologically isolated syndrome. A consensus was not reached about using PRL for diagnosis in older people or in those with comorbidities.

Conclusion

Diagnosing multiple sclerosis requires a balance between facilitating early recognition and avoiding misdiagnosis, without unnecessary complexity and considering the diversity of clinical settings worldwide. Periodic revision of the diagnostic criteria has directly affected long-term outcomes of people with multiple sclerosis. Consistent with these principles, the 2024 McDonald criteria are based on the most recent robust evidence, extend the boundaries of previous criteria, and lay the groundwork for future innovations based on the updated mechanistic framework for disease progression

Search strategy and selection criteria

References for this Position Paper were identified by searches of PubMed between Jan 1, 2017, and Dec 31, 2024, and references from relevant articles. The search terms "multiple sclerosis", "MRI", "OCT", "VEP", "CVS", "PRL", "diagnosis", and "PPMS" were used. The final reference list was generated on the basis of relevance to the diagnostic criteria.

(panel 7).[33] The applicability of the revised diagnostic criteria might vary across regions because of differences in epidemiological context. As such, research to understand how the criteria perform in different settings and the prevalence of multiple sclerosis mimics should be prioritised.

Demonstrating typical lesions by MRI in characteristic anatomical locations is now the cornerstone of diagnosis. The optic nerve can now serve as a fifth CNS region for diagnosis, and can be assessed by OCT, VEP, or MRI. CVS and PRLs can be used to diagnose multiple sclerosis in specific situations to reduce the risk of misdiagnosis. The kFLC index can be an alternative to oligoclonal bands to support the diagnosis of multiple sclerosis. The 2024 McDonald criteria provide a unified approach to diagnose multiple sclerosis in patients experiencing typical relapsing or progressive presentations and radiologically isolated syndrome, across the lifespan. Moving toward a unifying biological framework of disease, radiologically isolated syndrome and symptoms in the absence of a typical relapsing or progressive course can be considered multiple sclerosis in specific situations. Additional recommendations for diagnosing multiple sclerosis in older people and in those with vascular comorbidities are incorporated to reduce misdiagnosis. Further detail regarding implementation of the new criteria can be found in the companion papers discussing the visual system, MRI, and CSF and other body fluid biomarkers.[51,54,108] The 2024 McDonald criteria are expected to facilitate the diagnosis of multiple sclerosis, thereby improving clinical outcomes of people with multiple sclerosis worldwide.

Contributors

XM, AJT, and TC drafted the conference agendas with the agreement of steering committee members, CL-F, JO, and PAC. XM, TC, SO-R, ÀM, JAC, AJT, HT, RAM, FL, AS, BW, RM, PAC, JS-G, AJG, SS, FB, GA, JO, DO, DR, CG, CL-F, MF, FD, BB, MPA, and OC made topic-related presentations at the consensus conference. All conference participants actively participated in discussion and reaching consensus. XM, TC, AJT, JO, CL-F, PAC, GA, and MM prepared the initial drafts of this manuscript. All conference participants were given the opportunity to review drafts and make revisions before finalisation, and approved the manuscript for submission.

Declaration of interests

GA received compensation for consulting services, speaking honoraria, or participation in advisory boards from Roche, Horizon Therapeutics, and Bristol Myers Squibb; travel support for scientific meetings from Novartis, Roche, ECTRIMS and EAN; GA serves as Editor for *Europe of the Multiple Sclerosis Journal – Experimental, Translational and Clinical*; is a member of the editorial and scientific committee for Acta Neurológica Colombiana; is a member of the International Women in Multiple Sclerosis (iWiMS) network executive committee, the European Biomarkers in Multiple Sclerosis (BioMS-eu) steering committee, the MOGAD Eugene Devic European Network (MEDEN) steering group, and the Platform Adaptive Trial for remyelination and neuroprotection in multiple Sclerosis (PLATYPUS) steering committee. MPA received research grants from the National MS Society, Canadian MS Society, Italian Health Ministry, Regione Toscana, Bayer, Biogen, Merck, Novartis, Sanofi Genzyme, Teva, Almirall, Roche; honoraria as a speaker and member of advisory boards for Bayer, Biogen, Merck, Novartis, Sanofi Genzyme, Teva, Almirall, Roche, Celgene Bristol Myers Squibb, and Sandoz; and is member of the editorial board for *Multiple Sclerosis*. LA received research support from the National Institutes of Health (NIH) National Institute of Neurological Disorders and Stroke (NINDS) and Bristol Myer Squibb Foundation; is a local Principal Investigator for commercial trials funded by Genentech and Sanofi Genzyme; and received consulting fees from TGI Therapeutics, Novartis, Genentech, and EMD Serono. FB is supported by European Commission, Medical Research Council, National Institute for Health and Care Research (NIHR) Biomedical Research Centre at University College London Hospitals (UCLH), GE Healthcare, Roche, and ADDI (paid to institution); is a consultant for Combinostics, IXICO, and Roche; and participates in steering committees or data safety monitoring boards for EISAI, Biogen, Prothena, and Merck. AB-O received consulting fees or advisory board participation fees from Abata, Autolus, Biogen, Cabaletta, Capstan, GlaxoSmithKline, Immunic, Merck EMD Serono, Moderna, Novartis, Roche Genentech, Sana, Sangamo, Sanofi Genzyme, and Viracta; and grant support to the University of Pennsylvania from Merck EMD Serono, Roche Genentech, Biogen Idec, and Novartis. BB served as a consultant to Novartis, Sanofi, Teva Neuroscience, and Biogen in the design of clinical trials for paediatric multiple sclerosis; has served as a central imaging Reviewer for clinical trials by Novartis and Roche; and received grant funding from the NIH, National Multiple Sclerosis Society, and Multiple Sclerosis Canada. PAC received grants from the NIH, National Multiple Sclerosis Society, Department of Defence, Genentech, and the Myelin Repair Foundation; and consulting honoraria for serving on safety advisory boards for Novartis, Idorsia, and Lilly. HB received research grants and contracts from Roche, Novartis, Biogen, UCB, Merck, National Health and Medical Research Council (NHMRC) Australia, Trish Foundation, MS Australia, Pennycook Foundation, and Alfred Health (to institution); honoraria for consulting and speaking from Roche, Novartis, UCB, Merck, and Neuorphan; travel support from Merck and Novartis; and personal compensation from the MSBase Foundation. JCh received support from the Health Technology Assessment (HTA) Programme NIHR, the UK MS Society, the US National MS Society, and the Rosetrees Trust; is supported in part by the NIHR UCLH Biomedical Research Centre; has been a local Principal Investigator for a trial in multiple sclerosis funded by MS Canada; is a local Principal Investigator for commercial trials funded by Ionis and Roche; and has taken part in advisory boards or consultancy for Biogen, Contineum Therapeutics, FSD Pharma, InnoCare, Pheno Therapeutics, and Roche. OC holds a NIHR Research Professorship (RP-2017-08-ST2-004); received grants from the NIHR, UK MS Society, Medical Research Council, Rosetrees Trust; and received personal compensation for consulting or speaking from Novartis, Merck, Roche, Biogen, and Lundbeck. TC is an employee of the National Multiple Sclerosis USA, a sponsor of the International Committee on Clinical Trials in multiple sclerosis. JAC received personal compensation for consulting for Astoria, Bristol Myers Squibb, Convelo, and Viatris; and is a chair for a data safety and monitoring board DSMB for Celltrion. JCo received economic compensation for academic presentations, participation in advisory councils, and assistance to attend congresses from Biogen, Merck, Novartis, Roche, Bayer, Sanofi Genzyme, Gador, Raffo, Bristol Myers Squibb, and Janssen. FD has participated in meetings sponsored by or received honoraria for acting as an advisor or speaker for Alexion, Almirall, Biogen, Bristol Myers Squibb, Sanofi, Horizon, Janssen, Laurea Group, Medwhizz, Merck, Novartis Pharma, Neuraxpharm, Roche, Sandoz, and Teva; received research grants from Biogen, Novartis Pharma, and Sanofi (to institution); and is Section

Editor of *Multiple Sclerosis and Related Disorders* and Review Editor for *Frontiers Neurology*. MF received compensation for consulting services from Alexion, Almirall, Biogen, Merck, Novartis, Roche, and Sanofi; speaker fees from Bayer, Biogen, Celgene, Chiesi Italia SpA, Eli Lilly, Genzyme, Janssen, Merck Serono, Neopharmed Gentili, Novartis, Novo Nordisk, Roche, Sanofi, Takeda, and TEVA; participated in advisory boards for Alexion, Biogen, Bristol Myers Squibb, Merck, Novartis, Roche, Sanofi, Sanofi Aventis, Sanofi Genzyme, and Takeda; fees for scientific direction of educational events for Biogen, Merck, Roche, Celgene, Bristol Myers Squibb, Lilly, Novartis, and Sanofi Genzyme; and research support from Biogen Idec, Merck Serono, Novartis, Roche, the Italian Ministry of Health, the Italian Ministry of University and Research, and Fondazione Italiana Sclerosi Multipla. JF is an employee of the National Multiple Sclerosis USA, a sponsor of the International Committee on Clinical Trials in multiple sclerosis. MSF received research support from Sanofi Genzyme Canada; speaking fees from Hoffman-La Roche, Novartis, and EMD; honoraria and consulting fees from Amgen, AstraZeneca, EMD, EMD Serono, Merck Serono, Find Therapeutics, Hoffman La-Roche, Novartis, Sandoz, Sanofi Genzyme, Sentrex, and TEVA Canada Innovation; compensation for service on advisory boards and corporate boards for Amgen, AstraZeneca, Autolus, Bayer Healthcare, Celestra Health, EMD, Merck Serono, Find Therapeutics, Hoffman-La Roche, Neurogenesis, Novartis, Sanofi Genzyme, Sentrex, and Setpoint Medical; and compensation for serving on data safety monitoring boards for Abata Therapeutics, Celltrion, Hoffman-La Roche, and Moderna. DK served as a consultant for CVS Health; received research support from the UK MS Society, National Multiple Sclerosis Society, BMA Foundation, Horne Family Charitable Foundation, Biogen, and Merck; and received honoraria for advisory boards and educational activities from Biogen, Novartis, Sandoz, Roche, Janssen, and Merck. KF received grants from the Ministry of Education, Culture, Sports, Science and Technology of Japan and Ministry of Health, Welfare and Labor of Japan; personal compensation for consulting from Merck Biopharma, Japan Tobacco, and AbbVie; payment or honoraria for lectures and presentations from Biogen, Eisai, Mitsubishi Tanabe, Novartis, Chugai Roche, Alexion, VielaBio Horizon Therapeutics, Teijin, Asahi Kasei Medical, Merck, and Takeda; participated on an advisory board for Biogen, Mitsubishi Tanabe, Novartis, Chugai Roche, Alexion, VielaBio Horizon Therapeutics, and UCB; serves as the immediate past President of the Pan-Asian Committee for Treatment and Research in Multiple Sclerosis (unpaid); is the immediate past President of the Japanese Society of Neuroimmunology (unpaid); is a board member of the Japan Multiple Sclerosis Society (unpaid); is a board member of the European Charcot Foundation (unpaid); and is a member of the International Medical and Scientific Board (MSIF; unpaid). CG is supported by the Swiss National Science Foundation and the Stiftung zur Förderung der gastroenterologischen und allgemeinen klinischen Forschung; received the fees that were used exclusively for research support from Siemens, GeNeuro, Genzyme Sanofi, Biogen, Novartis, and Hoffman-La Roche (to institution); advisory board and consultancy fees from Actelion, Genzyme Sanofi, Novartis, GeNeuro, Merck, Biogen, and Hoffman-La Roche (to institution); and speaker fees from Genzyme Sanofi, Novartis, GeNeuro, Merck, Biogen, and Hoffmann-La Roche (to institution). AJG receiveds grants from the Conrad N Hilton Foundation and the Tom Sherak MS Hope Foundation; other financial relationships for activities as expert witness, Associate Editor, advisory board or steering committee participation, and endpoint adjudication from Bionure, Inception Sciences, *JAMA Neurology*, MedImmune Viela Bio, Mylan, Synthon, and Trims Pharma; and personal fees from Pipeline Therapeutics. H-PH received honoraria for serving on a steering committee from Sanofi, TG Therapeutics, and Hoffmann-La Roche; served on data monitoring committees for Boehringer Ingelheim, Merck, and Novartis; and received consulting fees from Neuraxpharm and Aurinia Pharma. KH received speaker honoraria and research support from Bayer, Biogen, Bristol Myers Squibb, Merck, Novartis, Sanofi Genzyme, Roche, Viatris, and TEVA; support for congress participation from Merck, Roche, Sanofi Genzyme, and Novartis; and has served on scientific advisory boards for Sanofi Genzyme, TEVA, Roche, Novartis, and Merck. LK received research support, including steering committee, advisory board, and consultancy fees from Actelion, Bayer, Biogen, Bristol Myers Squibb, GlaxoSmithKline, Janssen Johnson & Johnson, Japan Tobacco, Merck, Novartis, Roche, Sanofi, Santhera, Shionogi, and TG Therapeutics (to institution); speaker fees from Bayer, Biogen, Merck, Novartis, Roche, and Sanofi; support of educational activities from Allergan, Bayer, Biogen, CSL Behring, Desitin, Merck, Novartis, Pfizer, Roche, Sanofi, Shire, and TEVA; license fees for Neurostatus platform access; and grants from Bayer, Biogen, the EU, InnoSwiss, Merck, Novartis, Roche, Swiss Multiple Sclerosis Society, and the Swiss National Research Foundation. JK received research grants for multicentre investigator-initiated trials DOT-MS (NCT04260711, ZonMW), Supernext (NCT04225312, Treatmeds) and BLOOMS (NCT05296161, ZonMW and Treatmeds); consulting fees from Hoffmann-La Roche, Biogen, TEVA, Merck, Novartis, Sandoz, and Sanofi Genzyme (to institution); reports speaker relationships with Hoffmann-La Roche, Biogen, Immunic, TEVA, Merck, Novartis, and Sanofi Genzyme (to institution); and is on the adjudication committee of multiple sclerosis clinical trials of Immunic (to institution). CL-F received travel support from the European Committee for Treatment and Research in Multiple Sclerosis (ECTRIMS). FL received research funding from Novartis, Biogen, Sanofi, National Multiple Sclerosis Society (NMSS), NIH, and Brainstorm Cell Therapeutics; consulting, advisory board, and data safety monitoring board fees from EMD Serono, Novartis, Sanofi Genzyme, Roche Genentech, Horizon Therapeutics Amgen, Bristol Myers Squibb, Brainstorm Cell Therapeutics, Mylan Viatris, Immunic, Avotres, LabCorp, Neuralight, SetPoint Medical, Hexal Sandoz, Baim Institute, Sudo Biosciences, Lapix Therapeutics, Biohaven Pharmaceuticals, Abata Therapeutics, Cognito Therapeutics, ImmPACT Bio, InnoCare Pharma, and Appia Bio; holds stock in Avotres, Neuralight, and Lapix Therapeutics; and received speaker fees from Sanofi. XM received compensation for lecture honoraria and travel expenses, participation in scientific meetings, clinical trial steering committee membership, or clinical advisory board participation from AbbVie, Actelion, Alexion, Bial PD, Biogen, Bristol Myers Squibb Celgene, EMD Serono, Genzyme, Hoffmann-La Roche, Immunic Therapeutics, Janssen Pharmaceuticals, Medday, Merck, Mylan, Nervgen, Neuraxpharm, Novartis, Peervoice, Samsung Biosys, Sandoz, Sanofi Genzyme, TEVA, TG Therapeutics, Excemed, Medscape, ECTRIMS, MSIF, and NMSS or any of their affiliates (to institution). JO holds the Waugh Family Chair in multiple sclerosis Research at St. Michael's Hospital, University of Toronto and received grant funding from MS Canada, Brain Canada, the National MS Society, Biogen-Idec, Roche, and EMD Serono; received personal compensation for consulting or speaker fees from Biogen Idec, Bristol Myers Squibb, EMD Serono, Eli Lilly, Horizon Therapeutics, Novartis, Roche, and Sanofi Genzyme. SO-R received compensation for consulting services, speaking honoraria, and travel expenses for participation in scientific meetings from Genzyme, Biogen, Novartis, Roche, Excemed, Merck, Moderna GlaxoSmithKline, Pfizer, and AstraZeneca; and research support from Novartis and GlaxoSmithKline. RAM received research funding from the Canadian Institutes of Health Research, MS Canada, Crohn's and Colitis Canada, National Multiple Sclerosis Society, Consortium of Multiple Sclerosis Centers, the Arthritis Society, Public Health Agency of Canada, Pfizer Foundation, Brain Canada, and the US Department of Defense; is a co-investigator on studies receiving funding from Biogen Idec and Roche Canada; and holds the Multiple Sclerosis Clinical Research Chair at Dalhousie University. RM serves on scientific advisory boards for Amgen Horizon Therapeutics, UCB, and Roche; and received funding for travel and fees from Amgen, Alexion, Biogen, Roche, and UCB. MM received financial support from the MUR PNRR Extended Partnership (MNESYS no. PE00000006 and DHEAL-COM no. PNC-E3-2022-23683267); research grants from ECTRIMS-European Magnetic Resonance Imaging in MS network (MAGNIMS), the UK MS Society, and Merck; salary as an Assistant Editor for *Neurology* and as social media Editor for *Multiple Sclerosis*; and honoraria from AbbVie, Biogen, Bristol Myers Squibb Celgene, Ipsen, Janssen, Merck, Novartis, Roche, and Sanofi Genzyme. AM received research support from Genzyme Sanofi; consulting fees from CVS Health, Biogen Idec, Corevitas, Mapi Pharma, Verana Health, and Viatris (Mylan); speaker fees from Biogen Idec, Alexion, and Amgen Horizon Therapeutics (all unbranded disease awareness programmes only). DR is supported by the Intramural Research Program of the NINDS NIH; and received research support from Abata Therapeutics and Sanofi. MAR received consulting fees from Biogen, Bristol Myers Squibb, Eli Lilly, Janssen, and Roche;

speaker honoraria from AstraZeneca, Biogen, Bristol Myers Squibb, Bromatech, Celgene, Genzyme, Horizon Therapeutics Italy, Merck Serono, Novartis, Roche, Sanofi, and TEVA; research support from the MS Society of Canada, the Italian Ministry of Health, the Italian Ministry of University and Research, and Fondazione Italiana Sclerosi Multipla. DO received research support from the NIH, NMSS, Patient Centered Outcomes Research Institute, Race to Erase MS Foundation, Genentech, Genzyme, Bristol Myers Squibb, and Novartis; and consulting fees from Bristol Myers Squibb, Genentech Roche, Novartis, and Contineum Therapeutics. SR received research funding from the NHMRC Australia, the Petre Foundation, the Brain Foundation, the Royal Australasian College of Physicians, and the University of Sydney; is supported by an NHMRC investigator grant (GNT2008339); serves as a consultant on an advisory board for UCB and Limbic Neurology; and has been an invited speaker for educational or research sessions coordinated by Biogen, Alexion, UCB, Novartis, Excemed, and Limbic Neurology. ÀR serves or served on scientific advisory boards for Novartis, Sanofi, Synthetic MR, Roche, and Biogen; received speaker honoraria from Bayer, Sanofi Genzyme, Merck Serono, TEVA, Novartis, Roche, Bristol Myers Squibb, and Biogen; is Chief Medical Officer and co-founder of TensorMedical; and receives research support from Fondo de Investigación en Salud (PI19/00950 and PI22/01589) from Instituto de Salud Carlos III, Spain. SS received consulting fees from Medical Logix for the development of continuing medical education programmes in neurology; has served on scientific advisory boards for Biogen, Novartis, Genentech, Clene Pharmaceuticals, Horizon therapeutics, and ReWind therapeutics; received consulting fees from Novartis, Genentech, JuneBrain, Innocare, Kiniksa, Lapix Therapeutics, and Setpoint Medical; is the Principal Investigator of investigator-initiated studies funded by Genentech, Biogen, and Novartis; was the site investigator of trials sponsored by MedDay Pharmaceuticals and Clene Pharmaceuticals; and is the site investigator of trials sponsored by Novartis and Lapix Therapeutics. AS received research funding from the Department of Defense Congressionally Directed Medical Research Program, Multiple Sclerosis Society of Canada, NMSS, Consortium of MS Centers; is a member of the editorial board for *Neurology*; serves as a consultant for Gryphon Bio, Sora Neuroscience, and Abata Therapeutics; has equity in Owl Therapeutics; is a member of the data and safety monitoring board for Central Vein Sign: A Diagnostic Biomarker in Multiple Sclerosis, P3 EQUATE Health Equity Research Network, a phase 3, randomised controlled trial of video telehealth rehabilitation to reduce hospital readmission in chronic obstructive pulmonary disease (Tele-COPD), and Methotrexate treatment of Arthritis caused by Chikungunya virus (MARCH) trials; and holds the Kenney Marie Dixon–Pickens Distinguished Professorship in Multiple Sclerosis Research. JS-G received compensation for consulting services and speaking honoraria from Bristol Myers Squibb, Sanofi, Merck, and Roche; is the Scientific Director of Revista de Neurología; is a member of the editorial committee of *Multiple Sclerosis* and received honorarium; and has received research support from Fondo de Investigación en Salud (PI19/00950 and PI22/00750) from Instituto de Salud Carlos III, Spain. DS received a pilot research grant from the NMSS (to institution); personal honoraria for lecturing from Roche; travel support from Roche; and is a committee member and Chair of the Multiple Sclerosis International Federation (unpaid). AJS received consulting fees from Octave Bioscience, Kiniksa, and TG Therapeutics; served on advisory boards for TG Therapeutics, Horizon Therapeutics, Genentech Roche, and Bristol Meyers Squibb; provided non-promotional speaking for EMD Serono; is a site Principal Investigator for contract research for Sanofi, Actelion, Genentech Roche, and Novartis; and received research funding from Bristol Myers Squibb. MPS received personal compensation for consulting services and for speaking activities from Merck, Novartis, Roche, Sanofi, Bristol Myers Squibb, Immunic, and Biogen. BS received compensation for lectures from Novartis, Roche, Biogen, Alexion, Merck, and Sanofi; research grant supports from Roche, Merck, and Novartis (to institution); and research funding from the Programme Hospitalier de Recherche Clinique from the French health ministry; and grants from the Big Brain Theory grant from Paris Brain Institute, France SEP-ARSEP, and Fondation pour la recherche médicale. MT received compensation for consulting services, speaking honoraria, and research support from Almirall, Bayer Schering Pharma, Biogen Idec, Genzyme, Immunic, Janssen, Merck Serono, Novartis, Roche, Sanofi Aventis, Viela Bio, and TEVA; and served on data safety monitoring boards for Parexel, UCB, and the Relapse Adjudication Committee for IMCYSE SA. HT received research support from the Canada Research Chair Program, the National Multiple Sclerosis Society, the CIHR, MS Canada, the Multiple Sclerosis Scientific Research Foundation, and the Fondation EDMUS contre la sclérose en plaques; served as an advisor for Canada's Drug Agency (2024–25, payment declined); is a clinical expert for the Scientific Advice Program; received travel expenses or registration fees to present at continuing medical eduation conferences or to attend meetings (as a member of the International Advisory Committee on Clinical Trials in Multiple Sclerosis) from the Consortium of MS Centres, the Canadian Neurological Sciences Federation, National MS Society, ECTRIMS ACTRIMS, and the American Academy of Neurology; and speaker honoraria are either declined or donated to an multiple sclerosis charity or to an unrestricted grant for use by HT's research group. AVdW served on advisory boards and received travel honoraria and unrestricted research grants from Novartis, Merck, and Roche; serves as the Chief Operating Officer of the non-profit MSBase Foundation (to self); and received research support from NHMRC Australia and MS Research Australia. SV is currently involved in industry sponsored trials with Novartis, and Sanofi; and has completed a trial with Alexion. HW received honoraria for acting as a member of scientific advisory boards from Alexion, Argenx, Biocryst, Bristol Myers Squibb, Cellerys, Galapagos, Janssen, Merck, Novartis, Sandoz Hexal, and uniQure; speaker honoraria and travel support from Alexion, AOCN, AstraZeneca, Biogen, BGP Products Operations GmbH, Bristol Myers Squibb, CEMCAT, EPG Health Medthority, Genzyme, Kohlhammer, Merck, MS at the Limits, Neurodiem, NMSS, Novartis, Ology, Roche, Sanofi, Springer, Streamed up, TEVA, Uvet, and WebMD Global; is a paid consultant for Alexion, Argenx, Argobio, Bristol Myers Squibb, Dianthus, EMD Serono, Fondazione Cariplo, Idorsia, Immunic, Immunovant, INmune Bio_Syneos Health, Janssen, LTS, Lundbeck, Merck, Muna Therapeutics, Myrobalan Therapeutics, Novartis, PSL Group, Red Nucleus, Roche, Samsung, Sangamo, Sanofi, Swiss Multiple Sclerosis Society, Teladochealth, Toleranzia, UCB, and Viatris; and received research funding from Deutsche Forschungsgemeinschaft, Deutsche Myasthenie Gesellschaft, the EU, Alexion, Amicus Therapeutics, Argenx, Biogen, CSL Behring, Hoffmann-La Roche, Genzyme, Merck, Novartis, Roche, and UCB. BW received grants from Deutsche Forschungsgemeinschaft, the German Ministry of Eduaction and Research, Baden-Württembeg Ministry of Science, Research and Arts, Dietmar-Hopp-Stiftung, Klaus-Tschira-Stiftung, Novartis, and Roche; and personal fees from Alexion, Argenx, INSTAND, Novartis, and Roche. BY received honoraria, consulting or speaker fees, and research grants from Merck Serono, Biogen, Bayer, Novartis, and Sanofi. AJT and PZ declare no competing interests.

Acknowledgments

The International Advisory Committee on Clinical Trials in Multiple Sclerosis and the consensus conference were supported by the European Committee for Treatments and Research in Multiple Sclerosis and the National Multiple Sclerosis Society USA. The views expressed are the authors' own and do not necessarily reflect those of the National Institutes of Health, the Department of Health and Human Services, or the US government.

References

1 Poser CM, Paty DW, Scheinberg L, et al. New diagnostic criteria for multiple sclerosis: guidelines for research protocols. *Ann Neurol* 1983; **13:** 227–31.

2 McDonald WI, Compston A, Edan G, et al. Recommended diagnostic criteria for multiple sclerosis: guidelines from the international panel on the diagnosis of multiple sclerosis. *Ann Neurol* 2001; **50:** 121–27.

3 Polman CH, Reingold SC, Edan G, et al. Diagnostic criteria for multiple sclerosis: 2005 revisions to the "McDonald Criteria". *Ann Neurol* 2005; **58:** 840–46.

4 Polman CH, Reingold SC, Banwell B, et al. Diagnostic criteria for multiple sclerosis: 2010 revisions to the McDonald criteria. *Ann Neurol* 2011; **69:** 292–302.

5 Thompson AJ, Banwell BL, Barkhof F, et al. Diagnosis of multiple sclerosis: 2017 revisions of the McDonald criteria. *Lancet Neurol* 2018; **17:** 162–73.

6 Arrambide G, Tintore M, Espejo C, et al. The value of oligoclonal bands in the multiple sclerosis diagnostic criteria. *Brain* 2018; **141:** 1075–84.

7 Tintore M, Cobo-Calvo A, Carbonell P, et al. Effect of changes in MS diagnostic criteria over 25 years on time to treatment and prognosis in patients with clinically isolated syndrome. *Neurology* 2021; **97:** e1641–52.

8 Beiki O, Frumento P, Bottai M, Manouchehrinia A, Hillert J. Changes in the risk of reaching multiple sclerosis disability milestones in recent decades: a nationwide population-based cohort study in Sweden. *JAMA Neurol* 2019; **76:** 665–71.

9 Jakimovski D, Kavak KS, Zakalik K, et al. Improvement in time to multiple sclerosis diagnosis: 25-year retrospective analysis from New York State MS Consortium (NYSMSC). *Mult Scler* 2023; **29:** 753–56.

10 Marrodan M, Piedrabuena MA, Gaitan MI, et al. Performance of McDonald 2017 multiple sclerosis diagnostic criteria and evaluation of genetic ancestry in patients with a first demyelinating event in Argentina. *Mult Scler* 2023; **29:** 559–67.

11 Hyun JW, Kim W, Huh SY, et al. Application of the 2017 McDonald diagnostic criteria for multiple sclerosis in Korean patients with clinically isolated syndrome. *Mult Scler* 2019; **25:** 1488–95.

12 Zhang K, Zhao Y, Liang Z, Wang C, Liu X. Validity of the McDonald criteria in predicting second events in multiple sclerosis. *Mult Scler Relat Disord* 2020; **43:** 102223.

13 Hacohen Y, Brownlee W, Mankad K, et al. Improved performance of the 2017 McDonald criteria for diagnosis of multiple sclerosis in children in a real-life cohort. *Mult Scler* 2020; **26:** 1372–80.

14 Souissi A, Mrabet S, Nasri A, et al. Clinical predictors of disease progression in a cohort of Tunisian progressive multiple sclerosis. *Mult Scler Relat Disord* 2021; **56:** 103232.

15 Gaitán MI, Sanchez M, Farez MF, et al. The frequency and characteristics of multiple sclerosis misdiagnosis in Latin America: a referral center study in Buenos Aires, Argentina. *Mult Scler* 2022; **28:** 1373–81.

16 Amezcua L, Robers MV, Soneji D, Manouvakhova O, Martinez A, Islam T. Inclusion of optic neuritis in dissemination in space improves the performance of McDonald 2017 criteria in Hispanic people with suspected multiple sclerosis. *Mult Scler* 2023; **29:** 1748–54.

17 Nolan-Kenney RC, Liu M, Akhand O, et al. Optimal intereye difference thresholds by optical coherence tomography in multiple sclerosis: an international study. *Ann Neurol* 2019; **85:** 618–29.

18 Bsteh G, Hegen H, Altmann P, et al. Diagnostic performance of adding the optic nerve region assessed by optical coherence tomography to the diagnostic criteria for multiple sclerosis. *Neurology* 2023; **101:** e784–93.

19 Vidal-Jordana A, Rovira A, Calderon W, et al. Adding the optic nerve in multiple sclerosis diagnostic criteria: a longitudinal, prospective, multicenter study. *Neurology* 2024; **102:** e200805.

20 Brownlee WJ, Miszkiel KA, Tur C, Barkhof F, Miller DH, Ciccarelli O. Inclusion of optic nerve involvement in dissemination in space criteria for multiple sclerosis. *Neurology* 2018; **91:** e1130–34.

21 Solomon AJ, Arrambide G, Brownlee WJ, et al. Differential diagnosis of suspected multiple sclerosis: an updated consensus approach. *Lancet Neurol* 2023; **22:** 750–68.

22 De Stefano N, Giorgio A, Tintore M, et al. Radiologically isolated syndrome or subclinical multiple sclerosis: MAGNIMS consensus recommendations. *Mult Scler* 2018; **24:** 214–21.

23 Lebrun-Frénay C, Okuda DT, Siva A, et al. The radiologically isolated syndrome: revised diagnostic criteria. *Brain* 2023; **146:** 3431–43.

24 Lebrun-Frénay C, Kantarci O, Siva A, Sormani MP, Pelletier D, Okuda DT. Radiologically isolated syndrome: 10-year risk estimate of a clinical event. *Ann Neurol* 2020; **88:** 407–17.

25 Lebrun-Frénay C, Rollot F, Mondot L, et al. Risk factors and time to clinical symptoms of multiple sclerosis among patients with radiologically isolated syndrome. *JAMA Netw Open* 2021; **4:** e2128271.

26 Höglinger GU, Adler CH, Berg D, et al. A biological classification of Parkinson's disease: the SynNeurGe research diagnostic criteria. *Lancet Neurol* 2024; **23:** 191–204.

27 Jack CR Jr, Andrews JS, Beach TG, et al. Revised criteria for diagnosis and staging of Alzheimer's disease: Alzheimer's Association Workgroup. *Alzheimers Dement* 2024; **20:** 5143–69.

28 Simuni T, Chahine LM, Poston K, et al. A biological definition of neuronal alpha-synuclein disease: towards an integrated staging system for research. *Lancet Neurol* 2024; **23:** 178–90.

29 Solomon AJ, Klein EP, Bourdette D. "Undiagnosing" multiple sclerosis: the challenge of misdiagnosis in MS. *Neurology* 2012; **78:** 1986–91.

30 Banwell B, Bennett JL, Marignier R, et al. Diagnosis of myelin oligodendrocyte glycoprotein antibody-associated disease: International MOGAD Panel proposed criteria. *Lancet Neurol* 2023; **22:** 268–82.

31 Wingerchuk DM, Banwell B, Bennett JL, et al. International consensus diagnostic criteria for neuromyelitis optica spectrum disorders. *Neurology* 2015; **85:** 177–89.

32 Jarius S, Aktas O, Ayzenberg I, et al. Update on the diagnosis and treatment of neuromyelits optica spectrum disorders (NMOSD) – revised recommendations of the Neuromyelitis Optica Study Group (NEMOS). Part I: diagnosis and differential diagnosis. *J Neurol* 2023; **270:** 3341–68.

33 Kuhlmann T, Moccia M, Coetzee T, et al. Multiple sclerosis progression: time for a new mechanism-driven framework. *Lancet Neurol* 2023; **22:** 78–88.

34 Solomon AJ, Naismith RT, Cross AH. Misdiagnosis of multiple sclerosis: impact of the 2017 McDonald criteria on clinical practice. *Neurology* 2019; **92:** 26–33.

35 Sinnecker T, Clarke MA, Meier D, et al. Evaluation of the central vein sign as a diagnostic imaging biomarker in multiple sclerosis. *JAMA Neurol* 2019; **76:** 1446–56.

36 Hemond CC, Reich DS, Dundamadappa SK. Paramagnetic rim lesions in multiple sclerosis: comparison of visualization at 1·5-T and 3-T MRI. *AJR Am J Roentgenol* 2022; **219:** 120–31.

37 Hegen H, Berek K, Bsteh G, et al. Kappa free light chain and neurofilament light independently predict early multiple sclerosis disease activity-a cohort study. *EBioMedicine* 2023; **91:** 104573.

38 McMillan SS, King M, Tully MP. How to use the nominal group and Delphi techniques. *Int J Clin Pharm* 2016; **38:** 655–62.

39 Caldito NG, Saidha S, Sotirchos ES, et al. Brain and retinal atrophy in African-Americans versus Caucasian-Americans with multiple sclerosis: a longitudinal study. *Brain* 2018; **141:** 3115–29.

40 Gray-Roncal K, Fitzgerald KC, Ryerson LZ, et al. Association of disease severity and socioeconomic status in Black and White Americans with multiple sclerosis. *Neurology* 2021; **97:** e881–89.

41 Souissi A, Mrabet S, Nasri A, et al. Multiple sclerosis 2017 McDonald criteria are also relevant for Tunisians. *Mult Scler Relat Disord* 2020; **43:** 102161.

42 Zheng Y, Shen CH, Wang S, et al. Application of the 2017 McDonald criteria in a Chinese population with clinically isolated syndrome. *Ther Adv Neurol Disord* 2020; **13:** 1756286419898083.

43 Pagani Cassará F, Curbelo MC, Vazquez G, et al. Application of the 2017 McDonald criteria for the diagnosis of multiple sclerosis after a first demyelinating event in patients from Argentina. *Mult Scler Relat Disord* 2020; **41:** 102043.

44 Calabrese M, Gasperini C, Tortorella C, et al. "Better explanations" in multiple sclerosis diagnostic workup: a 3-year longitudinal study. *Neurology* 2019; **92:** e2527–37.

45 Tintore M, Rovira A, Rio J, et al. Defining high, medium and low impact prognostic factors for developing multiple sclerosis. *Brain* 2015; **138:** 1863–74.

46 Freiha J, Riachi N, Chalah MA, Zoghaib R, Ayache SS, Ahdab R. Paroxysmal symptoms in multiple sclerosis–a review of the literature. *J Clin Med* 2020; **9:** 3100.

47 Balcer LJ. Clinical practice. Optic neuritis. *N Engl J Med* 2006; **354:** 1273–80.

48 Ikuta F, Zimmerman HM. Distribution of plaques in seventy autopsy cases of multiple sclerosis in the United States. *Neurology* 1976; **26:** 26–28.

49 Outteryck O, Lopes R, Drumez E, et al. Optical coherence tomography for detection of asymptomatic optic nerve lesions in clinically isolated syndrome. *Neurology* 2020; **95:** e733–44.

50 Davion JB, Lopes R, Drumez E, et al. Asymptomatic optic nerve lesions: an underestimated cause of silent retinal atrophy in MS. *Neurology* 2020; **94:** e2468–78.

51 Saidha S, Green AJ, Leocani L, et al. The use of optical coherence tomography and visual evoked potentials in the 2024 McDonald diagnostic criteria for multiple sclerosis. *Lancet Neurol* 2025; **24:** 880–92.

52 Vidal-Jordana A, Sastre-Garriga J, Tintore M, Rovira A, Montalban X. Optic nerve topography in multiple sclerosis diagnostic criteria: existing knowledge and future directions. *Mult Scler* 2024; **30:** 139–49.

53 Petzold A, Fraser CL, Abegg M, et al. Diagnosis and classification of optic neuritis. *Lancet Neurol* 2022; **21:** 1120–34.

54 Barkhof F, Reich DS, Oh J, et al. 2024 MAGNIMS–CMSC–NAIMS consensus recommendations on the use of MRI for the diagnosis of multiple sclerosis. *Lancet Neurol* 2025; **24:** 866–79.

55 Vidal-Jordana A, Rovira A, Arrambide G, et al. Optic nerve topography in multiple sclerosis diagnosis: the utility of visual evoked potentials. *Neurology* 2021; **96:** e482–90.

56 Habek M, Pavicic T, Ruska B, et al. Establishing the diagnosis of multiple sclerosis in Croatian patients with clinically isolated syndrome: 2010 versus 2017 McDonald criteria. *Mult Scler Relat Disord* 2018; **25:** 99–103.

57 Clarke MA, Pareto D, Pessini-Ferreira L, et al. Value of 3T susceptibility-weighted imaging in the diagnosis of multiple sclerosis. *AJNR Am J Neuroradiol* 2020; **41:** 1001–08.

58 Filippi M, Preziosa P, Banwell BL, et al. Assessment of lesions on magnetic resonance imaging in multiple sclerosis: practical guidelines. *Brain* 2019; **142:** 1858–75.

59 Dutra BG, da Rocha AJ, Nunes RH, Maia ACMJ. Neuromyelitis optica spectrum disorders: spectrum of MR imaging findings and their differential diagnosis. *Radiographics* 2018; **38:** 169–93.

60 Fisniku LK, Brex PA, Altmann DR, et al. Disability and T2 MRI lesions: a 20-year follow-up of patients with relapse onset of multiple sclerosis. *Brain* 2008; **131:** 808–17.

61 Brownlee WJ, Vidal-Jordana A, Shatila M, et al. Towards a unified set of diagnostic criteria for multiple sclerosis. *Ann Neurol* 2025; **97:** 571–82.

62 Allison RS, Millar JH. Prevalence of disseminated sclerosis in Northern Ireland. *Ulster Med J* 1954; **23** (suppl 2): 1–27.

63 Schumacher GA, Beebe G, Kibler RF, et al. Problems of experimental trials of therapy in multiple sclerosis: report by the panel on the evaluation of experimental trials of therapy in multiple sclerosis. *Ann N Y Acad Sci* 1965; **122:** 552–68.

64 Rose AS, Ellison GW, Myers LW, Tourtellotte WW. Criteria for the clinical diagnosis of multiple sclerosis. *Neurology* 1976; **26:** 20–22.

65 Freedman MS, De Stefano N, Barkhof F, et al. Patient subgroup analyses of the treatment effect of subcutaneous interferon beta-1a on development of multiple sclerosis in the randomized controlled REFLEX study. *J Neurol* 2014; **261:** 490–99.

66 Freedman MS, Comi G, Coyle PK, et al. No evidence of disease activity status in patients treated with early vs. delayed subcutaneous interferon beta-1a. *Mult Scler Relat Disord* 2020; **39:** 101891.

67 Erbayat Altay E, Fisher E, Jones SE, Hara-Cleaver C, Lee JC, Rudick RA. Reliability of classifying multiple sclerosis disease activity using magnetic resonance imaging in a multiple sclerosis clinic. *JAMA Neurol* 2013; **70:** 338–44.

68 Brownlee WJ, Miszkiel KA, Altmann DR, Ciccarelli O, Miller DH. Periventricular lesions and MS diagnostic criteria in young adults with typical clinically isolated syndromes. *Mult Scler* 2017; **23:** 1031–34.

69 Arrambide G, Tintore M, Auger C, et al. Lesion topographies in multiple sclerosis diagnosis: a reappraisal. *Neurology* 2017; **89:** 2351–56.

70 Rae-Grant AD, Wong C, Bernatowicz R, Fox RJ. Observations on the brain vasculature in multiple sclerosis: a historical perspective. *Mult Scler Relat Disord* 2014; **3:** 156–62.

71 Tan IL, van Schijndel RA, Pouwels PJ, et al. MR venography of multiple sclerosis. *AJNR Am J Neuroradiol* 2000; **21:** 1039–42.

72 Sati P, Oh J, Constable RT, et al. The central vein sign and its clinical evaluation for the diagnosis of multiple sclerosis: a consensus statement from the North American Imaging in Multiple Sclerosis Cooperative. *Nat Rev Neurol* 2016; **12:** 714–22.

73 Maggi P, Absinta M, Grammatico M, et al. Central vein sign differentiates multiple sclerosis from central nervous system inflammatory vasculopathies. *Ann Neurol* 2018; **83:** 283–94.

74 Daboul L, O'Donnell CM, Amin M, et al. A multicenter pilot study evaluating simplified central vein assessment for the diagnosis of multiple sclerosis. *Mult Scler* 2024; **30:** 25–34.

75 Mistry N, Abdel-Fahim R, Samaraweera A, et al. Imaging central veins in brain lesions with 3-T T2*-weighted magnetic resonance imaging differentiates multiple sclerosis from microangiopathic brain lesions. *Mult Scler* 2016; **22:** 1289–96.

76 Clarke MA, Samaraweera AP, Falah Y, et al. Single Test to ARrive at Multiple Sclerosis (STAR-MS) diagnosis: a prospective pilot study assessing the accuracy of the central vein sign in predicting multiple sclerosis in cases of diagnostic uncertainty. *Mult Scler* 2020; **26:** 433–41.

77 Toljan K, Daboul L, Raza P, et al. Diagnostic performance of central vein sign versus oligoclonal bands for multiple sclerosis. *Mult Scler* 2024; **30:** 1268–77.

78 Landes-Chateau C, Levraut M, Okuda DT, et al. The diagnostic value of the central vein sign in radiologically isolated syndrome. *Ann Clin Transl Neurol* 2024; **11:** 662–72.

79 Boccia VD, Lapucci C, Cellerino M, et al. Evaluating the central vein sign in paediatric-onset multiple sclerosis: a case series study. *Mult Scler* 2023; **29:** 475–78.

80 Harrison KL, Gaudioso C, Levasseur VA, et al. Central vein sign in pediatric multiple sclerosis and myelin oligodendrocyte glycoprotein antibody-associated disease. *Pediatr Neurol* 2023; **146:** 21–25.

81 Sacco S, Virupakshaiah A, Papinutto N, et al. Susceptibility-based imaging aids accurate distinction of pediatric-onset MS from myelin oligodendrocyte glycoprotein antibody-associated disease. *Mult Scler* 2023; **29:** 1736–47.

82 Margoni M, Preziosa PEP, Pagani E, et al. Assessment of central vein sign and paramagnetic rim lesions in pediatric multiple sclerosis. *Ann Clin Transl Neurol* 2024; **11:** 3031–36.

83 Kaisey M, Solomon ABG, Guerrero BL, et al. Preventing multiple sclerosis misdiagnosis using the "central vein sign": a real-world study. *Mult Scler Relat Disord* 2021; **48:** 102671.

84 Frischer JM, Weigand SD, Guo Y, et al. Clinical and pathological insights into the dynamic nature of the white matter multiple sclerosis plaque. *Ann Neurol* 2015; **78:** 710–21.

85 Absinta M, Sati P, Fechner A, Schindler MK, Nair G, Reich DS. Identification of chronic active multiple sclerosis lesions on 3T MRI. *AJNR Am J Neuroradiol* 2018; **39:** 1233–38.

86 Comabella M, Clarke MA, Schaedelin S, et al. CSF chitinase 3-like 1 is associated with iron rims in patients with a first demyelinating event. *Mult Scler* 2022; **28:** 71–81.

87 Hemond CC, Baek J, Ionete C, Reich DS. Paramagnetic rim lesions are associated with pathogenic CSF profiles and worse clinical status in multiple sclerosis: a retrospective cross-sectional study. *Mult Scler* 2022; **28:** 2046–56.

88 Martire MS, Moiola L, Rocca MA, Filippi M, Absinta M. What is the potential of paramagnetic rim lesions as diagnostic indicators in multiple sclerosis? *Expert Rev Neurother* 2022; **22:** 829–37.

89 Suthiphosuwan S, Sati P, Absinta M, et al. Paramagnetic rim sign in radiologically isolated syndrome. *JAMA Neurol* 2020; **77:** 653–55.

90 Absinta M, Sati P, Gaitan MI, et al. Seven-tesla phase imaging of acute multiple sclerosis lesions: a new window into the inflammatory process. *Ann Neurol* 2013; **74:** 669–78.

91 Meaton I, Altokhis A, Allen CM, et al. Paramagnetic rims are a promising diagnostic imaging biomarker in multiple sclerosis. *Mult Scler* 2022; **28:** 2212–20.

92 Tintoré M, Rovira A, Rio J, et al. Do oligoclonal bands add information to MRI in first attacks of multiple sclerosis? *Neurology* 2008; **70:** 1079–83.

93 Freedman MS, Thompson EJ, Deisenhammer F, et al. Recommended standard of cerebrospinal fluid analysis in the diagnosis of multiple sclerosis: a consensus statement. *Arch Neurol* 2005; **62:** 865–70.

94 Levraut M, Laurent-Chabalier S, Ayrignac X, et al. Kappa free light chain biomarkers are efficient for the diagnosis of multiple sclerosis: a large multicenter cohort study. *Neurol Neuroimmunol Neuroinflamm* 2023; **10:** e200049.

95 Rudick RA, Pallant A, Bidlack JM, Herndon RM. Free kappa light chains in multiple sclerosis spinal fluid. *Ann Neurol* 1986; **20:** 63–69.

96 Bradwell AR, Carr-Smith HD, Mead GP, et al. Highly sensitive, automated immunoassay for immunoglobulin free light chains in serum and urine. *Clin Chem* 2001; **47:** 673–80.

97 Hegen H, Walde J, Berek K, et al. Cerebrospinal fluid kappa free light chains for the diagnosis of multiple sclerosis: a systematic review and meta-analysis. *Mult Scler* 2023; **29:** 169–81.

98 Hegen H, Walde J, Milosavljevic D, et al. Free light chains in the cerebrospinal fluid. Comparison of different methods to determine intrathecal synthesis. *Clin Chem Lab Med* 2019; **57:** 1574–86.

99 Berek K, Bsteh G, Auer M, et al. Kappa-free light chains in CSF predict early multiple sclerosis disease activity. *Neurol Neuroimmunol Neuroinflamm* 2021; **8:** e1005.

100 Arrambide G, Espejo C, Carbonell-Mirabent P, et al. The kappa free light chain index and oligoclonal bands have a similar role in the McDonald criteria. *Brain* 2022; **145:** 3931–42.

101 Levraut M, Gavoille A, Landes-Chateau C, et al. Kappa free light chain index predicts disease course in clinically and radiologically isolated syndromes. *Neurol Neuroimmunol Neuroinflamm* 2023; **10:** e200156.

102 Hegen H, Berek K, Cavalla P, et al. Diagnostic value of kappa free light chain index in patients with primary progressive multiple sclerosis – a multicentre study. *Front Immunol* 2023; **14:** 1327947.

103 Hegen H, Arrambide G, Gnanapavan S, et al. Cerebrospinal fluid kappa free light chains for the diagnosis of multiple sclerosis: a consensus statement. *Mult Scler* 2023; **29:** 182–95.

104 Senel M, Tumani H, Lauda F, et al. Cerebrospinal fluid immunoglobulin kappa light chain in clinically isolated syndrome and multiple sclerosis. *PLoS One* 2014; **9:** e88680.

105 Crespi I, Vecchio D, Serino R, et al. K index is a reliable marker of intrathecal synthesis, and an alternative to IgG index in multiple sclerosis diagnostic work-up. *J Clin Med* 2019; **8:** 446.

106 Demortiere S, Stolowy N, Perriguey M, et al. Diagnostic utility of kappa free light chain index in adults with inaugural optic neuritis. *Neurol Neuroimmunol Neuroinflamm* 2025; **12:** e200386.

107 Deschamps R, Shor N, Papeix C, et al. Relevance of kappa free light chains index in patients with aquaporin-4 or myelin-oligodendrocyte-glycoprotein antibodies. *Eur J Neurol* 2023; **30:** 2865–69.

108 Deisenhammer F, Hegen H, Arrambide G, et al. 'Positive cerebrospinal fluid in the 2024 McDonald criteria for Multiple Sclerosis. *eBioMedicine* (in press).

109 Lebrun-Frenay C, Kantarci O, Siva A, et al. Radiologically isolated syndrome. *Lancet Neurol* 2023; **22:** 1075–86.

110 Matute-Blanch C, Villar LM, Alvarez-Cermeno JC, et al. Neurofilament light chain and oligoclonal bands are prognostic biomarkers in radiologically isolated syndrome. *Brain* 2018; **141:** 1085–93.

111 Lebrun-Frénay C. The confavreux lecture: the radiologically isolated syndrome diagnosis, prognosis and perspectives. *Mult Scler* 2025; **31:** 249–56.

112 Suthiphosuwan S, Sati P, Guenette M, et al. The central vein sign in radiologically isolated syndrome. *AJNR Am J Neuroradiol* 2019; **40:** 776–83.

113 Fadda G, Brown RA, Longoni G, et al. MRI and laboratory features and the performance of international criteria in the diagnosis of multiple sclerosis in children and adolescents: a prospective cohort study. *Lancet Child Adolesc Health* 2018; **2:** 191–204.

114 van Pelt ED, Mescheriakova JY, Makhani N, et al. Risk genes associated with pediatric-onset MS but not with monophasic acquired CNS demyelination. *Neurology* 2013; **81:** 1996–2001.

115 Fadda G, Yea C, O'Mahony J, et al. Epstein–Barr virus strongly associates with pediatric multiple sclerosis, but not myelin oligodendrocyte glycoprotein-antibody-associated disease. *Ann Neurol* 2024; **95:** 700–05.

116 Iaffaldano P, Portaccio E, Lucisano G, et al. Multiple sclerosis progression and relapse activity in children. *JAMA Neurol* 2024; **81:** 50–58.

117 Verhey LH, Branson HM, Shroff MM, et al. MRI parameters for prediction of multiple sclerosis diagnosis in children with acute CNS demyelination: a prospective national cohort study. *Lancet Neurol* 2011; **10:** 1065–73.

118 Baroncini D, Simone M, Iaffaldano P, et al. Risk of persistent disability in patients with pediatric-onset multiple sclerosis. *JAMA Neurol* 2021; **78:** 726–35.

119 Gorman MP, Healy BC, Polgar-Turcsanyi M, Chitnis T. Increased relapse rate in pediatric-onset compared with adult-onset multiple sclerosis. *Arch Neurol* 2009; **66:** 54–59.

120 McKay KA, Hillert J, Manouchehrinia A. Long-term disability progression of pediatric-onset multiple sclerosis. *Neurology* 2019; **92:** e2764–73.

121 Margoni M, Preziosa P, Storelli L, et al. Paramagnetic rim and core sign lesions in paediatric multiple sclerosis patients. *J Neurol Neurosurg Psychiatry* 2023; **94:** 873–76.

122 Sarthou A, Chretien P, Giorgi L, et al. The kappa free light chains index is an accurate diagnostic biomarker for paediatric multiple sclerosis. *Mult Scler* 2024; **30:** 1436–44.

123 Wong YYM, de Mol CL, van der Vuurst de Vries RM, et al. Real-world validation of the 2017 McDonald criteria for pediatric MS. *Neurol Neuroimmunol Neuroinflamm* 2019; **6:** e528.

124 Fadda G, Waters P, Woodhall M, et al. Serum MOG-IgG in children meeting multiple sclerosis diagnostic criteria. *Mult Scler* 2022; **28:** 1697–709.

125 Gaudioso CM, Mar S, Casper TC, et al. MOG and AQP4 antibodies among children with multiple sclerosis and controls. *Ann Neurol* 2023; **93:** 271–84.

126 Blok KM, Smolders J, van Rosmalen J, Martins Jarnalo CO, Wokke B, de Beukelaar J. Real-world challenges in the diagnosis of primary progressive multiple sclerosis. *Eur J Neurol* 2023; **30:** 3799–808.

127 Antel J, Antel S, Caramanos Z, Arnold DL, Kuhlmann T. Primary progressive multiple sclerosis: part of the MS disease spectrum or separate disease entity? *Acta Neuropathol* 2012; **123:** 627–38.

128 de Boer A, van den Bosch AMR, Mekkes NJ, et al. Disentangling the heterogeneity of multiple sclerosis through identification of independent neuropathological dimensions. *Acta Neuropathol* 2024; **147:** 90.

129 Filippi M, Preziosa P, Barkhof F, et al. Diagnosis of progressive multiple sclerosis from the imaging perspective: a review. *JAMA Neurol* 2021; **78:** 351–64.

130 Montalban X, Sastre-Garriga J, Filippi M, et al. Primary progressive multiple sclerosis diagnostic criteria: a reappraisal. *Mult Scler* 2009; **15:** 1459–65.

131 Marrie RA. Comorbidity in multiple sclerosis: implications for patient care. *Nat Rev Neurol* 2017; **13:** 375–82.

132 Midaglia L, Sastre-Garriga J, Pappolla A, et al. The frequency and characteristics of MS misdiagnosis in patients referred to the multiple sclerosis centre of Catalonia. *Mult Scler* 2021; **27:** 913–21.

133 Portaccio E, Magyari M, Havrdova EK, et al. Multiple sclerosis: emerging epidemiological trends and redefining the clinical course. *Lancet Reg Health Eur* 2024; **44:** 100977.

134 Solomon AJ, Bourdette DN, Cross AH, et al. The contemporary spectrum of multiple sclerosis misdiagnosis: a multicenter study. *Neurology* 2016; **87:** 1393–99.

135 Casini G, Yurashevich M, Vanga R, et al. Are periventricular lesions specific for multiple sclerosis? *J Neurol Neurophysiol* 2013; **4:** 150.

136 Lapucci C, Saitta L, Bommarito G, et al. How much do periventricular lesions assist in distinguishing migraine with aura from CIS? *Neurology* 2019; **92:** e1739–44.

137 Filippi M, Preziosa P, Meani A, et al. Performance of the 2017 and 2010 revised McDonald criteria in predicting MS diagnosis after a clinically isolated syndrome: a MAGNIMS study. *Neurology* 2022; **98:** e1–14.

138 Absinta M, Rocca MA, Colombo B, et al. Patients with migraine do not have MRI-visible cortical lesions. *J Neurol* 2012; **259:** 2695–98.

139 Liu S, Kullnat J, Bourdette D, et al. Prevalence of brain magnetic resonance imaging meeting Barkhof and McDonald criteria for dissemination in space among headache patients. *Mult Scler* 2013; **19:** 1101–05.

140 Geraldes R, Jurynczyk M, Dos Passos GR, et al. The role of pontine lesion location in differentiating multiple sclerosis from vascular risk factor-related small vessel disease. *Mult Scler* 2021; **27:** 968–72.

141 Lapucci C, Tazza F, Rebella S, et al. Central vein sign and diffusion MRI differentiate microstructural features within white matter lesions of multiple sclerosis patients with comorbidities. *Front Neurol* 2023; **14:** 1084661.

142 Guisset F, Lolli V, Bugli C, et al. The central vein sign in multiple sclerosis patients with vascular comorbidities. *Mult Scler* 2021; **27:** 1057–65.

Copyright © 2025 Elsevier Ltd. All rights reserved, including those for text and data mining, AI training, and similar technologies.