Bioscience, Biotechnology, and Biochemistry, 2023, Vol. 87, No. 3, 279-289

https:/doi.org/10.1093/bbb/zbac198
Advance access publication date: 9 December 2022
REGULAR PAPER

REGULAR PAPER

Hericium erinaceus polysaccharide improves the microstructure, immune function, proliferation and reduces apoptosis of thymus and spleen tissue cells of immunosuppressed mice

Yujiao Han,[1] Jialiang Huang,[1] Chunfang Zhao,[1] Feng Zhang,[1] Youfang Gu,[1,2] Chenfang Wang,[3,*] and Erhui Jin [1,2,*]

[1]College of Animal Science, Anhui Science and Technology University, Chuzhou, China; [2]Anhui Province Key Laboratory of Animal Nutritional Regulation and Health, Chuzhou, China; and [3]College of life and Health Sciences, Anhui Science and Technology University, Chuzhou, China

*Correspondence: Chenfang Wang, wangcf@ahstu.edu.cn; Erhui Jin, jineh@ahstu.edu.cn

Downloaded from https://academic.oup.com/bbb/article/87/3/279/6886539 by guest on 11 November 2025

ABSTRACT

In order to study the effect of *Hericium erinaceus* polysaccharide (HEP) on the immune and antioxidation functions of immunosuppressed mice. The control group received distilled water orally and the model and experimental groups I, II, and III received 0, 80, 160, and 320 mg/kg HEP respectively for a fortnight after re-molding with cyoclphosphnalide (CTX). Compared with the control group, the secretion of IL-2, IL-4, and IFN-γ, the activity or content of T-AOC, T-SOD, and GSH-PX, and the expression of PCNA mRNA in the thymus and spleen were reduced in immunosuppressed mice ($P < .05$ or $P < .01$). Compared with immunosuppressed mice, the levels of IL-2, IFN-γ, and GSH-PX and the PCNA mRNA expression of spleen and thymus were increased ($P < .05$ or $P < .01$), and the microstructure were also obviously improved in the experimental group III. Overall, 320 mg/kg of HEP significantly improved the immune and antioxidant functions.

Graphical Abstract

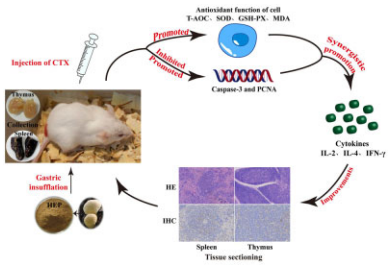

HEP can improve cytokine secretion by regulating antioxidant function and expression of apoptosis-related genes, thereby ameliorating tissue microstructure of thymus and spleen.

Received: 12 July 2022; **Accepted:** 1 December 2022
© The Author(s) 2022. Published by Oxford University Press on behalf of Japan Society for Bioscience, Biotechnology, and Agrochemistry. This is an Open Access article distributed under the terms of the Creative Commons Attribution-NonCommercial License (https://creativecommons.org/licenses/by-nc/4.0/), which permits non-commercial re-use, distribution, and reproduction in any medium, provided the original work is properly cited. For commercial re-use, please contact journals.permissions@oup.com

Keywords: *Hericium erinaceus* polysaccharide, microstructure, immune function, antioxidant function, cell proliferation and apoptosis

Immunosuppression is a manifestation of an abnormal immune response. Immunosuppression impairs immune cell activities, including antigen presentation, antibody synthesis, and the secretion of cytokines and other immune mediators. Together, these events weaken the immune response or disease resistance, predisposing the animal to infection and promoting tumorigenesis (Pelaez *et al.* 2001). In contemporary livestock production, the irrational use of antibiotics, feeding livestock on feeds contaminated with mycotoxins, and frequent infection with immunosuppression-related pathogenic microorganisms increase the risk of immunosuppression. Impaired immune response reduces the effectiveness of vaccines and increases the susceptibility of animals to diseases and death, greatly impacting animal husbandry (Mcdaid *et al.* 2015). Nutrition regulation technology aims at reducing immunosuppression and enhancing the immune function of animals. Therefore, under the pressure of resistance reduction, how to improve the state of animal immunosuppression and enhance the immune function of the organism through nutritional regulation technology has become a key problem to be solved in animal husbandry production. Cyoclphosphnalide (CTX), a combination of nitrogen mustard with phosphoramidite, inhibits the proliferation of cells by disrupting DNA synthesis or impairs immune function by inhibiting antibody production. Accordingly, CTX is widely used in establishing immunosuppressed animal models (Siegel, Liu and Cleicher 1981; Luster *et al.* 1992; Vallant *et al.* 2007; Elazab *et al.* 2021).

Hericium erinaceus is an edible mushroom containing numerous nutritional and medicinal compounds, including *Hericium* polysaccharide, *Hericium* ketone, sterols, etc. Among them, *H. erinaceus* polysaccharide (HEP), with the most significant health function, is widely present in the fruiting bodies, mycelium, and fermented broth of *H. erinaceus* (He *et al.* 2017). In recent years, numerous studies have shown that HEP strengthens the stomach (Wang *et al.* 2019), improves immune functions, inhibits the growth and proliferation of tumor cells (Lee and Hong 2010), is antioxidant (Chen *et al.* 2015), and lowers blood sugar (Chen *et al.* 2017). HEP significantly enhances CTX-induced immune organ index in immunosuppressed mice, induces spleen lymphocyte proliferation, natural killer cell activity, IL-2 secretion, and macrophage phagocytosis, and protects the immune organs (Wu *et al.* 2018). Xylanase and fermentable polysaccharides secreted by *H. erinaceus* reduce infections in broiler chickens by enhancing antioxidation and anti-inflammatory functions and increasing the abundance/diversity of probiotics, including *Bacillus licheniformis, Bacillus subtilis,* and *Lactobacillus plantarum* (Zhang *et al.* 2018). Also, HEP activates rat dendritic cells, increases the expression of major histocompatibility complex class II and CD 80/86 surface antigens, and decreases endocytosis of dendritic cells (Sheu *et al.* 2013).

These findings indicated that HEP could increase the index of immune organs, increase resistance against pathogens in animals, and enhance cellular immune function. However, the effect of HEP on the microstructure, immune and antioxidation functions, and proliferation and apoptosis of immune organ cells of immunosuppressed animals remain unclear. In the present study, the mouse immunosuppressed model was established through intraperitoneal CTX injection. Different HEP dosages were administrated orally. The effects of HEP on the microstructure of immune organs, immune and antioxidation function, and proliferation and apoptosis of cells were then assessed. The findings of this study will provide solid evidence on the effect of HEP on the aforementioned events in humans and animals with immunosuppressed abnormalities.

Materials and methods

Immunosuppressed animal model

A total of 50 healthy specific pathogen-free (SPF) 12-weeks-old male Kunming mice were purchased from Nanjing Jiangning District Qinglongshan Experimental Animal Breeding Farm (production license number SCXK [Su] 2017-001). Animal use was approved by Anhui Science and Technology University Experimental Animal Ethics Committee (Approval No.2022026). The mice were housed in indexed vertex cache of the SPF Laboratory Animal Center of Anhui Institute of Science and Technology. Each cage contained five mice. The temperature was maintained at 25-27 °C, the relative humidity at 40%-60%, and light for 12 h. The mouse bedding was autoclaved at 121 °C for 20 min and blast dried at 60 °C before use.

After 1 week of acclimatization, the mice were randomly divided into the control group, model group, and experimental groups I, II, and III. Each group contained 10 mice. Mice in experimental groups I, II, and III received an oral dose of 80 mg/kg, 160 mg/kg, and 320 mg/kg, respectively, of HEP once a day for 2 weeks. The CTX and experimental groups I, II, and III received intraperitoneal injections of 1.5 mL/kg/d of CTX (diluted to 1 mg/mL in saline) for 3 days before the end of the test, whereas the control group received a similar dose of saline for 3 days. Thymus and spleen tissue were collected 12 h after the last CTX injection.

Source of primary reagents

HEP (polysaccharide content 50%) was purchased from Xi′an Shengqing Biotechnology Co., Ltd., (Xi′an, China). Cyclophosphamide (purity 98.9%, PHR1404) was purchased from Sigma–Aldrich (St. Louis, USA), interleukin-2 (IL-2), interleukin-4 (IL-4), and interferon-γ (IFN-γ) ELISA kits (Cat: SMK5699A, SMK3400A, SMK2918A) were purchased from Beijing Dakome Technology Co. Ltd., (Beijing, China). Animal Tissue Total RNA Extraction Kit (Cat: DP431) was purchased from Tiangen Biochemical Technology Co., Ltd., (Beijing, China). Real-time Fluorescence Quantitative PCR Kit (Cat: RR420e) was purchased from Baobao Biological (Dalian) Engineering Co., Ltd., (Dalian, China). Superoxide dismutase (T-SOD, Cat: A001-3-2), glutathione peroxidase (GSH-Px, Cat: A005-1-2), total antioxidant capacity (T-AOC, Cat: A015-3-1), and malondialdehyde (MDA, Cat: A003-1-1) assay kits were purchased from Nanjing Jiancheng Institute of Biological Engineering Co., Ltd., (Nanjing, China).

Primers used in this research were synthesized by Shanghai Bioengineering Co., Ltd. (Shanghai, China) and included 5′-CAC CTT AGC ACT AGT ATT CGA AGC AC-3′, and 5′-CAC CCG ACG GCA TCT TTAT TAC-3′ for proliferating cell nuclear antigen (PCNA); 5′-CTG CCG GAG TCT GAC TGG AA-3′, and 5′-ATC AGT CCC ACT GTC TCT GTC TCA ATG-3′ for Caspase-3; 5′-CTG CCG

Downloaded from https://academic.oup.com/bbb/article/87/3/279/6886539 by guest on 11 November 2025

GAG TCT GAC TGG AA-3′, and 5′-ATC AGT CCC ACT GTC TCT GTC TCA ATG-3′ for glyceraldehype-3 phosphate dehydrogenase (GAPDH) primer sequences are: upstream; 5′-TGT TTC CTC GTC CCG TAG-3′, and 5′-CAA TCT CCA CTT TGC CAC T-3′ for GAPDH.

Sample collection and processing

At the end of the experiment, six mice in each group were randomly selected and sacrificed after anesthetization with ether and cervical dislocation. The thymus and spleen were rapidly isolated and divided into three portions. The first portion for H&E staining and immunohistochemical analysis was fixed in 4% paraformaldehyde phosphate buffer. The second portion for measuring cytokine content and antioxidant function assay was frozen in liquid nitrogen and stored at −80 °C. The third portion for RNA extraction for cell proliferation and apoptosis gene expression assays was frozen in liquid nitrogen and stored at −80 °C.

H&E staining

The thymus and spleen tissues were fixed in 4% paraformaldehyde phosphate buffer, dehydrated in serial alcohol concentrations, cleaned using methyl salicylate, embedded in paraffin, and sliced into thin (6 μm thick) sections using a paraffin rotary microtome. Two slices of every 10 wax sections were selected for H&E staining and immunohistochemical analysis. The tissues were then observed and photographed using an automated digital microtome scanning and application system (VM1, McAudi, China). Thymus cortical thickness, spleen nodule area, and lymphatic sheath area around the spleen artery were measured using the IPP software, V 6.0.

Determining the cytokine content in the thymus and spleen tissues

Mice thymus and spleen tissues were thawed at room temperature and homogenized in an ice bath. Thereafter, 10% of tissue homogenate was prepared and centrifuged at 3,000 r/min for 15 min, and the supernatant was collected for further analyses. The IL-2, IL-4, and IFN-γ contents were determined using respective ELISA kits, following the manufacturer's instructions. The absorbance was measured using a full-wavelength enzyme marker (Multiskan GO US Thermoelectric). The correlation coefficients of the standard curves for determining IL-2, IL-4, and IFN-γ levels in the tissues were 0.9875, 0.9918, and 0.9914, respectively.

Antioxidant assay

Total protein content in the mouse thymus and spleen homogenates was determined using the Total Protein Assay Kit. T-AOC, T-SOD, MDA, and GSH-Px mediate antioxidation in the cell. The content or activity of these proteins was determined using the Antioxidant Function Assay Kit, according to the manufacturer's instructions.

Immunohistochemical assay

Thymus and spleen tissue sections were dewaxed in xylene, dehydrated using serial ethanol concentrations, washed three times with 0.01 mol/L phosphate-buffered saline (PBS, pH 7.4) for 5 min each time, and immersed in 0.1 mol/L citrate buffer (pH 6.0). To repair the antigens in the cells, the sections were heated in antigen repair agent at 100 °C for 15 min, cooled to room temperature, washed three times (5 min each time) with 0.01 mol/L PBS, and incubated with 10% normal horse serum or goat serum (in 0.01 mol/L PBS) for 30 min at room temperature. After shaking off the serum, a caspase-3 antibody was added dropwise before overnight incubation at 4 °C. The tissues were equilibrated at room temperature for 30 min, washed three times (5 min each time) with 0.01 mol/L PBS, and incubated for 2 h at 37 °C with biotinylated horse anti-mouse or goat anti-rabbit IgG. After three washes (5 min each time) with 0.01 mol/L PBS, the tissues were incubated for 2 h at 37 °C with HRP-labeled streptavidin and washed twice (5 min each time) with 0.01 mol/L PBS. The tissues were preincubated with DAB preincubation solution for 30 min, DAB chromogenic solution for 5 min, hematoxylin re-staining for 3 min, dehydrated using serial ethanol concentrations, and cleaned using xylene, and sealed with neutral resin. The cells were observed and photographed using an Olympus BX51 + DP73 ortho-fluorescence microscope. A total of 15 transverse thymus and spleen sections from each rat were selected for immunohistochemical staining. Five random tissue fields were observed and photographed. The integral optical density (IOD) of positive cells was determined using Image-Pro Plus software V. 6.0.

Cell proliferation and assessing the expression of apoptosis-related genes

Thymus and spleen tissues were added to separate lysates and ground using a high-throughput tissue grinder (TissueLyser II, Germany). Total RNA was extracted from the homogenates using the Animal Tissue Total RNA Extraction Kit. The total RNA concentration and quality were determined using a nucleic acid-protein analyzer (NanoDrop One, USA). cDNA was synthesized using a reverse transcription kit. Real-time fluorescent quantitative PCR was performed using the ABI QuantStudio 5 (ABI, USA) system. The GAPDH gene was used as an internal control, and the relative expression of genes was calculated using the $2^{-\Delta\Delta ct}$ method.

Statistical analysis

Data were analyzed using SPSS software V. 22.0. Differences between groups were analyzed using one-way ANOVA and Dunnett's test. Continuous randomly distributed data were expressed as mean ± standard deviation (Mean ± SD). Statistical significance was set at $P < .05$ or $P < .01$.

Results

HEP improves the microstructure and histological parameters of thymus and spleen in CTX-induced immunosuppressed mice

The thymus microstructure of mice in the control group was typical, with a clear thymus lobule, cortex, and medulla. The cortical layer of mice in this group was thick with dense and well-arranged cells, and the medullary region contained few thymus vesicles (Figure 1a). However, the thymus of mice in the model group showed obvious pathological changes, including blurred thymus lobule, the unclear boundary between the cortex and medulla, thin cortex, loosely arranged, large, and morphologically distorted cells, and many thymus vesicles in the medulla (Figure 1c). There was no significant difference

Downloaded from https://academic.oup.com/bbb/article/87/3/279/6886539 by guest on 11 November 2025

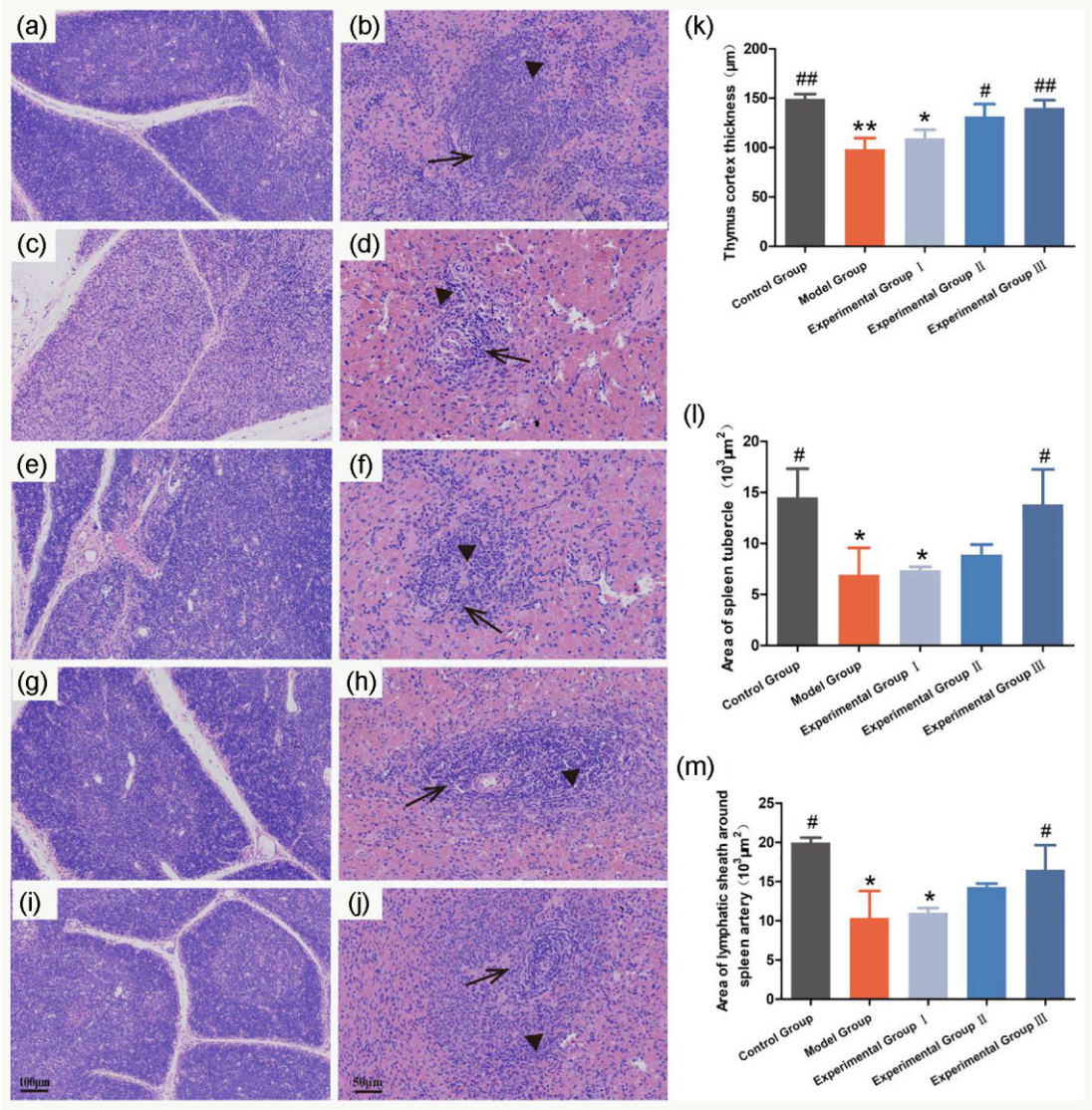

Figure 1. Effect of HEP on microstructure of thymus and spleen of Immunosuppressive Mice Induced by CTX. (a, c, e, g, i) Microstructure of thymus in control group (a), model group (c), experimental group I (e), experimental group II (g) and experimental group III (i). Magnification 100X and Scale bar 100 μm. (b, d, f, h, j): Microstructure of spleen in control group (b), model group (d), experimental group I (f), experimental group II (h) and experimental group III (j). Magnification 200X and Scale bar 50 μm. ▲ indicates splenic nodule, → indicates lymphatic sheath around splenic artery. (k) Thymus cortex thickness. (l) Area of spleen tubercle. (m) Area of lymphatic sheath around spleen artery. $^{*}P < .05$ or $^{**}P < .01$ vs Control Group; $^{\#}P < .05$ or $^{\#\#}P < .01$ vs Model Group.

between the thymus structure of mice in the model and experimental group I. However, the cortical thickness of mice in the experimental group I was thicker than that of mice in the model group. An opposite trend was observed for the number of thymus vesicles in the medulla (Figure 1e). The thymus microstructure of mice in experimental group II was better than that of mice in the model group. The thymus lobule was well structured, the cortex was thick, and the cells were many and closely packed (Figure 1g). Mice in experimental group III had a better thymus microstructure, with clear lobule, cortex, and medulla structures, well-arranged cells, and only a few thymus vesicles in the medullary region (Figure 1i).

The spleen microstructure of mice in the control group displayed normal development, with a clear red and white marrow, periarterial lymph sheath, and spleen nodules. The lymphocytes were well arranged and closely packed (Figure 1b). Compared with mice in the control group, the spleen microstructure of mice in the model group was abnormal. There was no clear boundary between white and red marrow, the outline of spleen nodes and peri-arterial lymphatic sheaths were also unclear, the spleen nodes were few, the peri-arterial lymphatic sheaths were few thinner, and the cells were loosely arranged. The spleen nodes were small, the cells were also loosely arranged, and vacuole-like structures were present in the white marrow (Figure 1d). Compared with the model group, there were no obvious microstructural changes in the spleen of mice in experimental group I, but the number of lymphocytes increased was high, and the cells were well arranged and tightly packed. The white medulla was more well-defined, the spleen nodules were many, and the spleen cords in the red medulla were relatively few (Figure 1f). The spleen microstructure of mice in experimental groups II and III was substantially better than that of the model group. Also, the spleen nodules were many and large; the lymphatic sheath around the

Downloaded from https://academic.oup.com/bbb/article/87/3/279/6886539 by guest on 11 November 2025

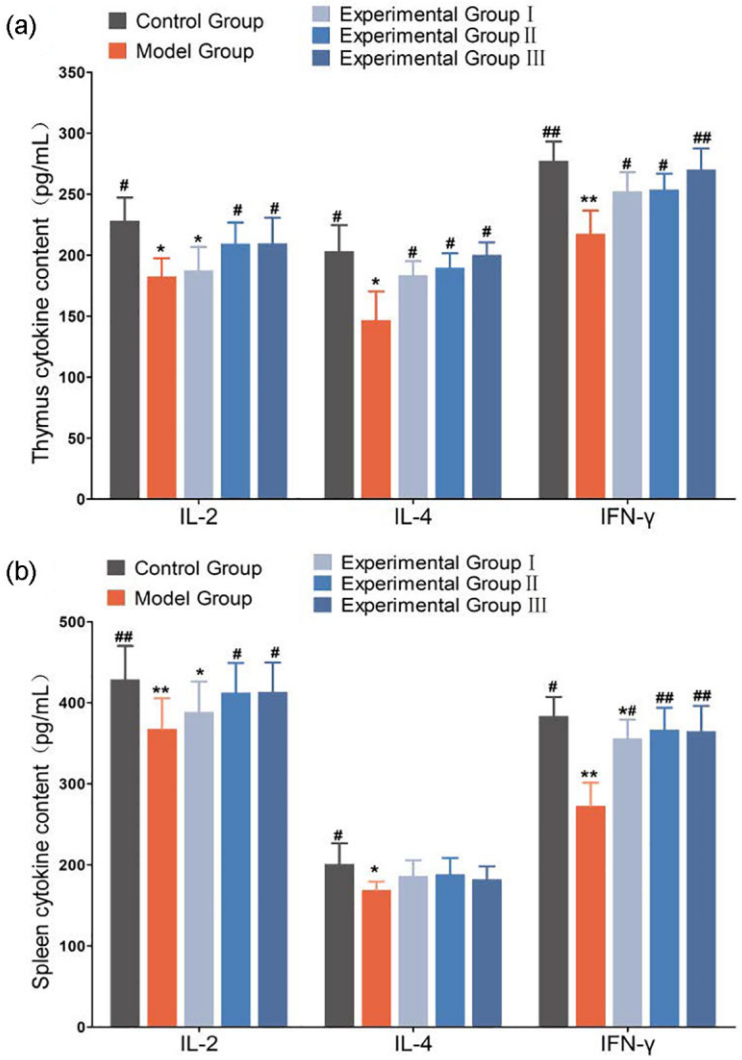

Figure 2. Effect of HEP on cytokine content in thymus and spleen of immunosuppressive mice induced by CTX. (a, b) Effect on cytokines in the thymus (a) and spleen. (b) $^{*}P < .05$ or $^{**}P < .01$ vs Control Group; $^{\#}P < .05$ or $^{\#\#}P < .01$ vs Model Group.

spleen artery was thick; and the cells were tight-arranged (Figure 1h-j).

Compared with mice in the control group, the thymus cortex of mice in the model group and the experimental group I was significantly thinner. A similar trend was observed for the spleen nodule and peri-arterial lymphatic sheath area ($P < .05$ or $P < .01$). Compared with the model group, the thymus cortex of mice in the control group and the experimental group III was thick, and the spleen nodule and lymphatic sheath were significantly larger than that of the model group ($P < .05$ or $P < .01$). The thymus cortex of mice was also significantly thicker in the experimental group II than that in the model group ($P < .05$, Figure 1k-m).

HEP dysregulated the expression of several cytokines in the thymus and spleen of CTX-induced immunosuppressed mice

Compared with mice in the control group, in model group the expression of IL-2, IL-4, and IFN-γ in the mice's thymus and spleen significantly decreased ($P < .01$ or $P < .05$). The thymus and spleen IL-2 and spleen IFN-γ contents were significantly lower in mice in experimental group I than that in the control group ($P < .05$). The thymus and spleen IL-2, IL-4, and IFN-γ contents were significantly higher in mice in the control group than that in the model group ($P < .01$ or $P < .05$). The thymus and spleen IL-2 and IFN-γ contents of mice in the control group and the experimental groups II and III were significantly higher than those in the model group ($P < .01$ or $P < .05$). The thymus and spleen IL-4 contents were significantly higher in mice in the control group than that in the model group ($P < .05$). The IL-4 content was substantially higher in the thymus of mice in experimental groups II and III than that in the model group ($P < .05$). The thymus and spleen IFN-γ content was significantly higher in the experimental group I ($P < .05$, Figure 2).

HEP enhanced the antioxidant function of thymus and spleen tissues in CTX induced-immunosuppressed mice

The thymus and spleen T-AOC and T-SOD activities and GSH-PX content were significantly lower in mice in the model group than

Downloaded from https://academic.oup.com/bbb/article/87/3/279/6886539 by guest on 11 November 2025

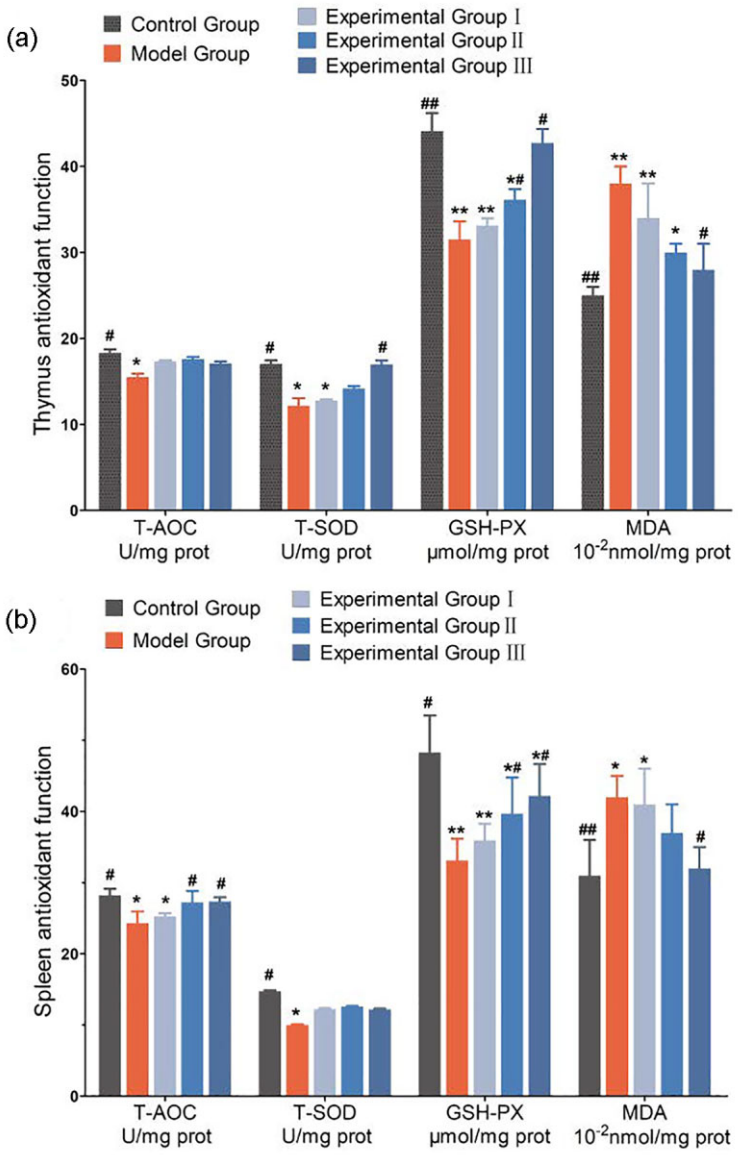

Figure 3. Effect of HEP on antioxidant function in thymus and spleen of immunosuppressive mice induced by CTX. (a, b) Effect on antioxidant function of thymus (a) and spleen (b). $^{*}P < .05$ or $^{**}P < .01$ vs Control Group; $^{\#}P < .05$ or $^{\#\#}P < .01$ vs Model Group.

that in the control group ($P < .01$ or $P < .05$). The MDA content was significantly higher in the model group ($P < .01$ or $P < .05$). The thymus and spleen GSH-PX contents were very significantly low in mice in the experimental group I ($P < .01$), and the thymus T-SOD activity and spleen T-AOC activity were also significantly lower in the experimental group I than that in the control group ($P < .05$). In contrast, the thymus and spleen MDA contents were significantly higher in the experimental group I than that in the control group ($P < .01$ or $P < .05$). The thymus and spleen GSH-PX contents were significantly lower ($P < .05$), whereas the thymus MDA content was significantly high in mice in experimental group II than that in the control group ($P < .05$). Compared with the model group, the thymus and spleen T-AOC, T-SOD activity, and GSH-PX content were significantly high for mice in the control group ($P < .01$ or $P < .05$), whereas the MDA content was significantly lower ($P < .05$). The thymus and spleen GSH-PX content were significantly higher in mice in the experimental group III than that in the model group ($P < .05$), thymus T-SOD activity was significantly higher than that in the model group ($P < .05$), and the spleen T-AOC activity was significantly higher than that in the model group ($P < .05$). In contrast, the thymus and spleen MDA content was significantly lower than that in the model group ($P < .05$). Compared with mice in the model group, the thymus and spleen GSH-PX content of mice in the experimental group II was significantly high ($P < .05$), and the spleen T-AOC activity was significantly high in mice in experimental group II ($P < .05$, Figure 3).

HEP down-regulated the expression of apoptosis-related genes and promoted proliferation-related genes in the thymus and spleen lymphocytes of immunosuppressed mice

Thymus PCNA mRNA expression was significantly lower in mice in the model group and the experimental groups I, II, and III

Downloaded from https://academic.oup.com/bbb/article/87/3/279/6886539 by guest on 11 November 2025

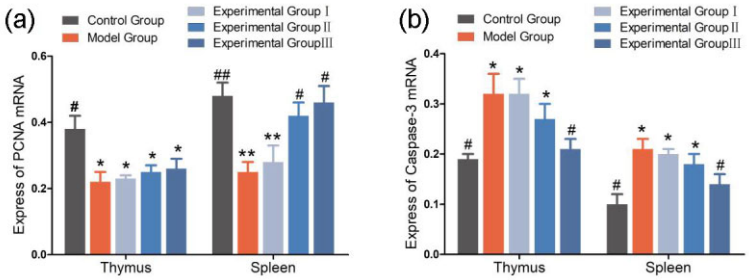

Figure 4. Effect of HEP on lymphocyte proliferation and apoptosis gene expression in thymus and spleen of immunosuppressive mice induced by CTX. (a, b) Effects on PCNA mRNA (a) and Caspase-3 mRNA (b) expression in thymus and spleen. $^{*}P < .05$ or $^{**}P < .01$ vs Control Group; $^{\#}P < .05$ or $^{\#\#}P < .01$ vs Model Group.

compared with the control group ($P < .05$). The expression of PCNA mRNA in the spleen of mice was significantly lower in the model group and experimental groups I compared with the control group ($P < .01$). Caspase-3 mRNA was significantly higher in the thymus and spleen of mice in the experimental groups I, II, and model group than that in the control group ($P < .05$). The expression of PCNA mRNA was significantly higher, and Caspase-3 mRNA expression was significantly lower in the thymus and spleen of mice in the control group than that in the model group ($P < .01$ or $P < .05$). The PCNA mRNA expression was significantly higher in the spleen of mice in the experimental groups II and III than that in the model group ($P < .01$). However, the thymus and spleen Caspase-3 mRNA was significantly lower in the experimental group III than that in the model group ($P < .05$, Figure 4).

HEP reduces the distribution and IOD of Caspase-3 in the thymus and spleen of CTX-induced immunosuppressed mice

Cells expressing caspase-3 in the thymus and spleen of mice appeared brown-black and were mainly distributed in the medulla of the thymus and around the white and red marrow. Compared with mice in the control group, more cells in the thymus and spleen of mice in the model group expressed Caspase-3. The cells were evenly distributed in the entire thymus medulla and the white and red marrow of the spleen (Figure 5c and d). There was no significant difference in the number of Caspase-3 positive cells in the thymus of mice in the experimental group I and model group, but the Caspase-3 positive cells were significantly fewer in the spleen of mice in the experimental group I than model group (Figure 5e and f). Caspase-3 positive cells were significantly fewer in experimental group II and experimental group III than that in the model group and were mainly at the medulla and cortex junction of the thymus and the edge of the white medulla of the spleen (Figure 5g-j). The IOD of Caspase-3 positive cells in the spleen was significantly higher in the model group mice than that in mice in the control group ($P < .05$), but there was no significant change in control between experimental groups I, II, and III. The IOD of the spleen Caspase-3 positive cells was significantly higher in the model group than that in the control, experimental I, and experimental III groups ($P < .05$, Figure 5).

Discussion

Chinese herbal medicines have long been used in humans and livestock for various health benefits. Certain herbal extracts can enhance the immune function of animals and improve disease resistance. For instance, Astragalus immunomodulators in feeds significantly improve the growth of immune organs and $CD4^{+}$ lymphocytes and $CD4^{+}/CD8^{+}$ T lymphocyte ratio in broiler chickens infected with Newcastle disease virus while decreasing the apoptosis rate of the spleen, thymus, and bursal cells (Zhang *et al.* 2009). A combination of Ganoderma lucidum polysaccharides and Porphyra polysaccharides enhances the phagocytic capacity of RAW264.7 macrophages and promotes the expression of inducible nitric oxide synthase (iNOS) and tumor necrosis factor (TNF) -α mRNAs (Huang *et al.* 2019). HEP is a bioactive component extracted from *H. erinaceus*, a Chinese herbal plant. This herb protects gastric mucosa and improves the microscopic structure of animal organs. HEP reduces immune organ damage in ducks caused by muscovy duck reovirus (MDRV), reverses MDRV-induced perihepatic venous infiltration of lymphocytes to the spleen and thymus vacuoles, and maintains the normal functioning of immune organs (Liu *et al.* 2021). CTX is the validated compound for establishing immunosuppressed animal models for related studies (Guo *et al.* 2012; Wang *et al.* 2012). CTX can decrease the number of leukocytes in mice and damage the thymus, spleen, and bone marrow cells and tissues. Also, from a pathological point of view, CTX causes structural disorders and fibrous hyperplasia in the thymus of Kunming mice. CTX further damages the lymphatic sheath around the arteries in the white marrow region of the spleen (Zhou *et al.* 2018).

The normal microscopic structure is necessary for the proper functioning of immune organs. The thymus and the spleen are important central and peripheral immune organs in animals and mediate cellular and humoral immune functions. T-lymphocyte differentiation and maturation occur in the thymus. Structurally, the thymus mainly comprises thymus lobules of different sizes, including the external cortex and the internal medulla. The spleen is the largest peripheral immune organ in the body, and it primarily comprises the red and white medullae. The white medullae consist of the spleen nodules and the periarterial lymph sheaths. The spleen performs the function of the body's immune response (Jin *et al.* 2014). Supplementation of 200 mg/kg·BW HEP in drinking water alleviates alcohol-induced gastric ulcers and pyloric ligation in rat models and improves (reduces) hemorrhagic spots and ulcer streaks in the gastric mucosal layer (Wang *et al.* 2018). In the present study, we found that oral administration of 320 mg/kg of HEP significantly increased the thickness of the thymus cortex and the area of spleen nodules and peri-pleural lymphatic sheaths in immunosuppressed mice and improved the microstructure of the thymus and spleen. HEP reverses CTX-induced immunosuppression by stimulating proper development of immune organs, inhibiting atrophy of immune organs caused by immunosuppression, modulating CTX-induced damage of the microstructure of immune organs, which improves the overall immune function of the animal. The immune functions are physiological functions

Downloaded from https://academic.oup.com/bbb/article/87/3/279/6886539 by guest on 11 November 2025

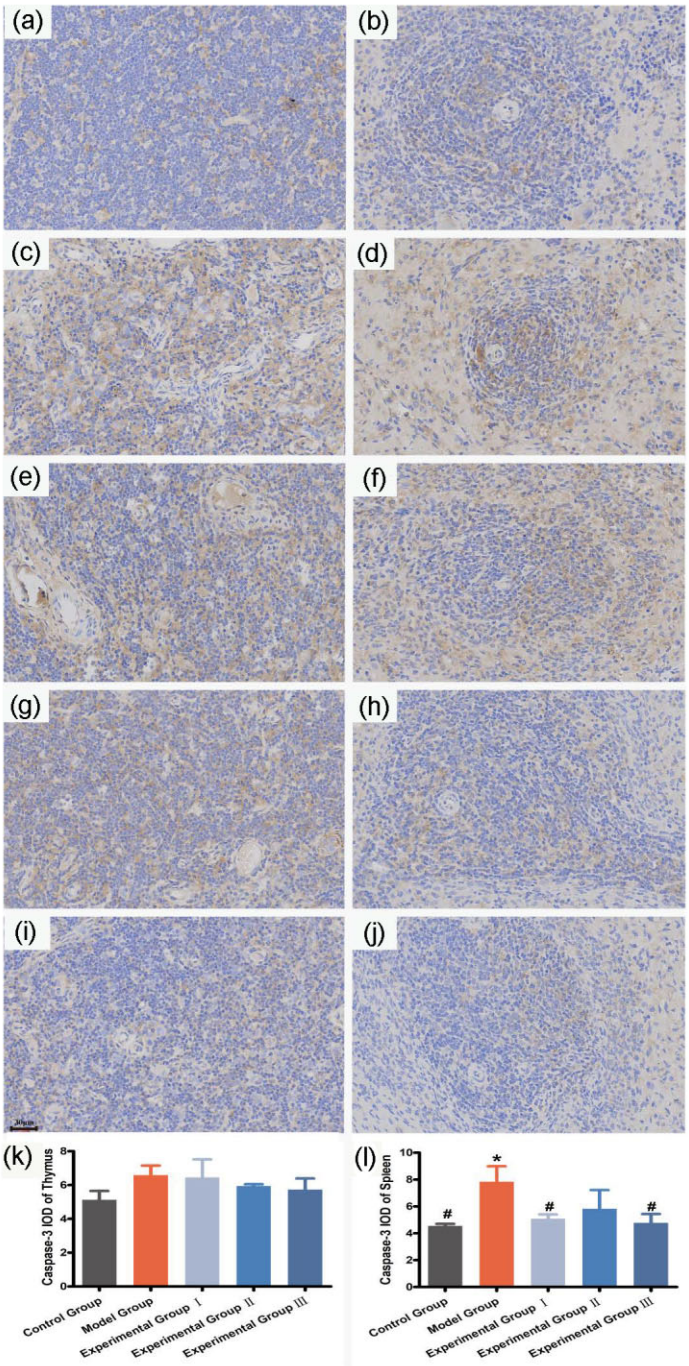

Figure 5. Effects of HEP on the distribution of Caspase-3 cells of thymus and spleen of CTX induced immune stress mice. (a, c, e, g, i) Microstructure of thymus in control group (a), model group (c), experimental group I (e), experimental group II (g) and experimental group III (i). Magnification 300X and Scale bar 30 μm. (b, d, f, h, j): Microstructure of spleen in control group (b), model group (d), experimental group I (f), experimental group II (h) and experimental group III (j). Magnification 300X and Scale bar 30 μm. (k, l) Thymus (k) and spleen (l) Caspase-3 cell IOD value statistics. $^{*}P < .05$ or $^{**}P < .01$ vs Control Group; $^{\#}P < .05$ or $^{\#\#}P < .01$ vs Model Group.

important for good animal health. Several immune organs and mediators work in synergy to resist harmful organisms and factors inside and outside the body. Cytokines are immunomodulatory factors mainly produced by T lymphocytes. They mediate and regulate immune response, metabolism of substances, and mediates cellular immunity. The level of cytokines reflects the immune and nutritional/metabolic status in organisms (Zheng *et al.* 2022). IL-2 is mainly secreted by Th1 cells and regulates cellular immune responses. IL-4 is mainly secreted by Th2 cells, and it mainly regulates humoral immune responses. IFN-γ is mainly secreted by activated T cells and natural killer cells and mediates antigen presentation (Mitsias *et al.* 2002; Shao *et al.* 2006). Numerous studies have shown that HEP enhances the body's immune function and antioxidant capacity and scavenges excess oxygen radicals. Cyclophosphamide can inhibit the secretion of Th1 and Th2 cytokines, while HEP can

Downloaded from https://academic.oup.com/bbb/article/87/3/279/6886539 by guest on 11 November 2025

weaken or protect the inhibitory effect of cyclophosphamide on immune function, thereby promoting or restoring the secretion of Th1 and Th2 cytokines at the same time. In the experiments of Wu and Huang, it was shown that serum levels of IL-2 were significantly reduced in immunosuppressed mice model with cyclophosphamide, while there was a significant recovery in serum levels of IL-2 in the experimental group of mice supplemented with *H. erinaceus* polysaccharide fraction (HEP-W). HEP-W was shown to have the ability to accelerate the recovery of serum IL-2 levels in cyclophosphamide-treated mice and subsequently enhance immunity (Wu and Huang 2020). Also, in a study by Sheu *et al* was shown that HEP significantly promoted the secretion of cytokines IL-12, IFN-γ, and IL-10 from rat dendritic cells (Sheu *et al.* 2013). These suggest that cyclophosphamide has an inhibitory effect on the secretion of cytokines and that the polysaccharide component of HEP may have a restorative effect on the secretion of cytokines. *Hericium erinaceus* extract inhibits lipopolysaccharide (LPS) stimulated secretion of TNF-α and IL-6 by RAW264 macrophages by activating the c-Jun amino-terminal kinase (JNK) signaling pathway (Mori *et al.* 2015). HEP pretreatment reduced the secretion of TNF-α and IL-1β in ethanol-induced gastric mucosal lesions and pylorus ligation-induced gastric ulcer wounds in rat models. Reducing the peroxidase activity of gastric tissues improves the antioxidant capacity (Wang *et al.* 2018). A previous study showed that HEP significantly increased the production of NO, IL-6, IL-10, IFN-γ, and TNF-α, as well as the phosphorylation of signaling molecules in the intestines and feces of mice (Yang *et al.* 2021). The present study revealed that oral 320 mg/kg HEP significantly increased IL-2 and IFN-γ secretion, increased the thymus IL-4 levels, indicating that HEP promotes cytokine secretion in the thymus and spleen of immunosuppressed mice and enhance immune function of these organs. It has been found that polysaccharides can regulate the immune environment of the small intestine, which in turn regulates the paracrine absorption pathway of intestinal cells and ultimately improves the absorption and utilization of other nutrients, thus providing a great site and nutritional conditions for biological responses such as cell proliferation and apoptosis, and enhancing the immune function of the animal organism (Yang *et al.* 2022). The reason for this result may also be due to the fact that some of the polysaccharides in HEP improve the structure of the intestinal microbiota and increase the variety of beneficial intestinal bacteria (Shao *et al.* 2019; Xie *et al.* 2021).

Immune function affects cytokine secretion, and cytokine secretion is affected by many conditions, including antioxidant function and cell proliferation and apoptosis. Enhancing the immune function directly improves the activity of antioxidant enzymes, providing a good environment for the proliferation and good functioning of immune cells. The antioxidant system facilities scavenging of excess free oxygen radicals in the body, protecting the body from oxidative damage. The system mainly includes SOD, AOC, GSH-PX, and MDA (Zhang *et al.* 2008). The antioxidant capacity (T-AOC) represents the overall level of enzymatic and non-enzymatic antioxidants in the body, and a reduction in T-AOC often causes various diseases. Superoxide dismutase (T-SOD) scavenges all types of oxygen radicals in the body and protects cells from free radical oxidative damage, whereas glutathione peroxidase (GSH-PX), together with SOD, protects cells from oxidative damages. Malondialdehyde (MDA) content reflects the lipid peroxidation levels in the body and indirectly reflects the degree of cell damage (Bozinovski *et al.* 2012). Similarly, 300 mg/kg HEP for 15 days significantly reduced lipid peroxidation and enhanced the activity of antioxidant enzymes in mice with renal ischemia-reperfusion injury (Han, Ye and Wang 2013). The present study revealed that oral 320 mg/kg HEP significantly increased the GSH-PX content, decreased MDA activity in the thymus and spleen of immunosuppressed mice and increased the thymus T-SOD activity. It is possible that the polysaccharide structure of HEP exhibits antioxidant activity, particularly in scavenging DPPH free radicals (Huo, Ding and Hou 2015). This may be because HEP activates Toll-like receptors (TLR) signaling through the MyD88 pathway, which further triggers NF-κB, and promotes the synthesis and secretion of cellular inflammatory factors, including TNF-α, IL-10, IL-6, and IFN-β (Fuu, Po and Kuang 2009), which in turn activates the antioxidant system, enhances antioxidant enzyme activity. These events reduce the oxidative damage of lymphocyte DNA by oxygen radicals, enhancing the immune function in an animal. Lymphocyte proliferative activity is an important event in the activation cascade of cellular and humoral immune responses, and HEP significantly increased the activation potential of T and B lymphocyte proliferation in immunosuppressed mice, thereby enhancing cellular and humoral immune responses. Cell proliferation and apoptosis are two key factors in maintaining the dynamic balance between cell growth and aging, and an imbalance between the two in immune response-related organs causes disrupts the immune response. PCNA is an auxiliary protein of cellular DNA polymerase δ, which participates in DNA synthesis during cell proliferation and, thus, is a key indicator for the proliferation status and rate of cells (Villar *et al.* 2002). Caspase-3 is a protease that cleaves substrates downstream of the apoptotic pathway, and it is also a common effector molecule in the death receptor, mitochondrial, and endoplasmic reticulum pathways (Hermeking 2010). Activated Caspase-3 binds to and inactivates protein-specific tetrapeptide sequences, destroying cellular structural and functional proteins, and its expression level is an important indicator of the apoptotic level of cells (Choudhary, Al and Almasan 2015). Many studies have shown that HEP regulates the proliferation and apoptosis of numerous animal cells. Flow cytometry (FACS) analysis showed that EP-1, a polysaccharide isolated from *H. erinaceus*, prevents hydrogen peroxide-induced apoptosis by inhibiting the mitochondria-dependent apoptosis pathway (Wang *et al.* 2017). Also, a polysaccharide from the cystocarp of the *H. erinaceus* enhances the immune function of RAW 264.7 cells by promoting the proliferation of T- and B-lymphocytes and corresponding secretion of IL-2, IL-4, and IFN-γ (Wu *et al.* 2018). We found that CTX downregulated PCNA mRNA expression in the thymus and spleen cells but increased that of Caspase-3, indicating that CTX could inhibit cell proliferation and promote apoptosis of cells. In contrast, oral 320 mg/kg of HEP significantly inhibited the expression of Caspase-3 mRNA in the thymus and spleen and promoted spleen PCNA mRNA expression, implying that HEP could promote proliferation and inhibit apoptosis of thymus and spleen lymphocytes in immunosuppressed mice. HEG-5 polysaccharide protein in HEP promotes apoptosis and cell cycle arrest through the caspase-8/-3 pathway, p53-dependent mitochondrial pathway, and PI3k/Akt signaling pathway by inducing the expression of apoptosis-related genes (Zan *et al.* 2015). Meanwhile, HEP protects the normal physiological function of immune organ cells by upregulating the phosphorylation of ERK1/2, p38, and JNK1/2 proteins via the MAPKs pathway. Studies have also shown that cells may bind polysaccharides and express their immunomodulatory effects mainly through toll-like receptors (TLR2 and TLR4), complement receptor 3 (CR3), mannose receptor (MR), beta glucan receptor (GR), scavenger receptor I (SR) or Dectin-1 (Xu, Yan and Zhang 2012; Zhang *et al.* 2017). However, the mechanisms by which HEP regulates cell proliferation and apoptosis

Downloaded from https://academic.oup.com/bbb/article/87/3/279/6886539 by guest on 11 November 2025

are unknown, so we will further investigate the specific regulatory mechanisms of HEP by sequencing the transcriptome of HEP-treated cells and functional analysis of the target signaling pathways related to cell proliferation and apoptosis, and by blocking the specific pathways targeted by HEP.

Conclusion

Overall, intake of 320 mg/kg of HEP significantly improved the microstructure, immune function, antioxidant function, and apoptosis of thymus and spleen cells in CTX-induced-immunosuppressed mice, increased the thickness of the thymus cortex and the area of lymphatic sheaths around spleen nodes and spleen arteries, promoted proliferation of cells thymus and spleen genes and decreased the expression and translocation of apoptotic proteins.

Data availability

The data that support the findings of this study are available from the corresponding author by reasonable request.

Author contribution

Y.H., C.Z., and F.Z. performed the laboratory work, analyzed the data. J.H. carried out animal feeding experiments and measured antioxidant function. Y.G. provided experimental technology. C.W. and E.J. designed the study. Y.H. wrote the manuscript.

Funding

National Natural Science Foundation of China (32002160, 32172816); Anhui Natural Science Foundation Project (2108085MC117, 2208085MC77); The Natural Science Key Foundation of Anhui Education Department (KJ2021A0868, KJ2020A0081); Collaborative innovation project of Anhui Province (gxxt-2019-035); Graduate program of Anhui Provincial Department of Education (YJS20210557); National Undergraduate Innovation Project (202210879072).

Disclosure statement

No potential conflict of interest was reported by the authors.

References

Bozinovski S, Seow HJ, Crack PJ *et al*. Glutathione peroxidase-1 primes pro-inflammatory cytokine production after LPS challenge *in vivo*. *PLoS One* 2012;**7**:e33172.

Chen P, Yong Y, Gu Y *et al*. Comparison of antioxidant and antiproliferation activities of polysaccharides from eight species of medicinal mushrooms. *Int J Med Mushrooms* 2015;**17**:287-95.

Chen Z, Li J, Hu C *et al*. SG-02 in streptozotocin-induced diabetic mice. *Sci Rep* 2017;**7**:10847.

Choudhary GS, Al HS, Almasan A. Caspase-3 activation is a critical determinant of genotoxic stress-induced apoptosis. *Methods Mol Biol* 2015;**1219**:1-9.

Elazab M, Younes AM, Gaafar AY *et al*. Immunosuppressive effect of cyclophosphamide in Nile tilapia (*Oreochromis niloticus*). *Environ Sci Pollut Res* 2021;**28**:20784-93.

Fuu S, Po JC, Kuang Y. Purification, cloning, and functional characterization of a novel immunomodulatory protein from *Antrodia camphorata* (Bitter Mushroom) that exhibits TLR2-Dependent NF-κB activation and M1 polarization within Murine macrophages. *J Agr Food Chem* 2009;**57**:4130-41.

Guo L, Liu J, Hu Y *et al*. Astragalus polysaccharide and sulfated epimedium polysaccharide synergistically resist the immunosuppression. *Carbohydr Polym* 2012;**90**:1055-60.

Han Z, Ye J, Wang G. Evaluation of in vivo antioxidant activity of *hericium erinaceus* polysaccharides. *Int J Biol Macromol* 2013;**52**:66-71.

He X, Wang X, Fang J *et al*. Structures, biological activities, and industrial applications of the polysaccharides from *Hericium erinaceus* (Lion's Mane) mushroom: A review. *Int J Biol Macromol* 2017;**97**:228-37.

Hermeking H. The miR-34 family in cancer and apoptosis. *Cell Death Differ* 2010;**17**:193-9.

Huang Q, Li L, Chen H *et al*. GPP (Composition of Ganoderma Lucidum Poly-saccharides and Polyporus Umbellatus Polysaccharides) enhances innate immune function in mice. *Nutrients* 2019;**11**:1480.

Hou Y, Ding X, Hou W. Composition and antioxidant activity of water-soluble oligosaccharides from *Hericium erinaceus*. *Mol Med Rep* 2015;**11**:3794-9.

Jin E, Wang C, Hu Q *et al*. The regular distribution and expression pattern of immunosuppressive cytokine IL-35 in mouse uterus during early pregnancy. *Rom J Morphol Embryol* 2014;**55**:1353-61.

Lee J, Hong E. *Hericium erinaceus* enhances doxorubicin-induced apoptosis in human hepatocellular carcinoma cells. *Cancer Lett* 2010;**297**:144-54.

Liu Z, Liao L, Chen Q *et al*. Effects of *Hericium erinaceus* polysaccharide on immunity and apoptosis of the main immune organs in Muscovy duck reovirus-infected ducklings. *Int J Biol Macromol* 2021;**171**:448-56.

Luster MI, Portier C, Pait DG *et al*. Risk assessment in immunotoxicology. I. Sensitivity and predictability of immune tests. *Fundam Appl Toxicol* 1992;**18**:200-10.

Mori K, Ouchi K, Hirasawa N *et al*. The anti-inflammatory effects of Lion's mane culinary-medicinal mushroom, *Hericium erinaceus* (Higher Basidiomycetes) in a coculture system of 3T3-L1 adipocytes and RAW264 macrophages. *Int J Med Mushrooms* 2015;**17**:609-18.

Mcdaid J, Scott CJ, Kissenpfennig A *et al*. The utility of animal models in developing immunosuppressive agents. *Eur J Pharmacol* 2015;**759**:295-302.

Mitsias DI, Tzioufas AG, Veiopoulou C *et al*. The Th1/Th2 cytokine balance changes with the progress of the immunopathological lesion of Sjogren's syndrome. *Clin Exp Immunol* 2002;**128**:562-8.

Pelaez B, Campillo JA, Lopez JA *et al*. Cyclophosphamide induces the development of early myeloid cells suppressing tumor cell growth by a nitric oxide-dependent mechanism. *J Immunol* 2001;**166**:6608-15.

Shao P, Zhao L, Pan J. Regulation on maturation and function of dendritic cells by *Astragalus mongholicus* polysaccharides. *Int Immunopharmacol* 2006;**128**:562-8.

Shao S, Wang D, Zheng W *et al*. A unique polysaccharide from *Hericium erinaceus* mycelium ameliorates acetic acid-induced ulcerative colitis rats by modulating the composition of the gut microbiota, short chain fatty acids levels and GPR41/43 respectors. *Int Immunopharmacol* 2019;**71**:411-22.

Sheu SC, Ying L, Lee MS *et al*. Immunomodulatory effects of polysaccharides isolated from *Hericium erinaceus* on dendritic cells. *Process Biochem* 2013;**48**:1402-8.

Siegel I, Liu T, Gleicher N. The red-cell immune system. *Lancet* 1981;**2**:556-9.

Downloaded from https://academic.oup.com/bbb/article/87/3/279/6886539 by guest on 11 November 2025

Yang Y, Ren R, Chen Q *et al*. *Coptis chinensis* polysaccharides dynamically influence the paracellular absorption pathway in the small intestine by modulating the intestinal mucosal immunity microenvironment. *Phytomedicine* 2022;**104**:154322.

Vallant B, Kadnar R, Goessler W. Development of a new HPLC method for the determination of inorganic and methylmercury in biological samples with ICP-MS detection. *J Anal At Spectrom* 2007;**22**:322-5.

Villar CB, Perez CE, Melendez FM *et al*. Proliferating cell nuclear antigen (PCNA) immunoreactivity and development of the pineal complex and habenula of the sea lamprey. *Brain Res Bull* 2002;**57**:285-7.

Wang D, Zhang Y, Yang S *et al*. A polysaccharide from cultured mycelium of *Hericium erinaceus* relieves ulcerative colitis by counteracting oxidative stress and improving mitochondrial function. *Int J Biol Macromol* 2019;**125**:572-9.

Wang M, Kanako N, Zhang Y *et al*. A unique polysaccharide purified from *Hericium erinaceus* mycelium prevents oxidative stress induced by H_2O_2 in human gastric mucosa epithelium cell. *PLoS One* 2017;**12**:e181546.

Wang M, Meng X, Yang R *et al*. *Cordyceps militaris* polysaccharides can enhance the immunity and antioxidation activity in immunosuppressed mice. *Carbohydr Polym* 2012;**89**:461-6.

Wang X, Yin J, Zhao M *et al*. Gastroprotective activity of polysaccharide from *Hericium erinaceus* against ethanol-induced gastric mucosal lesion and pylorus ligation-induced gastric ulcer, and its antioxidant activities. *Carbohydr Polym* 2018;**186**:100-9.

Wu F, Zhou C, Zhou D *et al*. Structure characterization of a novel polysaccharide from *Hericium erinaceus* fruiting bodies and its immunomodulatory activities. *Food Funct* 2018;**9**:294-306.

Wu F, Huang H. Surface morphology and protective effect of *Hericium erinaceus* polysaccharide on cyclophosphamide-induced immunosuppression in mice. *Carbohydr Polym* 2020;**251**:116930.

Xu X, Yan H, Zhang X. Structure and immuno-Stimulating activities of a new heteropolysaccharide from Lentinula edodes. *J Agric Food Chem* 2012;**46**:11560.

Xie XQ, Geng Y, Guan Q *et al*. Influence of short-Term consumption of *Hericium erinaceus* on serum biochemical markers and the changes of the gut microbiota: A pilot study. *Nutrients* 2021;**13**:1008.

Yang Y, Ye H, Zhao C *et al*. Value added immunoregulatory polysaccharides of *Hericium erinaceus* and their effect on the gut microbiota. *Carbohydr Polym* 2021;**262**:117668.

Zan X, Cui F, Li Y *et al*. *Hericium erinaceus* polysaccharide-protein HEG-5 inhibits SGC-7901 cell growth via cell cycle arrest and apoptosis. *Int J Biol Macromol* 2015;**76**:242-53.

Zhang H, Tian Y, Guo Y *et al*. Dietary conjugated linoleic acid improves antioxidant capacity in broiler chicks. *Br Poult Sci* 2008;**49**:213-21.

Zhang Q, Jiang G, Li S *et al*. Effect of a Chinese herbal formula astragalus immunomodulator on immune function of chickens. *Front Agric China* 2009;**3**:209-15.

Zhang S, Wang C, Sun Y *et al*. Xylanase and fermented polysaccharide of *Hericium caputmedusae* reduce pathogenic infection of broilers by improving antioxidant and anti-Inflammatory properties. *Oxid Med Cell Longev* 2018;**11**:4296985.

Zheng X, Wu Y, Bi J *et al*. The use of supercytokines, immunocytokines, engager cytokines, and other synthetic cytokines in immunotherapy. *Cell Mol Immunol* 2022;**19**:192-209.

Zhang M, Wu W, Ren Y *et al*. Structural characterization of a novel polysaccharide from *lepidium meyenii* (Maca) and analysis of its regulatory function in macrophage polarization in vitro. *J Agric Food Chem* 2017;**65**:1146-57.

Zhou Y, Chen X, Yi R *et al*. Immunomodulatory effect of Tremella polysaccharides against cyclophosphamide-Induced immunosuppression in mice. *Molecules* 2018;**23**:239.

Downloaded from https://academic.oup.com/bbb/article/87/3/279/6886539 by guest on 11 November 2025