Carbohydrate Polymers 186 (2018) 100–109

Contents lists available at ScienceDirect

Carbohydrate Polymers

journal homepage: www.elsevier.com/locate/carbpol

Gastroprotective activity of polysaccharide from *Hericium erinaceus* against ethanol-induced gastric mucosal lesion and pylorus ligation-induced gastric ulcer, and its antioxidant activities

Xiao-Yin Wang, Jun-Yi Yin, Ming-Ming Zhao, Shi-Yu Liu, Shao-Ping Nie, Ming-Yong Xie*

State Key Laboratory of Food Science and Technology, Nanchang University, Nanchang 330047, China

ARTICLE INFO

Keywords:
Hericium erinaceus
Polysaccharide
Gastroprotective activity
Anti-inflammatory
Antioxidant activity

ABSTRACT

The gastroprotective activity of *Hericium erinaceus* polysaccharide was investigated in rats. The antioxidant activities were also evaluated. Pre-treatment of polysaccharide could reduce ethanol-induced gastric mucosal lesion and pylorus ligation-induced gastric ulcer. The polysaccharide exhibited scavenging activities of 1, 1-diphenyl-2-picryl-hydrozyl and hydroxyl radicals, and ferrous ion-chelating ability. In the pylorus ligation-induced model, gastric secretions (volume of gastric juice, gastric acid, pepsin and mucus) of ulcer rats administrated with polysaccharide were regulated. Levels of tumor necrosis factor-α and interleukins-1β in serum, and myeloperoxidase activity of gastric tissue were reduced, while antioxidant status of gastric tissue was improved. Defensive factors (nitric oxide, prostaglandin E2, epidermal growth factor) in gastric tissue were increased. These results indicate that *Hericium erinaceus* polysaccharide possess gastroprotective activity, and the possible mechanisms are related to its regulations of gastric secretions, improvements of anti-inflammatory and anti-oxidant status, as well as increments of defensive factors releases.

1. Introduction

Gastric ulcer is a common type of peptic ulcer, afflicting millions of individuals worldwide. Treatment of gastric ulcer mostly depends on the usage of synthetic drugs, while it triggers diverse side-effects (Kangwan, Park, Kim, & Hahm, 2014). In this regard, exploring more effective and safe anti-gastric ulcer products or seeking for materials with auxiliary protection function against gastric ulcer from natural resources has attracted much attention (Awaad, El-Meligy, & Soliman, 2012; Venkateswararao & Venkataramana, 2013). Currently, many edible and medicinal resources have been demonstrated to be conducive to the improvement of gastric ulcers in humans and many animal models with fewer adverse effects (Bi, Man, & Man, 2014; Gargano et al., 2017).

As an edible and medicinal mushroom, *Hericium erinaceus* is widely used in traditional Chinese medicine and cuisine (He et al., 2017). Its bioactive activity was recorded in “Ben Cao Gang Mu”, which showed that *Hericium erinaceus* could protect the five internal organs and improve digestion function. The cytoprotection of the freeze-dried fruiting body of *Hericium erinaceus* against ethanol-induced gastric ulcers has already been established (Abdulla, Noor, Wong, and Ali, 2008). Recent investigations have established that the aqueous extract of *Hericium erinaceus* fruiting body exerted anti-gastric ulcer activity in animal models (C. Wang et al., 2015; Wong et al., 2013). The polysaccharide isolated from the aqueous extract of mycelium culture of *Hericium erinaceus* has been ascertained to be the active component with anti-gastric ulcer activity in mice induced by ethanol and in cell experiments (Wang, Konishi, Gao, Xu, & Gao, 2015). However, it is not clear whether the polysaccharide is the bioactive compound or not. A study revealed that a purified polysaccharide isolated from *Hericium erinaceus* mycelium prevented the apoptosis of human gastric mucosal epithelial cell line (GES-1) induced by H_2O_2 through inhibiting activation of apoptotic cellular signals within mitochondria-dependent apoptotic pathways (Wang et al., 2017). In terms of polysaccharide obtained from the fruiting body of *Hericium erinaceus*, the action mechanism of anti-ulcerative effect has not been carried out.

Currently, ethanol-induced gastric mucosal lesion model has been adopted to investigate the protection of freeze-dried fruiting body,

Abbreviations: HECP, *Hericium erinaceus* crude polysaccharide; HERP, *Hericium erinaceus* refined polysaccharide; GES-1, human gastric mucosal epithelial cell line; DPPH, 1, 1-diphenyl-2-picryl hydrozyl; DPPH·, DPPH radical; ·OH, hydroxyl radical; Fe^{2+}, ferrous ion; Vc, ascorbic acid; EDTA, ethylenediamine tetraacetic acid disodium salt; SD, standard deviation; ANOVA, one-way analysis of variance; NC, normal control; LC, lesion control; UC, ulcer control; TNF-α, tumor necrosis factor-α; IL-1β, interleukin-1β; IL-6, interleukin-6; MPO, myeloperoxidase; SOD, superoxide dismutase; GPx, glutathione peroxidase; NO, nitric oxide; PGE2, prostaglandin E2; EGF, epidermal growth factor

* Corresponding author.
E-mail address: myxie@ncu.edu.cn (M.-Y. Xie).

https://doi.org/10.1016/j.carbpol.2018.01.004
Received 18 July 2017; Received in revised form 22 December 2017; Accepted 1 January 2018
Available online 02 January 2018
0144-8617/ © 2018 Elsevier Ltd. All rights reserved.

aqueous extract or polysaccharide from *Hericium erinaceus* on gastric mucosa (Abdulla et al., 2008; C. Wang et al., 2015; M. Wang et al., 2015; Wong et al., 2013). On the other hand, pylorus ligation is a typical method for the uniform production of gastric ulceration in rat, thereby being commonly used in the assessment of antiulcer substance (Berté et al., 2014; Ribeiro et al., 2013; Zaghlool, Shehata, Abo-Seif, & El-Latif, 2015). Ethanol-induced and pylorus ligation-induced models have been widely applied together in the investigation of the gastroprotective activity of polysaccharides (Maria-Ferreira et al., 2014; Sun, Matsumoto, & Yamada, 1991). Accordingly, the gastroprotective effect of polysaccharide from *Hericium erinaceus* fruiting body was investigated in the present study using ethanol-induced and pylorus ligation-induced models in *Sprague-Dawley* rats. The action mechanism was systematically explored in the pylorus ligation-induced model. Besides, the *in vitro* antioxidant activities of this polysaccharide was evaluated, including scavenging activities of 1, 1-diphenyl-2-picryl hydrozyl (DPPH) and hydroxyl radicals along with the ability of ferrous ion-chelating.

2. Materials and methods

2.1. Materials and chemicals

Hericium erinaceus fruiting body from Changbai Mountains was obtained from Jiangxi NanHua Medicine Co. Ltd. (Jiangxi, China). Pentobarbital sodium salt and DPPH were gained from Sigma Chemical Corp. (St. Louis, USA). ELISA kits including tumor necrosis factor-α (TNF-α), interleukin-1β (IL-1β) and epidermal growth factor (EGF) were bought from BOSTER (Wuhan, China). Gastrin, prostaglandin E2 and histamine ELISA kits, and pepsin, myeloperoxidase, α-amylase, trypsin and chymotrypsin assay kits were purchased from Nanjing jiancheng Bioengineering institute (Nanjing, China). Superoxide dismutase (SOD), glutathione peroxidase (GPx) and nitric oxide (NO) assay kits were obtained from Beyotime Institute of Biotechnology (Shanghai, China). Ferrozine and pyrogallic acid were attained from Aladdin Industrial Corp. (Shanghai, China). All other chemicals used in this study were of analytical grade.

2.2. Animals

Male adult *Sprague-Dawley* rats (180–220 g) purchased from Beijing HFK Bioscience (certificate SCXK (jing) 2014-0004) were used to investigate the protective effect of polysaccharide on ethanol-induced gastric mucosal lesion. Rats (160–180 g) bought from Hunan Slac Jingda Laboratory Animal Co. Ltd. (certificate SCXK (xiang) 2011-0003) were applied to evaluate the effect of polysaccharide against pylorus ligation-induced gastric ulcer. All of them were handled in accordance with the Guide for Care and Use of Laboratory Animals (NIH Publication No. 85-23, revised 1996). The rats were raised in cages in a room with controlled temperature (25.0 ± 0.5 °C), relative humidity (50 ± 5%), 12/12 h of light-dark periods with *ad libitum* food and water before starting the experiments.

2.3. Polysaccharide preparation

Hericium erinaceus crude polysaccharide (HECP) and *Hericium erinaceus* refined polysaccharide (HERP) were prepared from the fruiting body using water-extraction and ethanol precipitation methods according to the previous procedures (Wang, Yin, Nie, & Xie, 2018).

2.4. Effect of polysaccharide against ethanol-induced gastric mucosal lesion

Protective effects of HECP and HERP on gastric mucosa were evaluated using an ethanol-induced gastric mucosal lesion model recommended by China Food and Drug Administration (CFDA Publication No.107, revised 2012). Briefly, rats were randomly assigned into eight groups (n = 12). Group 1 and 2 received normal saline (0.9% NaCl), and other six groups received HERP or HECP at doses of 100, 200 and 400 mg/kg bw for 2 weeks. After the last intragastric administration, they were fasted and freely accessed to water for 24 h, and then received 1.0 mL of absolute ethanol except the rats in the normal control (NC) group. One hour later, rats were sacrificed and their stomachs were removed. The cardia of each rat was ligated with thin line and 5.0 mL of 10% formalin was injected into the stomach. Stomach of each animal was subjected to fixation with 10% formalin solution for 20 min after pylorus ligation. Formalin-fixed stomach was opened along the greater curvature and washed with normal saline. After that, flattened stomach was viewed and its lesion stripes were measured with a vernier caliper to evaluate the gastric mucosal lesion as: stripe length was recorded as the lesion score, and the score would double if the stripe width was over 1 mm. The mean lesion score for each group was expressed as lesion index and the lesion inhibition rate was calculated by formula (1):

$$\text{Lesion inhibition (\%)} = [(A_0 - A_1)/A_0] \times 100 \quad (1)$$

Where A_0 is the lesion index of lesion control (LC) group, A_1 is the lesion index of polysaccharide group.

2.5. Effect of polysaccharide against pylorus ligation-induced gastric ulcer

2.5.1. Animal experiment design

Effect of *Hericium erinaceus* polysaccharide against pylorus ligation-induced ulcer was assessed adopting the model described by Kamarolzaman et al. (2014) with slight modifications. Briefly, rats were randomly divided into eight groups (12 rats per group). Group 1 (normal control group, NC) and group 2 (ulcer control group, UC) received normal saline (0.9% NaCl). Other six groups received HERP or HECP at dosages of 100, 200 and 400 mg/kg bw. On the 14th day, animals were fasted for 24 h with free access to water after the last orally administration. Then, they were in narcotism by injecting pentobarbital sodium salt solution (12 mg/mL, 2.0 mL) into cavum abdominis, and abdomens of them were incised an osculum of 2–3 cm without damaging any blood supply to allow pylorus ligation. The pylorus of each rat was ligated with silk thread except the NC group. And their duodenums were injected into equivalent volume as oral administration of the corresponding solution. Abdomen of each animal was sutured and allowed to recuperate for 5 h in the cage. Subsequently, blood of each rat was collected and animal was sacrificed by cervical dislocation. Finally, gastric juice, stomach, duodenum content and colonic content were collected for following measurements.

2.5.2. Gastric ulcer evaluation

Stomach of rat was opened along the greater curvature and cleaned with normal saline. Ulcer occurrence in the gastric mucosal layer was carefully observed. Meanwhile, the number of hemorrhagic spot was recorded and the length and width of ulcer stripes were measured with a vernier caliper. Ulcer index was calculated applying GUTH method (Park et al., 2015), and the scoring criteria was followed Table 1. The ulcer inhibition rate was computed using Eq. (2):

$$\text{Ulcer inhibition (\%)} = [(A_0 - A_1)/A_0] \times 100 \quad (2)$$

Table 1
The scoring criteria of pylorus ligation-induced ulcer model.

Ulcer morphology		Score
Each Hemorrhagic spot		1
Erosion		2
Length of ulcer stripe	< 1 mm	3
	1–2 mm	4
	> 2 mm	5

The score would double if the stripe width was > 1 mm.

Table 2
Effect of *Hericium erinaceus* polysaccharide on gastric mucosal lesion induced by ethanol (n = 12, mean ± SD).

Group	Gavage dose of polysaccharide (mg/kg bw)	Total lesion score	Lesion index	Lesion inhibition rate (%)
NC	0.9% NaCl[α]	–	–	–
LC	0.9% NaCl[α]	1293.0	105.6 ± 30.3[b]	–
HERP-L	100	1090.2	94.4 ± 32.1[ab]	10.6
HERP-M	200	970.8	85.9 ± 21.4[ab]	18.6
HERP-H	400	761.1	68.3 ± 22.5[a]	35.3
HECP-L	100	1132.4	98.8 ± 19.9[ab]	6.5
HECP-M	200	1074.1	90.7 ± 22.4[ab]	14.1
HECP-H	400	821.4	73.8 ± 18.5[a]	30.1

NC, normal control group; LC, lesion control group; HERP-L, 100 mg/kg bw of HERP; HERP-M, 200 mg/kg bw of HERP; HERP-H, 400 mg/kg bw of HERP; HECP-L, 100 mg/kg bw of HECP; HECP-M, 200 mg/kg bw of HECP; HECP-H, 400 mg/kg bw of HECP. Values in the same column with different letters represent significantly different ($p < 0.05$) from each other.
[α] Oral administration of 0.9% NaCl solution without polysaccharide.

Table 3
Effect of *Hericium erinaceus* polysaccharide on gastric ulcer induced by pylorus ligation (n = 12, mean ± SD).

Group	Gavage dose of polysaccharide (mg/kg bw)	Ulcer index	Ulcer inhibition (%)
NC	0.9% NaCl[α]	–	–
UC	0.9% NaCl[α]	20.6 ± 7.9[b]	–
HERP-L	100	14.4 ± 4.8[ab]	30.1
HERP-M	200	9.7 ± 2.9[a]	52.9
HERP-H	400	12.4 ± 2.9[a]	39.8
HECP-L	100	12.8 ± 5.2[a]	37.9
HECP-M	200	10.7 ± 2.8[a]	48.1
HECP-H	400	11.2 ± 1.8[a]	45.6

NC, normal control group; UC, Ulcer control group; HERP-L, 100 mg/kg bw of HERP; HERP-M, 200 mg/kg bw of HERP; HERP-H, 400 mg/kg bw of HERP; HECP-L, 100 mg/kg bw of HECP; HECP-M, 200 mg/kg bw of HECP; HECP-H, 400 mg/kg bw of HECP. Values in the same column with different letters represent significantly different ($p < 0.05$) from each other.
[α] Oral administration of 0.9% NaCl solution without polysaccharide.

Where A_0 is the ulcer index of UC group, A_1 is the ulcer index of polysaccharide group.

2.5.3. Histopathological observation

Hematoxylin and eosin staining method were used for the histopathological observation of the general microstructure of gastric mucosa. The most serious parts of ulcer region obtained from stomach were chosen to produce paraffin wax tissue sections (4 μm). The sections were stained in hematoxylin and eosin stain, and then observed under a light microscopy.

2.5.4. Gastric secretion

Volume of gastric juice supernatant obtained by centrifugation (1799 × *g*, 10 min) was recorded and the supernatant was used for the following analysis. pH value was measured by a FE-28 pH meter (Mettler-Toledo Co., Zurich, Switzerland) and pepsin activity was determined using the corresponding assay kit. Free acidity and total acidity were assayed by titration method with 10 mM sodium hydroxide, and the indicator was methyl orange and phenolphthale, respectively. Gastric acid output was calculated according to Eq. (3) (Zaghlool et al., 2015):

$$\text{Acid output} = (\text{total acidity} \times \textit{volume} \text{ of gastric juice})/5\,\text{h} \quad (3)$$

Mucus content of gastric juice was detected according to the procedures reported by Berté et al. (Berté et al., 2014) with slight modifications. 4 μL of gastric juice supernatant was diluted with ultrapure water to 40 μL, and mixed with 1% (w/v) alcian blue GX solution (4 μL), citric acid phosphate buffer (pH 5.8, 132 μL), and ultrapure water (92 μL). After 24 h of incubation at 20 °C, the mixture was centrifuged (2236 × *g*, 10 min). Absorbance of obtained supernatant was measured at 615 nm. Ultrapure water was used as blank control, and the D-value between the absorbance of ultrapure water and that of supernatant represented the amount of alcian blue binding (unit of mg/mL), regarding as the free mucus content.

2.5.5. Serum and gastric tissues parameters

Blood of rat was centrifuged at 4 °C (2683 × *g*, 10 min) to gather the

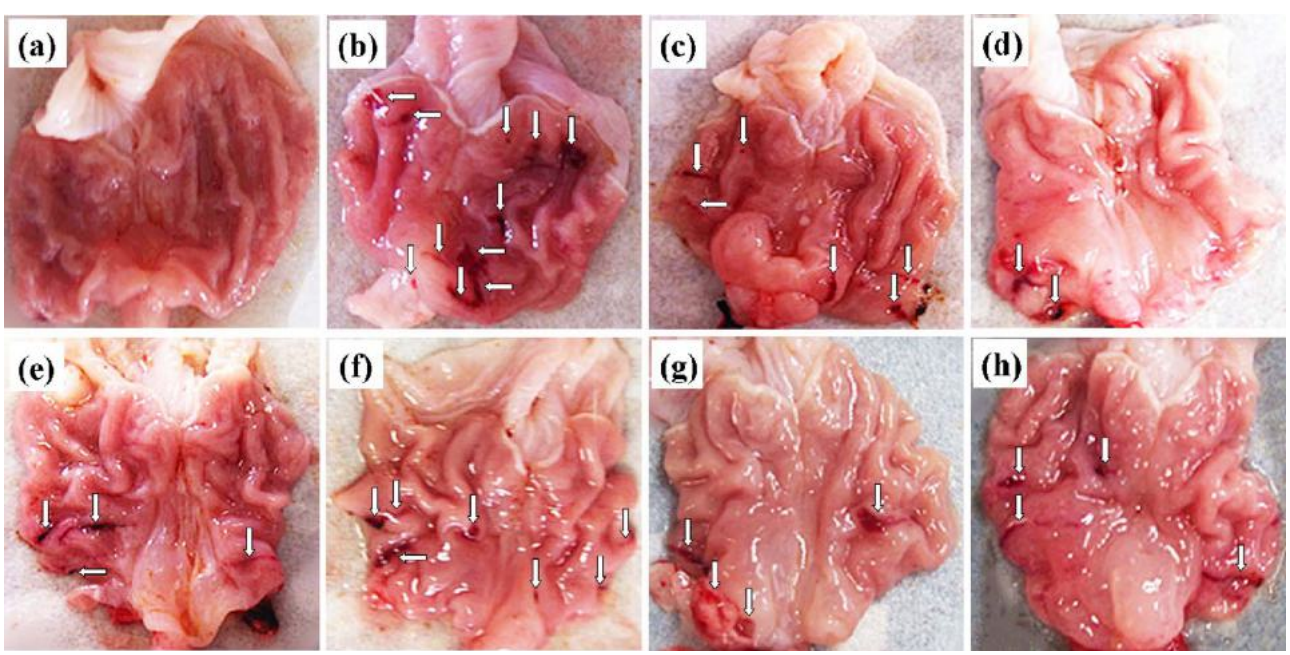

Fig. 1. Macroscopical evaluation of protective effect of *Hericium erinaceus* polysaccharide against gastric ulcer induced by pylorus ligation. (a) NC group, normal control group; (b) UC group, ulcer control group; (c) HERP-L group, 100 mg/kg bw of HERP; (d) HERP-M group, 200 mg/kg bw of HERP; (e) HERP-H group, 400 mg/kg bw of HERP; (f) HECP-L group, 100 mg/kg bw of HECP; (g) HECP-M group, 200 mg/kg bw of HECP; (h) HECP-H group, 400 mg/kg bw of HECP. Arrow indicates hemorrhagic spots or ulcer stripes.

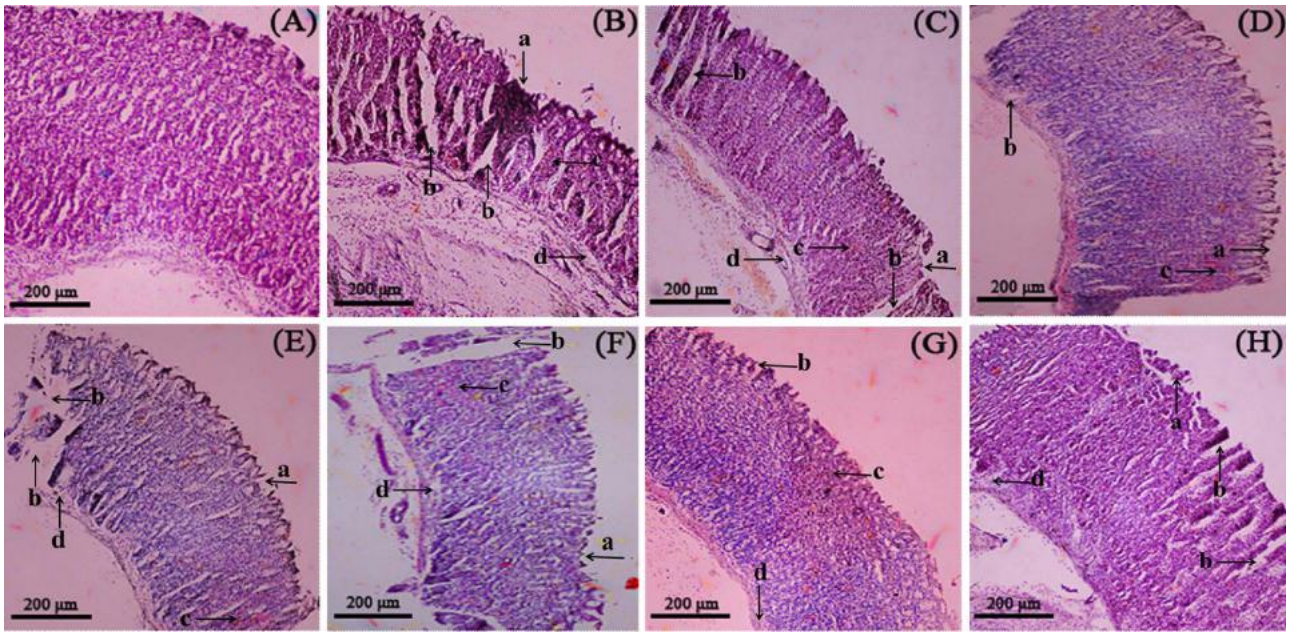

Fig. 2. Histological morphology of gastric mucosa of rats (magnification 40×). (A) NC group, normal control group; (B) UC group, ulcer control group; (C) HERP-L group, 100 mg/kg bw of HERP; (D) HERP-M group, 200 mg/kg bw of HERP; (E) HERP-H group, 400 mg/kg bw of HERP. (F) HECP-L group, 100 mg/kg bw of HECP; (G) HECP-M group, 200 mg/kg bw of HECP; (H) HECP-H group, 400 mg/kg bw of HECP. Letters a–d represent the loss of normal stomach glandular structure, disorganized glandular structure, hemorrhage and submucosal edema, successively.

Table 4
Effect of *Hericium erinaceus* polysaccharide on gastric secretions of rats induced by pylorus ligation (n = 12, mean ± SD).

Group	Gavage dose of polysaccharide (mg/kg bw)	Volume of gastric juice (mL)	pH value	Pepsin activity (U/mL)[β]	Mucus (mg/mL)[β]	Free acidity (mmol/L)[β]	Total acidity (mmol/L)[β]	Acid output (mmol/h)
NC	0.9% NaCl[α]	0.23 ± 0.1[a]	2.2 ± 0.5[c]	9.1 ± 1.3[a]	36.2 ± 2.8[c]	21.0 ± 3.6[a]	67.2 ± 8.5[a]	3.1 ± 1.0[a]
UC	0.9% NaCl[α]	12.7 ± 4.1[c]	1.5 ± 0.3[a]	15.4 ± 2.0[c]	27.4 ± 2.1[a]	43.7 ± 8.2[c]	85.8 ± 14.2[c]	203.3 ± 63.2[d]
HERP-L	100	10.2 ± 2.3[bc]	1.6 ± 0.4[ab]	14.8 ± 2.8[bc]	29.1 ± 2.1[ab]	39.4 ± 3.6[bc]	85.6 ± 7.5c	176.0 ± 47.4[cd]
HERP-M	200	7.2 ± 2.8[b]	2.2 ± 0.1[c]	11.5 ± 2.6[ab]	31.5 ± 2.3[b]	32.3 ± 8.0[b]	69.1 ± 10.6[a]	98.5 ± 38.6[b]
HERP-H	400	8.5 ± 2.3[b]	1.9 ± 0.4[abc]	13.9 ± 1.3[bc]	29.9 ± 0.7[ab]	36.4 ± 8.0[bc]	79.0 ± 9.3[abc]	134.0 ± 38.8[bc]
HECP-L	100	9.9 ± 2.1[bc]	1.7 ± 0.4[abc]	14.7 ± 2.2[bc]	29.7 ± 1.0[ab]	38.7 ± 4.0[bc]	84.0 ± 9.9[bc]	168.5 ± 48.0[cd]
HECP-M	200	8.2 ± 3.3[b]	2.0 ± 0.3[bc]	11.7 ± 0.9[ab]	31.3 ± 2.4[b]	34.1 ± 7.4[b]	73.1 ± 5.5[ab]	120.0 ± 46.9[bc]
HECP-H	400	8.3 ± 3.4[b]	1.9 ± 0.3[abc]	11.9 ± 4.7[ab]	30.2 ± 1.1[b]	34.8 ± 7.1[b]	78.2 ± 6.3[abc]	147.8 ± 64.5[bcd]

NC, normal control group; UC, ulcer control group; HERP-L, 100 mg/kg bw of HERP; HERP-M, 200 mg/kg bw of HERP; HERP-H, 400 mg/kg bw of HERP; HECP-L, 100 mg/kg bw of HECP; (g) HECP-M, 200 mg/kg bw of HECP; (h) HECP-H, 400 mg/kg bw of HECP. Values in the same column with different letters represent significantly different ($p < 0.05$) from each other.
[α] Oral administration of 0.9% NaCl solution without polysaccharide.
[β] Values were calculated based on the volume of tested gastric juice.

serum. Levels of TNF-α, IL-1β and gastrin in serum were detected by ELISA kits referring to the instructions provided by manufacturers. Supernatant of the gastric tissue homogenate (10%, w/v) was harvested at 4 °C (2683 × *g*, 15 min). Activities of SOD, GPx and MPO of supernatant were evaluated under the guide of the manufacturer's instructions. Meanwhile, levels of biochemical molecules (NO, PGE2, HIS and EGF) in supernatant were detected using the procedures given by manufacturers.

2.5.6. Digestive enzyme activity in duodenum contents

Duodenum contents were collected into a tube in an ice-bath, and then centrifuged at 13000 × *g* for 15 min at 4 °C to achieve the supernatant. Activities of digestive enzymes, including α-amylase, trypsin and chymotrypsin of supernatant were determined using the assay kits.

2.6. In vitro antioxidant assays

DPPH radical (DPPH·) scavenging activity of *Hericium erinaceus* polysaccharide was investigated on the basis of the method described by Shimada, Fujikawa, Yahara and Nakamura, (1992), while the hydroxyl radical (·OH) scavenging activity and ferrous ion (Fe^{2+})-chelating activity were performed referring to the method of Zhang et al. (2012). Ascorbic acid (Vc) was used as the standard in the measurements of DPPH· and ·OH scavenging activity. Ethylenediamine tetraacetic acid disodium salt (EDTA) was applied for the standard in Fe^{2+}-chelating activity examination. All samples were thrice assayed at five different concentrations (1.0, 2.0, 4.0, 8.0 and 16.0 mg/mL).

2.7. Statistical analysis

All values were represented as mean ± standard deviation (SD). Statistical analysis was carried out using SPSS 19.0 software (SPSS Inc., Chicago, United States). One-way analysis of variance (ANOVA) was adopted to compare the significant differences among all of groups using Tukey's analysis. Differences were considered to be significant at $p < 0.05$.

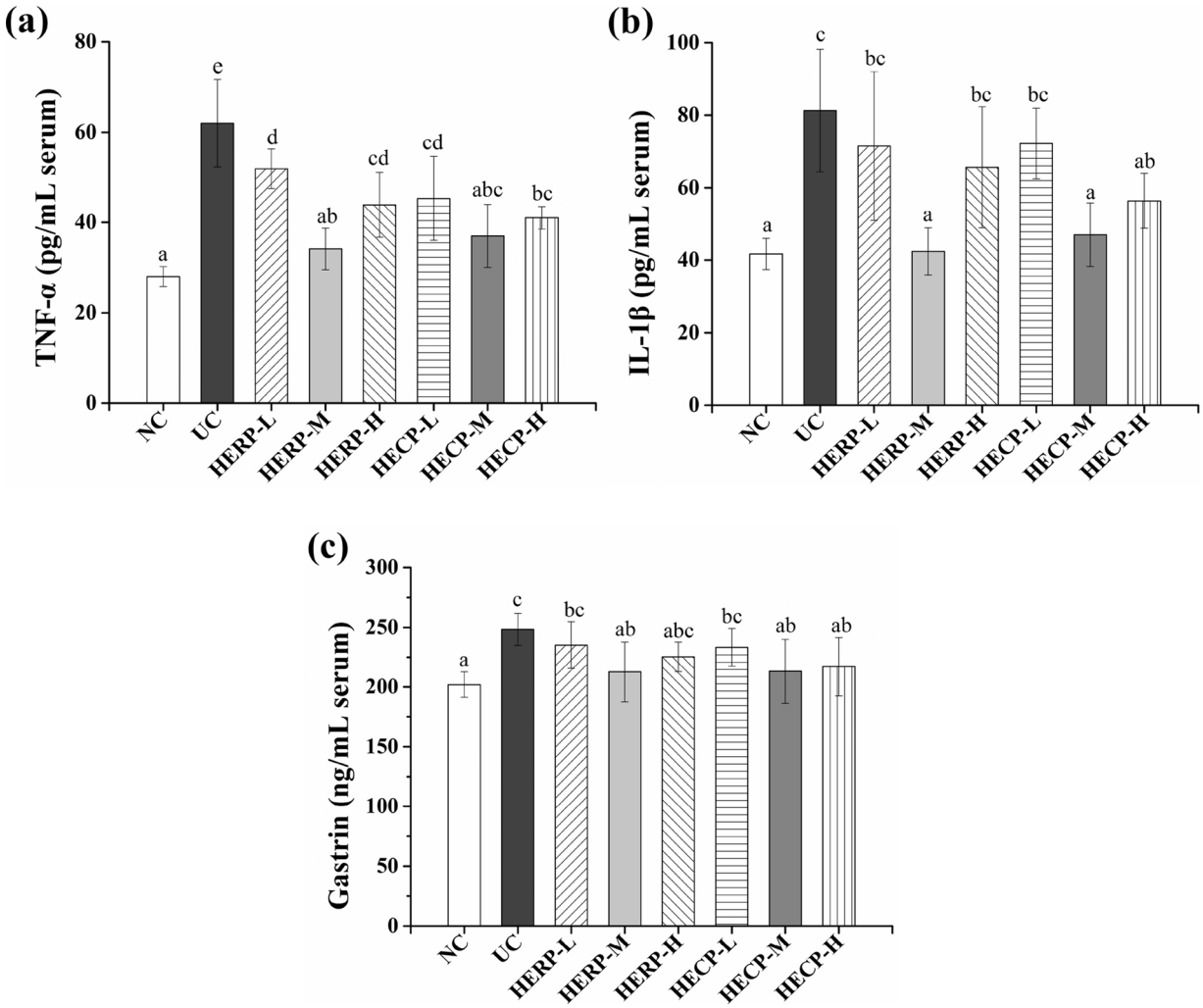

Fig. 3. The levels of TNF-α (a), IL-1β (b) and gastrin (c) in serum of rats. NC, normal control group; UC, ulcer control group; HERP-L, 100 mg/kg bw of HERP; HERP-M, 200 mg/kg bw of HERP; HERP-H, 400 mg/kg bw of HERP; HECP-L, 100 mg/kg bw of HECP; HECP-M, 200 mg/kg bw of HECP; HECP-H, 400 mg/kg bw of HECP. All values were expressed as the mean ± SD (n = 12). Different letters represented significantly different ($p < 0.05$) from each other.

3. Results

3.1. Protective effect of polysaccharide against ethanol-induced gastric mucosal lesion

It is well known that ethanol is an ulcerogenic agent that produces erosions, ulcerative lesions, and petechial bleeding on the gastric mucosa layer (Tu, Tung, Lee, & Yen, 2017). Macroscopical observations of gastric mucosa showed that there was no lesion strip in the NC group, while lesion strips appeared in other groups. Meanwhile, total lesion score, lesion index and lesion inhibition rate were summarized in Table 2. The highest total lesion score and lesion index were found in the LC group which had the most serious lesion. Total lesion score and lesion index were dose-dependently decreased in HERP or HECP groups. Particularly, lesion index was significantly reduced when rat pre-treated with 400 mg/kg bw of HERP or HECP. The results implied that *Hericium erinaceus* polysaccharide exerted positive effects against gastric mucosal lesion caused by ethanol.

3.2. Protective effect of polysaccharide against pylorus-ligation induced gastric ulcer

3.2.1. Gastric ulcer index and ulcer inhibition

Macroscopical observations showed that hemorrhagic spots and ulcer stripes were occurred in the mucosal layer of stomach in the UC group (Fig. 1). Gastric ulcer was alleviated in the polysaccharide treated groups, especially in the medium dose groups. As shown in Table 3, significant reduction of ulcer index was seen in polysaccharide treated groups except the HERP-L group. The most apparent decrease of ulcer index and increase of ulcer inhibition rate were generated when rat fed with HERP or HECP at dose of 200 mg/kg bw. Moreover, there were some differences in inhibiting ulcer formation between HERP and HECP. Lower ulcer index and higher ulcer inhibition rate were observed in the HECP groups, apart from at the medium dosage.

3.2.2. Histological morphology

In the NC group, the gastric mucosa was smooth with no stomach glandular structure loss, disorganized glandular structure, hemorrhage and submucosal edema (Fig. 2A). However, extensive stomach glandular structure loss, large amounts of disorganized glandular structure, and occurrences of hemorrhage and submucosal edema were observed in the UC group (Fig. 2B). With the pre-treatment of HERP or HECP, these symptoms were alleviated. The disorganized glandular structure in the HERP-L (Fig. 2C) or HECP-L (Fig. 2F) group was less than that in the UC group. There was little glandular structure loss and small amount of disorganized glandular structure in the HERP-H (Fig. 2E) or HECP-H group (Fig. 2H). Remarkably, the gastric mucosa in HERP-M (Fig. 2D) or HECP-M (Fig. 2G) group was almost smooth, with no obvious disorganized glandular structure.

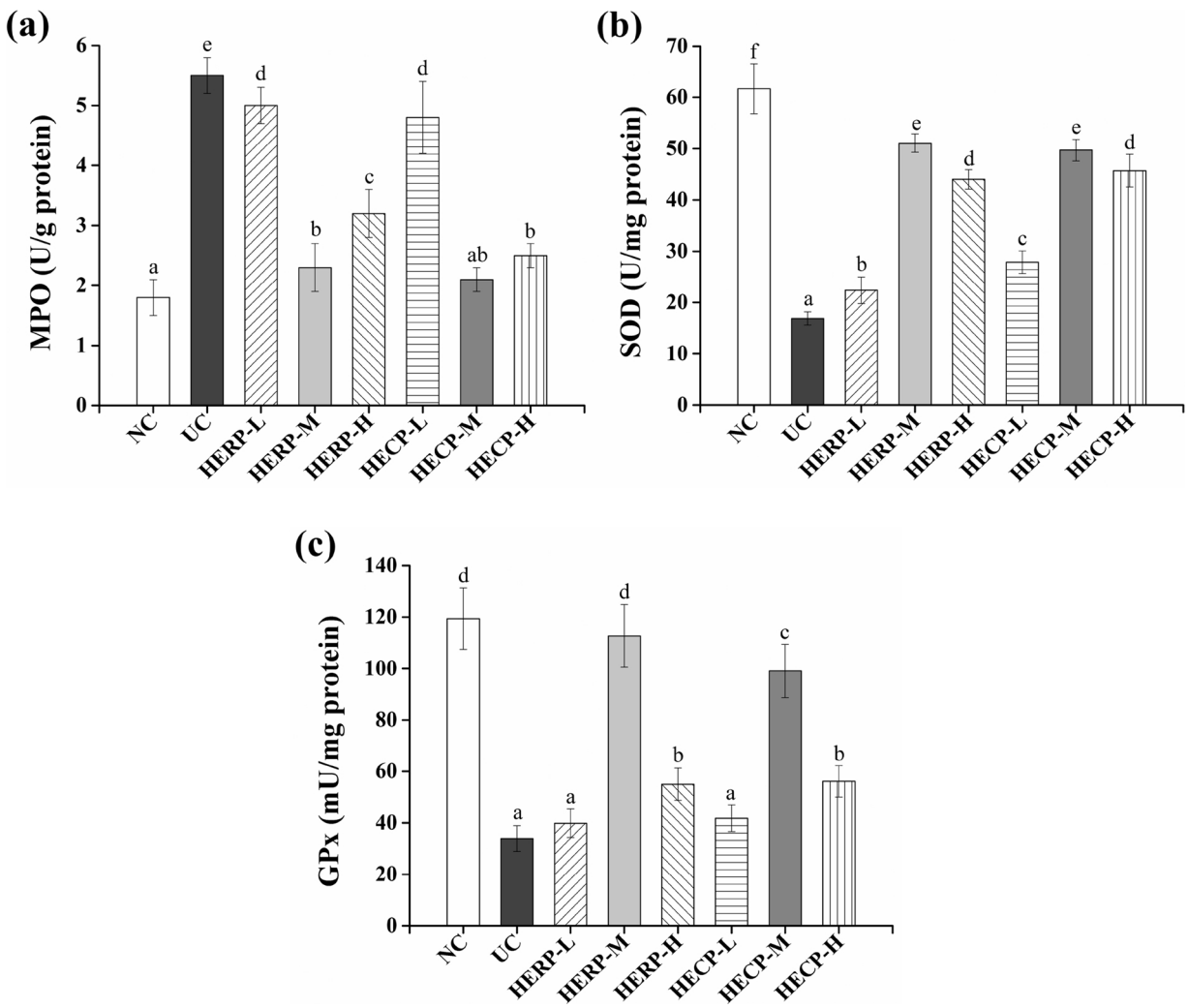

Fig. 4. The activities of MPO (a), SOD (b) and GPx (c) in gastric tissues of rats. NC, normal control group; UC, ulcer control group; HERP-L, 100 mg/kg bw of HERP; HERP-M, 200 mg/kg bw of HERP; HERP-H, 400 mg/kg bw of HERP; HECP-L, 100 mg/kg bw of HECP; HECP-M, 200 mg/kg bw of HECP; HECP-H, 400 mg/kg bw of HECP. All values were expressed as the mean ± SD (n = 12). Different letters represent significantly different ($p < 0.05$) from each other.

Table 5
Effect of *Hericium erinaceus* polysaccharide on the releases of offensive and defensive factors in gastric tissues of rats induced by pylorus ligation (n = 12, mean ± SD).

Group	Gavage dose of polysaccharide (mg/kg bw)	NO (μM)[β]	HIS (ng/mL)[γ]	PGE2 (ng/L)[γ]	EGF (pg/mL)[γ]
NC	0.9% NaCl[α]	17.3 ± 1.7[f]	276.8 ± 14.7[a]	312.5 ± 16.6[e]	255.1 ± 14.1[e]
UC	0.9% NaCl[α]	6.2 ± 0.9[a]	441.6 ± 17.5[g]	197.9 ± 18.9[a]	127.4 ± 7.3[a]
HERP-L	100	7.3 ± 0.5[ab]	419.7 ± 18.6[f]	217.5 ± 17.5[a]	169.8 ± 9.1[b]
HERP-M	200	14.0 ± 1.0[e]	324.5 ± 14.2[b]	284.7 ± 19.8[d]	228.3 ± 14.3[d]
HERP-H	400	8.6 ± 1.7[bc]	362.0 ± 11.9[d]	244.9 ± 15.4[b]	197.1 ± 15.9[c]
HECP-L	100	8.1 ± 1.2[b]	392.0 ± 16.6[e]	218.0 ± 13.5[a]	172.4 ± 15.1[b]
HECP-M	200	12.1 ± 0.3[d]	339.2 ± 15.8[bc]	273.4 ± 17.8[cd]	219.0 ± 11.0[d]
HECP-H	400	9.6 ± 0.8[c]	347.8 ± 13.3[cd]	259.1 ± 15.8[bc]	209.7 ± 18.7[cd]

NC, normal control group; UC, ulcer control group; HERP-L, 100 mg/kg bw of HERP; HERP-M, 200 mg/kg bw of HERP; HERP-H, 400 mg/kg bw of HERP; HECP-L, 100 mg/kg bw of HECP; HECP-M, 200 mg/kg bw of HECP; HECP-H, 400 mg/kg bw of HECP. Values in the same column with different letters represent significantly different ($p < 0.05$) from each other.

[α] Oral administration of 0.9% NaCl solution without polysaccharide.

[β] Values were calculated from the NO calibration curve.

[γ] Values were calculated based on the volume of gastric tissue homogenate.

3.2.3. Gastric secretions

As a result of pylorus ligation, the pH value and mucus content of gastric juice of rat in the UC group were significantly declined, compared with those of rat in the NC group. Meanwhile, gastric juice volume, pepsin activity, free acidity, total acidity and acid output were obviously increased (Table 4). After administrating with HERP or HECP, the phenomena were alleviated, especially at the dose of 200 mg/kg bw. The results indicated that *Hericium erinaceus* polysaccharide could regulate the gastric secretions of rat in the pylorus ligation-induced model, which might play crucial roles in maintaining gastric barrier and reducing gastric ulcer (Gasbarrini, D'Aversa, Rienzo, & Franceschi, 2014). Moreover, there were some differences between HERP and HECP in regulating the gastric secretions. At a same dosage (except 200 mg/kg bw), administration of HECP caused more obvious

Table 6
Effect of *Hericium erinaceus* polysaccharides on digestive enzymes activities in duodenum contents (n = 12, mean ± SD).

Group	Gavage dose of polysaccharide (mg/kg bw)	α-amylase (U/dL)[β]	Trypsin (KU/mL)[β]	Chymotrypsin (U/mg prot)[γ]
NC	0.9% NaCl[α]	1334.6 ± 67.7[a]	299.4 ± 12.8[a]	0.6 ± 0.2[a]
UC	0.9% NaCl[α]	1293.0 ± 57.0[a]	1225.1 ± 44.7[f]	2.3 ± 0.6[d]
HERP-L	100	1302.2 ± 59.5[a]	764.4 ± 20.0[e]	1.8 ± 0.1[c]
HERP-M	200	1332.1 ± 61.0[a]	355.4 ± 21.9[b]	0.7 ± 0.1[a]
HERP-H	400	1320.6 ± 62.2[a]	640.8 ± 24.4[d]	1.3 ± 0.2[b]
HECP-L	100	1314.3 ± 54.8[a]	653.7 ± 22.8[d]	1.6 ± 0.4[bc]
HECP-M	200	1331.3 ± 49.5[a]	363.6 ± 13.8[b]	0.8 ± 0.2[a]
HECP-H	400	1325.8 ± 55.1[a]	497.9 ± 22.6[c]	1.3 ± 0.1[b]

NC, normal control group; UC, ulcer control group; HERP-L, 100 mg/kg bw of HERP; HERP-M, 200 mg/kg bw of HERP; HERP-H, 400 mg/kg bw of HERP; HECP-L, 100 mg/kg bw of HECP; HECP-M, 200 mg/kg bw of HECP; HECP-H, 400 mg/kg bw of HECP. Values in the same column with different letters represent significantly different ($p < 0.05$) from each other.

[α] Oral administration of 0.9% NaCl solution without polysaccharide.

[β] Values were caculated based on the volume of duodenum content supernatant.

[γ] Values were caculated based on the protein content of duodenum content supernatant.

reduction or increase in aforementioned gastric secretion parameters. This might be explained by the different contents between HECP and HERP (Wang et al., 2017; Wang et al., 2018).

3.2.4. TNF-α, IL-1β and gastrin levels in serum

Previous report demonstrated that the inflammatory response was activated when gastric mucosa was damaged, and it may cause secondary mucosal damage (Franke, Teyssen, & Singer, 2005). Levels of TNF-α and IL-1β in serum were obviously increased in the UC group (Fig. 3). Lower TNF-α level were observed when rat was supplemented with HERP or HECP (Fig. 3a). Moreover, the IL-1β level was significantly decreased in the HERP-M, HECP-M and HECP-H groups (Fig. 3b). The aforementioned results suggested that the pre-treatment of HERP or HECP could attenuate the inflammatory response of ulcer rat. Besides, the level of gastrin, a mucosal defense moderator (Komori et al., 2002), in serum was obviously up-regulated in the UC group, whereas this up-regulation was markedly inhibited in the HERP-M, HECP-M and HECP-H groups (Fig. 3c).

3.2.5. MPO, SOD and GPx activities in gastric tissue

MPO activity was commonly used to assess the degree of neutrophil infiltration into gastric mucosa in the gastric injury model (Olatunji, Chen, & Zhou, 2015). It was found that the MPO activity was observably increased in the UC group, while the increase was clearly mitigated in the polysaccharide treated groups (Fig. 4a). The result implied that HERP or HECP exerted inhibition effect on the neutrophil infiltration, which was beneficial to maintain the integrity of gastric mucosa (Amirshahrokhi & Khalili, 2015). Oxidative stress caused by the imbalance between oxidation level and antioxidant defenses is an important pathogenesis of gastric ulcer (Zaghlool et al., 2015). The activities of antioxidant enzymes (SOD and GPx) were significantly abated in the UC group (Fig. 4b and c). It was clear that SOD activity in polysaccharide treated groups, and GPx activity in the medium and high doses groups of HERP or HECP were obvious higher than those in the UC group.

3.2.6. Offensive and defensive factors in gastric tissue

Releases of NO, HIS, PGE2 and EGF in gastric tissue are summarized in Table 5. These biochemical molecules (NO, HIS, PGE2 and EGF) are closely associated with the offense and defense of gastric mucosa (Kemmerly & Kaunitz, 2013). Compared with the NC group, significant reductions in levels of NO, PGE2 and EGF accompanied by obvious increment in HIS level were discovered in the UC group. However, the phenomena were significantly altered when rat was fed with HERP or HECP, suggesting that the administration of HERP or HECP was conducive to modulate the synthesis of offensive and defensive factors in gastric tissue. Similar effects were found in other polysaccharides previously reported (Chatterjee et al., 2013; Manjegowda, Rajagopal, & Dharmesh, 2017).

3.2.7. Digestive enzymes activities in duodenum contents

The blend of gastric content, pancreatic juice and bile in the duodenum was failed to proceed because of pylorus ligation, resulting in alterations of internal environment of duodenum, which contributed to the occurrence of duodenum ulcer (Boylan et al., 2014). Thus, activities of digestive enzymes in duodenum contents of rats were determined (Table 6). There was no conspicuous difference in α-amylase activity among all groups. However, the activities of trypsin and chymotrypsin were obviously increased in the UC group compared with those in the NC group. In the HERP or HECP groups, significant decrease of trypsin activity was produced. Moreover, chymotrypsin activity was significantly reduced in the medium and high doses groups of HERP or HECP. Trypsin and chymotrypsin have been reported to be descriptors for duodenum inflammation (Mcneish, Roux, Aylett, Am, & Cottrell, 2012). Therefore, *Hericium erinaceus* polysaccharide might also have potential in preventing duodenum ulcer through down-regulating the inflammatory response.

3.3. In vitro antioxidant activities of polysaccharide

It was reported that generations of $O_2^-\cdot$, $H_2O_2^-$ and ·OH radicals in gastric tissue contribute to the increase of lipid peroxidation and decrease of antioxidant in pylorus-ligated and ethanol-induced ulcer rats (Hariprasath, Raman, & Nanjian, 2012). In this regard, the roles of *Hericium erinaceus* polysaccharide in free radicals scavenging and Fe^{2+}-chelating were assessed (Fig. 5). In the concentration range from 1.0 mg/mL to 16.0 mg/mL, HERP or HECP exhibited high scavenging effects of DPPH· and ·OH and moderate Fe^{2+}-chelating activity. The DPPH· scavenging activity of HERP or HECP was concentration-dependently increased (Fig. 5a), and this activity of HERP (40.8%–81.1%) was always higher than that of HECP (37.0%–76.5%). It was worth noting that the ·OH scavenging percentage of HERP (90.0 ± 3.1%) was close to that of Vc (96.2 ± 0.4%) at the concentration of 16.0 mg/mL (Fig. 5b). As shown in Fig. 5c, HECP exerted higher Fe^{2+}-chelating activity than HERP in the tested concentration range.

4. Discussion

Ethanol-induced and pylorus ligation-induced models are widely used for the reproduction of gastric injury or ulcer (Berté et al., 2014; Hariprasath et al., 2012). Accordingly, these two models were adopted in the gastroprotective investigation of *Hericium erinaceus* polysaccharide in rats in our study. Overdose ethanol ingestion could directly damage gastric mucosa through its diffusion into gastric mucosa (Amirshahrokhi & Khalili, 2015). This study showed that *Hericium erinaceus* polysaccharide could significantly decrease gastric injury at the dose of 400 mg/kg bw. The gastric ulcer induced by pylorus ligation is mainly resulted from excessive secretions of gastric acid and pepsin (Xu et al., 2016). Gastrin and HIS are stimulators for the secretion of gastric acid, which is responsible for altering the permeability of gastric mucosal wall and accelerating ulceration (Bishr, 2016; Zhang et al., 2014). Excessive gastric acid secretion stimulates pepsin release and then up-regulates the self-digestion of gastric mucosa (Venables, 1986). In our investigation, volume of gastric juice, gastric acid secretion, pepsin activity of gastric juice, gastrin level in serum and HIS level in gastric tissue were significantly increased in the UC group. However, the phenomena were attenuated in HERP or HECP groups.

Once gastric mucosa was damaged, inflammatory process was activated (Liu et al., 2016), thereby increasing inflammatory mediators,

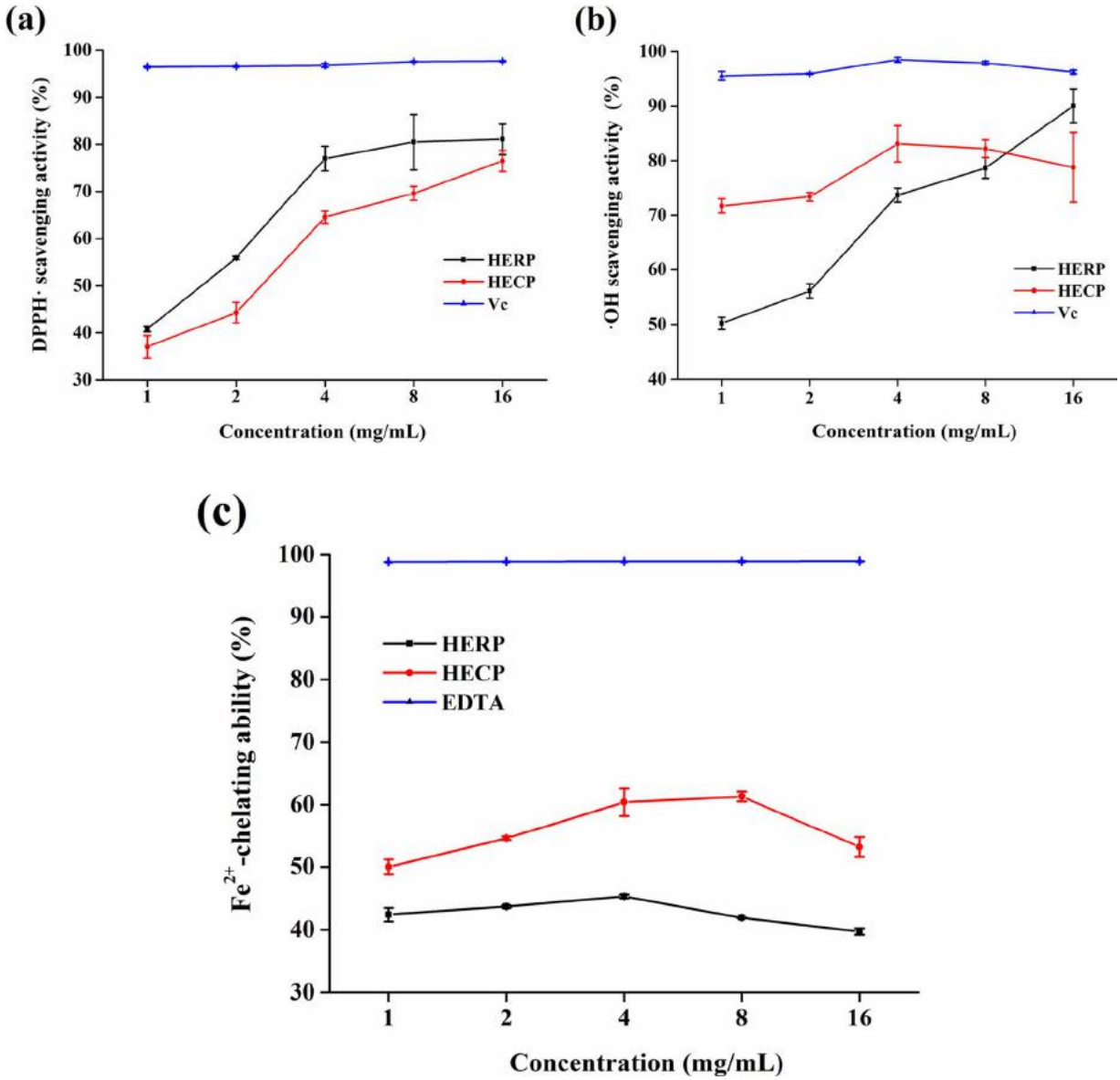

Fig. 5. *In vitro* antioxidant activities of *Hericium erinaceus* polysaccharide. (a) DPPH radical scavenging activity; (b) Hydroxyl radical scavenging activity; (c) Fe^{2+}-chelating activity. Values were expressed as the mean ± SD (n = 3).

including TNF-α, IL-1β and IL-6 (Liu et al., 2016). TNF-α stimulates neutrophil infiltration and epithelial cell apoptosis, reduces gastric microcirculation around the ulcer region and delays gastric ulcer healing (Rozza, Meira, Souza Brito, & Pellizzon, 2014). The extensive expression of IL-1β greatly contributes to ulcer formation (Moezi et al., 2013). Significant declines in expressions of TNF-α and IL-1β in serum of rats generated by HERP or HECP implying that the polysaccharide was capable of reducing inflammatory response. Infiltration and accumulation of leucocytes in gastric mucosa were usually assessed using MPO activity (Amirshahrokhi & Khalili, 2015). In this investigation, MPO activity of gastric tissue in polysaccharide treated group was lower than that in UC group, which well confirmed the effect of the polysaccharide on the reduction of inflammatory response.

Mucus-bicarbonate barrier is the primary defense of gastric mucosa. Mucus is a gel adhering to the mucosa, preventing gastric acid penetrating into the mucosa and whittling some mechanical abrasion (Bishr, 2016). The mucus content in gastric juice was higher in HERP or HECP group than the UC group, indicating supplement of polysaccharide could protect the integrity of gastric mucosa. This effect was well confirmed in histopathological observation. Generally, mucus interacts with NO, PGE2 and EGF to maintain the mucosal integrity (Bishr, 2016). NO protects mucus barrier and gastric epithelial integrity through diminishing the gastric acid secretion from parietal cells (Yandrapu & Sarosiek, 2015). PEG2 increases mucus and bicarbonate secretion led to decrease gastric epithelial permeability (Sofidiya, Orisaremi, Sansaliyu, & Adetunde, 2015). EGF induces the proliferation of epithelial cell and then promotes tissue healing (Bishr, 2016). The present study showed that the protective effects of *Hericium erinaceus* polysaccharide on the integrity of gastric mucosa were achieved by increasing the releases of NO, PGE2 and EGF in gastric tissue.

There is also an antioxidant defense established by non-enzymatic and enzymatic antioxidants for gastric mucosa (Nartey, Ofosuhene, & Agbale, 2012). Among them, SOD could rapidly convert peroxyl radicals into biologically safe inactive substances (Kemmerly & Kaunitz, 2013). GPx protects gastric mucosa from ROS injury and reduces lipid hydroperoxides (Sidahmed et al., 2013). The increases of SOD and GPx activities resulted from HERP or HECP administration suggested the enhancement of antioxidant status of gastric tissue. HERP or HECP also showed scavenging effects of DPPH· and ·OH and Fe^{2+}-chelating ability *in vitro*. Having considered that phenolic compounds have been

reported to be main contributors of antioxidant capacities of *Hericium erinaceus* (Guo et al., 2012), the different behaviours appeared in *in vitro* antioxidant activity between HERP and HECP was mainly because of their differences in total phenols content (Wang et al., 2017; Wang et al., 2018). A previous investigation carried out by Wang et al. demonstrated that the *in vitro* antioxidant properties of a purified polysaccharide isolated from *Hericium erinaceus* mycelium closely correlated with its positive roles in preventing H_2O_2-induced apoptotic cell death of GES-1 (Wang et al., 2017; Wang et al., 2018). Therefore, the antioxidant activity might be a crucial mechanism for the polysaccharide prepared from the fruiting body of *Hericium erinaceus* polysaccharide in allivating gastric ulcer formation.

Previous studies have shown that the anti-ulcer effects of polysaccharides were mainly achieved in one or more pathways (Maria-Ferreira et al., 2014; Yamada, 1994): binding to the mucosa surface to provide a protective coating, diminishing the secretions of gastric acid and pepsin, protecting the mucus barrier, reducing oxidative stress and/or inflammatory response of gastric mucosa. Our observation indicated that the latter three pathways were involved in the gastroprotective effects of *Hericium erinaceus* polysaccharide in pylrous ligation-induced model. Similar effects were also found in polysaccharides from *Lachnum* sp. (Xu et al., 2016), potato (Chandrashekar & Dharmesh, 2016), *Curcuma longa* (Harsha, Prakash, & Dharmesh, 2016) and marine algae *Solieria filiformis* (Sousa et al., 2016). Moreover, *Hericium erinaceus* polysaccharide might also exert anti-ulcer effects by up-regulating the synthesis of NO, PGE2 and EGF, which was consistent with previously reported polysaccharides (Damasceno et al., 2013; Gao et al., 2004). The findings of Wong et al. suggested that the gastroprotective effects of aqueous extract of the fruiting body from *Hericium erinaceus* against ethanol-induced ulcers were operated by increasing mucus production and depletion of antioxidant enzymes (Wong et al., 2013). Obviously, the *Hericium erinaceus* polysaccharide might be the main bioactive compound in protecting gastric mucosa.

5. Conclusions

Hericium erinaceus polysaccharide had gastroprotective effects against ethanol-induced gastric mucosal lesion and pylorus ligation-induced gastric ulcer in rats. It has potential in preventing duodenum ulcer and promoting SCFAs productions (seen in Fig. S1 in Supplementary data). The increase of SCFAs was beneficial to the suppression of gastric acid secretion in ulcer rats apart from improving improve colonic health (Berehova & Falalieieva, 2006). The mechanism of gastroprotective activity was disclosed as its antisecretory, antioxidant, anti-inflammatory and increments of defensive factors (NO, PGE2 and EGF). This study clearly highlights the application of *Hericium erinaceus* extract in adjuvant therapy of gastric ulcers. The future work will focus on exploring the relationships between structural features and gastroprotective activities.

Acknowledgments

The authors are grateful for the support from the National Natural Science Foundation of China for Excellent Young Scholars (31422042), National Key Technology R & D Program of China (2012BAD33B06), Outstanding Science and Technology Innovation Team Project in Jiangxi Province (20165BCB19001) and Collaborative Project in Agriculture and Food Field between China and Canada (2017ZJGH0102001).

Appendix A. Supplementary data

Supplementary data associated with this article can be found, in the online version, at https://doi.org/10.1016/j.carbpol.2018.01.004.

References

Abdulla, M. A., Noor, S., Wong, K. H., & Ali, M. H. (2008). Effect of culinary-medicinal lion's mane mushroom, *Hericium erinaceus* (Bull.: Fr.) pers. (aphyllophoromycetideae), on ethanol-induced gastric ulcers in rats. *International Journal of Medicinal Mushrooms, 10*, 325–330.

Amirshahrokhi, K., & Khalili, A. R. (2015). The effect of thalidomide on ethanol-induced gastric mucosal damage in mice: Involvement of inflammatory cytokines and nitric oxide. *Chemico-Biological Interactions, 225*, 63–69.

Awaad, A. S., El-Meligy, R. M., & Soliman, G. A. (2012). Natural products in treatment of ulcerative colitis and peptic ulcer. *Journal of Saudi Chemical Society, 17*, 101–124.

Berehova, T. V., & Falalieieva, T. M. (2006). The role of short chain fatty acids and lactate in regulation of the gastric secretion. *Fiziolohichnyĭ Zhurnal, 52*, 42–51.

Berté, P. E., Lopes, J. D. S., Comandulli, N. G., Rangel, D. W., Monache, F. D., Filho, V. C., et al. (2014). Evaluation of the gastroprotective activity of the extracts, fractions, and pure compounds obtained from aerial parts of *Rubus imperialis* in different experimental models. *Naunyn-Schmiedeberg's Archives of Pharmacology, 387*, 313–319.

Bi, W. P., Man, H. B., & Man, M. Q. (2014). Efficacy and safety of herbal medicines in treating gastric ulcer: A review. *World Journal of Gastroenterology, 20*, 17020–17028.

Bishr, A. M. (2016). *The potential gastro protective effect of certain natural products in experimentally induced ulceration in rats. Cu Theses*1–21.

Boylan, M. R., Khalili, H., Huang, E. S., Michaud, D. S., Izard, J., Joshipura, K. J., et al. (2014). A prospective study of periodontal disease and risk of gastric and duodenal ulcer in male health professionals. *Clinical and Translational Gastroenterology, 5*, 1–6.

Chandrashekar, K. B., & Dharmesh, S. M. (2016). Gastro protective and H+, K+-ATPase/H. pylori inhibitory properties of pectic polysaccharides from potato. *International Journal of Biological Macromolecules, 84*, 385–393.

Chatterjee, A., Khatua, S., Chatterjee, S., Mukherjee, S., Mukherjee, A., Paloi, S., et al. (2013). Polysaccharide-rich fraction of *Termitomyces eurhizus* accelerate healing of indomethacin induced gastric ulcer in mice. *Glycoconjugate Journal, 30*, 759–768.

Damasceno, S. R., Rodrigues, J. C., Silva, R. O., Nicolau, L. A., Chaves, L. S., Freitas, A. L., et al. (2013). Role of the NO/KATP pathway in the protective effect of a sulfated-polysaccharide fraction from the algae *Hypnea musciformis* against ethanol-induced gastric damage in mice. *Revista Brasileira de Farmacognosia, 23*, 320–328.

Franke, A., Teyssen, S., & Singer, M. V. (2005). Alcohol-related diseases of the esophagus and stomach. *Digestive Diseases, 23*, 204–213.

Gao, Y., Tang, W., Gao, H., Chan, E., Lan, J., & Zhou, S. (2004). *Ganoderma lucidum* polysaccharide fractions accelerate healing of acetic acid-induced ulcers in rats. *Journal of Medicinal Food, 7*, 417–421.

Gargano, M. L., van Griensven, L. J., Isikhuemhen, O. S., Lindequist, U., Venturella, G., Wasser, S. P., et al. (2017). Medicinal mushrooms: Valuable biological resources of high exploitation potential. *Plant Biosystems, 151*, 548–565.

Gasbarrini, A., D'Aversa, F., Rienzo, T. D., & Franceschi, F. (2014). Nutrients affecting gastric barrier. *Digestive Diseases, 32*, 243–248.

Guo, Y. J., Deng, G. F., Xu, X. R., Wu, S., Li, S., Xia, E. Q., et al. (2012). Antioxidant capacities, phenolic compounds and polysaccharide contents of 49 edible macrofungi. *Food & Function, 3*, 1195–1205.

Hariprasath, L., Raman, J., & Nanjian, R. (2012). Gastroprotective effect of Senecio candicans DC on experimental ulcer models. *Journal of Ethnopharmacology, 140*, 145–150.

Harsha, M. R., Prakash, S. V. C., & Dharmesh, S. M. (2016). Modified pectic polysaccharide from turmeric (*Curcuma longa*): A potent dietary component against gastric ulcer. *Carbohydrate Polymers, 138*, 143–155.

He, X. R., Wang, X. X., Fang, J. C., Chang, Y., Ning, N., Guo, H., et al. (2017). Structures, biological activities, and industrial applications of the polysaccharides from *Hericium erinaceus* (Lion's Mane) mushroom: A review. *International Journal of Biological Macromolecules, 97*, 228–237.

Kamarolzaman, M., Yahya, F., Mamet, S. S., Jakius, K. F., Mahmood, N. D., Shahril, M. S., et al. (2014). Gastroprotective activity and mechanisms of action of *Bauhinia purpurea* Linn (Leguminoseae) leaf methanol extract. *Tropical Journal of Pharmaceutical Research, 13*, 1889–1898.

Kangwan, N., Park, J. M., Kim, E. H., & Hahm, K. B. (2014). Quality of healing of gastric ulcers: Natural products beyond acid suppression. *World Journal of Gastrointestinal Pathophysiology, 5*, 40–47.

Kemmerly, T., & Kaunitz, J. D. (2013). Gastroduodenal mucosal defense. *Current Opinion in Gastroenterology, 29*, 642–649.

Komori, M., Tsuji, S., Sun, W. H., Tsujii, M., Kawai, N., Yasumaru, M., et al. (2002). Gastrin enhances gastric mucosal integrity through cyclooxygenase-2 upregulation in rats. *American Journal of Physiology-Gastrointestinal and Liver Physiology, 283*, 1368–1378.

Liu, J., Wang, F., Luo, H., Liu, A., Li, K., Li, C., et al. (2016). Protective effect of butyrate against ethanol-induced gastric ulcers in mice by promoting the anti-inflammatory, anti-oxidant and mucosal defense mechanisms. *International Immunopharmacology, 30*, 179–187.

Manjegowda, S. B., Rajagopal, H. M., & Dharmesh, S. M. (2017). Polysaccharide of Black cumin (Nigella sativa) modulates molecular signaling cascade of gastric ulcer pathogenesis. *International Journal of Biological Macromolecules, 101*, 823–836.

Maria-Ferreira, D., Da Silva, L. M., Mendes, D. A. G. B., de Almeida Cabrini, D., Nascimento, A. M., Iacomini, M., et al. (2014). Rhamnogalacturonan from *Acmella oleracea* (L.) RK Jansen: Gastroprotective and ulcer healing properties in rats. *Plos One, 9*, 1–11.

Mcneish, A. J., Roux, B. T., Aylett, S. B., Am, V. D. B., & Cottrell, G. S. (2012). Endosomal proteolysis regulates calcitonin gene-related peptide responses in mesenteric arteries. *British Journal of Pharmacology, 167*, 1679–1690.

Moezi, L., Heidari, R., Amirghofran, Z., Nekooeian, A. A., Monabati, A., & Dehpour, A. R.

(2013). Enhanced anti-ulcer effect of pioglitazone on gastric ulcers in cirrhotic rats: The role of nitric oxide and IL-1β. *Pharmacological Reports, 65*, 134–143.
Nartey, E. T., Ofosuhene, M., & Agbale, C. M. (2012). Anti-ulcerogenic activity of the root bark extract of the African laburnum "*Cassia sieberiana*" and its effect on the anti-oxidant defence system in rats. *BMC Complementary and Alternative Medicine, 12*, 1–9.
Olatunji, O. J., Chen, H., & Zhou, Y. (2015). Anti-ulcerogenic properties of *Lycium chinense* Mill extracts against ethanol-induced acute gastric lesion in animal models and its active constituents. *Molecules, 20*, 22553–22564.
Park, J. H., Jang, K. J., Kim, C. H., Kim, J. H., Kim, Y. K., & Yoon, H. M. (2015). *Ganoderma Lucidum* pharmacopuncture for teating ethanol-induced chronic gastric ulcers in rats. *Journal of Pharmacopuncture, 18*, 72–78.
Ribeiro, A. R., Diniz, P. B., Estevam, C. S., Pinheiro, M. S., Albuquerquejúnior, R. L., & Thomazzi, S. M. (2013). Gastroprotective activity of the ethanol extract from the inner bark of Caesalpinia pyramidalis in rats. *Journal of Ethnopharmacology, 147*, 383–388.
Rozza, A. L., de Faria, F. M., Brito, A. R., & Pellizzon, C. H. (2014). The gastroprotective effect of menthol: Involvement of anti-apoptotic, antioxidant and anti-inflammatory activities. *Plos One, 9*, 1–6.
Shimada, K., Fujikawa, K., Yahara, K., & Nakamura, T. (1992). Antioxidative properties of xanthone on the auto oxidation of soybean in cylcodextrin emulsion. *Journal of Agricultural and Food Chemistry, 40*, 945–948.
Sidahmed, H. M., Hashim, N. M., Amir, J., Abdulla, M. A., Hadi, A. H., Abdelwahab, S. I., et al. (2013). Pyranocycloartobiloxanthone A, a novel gastroprotective compound from *Artocarpus obtusus* Jarret, against ethanol-induced acute gastric ulcer in vivo. *Phytomedicine, 20*, 834–843.
Sofidiya, M. O., Orisaremi, C. O., Sansaliyu, I., & Adetunde, T. O. (2015). Gastroprotective and antioxidant potentials of ethanolic stem bark extract of *Margaritaria discoidea* (Euphorbiaceae) in rats. *Journal of Ethnopharmacology, 171*, 240–246.
Sousa, W. M., Silva, R. O., Bezerra, F. F., Bingana, R. D., Barros, F. C., Costa, L. E., et al. (2016). Sulfated polysaccharide fraction from marine algae *Solieria filiformis*: Structural characterization, gastroprotective and antioxidant effects. *Carbohydrate Polymers, 152*, 140–148.
Sun, X. B., Matsumoto, T., & Yamada, H. (1991). Effects of a polysaccharide fraction from the roots of *Bupleurum falcatum* L. on experimental gastric ulcer models in rats and mice. *Journal of Pharmacy & Pharmacology, 43*, 699–704.
Tu, P. S., Tung, Y. T., Lee, W. T., & Yen, G. C. (2017). Protective effect of camellia oil (Camellia oleifera abel.) against ethanol-induced acute oxidative injury of the gastric mucosa in mice. *Journal of Agricultural and Food Chemistry, 65*, 4932–4941.
Venables, C. W. (1986). Mucus, pepsin, and peptic ulcer. *Gut, 27*, 233–238.
Venkateswararao, C., & Venkataramana, K. (2013). A pharmacological review on natural antiulcer agents. *Journal of Global Trends in Pharmaceutical Sciences, 4*, 1118–1131.
Wang, C., Su, W., Su, X., Ni, G., Liu, T., & Kong, Y. (2015). Synergy effects of three plant extracts on protection of gastric mucosa. *Natural Product Communications, 10*, 1989–1991.
Wang, M., Konishi, T., Gao, Y., Xu, D., & Gao, Q. (2015). Anti-gastric ulcer activity of polysaccharide fraction isolated from mycelium culture of Lion's Mane medicinal mushroom, *Hericium erinaceus* (Higher Basidiomycetes). *International Journal of Medicinal Mushrooms, 17*, 1055–1060.
Wang, M., Kanako, N., Zhang, Y., Xiao, X., Gao, Q., & Tetsuya, K. (2017). A unique polysaccharide purified from *Hericium erinaceus* mycelium prevents oxidative stress induced by H_2O_2 in human gastric mucosa epithelium cell. *Plos One, 12*, e0181546. http://dx.doi.org/10.1371/journal.pone.0181546.
Wang, X. Y., Yin, J. Y., Nie, S. P., & Xie, M. Y. (2018). Isolation, purification and physicochemical properties of polysaccharide from fruiting body of *Hericium erinaceus* and its effect on colonic health of mice. *International Journal of Biological Macromolecules, 107*, 1310–1319.
Wong, J. Y., Abdulla, M. A., Raman, J., Phan, C. W., Kuppusamy, U. R., Golbabapour, S., et al. (2013). Gastroprotective effects of Lion's Mane mushroom *Hericium erinaceus* (Bull.:Fr.) Pers. (Aphyllophoromycetideae) extract against ethanol-induced ulcer in rats. *Evidence-Based Complementary and Alternative Medicine, 2013*, 1–9.
Xu, P., Yang, L., Yuan, R. Y., Ye, Z. Y., Ye, H. R., & Ye, M. (2016). Structure and preventive effect against ethanol-induced gastric ulcer of expolysaccharide from *Lachnum* sp. *International Journal of Biological Macromolecules, 86*, 10–17.
Yamada, H. (1994). Pectic polysaccharides from Chinese herbs: Structure and biological activity. *Carbohydrate Polymers, 25*, 269–276.
Yandrapu, H., & Sarosiek, J. (2015). Protective factors of the gastric and duodenal mucosa: An overview. *Current Gastroenterology Reports, 17*, 1–8.
Zaghlool, S. S., Shehata, B. A., Abo-Seif, A. A., & El-Latif, H. A. A. (2015). Assessment of protective effects of extracts of *Zingiber officinale* and *Althaea officinalis* on pyloric ligation-induced gastric ulcer in experimental animals. *UK Journal of Pharmaceutical and Biosciences, 3*, 44–53.
Zhang, Z., Lv, G., Pan, H., Pandey, A., He, W., & Fan, L. (2012). Antioxidant and hepatoprotective potential of endo-polysaccharides from *Hericium erinaceus* grown on tofu whey. *International Journal of Biological Macromolecules, 51*, 1140–1146.
Zhang, S. L., Li, H., He, X., Zhang, R. Q., Sun, Y. H., Zhang, C. F., et al. (2014). Alkaloids from Mahonia bealei posses anti-H(+)/K(+)-ATPase and anti-gastrin effects on pyloric ligation-induced gastric ulcer in rats. *Phytomedicine, 21*, 1356–1363.