medRxiv preprint doi: https://doi.org/10.64898/2026.03.04.26347460; this version posted March 10, 2026. The copyright holder for this preprint (which was not certified by peer review) is the author/funder, who has granted medRxiv a license to display the preprint in perpetuity. It is made available under a CC-BY-NC 4.0 International license .

Title: Diagnosis of Multiple Sclerosis Using Multimodal Deep Learning Integrating Lesion and Normal-Appearing White Matter: A Retrospective Study with International Multicentre External Validation

Authors: Jiajian Ma[1], Valentin Stepanov[2-4], Wushuang Rui[5], Hsuan-Chih Chen[1], Maciej Lis[6,7], Aleksandra Stanek[6], Tomasz Puto[6,8], Michael Lan[2], Jenny Chen[2-4], Timothy Liu[9], Roshni Patel[2], Matthew Breen[2], Matthew Lee[2], Katharina Eikermann-Haerter[2], Timothy M. Shepherd[2], Dmitry S. Novikov[2-4], Kimberly A. O'Neill[10], Els Fieremans[2-4]*, Yiqiu Shen[2,4,1]*

Author Affiliation:
[1] Center for Data Science, New York University, New York, NY, USA
[2] Department of Radiology, New York University Grossman School of Medicine, New York, NY, USA
[3] Bernard and Irene Schwartz Center for Biomedical Imaging, Department of Radiology, New York University Grossman School of Medicine, New York, NY, USA
[4] Center for Advanced Imaging Innovation and Research (CAI2R), Department of Radiology, New York University Grossman School of Medicine, New York, NY, USA
[5] Department of Biology, New York University, New York, NY, USA
[6] Clinical Imaging Diagnostics Center, 5th Military Hospital with Polyclinic in Krakow, 30-901 Krakow, Poland
[7] Department of Anatomy, Jagiellonian University Medical College, 31-008 Krakow, Poland
[8] Department of Diagnostic Imaging, Faculty of Medicine, Andrzej Frycz Modrzewski Krakow University, 30-705 Krakow, Poland
[9] New York University Grossman School of Medicine, New York, NY, USA
[10] Department of Neurology, New York University Grossman School of Medicine, New York, NY, USA
* Equal Contribution

Corresponding Author: Yiqiu Shen, 227 East 30th Street 745, New York, NY, 10016, Telephone: 832-693-4010, Email: Yiqiu.Shen@nyulangone.org

NOTE: This preprint reports new research that has not been certified by peer review and should not be used to guide clinical practice.

medRxiv preprint doi: https://doi.org/10.64898/2026.03.04.26347460; this version posted March 10, 2026. The copyright holder for this preprint (which was not certified by peer review) is the author/funder, who has granted medRxiv a license to display the preprint in perpetuity. It is made available under a CC-BY-NC 4.0 International license .

Abstract

Background: Current diagnostic criteria for multiple sclerosis (MS) rely on white matter lesions (WMLs), which are not specific and often occur in other disorders. Microstructural abnormalities in normal-appearing white matter (NAWM) may provide complementary information beyond focal lesions. However, the diagnostic use of NAWM in MS remains limited because a reproducible, diagnostically specific NAWM signature has not been established, and NAWM abnormalities detection typically requires quantitative MRI methods beyond routine clinical MRI protocols.

Methods: In this retrospective study, we proposed DeepMS, a deep learning model trained with both quantitative diffusion MRI (dMRI) and structural MRI (sMRI) to diagnose MS by integrating WML and NAWM features captured from routine MRI alone. Development utilized 8,450 scans from 7,703 patients (NYU Langone/ADNI). Evaluation included an internal test set (n=837) and two independent external cohorts: the Krakow cohort (Poland, n=293) and a public multi-site cohort curated from 15 datasets (n=1,756). We compared DeepMS against 2024 McDonald criteria biomarkers (Dissemination in Time [DIT], Dissemination in Space [DIS], Central Vein Sign [CVS], and Paramagnetic Rim Lesion [PRL]) in a multireader study (n=308). To validate the model's use of NAWM, we performed lesion-masking experiments (n=550), comparing performance after removal of focal lesions.

Findings: DeepMS achieved robust AUCs in the internal (0·968 [95% CI 0·946–0·987]), Krakow (0·940 [0·898–0·974]), and public external (0·974 [0·966–0·982]) cohorts. In the multireader study, DeepMS outperformed established biomarkers: at matched sensitivity (92·9%),

medRxiv preprint doi: https://doi.org/10.64898/2026.03.04.26347460; this version posted March 10, 2026. The copyright holder for this preprint (which was not certified by peer review) is the author/funder, who has granted medRxiv a license to display the preprint in perpetuity. It is made available under a CC-BY-NC 4.0 International license .

DeepMS achieved higher specificity than DIS (89·0% vs 78·5%; p=0·0061); at matched specificity (92·8%), DeepMS achieved higher sensitivity than CVS (88·2% vs 52·0%; p<0·0001). Furthermore, DeepMS retained diagnostic capability after WML masking (AUC 0·959 to 0·881) compared to the model trained with only sMRI (0·895 to 0·764).

Interpretation: Our findings suggest it is feasible for deep learning models to leverage NAWM-related information directly from routine sMRI. Integrating these features could help MS diagnosis in patients with ambiguous white matter abnormalities.

Funding: National Institute of Neurological Disorders and Stroke, the National Institute of Biomedical Imaging and Bioengineering, and the Irma T. Hirschl Trust.

medRxiv preprint doi: https://doi.org/10.64898/2026.03.04.26347460; this version posted March 10, 2026. The copyright holder for this preprint (which was not certified by peer review) is the author/funder, who has granted medRxiv a license to display the preprint in perpetuity. It is made available under a CC-BY-NC 4.0 International license .

Introduction

Multiple sclerosis (MS) affects over 2·8 million people worldwide and is a leading cause of non-traumatic neurological disability in young adults.[1] Accurate diagnosis is crucial for the appropriate initiation of disease-modifying therapies.[2] Current diagnostic frameworks rely heavily on MRI biomarkers derived from white-matter lesions (WMLs).[3] However, other neurological disorders, such as cerebral small vessel disease, migraine, and other inflammatory demyelinating disorders, manifest with radiologically similar WMLs.[4] Consequently, about 10-20% of patients referred for an MS diagnosis have alternative conditions,[5,6] leading to inappropriate management and unnecessary patient anxiety.[4–6]

To improve diagnostic accuracy, the 2024 revisions of the McDonald Criteria incorporated lesion-specific biomarkers, such as the central vein sign (CVS) and paramagnetic rim lesion (PRL), alongside established dissemination in space and time (DIS/DIT).[3] However, these biomarkers have trade-offs: DIS/DIT is sensitive but often lacks specificity,[7] particularly when incidental WMLs coexist;[8] conversely, CVS[9] and PRL[10] improve specificity but have low sensitivity in routine clinical settings. Even with these advances, current diagnostic methods remain lesion-centric, overlooking the diffuse microstructural injury within the normal-appearing white matter (NAWM), another key feature of MS pathology.[11]

NAWM contains clinically relevant pathology (eg, partial demyelination, axonal loss, and microglial activation)[12] and has been linked to subsequent lesion development[13] and disability.[14] Emerging evidence also suggests that NAWM-derived measures may help differentiate MS from mimics such as cerebral small vessel disease[15] and neuromyelitis optica spectrum disorder

medRxiv preprint doi: https://doi.org/10.64898/2026.03.04.26347460; this version posted March 10, 2026. The copyright holder for this preprint (which was not certified by peer review) is the author/funder, who has granted medRxiv a license to display the preprint in perpetuity. It is made available under a CC-BY-NC 4.0 International license .

(NMOSD).[16] However, NAWM abnormalities are not routinely leveraged for MS differential diagnosis in clinical practice[3] due to two challenges: first, a MS-specific NAWM signature has not yet been established; and second, the detection of NAWM abnormalities typically requires quantitative MRI maps derived from specialized acquisitions (eg, multi-shell diffusion MRI [dMRI]), neither of which is part of routine clinical workflows.

Deep learning offers an opportunity to leverage this underused source of potential diagnostic information by detecting subtle NAWM-related patterns on routine structural MRI (sMRI) that may evade visual assessment. Although recent AI studies have explored MS diagnosis, most are limited by small single-centre cohorts,[17–19] a lack of clinically relevant mimics,[18–20] insufficient benchmarking against established MRI biomarkers,[17–20] and unclear utilization of NAWM information.[17–20] In this study, we aimed to overcome these limitations by developing DeepMS, a deep learning system trained on a large multimodal dataset that included quantitative maps derived from multi-shell dMRI, which can capture NAWM microstructural injury by detecting alterations in microscopic water displacement.[15] We hypothesized that training a unified feature extractor on paired sMRI and dMRI would enable DeepMS to learn NAWM-related diagnostic signatures from dMRI and capture their subtle correlates in routine sMRI. Consequently, in everyday clinical practice, the system could integrate both focal WML-related cues with diffuse NAWM-associated signals from sMRI alone, thereby improving diagnostic accuracy.

Method

Study design

medRxiv preprint doi: https://doi.org/10.64898/2026.03.04.26347460; this version posted March 10, 2026. The copyright holder for this preprint (which was not certified by peer review) is the author/funder, who has granted medRxiv a license to display the preprint in perpetuity. It is made available under a CC-BY-NC 4.0 International license .

This HIPAA-compliant retrospective study aimed to develop and validate a deep learning model for diagnosing MS from routine sMRI. Figure 1 provides an overview of the study workflow. The protocol was approved by the Institutional Review Board of NYU Grossman School of Medicine (IRB i14-01224, i25-01143), and the requirement for informed consent was waived. All analyses complied with the principles of the Declaration of Helsinki and were reported in accordance with the STARD 2015 guideline.[21]

Study Population and Datasets

A cohort flowchart is provided in Figure 2. We retrospectively identified a consecutive cohort of clinically indicated brain MRI examinations acquired at NYU Langone Health outpatient imaging centers (2014-2020). Eligible examinations were required to include single-/multi-shell dMRI and routine sMRI sequences as part of the clinical brain MRI protocol, yielding 7,493 studies from 6,825 patients. MS status was ascertained from the clinical record, based on diagnoses made by treating board-certified neurologists, according to standard diagnostic criteria.[22,23] We defined early MS as symptom onset ≤3 years before the index MRI (appendix p 16). The internal dataset was split at the patient level into internal training, validation, and test sets. To increase diversity, training data were augmented with non-MS participants from the Alzheimer's Disease Neuroimaging Initiative (ADNI).[24]

For external validation, we included an independent cohort from the Clinical Imaging Diagnostics Center of the 5th Military Hospital with Polyclinic in Krakow (Krakow, Poland; 2020–2025). Inclusion criteria required complete 3D FLAIR, 3D T1-w, and 3D T1-CE sequences. MS diagnoses were established by neurologists according to the 2017 McDonald criteria.[22]

medRxiv preprint doi: https://doi.org/10.64898/2026.03.04.26347460; this version posted March 10, 2026. The copyright holder for this preprint (which was not certified by peer review) is the author/funder, who has granted medRxiv a license to display the preprint in perpetuity. It is made available under a CC-BY-NC 4.0 International license .

We further curated a cohort of 1,756 individuals from 15 publicly available datasets, covering healthy controls (MPI-Leipzig), patients with MS (MSSEG-2016, MSSEG-2, OpenMS-Long, OpenMS-Cross, MS-ISBI, PediMS, QSM-MS), and diverse non-MS neurological conditions, including demyelinating disease (PediDemi), vascular WMH (WMH, MRBrainS18), stroke (ISLES-2022), tumours (UCSF-PDGM, MetsToBrain), and epilepsy (OpenNeuro Epilepsy). These datasets were acquired across 13 international sites, and diagnosis labels were obtained from the original dataset releases. Detailed cohort characteristics and citation are provided in the appendix (pp 2-3, 34-36).

Uniform exclusion criteria were applied across all datasets, removing cases with clinically isolated syndrome (CIS) or radiologically isolated syndrome (RIS) without confirmed MS conversion, inadequate image quality, or missing FLAIR sequences. When two or more scans were available for the same patient, only the earliest scan was retained. Cohort characteristics and exclusion flow are detailed in Table 1 and the appendix (p 21).

MRI acquisition and preprocessing

In the NYU Langone Health cohort, imaging was performed during routine clinical care on 3T Siemens Magnetom Prisma or Skyra scanners. sMRI protocols included heterogeneous 2D and 3D acquisitions, comprising T1-weighted (T1-w), contrast-enhanced T1-weighted (T1-CE), and fluid-attenuated inversion recovery (FLAIR). Susceptibility-weighted imaging (SWI) was acquired and used for the reader study to assess the CVS and PRL. dMRI analyses were restricted to multi-shell acquisitions obtained by a standard single-shot EPI protocol[25]. In the Krakow external cohort, only sMRI was used and was acquired on a 1·5 T GE SIGNA Artist system, including complete 3D T1-w, 3D T1-CE, and 3D FLAIR sequences. The public external

medRxiv preprint doi: https://doi.org/10.64898/2026.03.04.26347460; this version posted March 10, 2026. The copyright holder for this preprint (which was not certified by peer review) is the author/funder, who has granted medRxiv a license to display the preprint in perpetuity. It is made available under a CC-BY-NC 4.0 International license .

cohort was restricted to sMRI and used heterogeneous protocols across vendors (Siemens, GE, Philips) and field strengths (predominantly 1·5–3 T). Detailed sequence parameters for all cohorts are provided in the appendix (pp 4, 37-39).

All available raw sMRI data were processed using a pipeline comprising bias-field correction, within-subject co-registration across sequences, skull stripping, and affine registration to MNI space. For dMRI, we employed the DESIGNER-v2 pipeline[25] for denoising and artefact correction before estimating diffusion tensor (DTI),[26] kurtosis (DKI),[27] and standard model (SMI) imaging metrics.[28] Final model inputs were background-cropped, resized to 128 × 128 × 128 voxels, and scaled to the [0, 1] interval. Detailed algorithmic steps and software specifications are provided in the appendix (pp 5-7, 22-23).

Model development

We developed DeepMS, a deep learning framework that predicts patient-level MS probability from at least one sMRI sequence acquired during a single imaging visit. dMRI maps were used for training when available, but are not required for deployment. The model uses a Swin-UNETR[29] feature extractor and an attention-based multiple-instance learning (ABMIL) predictor,[30] with all parameters shared across MRI modalities. Each forward pass processes a single-modality 3D brain MRI volume (eg, T1-w, T1-CE, FLAIR, or a dMRI map) and outputs a sequence-level MS logit.

As shown in Figure 1A, DeepMS was trained with both quantitative dMRI and sMRI to improve sensitivity to NAWM abnormalities, which are often subtle on routine sMRI. In the internal cohort, dMRI and sMRI were acquired during the same imaging session and were preprocessed

medRxiv preprint doi: https://doi.org/10.64898/2026.03.04.26347460; this version posted March 10, 2026. The copyright holder for this preprint (which was not certified by peer review) is the author/funder, who has granted medRxiv a license to display the preprint in perpetuity. It is made available under a CC-BY-NC 4.0 International license .

to achieve approximate anatomical correspondence. During training, each MRI sequence was treated as a separate input but passed through a unified, parameter-shared image encoder and supervised using the same patient-level diagnostic labels. Through this shared parameter optimization, the model is encouraged to learn representations that are generalizable across modalities, enabling it to leverage patterns learned from dMRI to identify corresponding subtle changes in sMRI.

At inference (Figure 1B), DeepMS operates on routine sMRI alone: the model is applied independently to each available sMRI sequence to generate sequence-level logits, which are then hierarchically aggregated to yield a single patient-level MS probability.

For interpretability, we generated 3D prediction heatmaps by applying the final linear layer to voxel-wise features before global aggregation, producing spatial attribution maps intrinsically linked to the model's prediction. Implementation details, including architecture, loss functions, hyperparameters, data augmentation, and interpretation analysis, are provided in the appendix (pp 7–15, 23-25, 40).

Reader study

To compare DeepMS with established MRI biomarkers, we conducted a reader study involving three board-certified neuroradiologists from NYU Langone Health (1-4 years post-fellowship experience; Figure 1C) on a subset of the internal test cohort (n=308; 127 MS, 181 non-MS). Inclusion required visible WMLs on 3D FLAIR, plus available SWI and a prior MRI (Figure 2). Scans were partitioned into three non-overlapping batches (93–109 each) and evaluated

medRxiv preprint doi: https://doi.org/10.64898/2026.03.04.26347460; this version posted March 10, 2026. The copyright holder for this preprint (which was not certified by peer review) is the author/funder, who has granted medRxiv a license to display the preprint in perpetuity. It is made available under a CC-BY-NC 4.0 International license .

independently by blinded readers (age/sex provided). Following the 2024 McDonald criteria,[3] each reader assessed four MRI biomarkers: DIS, DIT, CVS (select-6 approach), and PRL.

Based on the McDonald criteria,[3] we defined a composite biomarker to integrate these four biomarkers. A case was classified as MS-positive if any condition was met: 1. DIS + DIT; 2. DIS + CVS; 3. DIS, with four characteristic regions involved (periventricular, juxtacortical, infratentorial, and spinal cord; dedicated orbital imaging was not available); or 4. PRL + DIT, with ≥1 characteristic region involved. All remaining cases were classified as MS-negative. Finally, to integrate model prediction and established biomarkers, we defined a hybrid approach requiring both a positive DeepMS prediction and ≥1 positive cross-sectional biomarker (DIS, CVS, or PRL).

External generalisability and lesion-masking analyses

As shown in Figure 1D, we performed two analyses to evaluate the impact of incorporating dMRI during training. As T1-w and T1-CE sequences were not consistently available across public external datasets, we standardised evaluation to FLAIR-only inference. First, to assess generalisability, we compared external performance between models trained with and without dMRI. Second, to evaluate whether the model leveraged information from NAWM beyond WMLs, we conducted a lesion-masking experiment by comparing model performance on original versus digitally lesion-removed scans on a public external cohort subset with available WML masks (7 public datasets; n=550 [89 MS, 461 non-MS]). Lesion masks were dilated by three voxels (SciPy) and zeroed (ANTsPy) to remove visible lesion-related signal, with effectiveness confirmed by inspecting post-masking activations (appendix p 26).

medRxiv preprint doi: https://doi.org/10.64898/2026.03.04.26347460; this version posted March 10, 2026. The copyright holder for this preprint (which was not certified by peer review) is the author/funder, who has granted medRxiv a license to display the preprint in perpetuity. It is made available under a CC-BY-NC 4.0 International license .

Quantitative and Statistical analysis

The primary performance metric was the area under the receiver operating characteristic curve (ROC-AUC). Secondary metrics were sensitivity and specificity, calculated at a decision threshold of 0·5 after calibration on the validation set (unless otherwise specified). Performance comparisons utilized DeLong's test for ROC-AUC and McNemar's test for paired sensitivity/specificity. In the reader study, DeepMS was further evaluated at operating points matched to the reference biomarkers: for DIS, we matched sensitivity to compare specificity; for CVS and the composite biomarker, we matched specificity to compare sensitivity. All tests were two-sided, with $p<0·05$ considered statistically significant. Performance metrics were reported with 95% confidence intervals (CIs) estimated using 2,000 bootstrap resamples. Analyses were conducted in Python 3·11 (scikit-learn, SciPy).

Results

A total of 11,336 brain MRI scans from 10,589 patients were included in the analysis (appendix p 21). The training set comprised 6,261 scans from 5,645 internal patients (806 [14·3%] MS; 4,839 [85·7%] non-MS) and 1,857 scans from 1,737 ADNI participants (all non-MS). The validation set included 332 scans from 321 patients (137 [42·7%] MS; 184 [57·3%] non-MS). The internal test set included 837 patients (138 [16·5%] MS; 699 [83·5%] non-MS; mean age 46·4 years [SD 17·1]; 837 scans). Notably, 450 (64·4%) of the 699 non-MS patients presented with WMLs, primarily due to cerebral vascular disease (n=155), non-specific WMLs (n=108), other inflammatory demyelinating disorders (n=16), and other neurological diseases (n=171).

medRxiv preprint doi: https://doi.org/10.64898/2026.03.04.26347460; this version posted March 10, 2026. The copyright holder for this preprint (which was not certified by peer review) is the author/funder, who has granted medRxiv a license to display the preprint in perpetuity. It is made available under a CC-BY-NC 4.0 International license .

The Krakow external cohort comprised 293 patients (63 [21·5%] MS; 230 [78·5%] non-MS; mean age 45·3 years [SD 17·8]; 293 scans). Among non-MS patients, 113 (49·1%) presented with WMLs, primarily including cerebral vascular disease (n=71), non-specific WMLs (n=10), or other inflammatory demyelinating disorders (n=13).

The public external cohort comprised 1,756 patients (263 [15·0%] MS; 1,493 [85·0%] non-MS; mean age 52·7 years [SD 23·1; n=1,686]; 1,756 scans). Among non-MS patients, 461 (30·9%) presented with confirmed WMLs, attributable primarily to cerebral vascular disease (n=450; 30·1%) or other inflammatory demyelinating disorders (n=11; 0·7%). Detailed demographics and imaging characteristics are provided in Table 1 and the appendix (pp 34-36).

In the internal test cohort (n=837; Figure 2A; Table 2), DeepMS achieved an ROC–AUC of 0·968 (95% CI 0·947–0·987), and 0·964 (0·941–0·984) in the WML subgroup (n=464). In the Krakow external cohort (n=293; Figure 2B; Table 2), DeepMS achieved an ROC–AUC of 0·940 (0·898–0·974), and 0·940 (0·901–0·972) in the WML subgroup (n=176). In the public external cohort (n=1,756; Figure 2C; Table 2), DeepMS maintained performance with an ROC–AUC of 0·974 (0·966–0·982), and 0·971 (0·962–0·980) in the WML subgroup (n=724). Sensitivity and specificity at the prespecified operating point are summarised in Table 2. Dataset-specific performance for the public external cohort is provided in the appendix (p 41).

In the multi-reader study (n=308; Figure 2D), DeepMS achieved an ROC–AUC of 0·971 (95% CI 0·951–0·987), with sensitivity 96·1% (92·4–99·1) and specificity 88·4% (83·7–93·0) in the overall population (Table 2), and a sensitivity of 96·3% (87·9–100·0) in the early MS subgroup (≤3 years; n=27; appendix pp 16, 27). In comparison, lesion-centric biomarkers showed variable trade-offs between sensitivity and specificity: DIS 92·9% (87·8–97·0) and 78·5% (72·0–84·8);

medRxiv preprint doi: https://doi.org/10.64898/2026.03.04.26347460; this version posted March 10, 2026. The copyright holder for this preprint (which was not certified by peer review) is the author/funder, who has granted medRxiv a license to display the preprint in perpetuity. It is made available under a CC-BY-NC 4.0 International license .

DIT 48·8% (40·5–57·2) and 92·3% (88·1–95·6); CVS 52·0% (42·8–60·3) and 92·8% (88·7–96·4); PRL 29·1% (20·9–37·2) and 98·3% (96·3–100·0); and the composite biomarker 74·8% (66·9–82·4) and 92·3% (88·3–95·9) (Table 2). At matched operating points, DeepMS achieved a higher specificity than DIS (89·0% [84·4–93·4] vs 78·5% [72·0–84·8]; p=0·0061) while matching sensitivity, and a higher sensitivity than CVS (88·2% [82·1–93·1] vs 52·0% [42·8–60·3], p<0·0001) and composite biomarker (90·6% [85·0–95·3] vs 74·8% [66·9–82·4], p=0·0011) while matching specificity. The hybrid approach that combines DeepMS and lesional biomarkers achieved a sensitivity of 92·1% (87·2–96·8) and a specificity of 96·1% (93·2–98·9), more specific compared with the standalone DeepMS model (p=0·0005). In early MS (≤3 years; n=27), DeepMS alone detected 26/27 cases, and the hybrid approach detected 25/27, comparable to DIS (24/27) but outperforming the composite biomarker (17/27; p=0·0077); case-level comparisons are shown in the appendix (pp 16, 27).

Ablation studies confirmed that training with both dMRI and sMRI improved generalisability compared with training using sMRI only (appendix p 28 A-C). This advantage was significant internally, where ROC-AUC improved from 0·946 (95% CI 0·918–0·971) to 0·963 (0·939–0·983) in the internal test cohort (DeLong's test p=0·025), and externally, where ROC-AUCs improved from 0·848 (0·785–0·901) to 0·944 (0·905–0·977) in the Krakow cohort (p=0·0007) and from 0·918 (0·898–0·936) to 0·971 (0·961–0·979) in the public external cohort (p<0·0001). Findings were consistent when using all available sMRI sequences at inference in the external cohorts (appendix p 28 D-F)

In the lesion-masking experiment (Figure 2E, F), sMRI-only trained models suffered substantial performance drops after lesion masking (FLAIR-only: ROC-AUC 0·840 [95% CI 0·780–0·892]

medRxiv preprint doi: https://doi.org/10.64898/2026.03.04.26347460; this version posted March 10, 2026. The copyright holder for this preprint (which was not certified by peer review) is the author/funder, who has granted medRxiv a license to display the preprint in perpetuity. It is made available under a CC-BY-NC 4.0 International license .

to 0·552 [0·478–0·624], ΔAUC: −0·288; FLAIR + T1: ROC-AUC 0·895 [0·863–0·923] to 0·764 [0·715–0·809], ΔAUC −0·131). In contrast, the model trained with both sMRI and dMRI demonstrated robustness (AUC 0·959 [0·940–0·974] to 0·881 [0·846–0·911]; ΔAUC −0·078). Consistently, in MS cases, the model trained with both dMRI and sMRI showed a strong association between lesion burden and lesion/perilesional activation (Spearman's r=0·800; p<0·0001), but no evidence of association between lesion burden and NAWM activation (r=0·056; p=0·5929; appendix pp 20, 29).

In the interpretability analysis, we visualised prediction heatmaps to compare spatial contribution patterns between the models trained with sMRI-only and both dMRI and sMRI in representative clinical scenarios (Figure 3). In a typical MS case (Figure 3A), the sMRI-only model showed predominantly lesion-centred positive signal, whereas the model trained with both sMRI and dMRI extended positive signal into NAWM. In an MS-mimic case that was clinically misdiagnosed as MS with DIS-positive (Figure 3B), the sMRI-only model produced a false-positive prediction, whereas the model trained with both sMRI and dMRI remained true negative and was not falsely activated by MS-typical lesion morphology. Failure cases were also observed, including a false-negative prediction in an MS case meeting DIS criteria (Figure 3C).

As a complementary analysis, we visualised heatmaps before and after lesion masking in representative cases (appendix p 30). Across examples, the model trained with both dMRI and sMRI maintained qualitatively similar NAWM activation patterns and stable predictions after lesion masking. In contrast, the sMRI-only model showed greater attenuation or spatial redistribution of the heatmap signal and more widespread sign reversals after masking.

medRxiv preprint doi: https://doi.org/10.64898/2026.03.04.26347460; this version posted March 10, 2026. The copyright holder for this preprint (which was not certified by peer review) is the author/funder, who has granted medRxiv a license to display the preprint in perpetuity. It is made available under a CC-BY-NC 4.0 International license .

Discussion

In this study, we present DeepMS, a 3D deep learning model for MS diagnosis, which was trained with quantitative maps from multi-shell dMRI to learn NAWM patterns and requires only routine sMRI for point-of-care inference. Across both internal and independent external test cohorts, DeepMS achieved robust performance, including in patients with non-MS WMLs, who represent a group at risk for misdiagnosis. In a multireader study, DeepMS mitigated the sensitivity–specificity trade-offs inherent to established biomarkers, integrating the high sensitivity of DIS with the high specificity of CVS. Furthermore, preliminary analyses indicate a synergistic effect when DeepMS is combined with these lesion-centric biomarkers.

Compared with previous AI studies, DeepMS offers advantages in generalisability. While earlier studies have reported encouraging performance, they often lack external validation[17–19] and are framed as simplified tasks: distinguishing MS from healthy controls[19] or from a single mimicking condition[18,20] (appendix pp 44-45). In contrast, our institutional cohorts represent real-world patients referred for routine clinical evaluation, encompassing a broad spectrum of MS mimics (eg, small-vessel disease, migraine, and other demyelinating disorders) rather than a single predefined comparator. We further assessed DeepMS across heterogeneous external populations, including the Krakow cohort with a distinct acquisition protocol and 15 public datasets from institutions worldwide (appendix pp 2-3).

DeepMS addresses the limitations of current lesion-centric biomarkers by effectively bridging the gap between sensitivity and specificity. Established biomarkers often face a trade-off: DIS offers high sensitivity but is prone to false positives in patients with non-specific WMLs,[7,22]

medRxiv preprint doi: https://doi.org/10.64898/2026.03.04.26347460; this version posted March 10, 2026. The copyright holder for this preprint (which was not certified by peer review) is the author/funder, who has granted medRxiv a license to display the preprint in perpetuity. It is made available under a CC-BY-NC 4.0 International license .

whereas CVS and PRL provide high specificity but lower sensitivity.[3,9] Our head-to-head comparison shows that DeepMS breaks this compromise: it matches the high sensitivity of DIS while achieving significantly improved specificity, reducing the risk of misdiagnosis. Furthermore, unlike CVS and PRL, which require susceptibility-weighted imaging and visual interpretation dependent on experience and pulse sequence parameters,[3] DeepMS operates automatically on routine sMRI.

Our findings suggest that NAWM harbors a rich, under-utilized diagnostic signal for MS. Although quantitative MRI studies, including diffusion MRI and other quantitative contrasts (eg, magnetization transfer, myelin water imaging, and QSM), have long reported NAWM alterations[11,13,16] in MS patients, these insights have not previously translated into diagnostic tools.[3] Our lesion-masking experiments demonstrate that DeepMS retains high diagnostic accuracy (ROC-AUC 0·881) even after all visible lesions are digitally removed. Moreover, NAWM activation showed no evidence of association with lesion burden (appendix p 28), suggesting that the NAWM signal leveraged by DeepMS is not merely a byproduct of lesion load. These results indicate that diffuse microstructural abnormalities in NAWM contain untapped value to differentiate MS from common mimics.

The ability of DeepMS to maintain diagnostic performance independently of visible lesions offers a plausible explanation for the synergistic improvements observed when it is combined with established biomarkers[14]. A hybrid approach combining DeepMS with lesional biomarkers achieved superior performance (sensitivity 92·1%; specificity 96·1%) compared with the composite lesional biomarker rule alone (sensitivity 74·8%; specificity 92·3%). This synergy likely reflects the integration of distinct diagnostic information: whereas existing biomarkers rely

medRxiv preprint doi: https://doi.org/10.64898/2026.03.04.26347460; this version posted March 10, 2026. The copyright holder for this preprint (which was not certified by peer review) is the author/funder, who has granted medRxiv a license to display the preprint in perpetuity. It is made available under a CC-BY-NC 4.0 International license .

on lesion characteristics,[5,6] DeepMS captures abnormalities in NAWM. These results suggest that strategies combining lesional markers with NAWM-based information may improve MS diagnosis and merit further clinical evaluation.

Our study has several limitations. First, as a retrospective analysis, it does not evaluate the impact of DeepMS on real-world clinical decision-making or patient outcomes. Future prospective studies are needed to determine whether deployment reduces misdiagnosis. Second, the limited number of participants with other inflammatory demyelinating disorders (eg, NMOSD, MOGAD, and ADEM; n=16 internal, 13 Krakow, 11 public external) resulted in imprecise specificity estimates for this subgroup; thus, validation in larger dedicated cohorts is required. Third, although subgroup analyses showed preserved performance in patients with early MS (appendix pp 16, 27), generalisability to patients at initial clinical presentation or those with RIS warrants further validation. Finally, although training with additional dMRI enables the model to leverage NAWM-related signals on sMRI and improves external generalizability, our study was not designed to fully characterize the NAWM-related information learned by the model. Future work should establish reproducible, biologically validated quantitative NAWM biomarkers and test whether integrating additional quantitative MRI contrasts further improves performance.

In conclusion, this study demonstrates that deep learning models, when incorporating quantitative dMRI during training, can accurately distinguish MS from mimics using only routine sMRI. By establishing that robust discriminatory information persists even after the removal of focal lesions, our findings support NAWM as a rich, under-utilized diagnostic resource. These results point to a promising direction for future research: integrating

medRxiv preprint doi: https://doi.org/10.64898/2026.03.04.26347460; this version posted March 10, 2026. The copyright holder for this preprint (which was not certified by peer review) is the author/funder, who has granted medRxiv a license to display the preprint in perpetuity. It is made available under a CC-BY-NC 4.0 International license .

conventional lesion biomarkers with AI-derived assessments of diffuse microstructural pathology. Ultimately, this approach offers a scalable pathway to reduce diagnostic uncertainty, enhancing specificity in routine clinical practice without requiring specialized imaging protocols.

Data sharing

The complete source code for model development, training, validation, and structural MRI (sMRI) preprocessing is publicly available at **https://github.com/nyu-shenlab/DeepMS**. The diffusion MRI (dMRI) preprocessing pipeline is available at **https://github.com/NYU-DiffusionMRI/DESIGNER-v2**. Access links to all external public datasets used in this study are documented within the DeepMS repository.

The internal clinical datasets and trained model weights are not publicly available due to patient privacy protections and institutional regulations. Any data access requests are subject to review and approval by the NYU Langone Health Institutional Review Board and require a formal Data Use Agreement.

Declaration of interests

We declare no competing interests.

Acknowledgments

This work was supported by the National Institute of Neurological Disorders and Stroke of the NIH under award R01 NS088040, National Institute of Biomedical Imaging and Bioengineering

medRxiv preprint doi: https://doi.org/10.64898/2026.03.04.26347460; this version posted March 10, 2026. The copyright holder for this preprint (which was not certified by peer review) is the author/funder, who has granted medRxiv a license to display the preprint in perpetuity. It is made available under a CC-BY-NC 4.0 International license .

of the NIH under award number R01 EB027075 and 1R01EB036530-01A1, Irma T. Hirschl Foundation, and was performed at the Center of Advanced Imaging Innovation and Research (CAI2R, www.cai2r.net), and NIBIB Biomedical Technology Resource Center (NIH P41 EB017183).

Declaration of generative AI usage

During the preparation of this work, the author(s) used ChatGPT and Gemini to improve readability and language clarity. After using this tool/service, the author(s) reviewed and edited the content as needed and take(s) full responsibility for the content of the published article.

Reference

1 Walton C, King R, Rechtman L, *et al*. Rising prevalence of multiple sclerosis worldwide: Insights from the Atlas of MS, third edition. *Mult Scler* 2020; **26**: 1816–21.

2 Brown JWL, Coles A, Horakova D, *et al.* Association of initial disease-modifying therapy with later conversion to secondary progressive multiple sclerosis. *JAMA* 2019; **321**: 175–87.

3 Montalban X, Lebrun-Frénay C, Oh J, *et al*. Diagnosis of multiple sclerosis: 2024 revisions of the McDonald criteria. *Lancet Neurol* 2025; **24**: 850–65.

4 Solomon AJ, Bourdette DN, Cross AH, *et al*. The contemporary spectrum of multiple sclerosis misdiagnosis: A multicenter study: A multicenter study. *Neurology* 2016; **87**: 1393–9.

5 Kaisey M, Solomon AJ, Luu M, Giesser BS, Sicotte NL. Incidence of multiple sclerosis misdiagnosis in referrals to two academic centers. *Mult Scler Relat Disord* 2019; **30**: 51–6.

6 Midaglia L, Sastre-Garriga J, Pappolla A, *et al*. The frequency and characteristics of MS misdiagnosis in patients referred to the multiple sclerosis centre of Catalonia. *Mult Scler* 2021; **27**: 913–21.

7 Bsteh G, Hegen H, Altmann P, *et al*. Diagnostic performance of adding the optic nerve region assessed by optical coherence tomography to the diagnostic criteria for multiple sclerosis. *Neurology* 2023; **101**: e784–93.

medRxiv preprint doi: https://doi.org/10.64898/2026.03.04.26347460; this version posted March 10, 2026. The copyright holder for this preprint (which was not certified by peer review) is the author/funder, who has granted medRxiv a license to display the preprint in perpetuity. It is made available under a CC-BY-NC 4.0 International license .

8 Liu S, Kullnat J, Bourdette D, *et al.* Prevalence of brain magnetic resonance imaging meeting Barkhof and McDonald criteria for dissemination in space among headache patients. *Mult Scler* 2013; **19**: 1101–5.

9 Cagol A, Cortese R, Barakovic M, *et al.* Diagnostic performance of cortical lesions and the central vein sign in multiple sclerosis. *JAMA Neurol* 2024; **81**: 143–53.

10 Hemond CC, Dundamadappa SK, Deshpande M, *et al.* Paramagnetic rim lesions are highly specific for multiple sclerosis in real-world data. *Brain Commun* 2025; **7**: fcaf211.

11 Moll NM, Rietsch AM, Thomas S, *et al.* Multiple sclerosis normal-appearing white matter: pathology-imaging correlations. *Ann Neurol* 2011; **70**: 764–73.

12 Rahmanzadeh R, Lu P-J, Barakovic M, *et al.* Myelin and axon pathology in multiple sclerosis assessed by myelin water and multi-shell diffusion imaging. *Brain* 2021; **144**: 1684–96.

13 Elliott C, Momayyezsiahkal P, Arnold DL, *et al.* Abnormalities in normal-appearing white matter from which multiple sclerosis lesions arise. *Brain Commun* 2021; **3**: fcab176.

14 Stepanov VN, Coelho S, Ades-Aron B, *et al.* Normal appearing white matter and disability in multiple sclerosis. medRxiv. 2025; published online Nov 9. DOI:10.1101/2025.11.07.25339773.

15 Zhuo Z, Xu X, Tian D, *et al.* Periventricular gradient of normal-appearing white matter in normal aging and multiple neurological diseases. *J Adv Res* 2025; published online Sept 24. DOI:10.1016/j.jare.2025.08.059.

16 Chen X, Roberts N, Zheng Q, *et al.* Comparison of diffusion tensor imaging (DTI) tissue characterization parameters in white matter tracts of patients with multiple sclerosis (MS) and neuromyelitis optica spectrum disorder (NMOSD). *Eur Radiol* 2024; **34**: 5263–75.

17 Rocca MA, Anzalone N, Storelli L, *et al.* Deep learning on conventional magnetic resonance imaging improves the diagnosis of multiple sclerosis mimics. *Invest Radiol* 2021; **56**: 252–60.

18 Amin M, Nakamura K, Ontaneda D. Differentiating multiple sclerosis from non-specific white matter changes using a convolutional neural network image classification model. *Mult Scler Relat Disord* 2024; **82**: 105420.

19 Eitel F, Soehler E, Bellmann-Strobl J, *et al.* Uncovering convolutional neural network decisions for diagnosing multiple sclerosis on conventional MRI using layer-wise relevance propagation. *NeuroImage Clin* 2019; **24**: 102003.

20 Cortese R, Sforazzini F, Gentile G, *et al.* Deep learning modeling to differentiate multiple sclerosis from MOG antibody-associated disease. *Neurology* 2025; **105**: e214075.

medRxiv preprint doi: https://doi.org/10.64898/2026.03.04.26347460; this version posted March 10, 2026. The copyright holder for this preprint (which was not certified by peer review) is the author/funder, who has granted medRxiv a license to display the preprint in perpetuity. It is made available under a CC-BY-NC 4.0 International license .

21 Cohen JF, Korevaar DA, Altman DG, *et al.* STARD 2015 guidelines for reporting diagnostic accuracy studies: explanation and elaboration. *BMJ Open* 2016; **6**: e012799.

22 Thompson AJ, Banwell BL, Barkhof F, *et al.* Diagnosis of multiple sclerosis: 2017 revisions of the McDonald criteria. *Lancet Neurol* 2018; **17**: 162–73.

23 Polman CH, Reingold SC, Banwell B, *et al.* Diagnostic criteria for multiple sclerosis: 2010 revisions to the McDonald criteria. *Ann Neurol* 2011; **69**: 292–302.

24 Jack CR Jr, Bernstein MA, Fox NC, *et al.* The Alzheimer's Disease Neuroimaging Initiative (ADNI): MRI methods. *J Magn Reson Imaging* 2008; **27**: 685–91.

25 Chen J, Ades-Aron B, Lee H-H, *et al.* Optimization and validation of the DESIGNER preprocessing pipeline for clinical diffusion MRI in white matter aging. *Imaging Neurosci (Camb)* 2024; **2**. DOI:10.1162/imag_a_00125.

26 Le Bihan D, Mangin JF, Poupon C, *et al.* Diffusion tensor imaging: concepts and applications. *J Magn Reson Imaging* 2001; **13**: 534–46.

27 Jensen JH, Helpern JA. MRI quantification of non-Gaussian water diffusion by kurtosis analysis. *NMR Biomed* 2010; **23**: 698–710.

28 Coelho S, Baete SH, Lemberskiy G, *et al.* Reproducibility of the Standard Model of diffusion in white matter on clinical MRI systems. *Neuroimage* 2022; **257**: 119290.

29 Wu L, Zhuang J, Chen H. Large-scale 3D medical image pre-training with geometric context priors. arXiv [cs.CV]. 2024; published online Oct 13. http://arxiv.org/abs/2410.09890.

30 Ilse M, Tomczak J, Welling M. Attention-based Deep Multiple Instance Learning. In: Dy J, Krause A, eds. Proceedings of the 35th International Conference on Machine Learning. PMLR, 10--15 Jul 2018: 2127–36.

medRxiv preprint doi: https://doi.org/10.64898/2026.03.04.26347460; this version posted March 10, 2026. The copyright holder for this preprint (which was not certified by peer review) is the author/funder, who has granted medRxiv a license to display the preprint in perpetuity. It is made available under a CC-BY-NC 4.0 International license .

Tables

Table 1. Cohort characteristics

	Training		Validation	Internal Test	Public External	Krakow External
	Internal	ADNI				
# Patients	5,645	1,737	321	837	1,756	293
Diagnosis						
MS	806	-	137	138	263	63
Non-MS	4,839	1,737	184	699	1,493	230
with WML	2,660	-	76	325	461	113
Sex						
Women	3,318	905	190	526	778	178
Men	2,327	830	131	311	802	115
Unknown	-	2	-	-	176	-
Age, years	52·1 ± 21·5	74·8 ±8·4	44·5 ± 16·6	46·4 ± 17·1	52·7 ± 23·1 (N=1,686)	45·3 ± 17·8
# Scans	6,261	1,857	332	837	1,756	293
MRI protocol						
3D FLAIR	1,622	1,456	293	630	1,052	293
2D FLAIR	4,691	-	164	512	704	-
3DT1-w	2,382	401	195	497	1,215	293
2DT1-w	3,832	-	140	360	50	-
3DT1-CE	1,384	-	189	414	784	293
2DT1-CE	375	-	113	236	-	-
Multi-Shell dMRI	3,621	-	229	579	-	-
Field Strength						
1·0T	-	-	-	-	4	-
1·5T	1	431	-	-	147	293
3·0T	6,260	1,423	332	837	1,499	-
Unknown	-	3	-	-	106	-
Scanner						
Siemens	6,261	1,001	332	837	711	-
GE	-	685	-	-	594	293
Philips	-	167	-	-	326	-
Others	-	-	-	-	4	-
Unknown	-	4	-	-	121	-

medRxiv preprint doi: https://doi.org/10.64898/2026.03.04.26347460; this version posted March 10, 2026. The copyright holder for this preprint (which was not certified by peer review) is the author/funder, who has granted medRxiv a license to display the preprint in perpetuity. It is made available under a CC-BY-NC 4.0 International license .

Table 2. Performance metrics of the model and biomarkers

	AUC (95% CI)	Sensitivity (95% CI)	Specificity (95% CI)
Internal Test			
DeepMS (Overall, n=837)	0·968 (0·947-0·987)	0·942 (0·902-0·977)	0·941 (0·923-0·958)
DeepMS (WMLs, n=464)	0·964 (0·941-0·984)	0·942 (0·899–0·978)	0·926 (0·897–0·952)
Public External			
DeepMS (Overall, n=1,756)	0·974 (0·966-0·982)	0·818 (0·772-0·862)	0·989 (0·983-0·994)
DeepMS (WMLs, n=724)	0·971 (0·962-0·980)	0·818 (0·770–0·860)	0·976 (0·961–0·989)
Krakow external			
DeepMS (Overall, n=293)	0·940 (0·898-0·974)	0·810 (0·705-0·902)	0·974 (0·952-0·992)
DeepMS (WMLs, n=176)	0·940 (0·901-0·972)	0·810 (0·704–0·903)	0·947 (0·901–0·983)
Reader Study (n=308)			
DeepMS	0·971 (0·951-0·987)	0·961 (0·924-0·991)	0·884 (0·837-0·930)
DIS	-	0·929 (0·878-0·970)	0·785 (0·720-0·848)†
DIT	-	0·488 (0·405-0·572)†	0·923 (0·881-0·956)
CVS	-	0·520 (0·428-0·603)†	0·928 (0·887-0·964)
PRL	-	0·291 (0·209-0·372)†	0·983 (0·963-1·000)†
Composite Biomarker	-	0·748 (0·669-0·824)†	0·923 (0·883-0·959)
DeepMS+Lesion	-	0·921 (0·872-0·968)	0·961 (0·932-0·989)†

† $P < 0·05$ by McNemar's test compared with DeepMS (threshold = 0·50).

medRxiv preprint doi: https://doi.org/10.64898/2026.03.04.26347460; this version posted March 10, 2026. The copyright holder for this preprint (which was not certified by peer review) is the author/funder, who has granted medRxiv a license to display the preprint in perpetuity. It is made available under a CC-BY-NC 4.0 International license .

Figure legends

Figure 1: Study design and development workflow of the DeepMS model. (A) Model training strategy. DeepMS was developed on a multimodal dataset with both sMRI (T1-CE, FLAIR, T1-w) and dMRI (DTI, DKI, SMI). **(B)** Inference pipeline. During inference, only sMRI modalities were used. Predictions were ensembled to generate a patient-level MS diagnosis. **(C)** Performance evaluation. The model was evaluated on internal and two independent external cohorts (Krakow external and public external). A reader study involving three radiologists was conducted on a subset of the internal test cohort (n=308) to compare model performance against existing MS imaging biomarkers (DIS, DIT, CVS, and PRL). **(D)** Ablation study and lesion masking experiment. To evaluate the contribution of training with additional dMRI and assess the model's capacity to exploit information from NAWM, performance was compared between the model trained with sMRI-only and with both dMRI and sMRI using original versus lesion-masked images from the external test set.

AUC=area under the curve. CVS=central vein sign. DIS=dissemination in space. DIT=dissemination in time. DKI=diffusional kurtosis imaging. dMRI=diffusion magnetic resonance imaging. DTI=diffusion tensor imaging. FLAIR=fluid-attenuated inversion recovery. MS=multiple sclerosis. NAWM=normal-appearing white matter. PRL=paramagnetic rim lesions. SMI=standard model imaging. sMRI=structural magnetic resonance imaging. T1-CE=T1-weighted contrast-enhanced. T1-w=T1-weighted. WML=white matter lesion.

Figure 2: Diagnostic performance, biomarker benchmarking, and lesion-masking analysis of DeepMS. (A–C) ROC curves of DeepMS in the **(A)** internal test cohort (n=837), **(B**) Krakow external cohort (n=293), and **(C)** public external cohort (n=1,756). Performance is shown for the overall cohort and the WML subgroup. **(D)** Benchmarking against lesion-centric imaging biomarkers in the reader study subset (n=308). DeepMS performance (shaded area indicates 95% CI) is compared with biomarkers (points). Stars denote performance at the prespecified default threshold (0·50) for the standalone DeepMS model and for a hybrid strategy defined as a positive DeepMS prediction combined with at least one positive cross-sectional lesion biomarker (DIS, CVS, or PRL). **(E–F)** Lesion-masking experiment in the external test subset with lesion masks available (n=550), showing ROC curves **(E)** before and **(F)** after digitally masking lesions. Models trained with sMRI only showed a marked decline after masking, whereas the model trained with both sMRI and dMRI retained performance with a smaller reduction in AUC.

AUC=area under the curve. CI=confidence interval. CVS=central vein sign. DIS=dissemination in space. dMRI=diffusion MRI. PRL=paramagnetic rim lesion. ROC=receiver operating characteristic. sMRI=structural MRI. SWI=susceptibility-weighted imaging. WML=white matter lesion.

Figure 3: Prediction heatmaps across representative clinical scenarios on FLAIR MRI. Axial FLAIR images (left) are shown alongside prediction heatmaps from DeepMS trained on sMRI only (middle; sMRI-only) and DeepMS trained on both dMRI and sMRI (right; sMRI+dMRI). Red indicates local contributions supporting MS diagnosis, and blue indicates local contributions supporting non-MS diagnosis (scale −1 to 1); the predicted MS probability is

medRxiv preprint doi: https://doi.org/10.64898/2026.03.04.26347460; this version posted March 10, 2026. The copyright holder for this preprint (which was not certified by peer review) is the author/funder, who has granted medRxiv a license to display the preprint in perpetuity. It is made available under a CC-BY-NC 4.0 International license .

shown below each heatmap. **(A)** Typical MS: sMRI-only model is lesion-focused, whereas the model trained on both sMRI and dMRI shows additional positive signals extending into the surrounding NAWM. **(B)** MS mimic with DIS-positive imaging: clinically misdiagnosed as MS; sMRI-only yielded a false positive, whereas sMRI+dMRI correctly excluded MS (true negative) despite visible lesions with broader negative signals from NAWM. **(C)** MS meeting DIS missed by both models.

dMRI=diffusion MRI; DIS=dissemination in space; FP=false positive; FN=false negative; MS=multiple sclerosis; NAWM=normal-appearing white matter; sMRI=structural MRI; TN=true negative; TP=true positive; WML=white matter lesion.

medRxiv preprint doi: https://doi.org/10.64898/2026.03.04.26347460; this version posted March 10, 2026. The copyright holder for this preprint (which was not certified by peer review) is the author/funder, who has granted medRxiv a license to display the preprint in perpetuity. It is made available under a CC-BY-NC 4.0 International license .

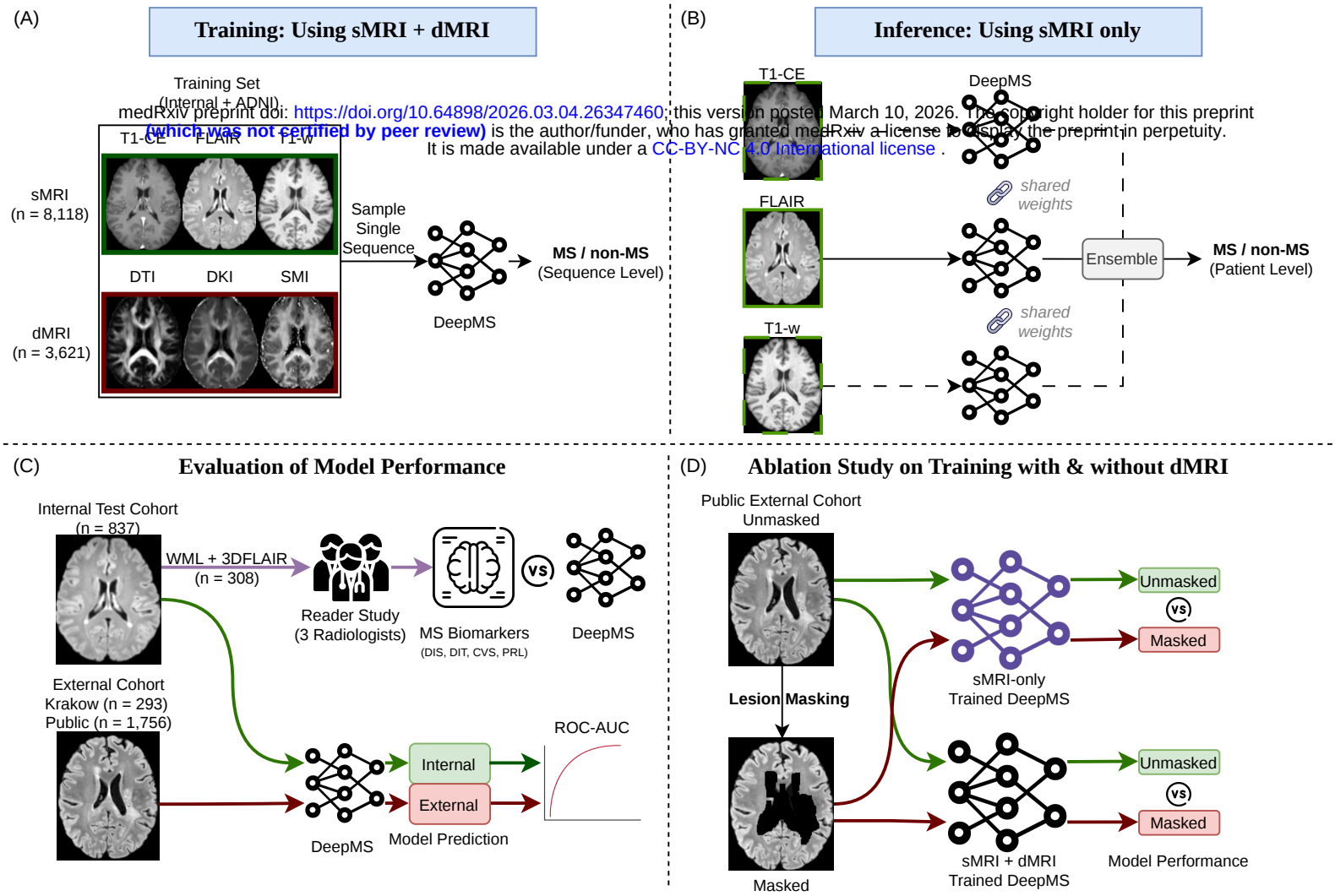

medRxiv preprint doi: https://doi.org/10.64898/2026.03.04.26347460; this version posted March 10, 2026. The copyright holder for this preprint
(which was not certified by peer review) is the author/funder, who has granted medRxiv a license to display the preprint in perpetuity.
It is made available under a CC-BY-NC 4.0 International license .

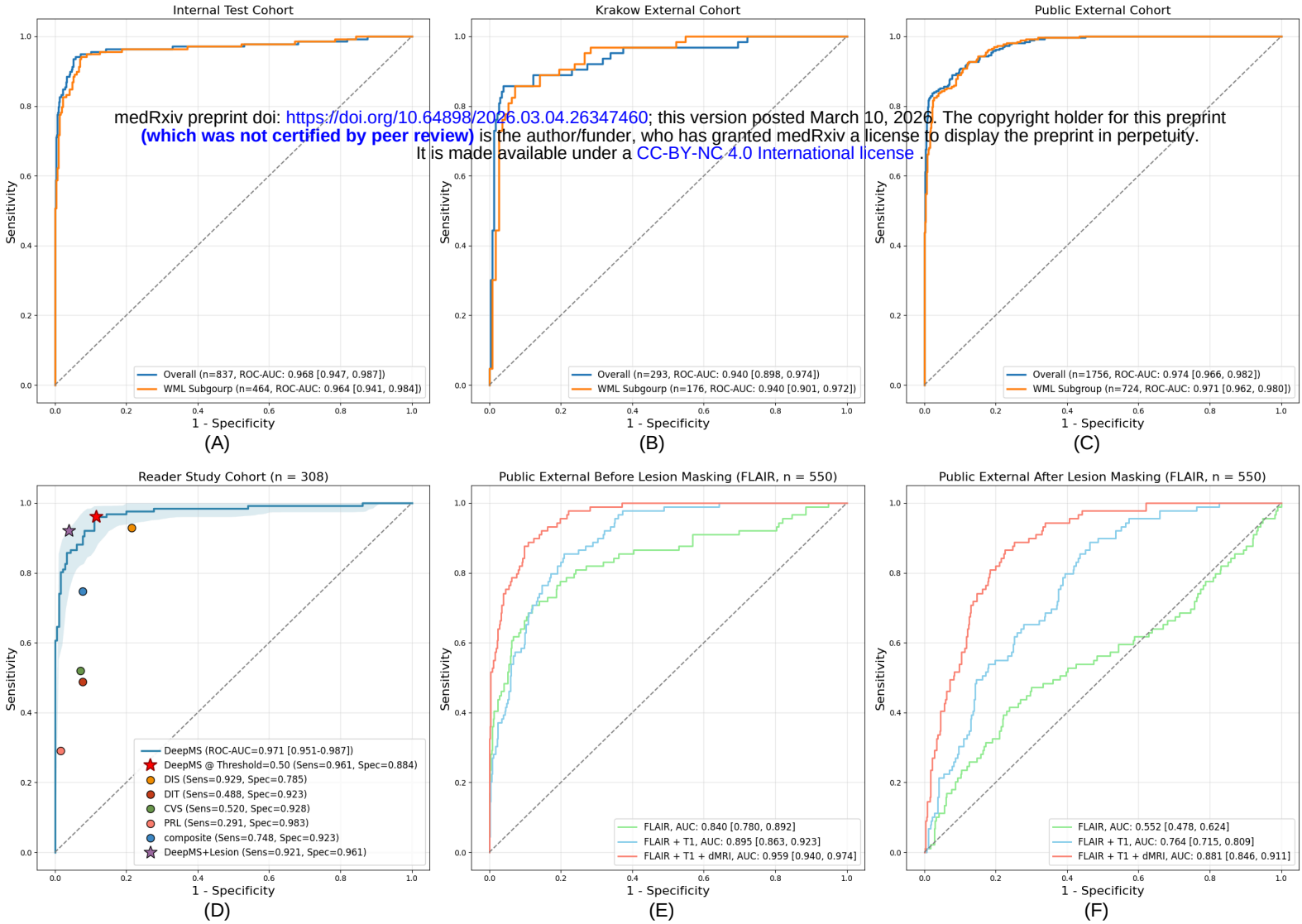
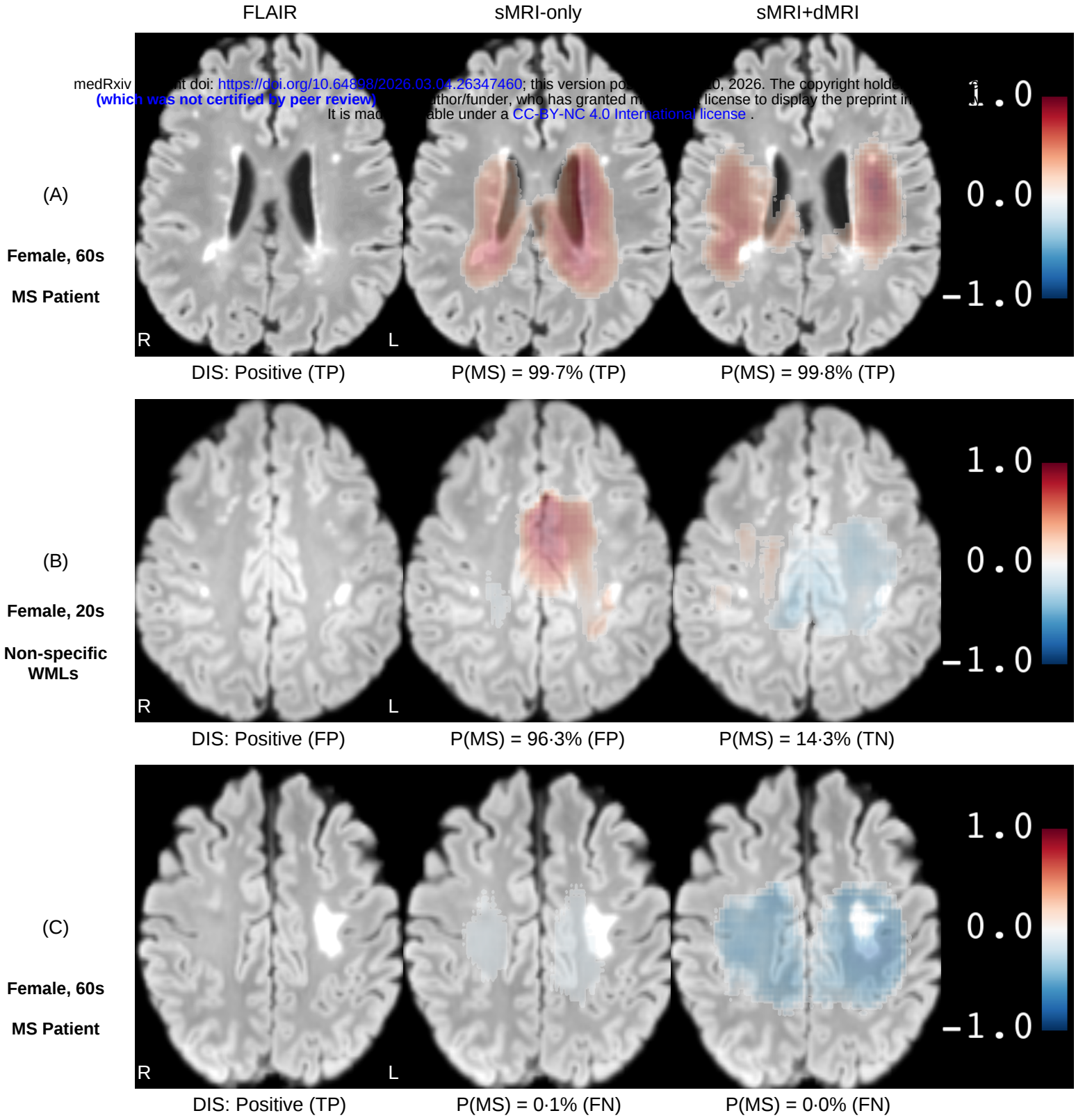
medRxiv [illegible]t doi: https://doi.org/10.64898/2026.03.04.26347460; this version po[illegible]0, 2026. The copyright holde[illegible]
(which was not certified by peer review) [illegible]uthor/funder, who has granted m[illegible] license to display the preprint i[illegible]
It is mad[illegible]able under a CC-BY-NC 4.0 International license .