References

1 Bortolussi R. Listeriosis: A primer. *CMAJ* 2008; **179**: 795–7.
2 Hamada S, Vearncomve M, McGeer A, Shah PS. Neonatal group B streptococcal disease: Incidence, presentation, and mortality. *J. Matern. Fetal Neonatal Med.* 2008; **21**: 53–7.
3 Schrag SJ, Hadler JL, Arnold KE *et al*. Risk factors for invasive, early on-set *Escherichia coli* in the era of widespread intrapartum antibiotic use. *Pediatrics* 2006; **118**: 570–76.
4 Takahashi N, Hasegawa H, Komiyama M *et al*. Selective excretion of anti-inflammatory cytokine interleukin-10 in a superantigen-inducing neonatal infectious disease. *Cytokine* 2008; **45**: 39–43.
5 Serushago B, Macdonald C, Lee SHS, Stadnyk A, Bortolussi R. Interferon-gamma detection in cultures of newborn cells exposed to *Listeria monocytogenes*. *J. Interferon Cytokine Res.* 1995; **15**: 633–5.
6 Mereghetti L, Roche SM, Lanotte P *et al*. Virulence and cord blood mononuclear cells cytokine production induced by perinatal *Listeria monocytogenes* strains from different phylogenetic lineages. *Biol. Neonate* 2004; **86**: 66–72.
7 Giardin E, Berner M, Grau GE, Dayer JM, Roux-Lombard P, Suter S. Tumour necrosis factor in neonatal listeriosis: A case report. *Eur. J. Pediatr.* 1989; **148**: 644–5.
8 Suda H, Moroi C, Inada K, Chida S, Koizumi Y. A case of congenital *Listeria* septicemia associated with high levels of inflammatory cytokines. *Acta Paediatr. Jpn.* 1997; **39**: 382–4.

Development of Kawasaki syndrome in autoimmune neutropenia after treatment with granulocyte colony-stimulating factor

Kentaro Ueno, Yuichi Nomura, Michiko Arata, Shinsuke Maruyama, Takayuki Tanabe, Taisuke Eguchi and Yoshifumi Kawano

Department of Pediatrics, Kagoshima University Hospital, Kagoshima, Japan

Key words autoimmune neutropenia, granulocyte colony-stimulating factor, Kawasaki syndrome.

Kawasaki syndrome (KS) is an acute febrile illness with systemic vasculitis, which may cause coronary artery abnormalities (CAA).[1] Laboratory findings show an increased white blood cell (WBC) count, a shift to the left with segmented neutrophils and increased C-reactive protein (CRP) levels in the acute phase of the disease. Pathological histology also shows infiltrating cells that initially mainly consist of neutrophils, followed in time by macrophages.[2] Primary autoimmune neutropenia occurs frequently in newborns with an incidence of approximately 1/100 000, and is usually diagnosed at the age of 5–15 months.[3,4] Although there is significant neutropenia at the time of disease onset (500–1000 neutrophils/μL), the clinical course tends to resolve by the age of 2 or 3 years in 95% of patients.[4] Patients with autoimmune neutropenia who have severe infections sometimes require not only antibiotics but also additional treatment with corticosteroids, i.v. immunoglobulin (IVIG), and granulocyte colony-stimulating factor (G-CSF).[3]

Here, we describe an 8-month-old boy with autoimmune neutropenia, who developed Kawasaki syndrome soon after being treated with G-CSF. This may provide an interesting viewpoint about potential onset mechanisms of KS.

Correspondence: Kentaro Ueno, MD, Department of Pediatrics, Kagoshima University Hospital, 8-35-1 Sakuragaoka, Kagoshima 890-8520, Japan. Email: ukenta@m3.kufm.kagoshima-u.ac.jp
Received 8 February 2010; revised 7 May 2010; accepted 15 June 2010.
doi: 10.1111/j.1442-200X.2011.03376.x

Case report

A previously healthy 5-month-old boy had high fever and lymphadenopathy, and was treated successfully with antibiotics. After treatment his lymphadenopathy soon improved but neutropenia with absolute neutrophil counts (ANC) <500/μL was noted (90–400/μL), and the condition lasted for months. He was diagnosed with autoimmune neutropenia because of the presence of anti-neutrophil antibody. At the age of 8 months he had high fever and complained of earache. Laboratory findings were as follows: WBC, 4500/mm^3; ANC, 626/mm^3; CRP, 5.4 mg/dL. He was diagnosed as having acute otitis media, and was admitted to the neighborhood hospital for initial treatment with the antibiotic flomoxef sodium. On the third day of illness he still had high fever, and developed right cervical lymphadenopathy. Computed tomography showed a ring-enhancing lesion, suggestive of a cervical abscess. WBC was 3560/mm^3, ANC, 819/mm^3; and CRP 11.9 mg/dL. The antibiotic was changed from flomoxef sodium to meropenem trihydrate and clindamycin, and G-CSF administration (5 μg/kg per day) was initiated as an additional treatment, but his clinical symptoms (i.e. high fever and lymphadenopathy) did not improve. On the fifth day of illness, 3 days after initiation of G-CSF, he suddenly developed skin rash, peripheral edema, injected lips, and conjunctival injection, and was then diagnosed as having KS. We administered IVIG (2 g/kg) for 1 day and oral aspirin (30 mg/kg) and stopped administration of clindamycin and G-CSF. Although the clinical symptoms partially subsided, he continued to have high fever, and WBC was 8430/mm^3, ANC was 6643/mm^3, and CRP was 22.9 mg/dL. He was then treated with IVIG (2 g/kg) for 1 day additionally on the seventh day, but

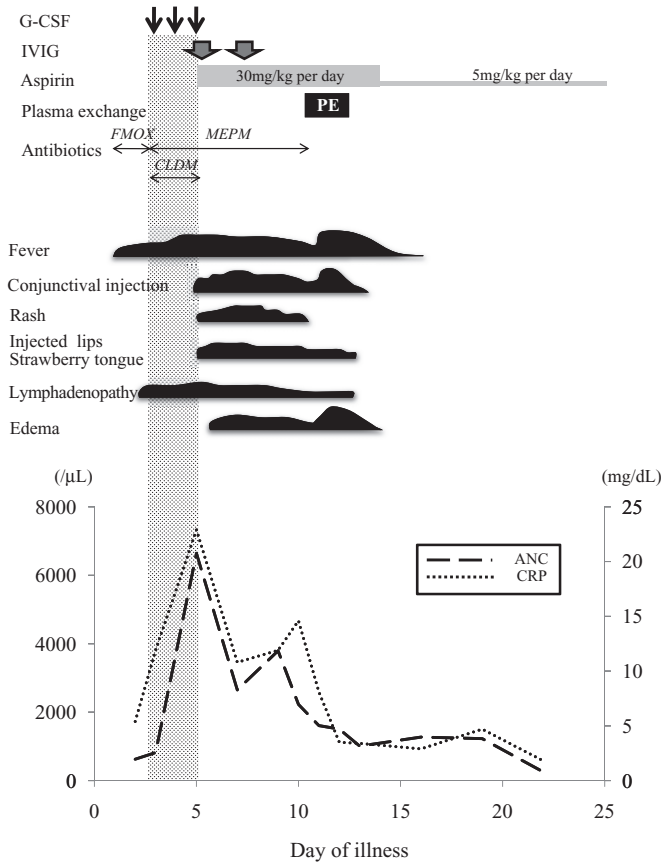

Fig. 1 Clinical course and laboratory data. ANC, absolute neutrophil count; CLDM, clindamycin; CRP, C-reactive protein; FMOX, flomoxef sodium; G-CSF, granulocyte colony-stimulating factor; IVIG, i.v. immunoglobulin; MEPM, meropenem trihydrate.

he had poor clinical resolution of symptoms, and was then referred to Kagoshima University Hospital.

At referral, echocardiography demonstrated mild dilatation of the origin of the left and right coronary arteries; we administered a 2 day course of plasma exchange (PE) with the consent of the parents on the 10th day. During the course of PE therapy, his clinical symptoms gradually subsided, and, similarly, inflammatory markers decreased after PE therapy (total exchange volume, 1625 mL): WBC decreased from 8620 to 4300/mm^3, ANC decreased from 4095 to 860/mm^3, and CRP decreased from 11.9 to 3.5 mg/dL. There were no complications during PE therapy. Aspirin was reduced to 5 mg/kg per day on the 13th day when the serum CRP level decreased. He was discharged on the 25th day. At discharge, echocardiography showed mild dilatation of the left coronary artery and his WBC was 4750/mm^3, and ANC 736/mm^3 (Fig. 1). Sequential follow up with catheter angiography after 4 months from KS onset showed complete regression of the left coronary artery dilatation.

Discussion

We encountered a patient with autoimmune neutropenia who developed KS clinical symptoms rapidly after receiving G-CSF treatment. Furthermore, he needed to undergo PE therapy for resistance to additional IVIG treatment. Functionally activated neutrophils are known to increase in number, and transient infiltration of neutrophils was identified in the early stage of KS.[2] Elevated neutrophil counts are associated with the development of coronary artery lesions, but early neutropenia within 10 days of illness is reported to be associated with CAA formation. The significance of neutrophils in KS has not been fully elucidated.[5] Inflammation associated with KS initially involves elevation of the levels of various cytokines such as interleukin (IL)-1β, IL-6, and tumor necrosis factor-α (TNF-α), and G-CSF may also play an important role in the acute phase of KS.[6,7]

The G-CSF treatment has also been associated with flares in patients with Felty's syndrome or other autoimmune diseases such as systemic lupus erythematosus.[8] Autoimmune neutropenia is likely to have a relatively benign course, but G-CSF treatment is indicated in some children in whom severe infections occur. G-CSF has been identified as a glycoprotein that stimulates the production and functional activation of neutrophils, and modulates the function and activity of matured neutrophils including production of chemokines, phagocytosis and cell surface receptor expression.[9] Activated neutrophils have been reported to induce organ damage by tissue infiltration and release of pro-inflammatory cytokines.[9] G-CSF treatment also induces excessive migration or activation of neutrophils and induces monocyte or macrophage production, which would promote vascular permeability.[9] KS patients, however, who present with only fever and cervical lymphadenopathy at admission have been reported to have an increased risk of additional IVIG treatment and of developing CAA.[10] Therefore it is possible that the present case may have been due to the natural course of the KS itself, but G-CSF treatment may have potentially contributed to the severity of KS inflammation. In light of these considerations, we suggest that G-CSF treatment might be involved in the onset mechanism of KS clinical symptoms.

The present case raises concerns about the potential complication of G-CSF treatment in children with autoimmune neutropenia. Pediatricians should be aware of this risk and ensure careful clinical observation when using G-CSF treatment in children with autoimmune neutropenia complicated with severe or recurrent infections.

References

1 Kawasaki T, Kosaki F, Okawa S, Shigematsu I, Yanagawa H. A new infantile acute febrile mucocutaneous lymph node syndrome (MLNS) prevailing in Japan. *Pediatrics* 1974; **54**: 271–6.
2 Naoe S, Shibuya K, Takahashi K, Wakayama M, Masuda H, Tanaka M. Pathological observations concerning the cardiovascular lesions in Kawasaki disease. *Cardiol. Young* 1991; **1**: 212–20.
3 Bux J, Behrens G, Jaeger G, Welte K. Diagnosis and clinical course of autoimmune neutropenia in infancy: Analysis of 240 cases. *Blood* 1998; **91**: 181–6.
4 Capsoni F, Sarzi-Puttini P, Zanella A. Primary and secondary autoimmune neutropenia. *Arthritis Res. Ther.* 2005; **7**: 208–14.
5 Onouchi Z, Hamaoka K, Ozawa S, Sakata K, Kiyosawa N, Ito H. Neutropenia in the acute phase of Kawasaki disease and prevention of coronary artery aneurysm. *Pediatr. Int.* 2009; **51**: 448–52.

6 Leung DY, Cotran RS, Kurt-Jones E, Burns JC, Newburger JW, Pober JS. Endothelial cell activation and high interleukin-1 secretion in the pathogenesis of acute Kawasaki disease. *Lancet* 1989; **2**: 1298–302.
7 Inoue Y, Kato M, Kobayashi T, Shinohara M, Sone K, Morikawa A. Increased circulating granulocyte colony-stimulating factor in acute Kawasaki disease. *Pediatr. Int.* 1999; **41**: 330–33.
8 Vasiliu IM, Petri MA, Baer AN. Therapy with granulocyte colony-stimulating factor in systemic lupus erythematosus may be associated with severe flares. *J. Rheumatol.* 2006; **33**: 1878–80.
9 Dale DC, Liles WC, Summer WR, Nelson S. Review: Granulocyte colony-stimulating factor: Role and relationships in infectious diseases. *J. Infect. Dis.* 1995; **172**: 1061–75.
10 Nomura Y, Arata M, Koriyama C *et al*. A severe form of Kawasaki disease presenting with only fever and cervical lymphadenopathy at admission. *J. Pediatr.* 2010; **156**: 786–91.

Blepharophimosis-ptosis-epicanthus inversus syndrome

Carla Graziadio,[1,2] Felipe Nora de Moraes,[1] Rafael Fabiano Machado Rosa,[1,2] Paulo Ricardo Gazzola Zen,[1,2] Giovanni Marcos Travi,[2] Carolina Waldman,[1,2] Cristina Touguinha Neves Medina,[1,2] Elfride De Baere[3] and Giorgio Adriano Paskulin[1,2]

[1]*Federal University of Health Sciences of Porto Alegre (UFCSPA) and* [2]*Santa Casa de Porto Alegre Hospital Complex (CHSCPA), Porto Alegre, Rio Grande do Sul, Brazil, and* [3]*Ghent University Hospital, Belgium*

Key words blepharophimosis, epicanthus inversus, *FOXL2* gene, genetic counseling, ptosis.

Blepharophimosis-ptosis-epicanthus inversus syndrome (BPES) (OMIM 110100)[1] is a rare autosomal dominant genetic disease that affects aproximatelly 1 in 50 000 liveborns. It is clinically characterized by a complex eyelid/ocular malformation that includes blepharophimosis, ptosis, epicanthus inversus and telecanthus. It is often associated with premature ovarian failure (POF), which is classified as BPES type I. BPES with normal ovarian function is classified as BPES type II.[2–4]

Mutations in the *FOXL2* gene (forkhead transcription factor gene 2) (OMIM 605597),[1] located at 3q23, have been shown to underly this syndrome. The majority of cases are due to a *de novo* mutation.[5]

Here a case report is provided of a 1-year-old girl with BPES caused by a de novo mutation of the *FOXL2* gene.

Case report

The patient was a Caucasian 1-year-old girl, the only daughter of young and non-consanguineous parents. Both the mother and the maternal grandfather presented a history of bilateral blepharoptosis, entropium, distichiasis and dysmorphic ears. The mother was previously referred for oculoplastic surgery for blepharophimosis correction. The parents had healthy children from their previous marriages. The familial history was negative for cases with POF or infertility (Fig. 1). The patient was born by vaginal delivery, at term, weighing 3500 g (50th–75th centile), measuring 44 cm (<2nd centile), with head circumference of 36 cm (50th–98th centile) and Apgar scores of 8 and 10 at the first and fifth minutes, respectively (Fig. 1). Although the mother's pregnancy was uneventful, the fetal ultrasound identified a right pyelocaliceal dilatation. Renal ultrasound performed soon after birth confirmed this finding. The evaluation made later, through the same exam and through excretory urography, was normal however.

At physical examination, at the age of 1 year and 9 months, the infant presented with a height of 70 cm (50th centile); weight of 8900 g (50th–75th centile) and head circumference of 44.3 cm (2nd–50th centile); supraciliar arch hypoplasia; arched eyebrows; blepharophimosis; ptosis, epicanthus inversus; telecanthus; low and broad nasal root; short columella; long philtrum; high arched palate; carp-shaped mouth; micrognathia; small, low-set and posteriorly displaced ears with overfolded helix; and redundant neck skin (Fig. 2). No heart murmur or sign of cardiorespiratory dysfunction was observed. Ophthalmological assessment did not identify any additional findings. Molecular analysis from a peripheral blood sample through polymerase chain reaction (PCR), sequencing, and multiplex ligation-dependent probe amplification (MLPA) of the *FOXL2* gene showed that the patient was heterozygous for the p.Pro287Fs (c.843-859dup) mutation in the *FOXL2* gene. The molecular evaluation of her mother and grandfather did not show the presence of this mutation, however.

The child presented a normal neuropsychomotor development: she had head support at age 3 months; sat alone at 7 months and started to walk alone at 1 year and 3 months. At 10 months, she was referred for simultaneous corrective surgeries for epicanthus inversus/telecanthus, through the technique of medial canthoplasty using Z-plasty, and for ptosis, through bilateral frontalis suspension. No complications were observed after the surgery.

Correspondence: Paulo Ricardo Gazzola Zen, MD PhD, Genética Clínica – UFCSPA/CHSCPA, Rua Sarmento Leite, 245/403, CEP: 90050-170 Porto Alegre, RS, Brazil. Email: paulozen@ufcspa.edu.br
Received 28 December 2009; revised 1 March 2010; accepted 28 April 2010.
doi: 10.1111/j.1442-200X.2010.03223.x