Elevated Retinal Neovascularization on Widefield Optical Coherence Tomography Angiography Predicts Complications in High-Risk Proliferative Diabetic Retinopathy

AN-LUN WU, JINYI HAO, LIQIN GAO, YUKUN GUO, TRISTAN T. HORMEL, CHRISTINA J. FLAXEL, MERINA THOMAS, BENJAMIN K. YOUNG, STEVEN T. BAILEY, DONG-WOUK PARK, YALI JIA, AND THOMAS S. HWANG

• PURPOSE: To determine whether retinal neovascularization (RNV) metrics derived from single-shot widefield swept-source OCT angiography (SS-OCTA) predict subsequent vision-threatening complications in eyes with high-risk proliferative diabetic retinopathy (PDR).

• DESIGN: Prospective case series.

• PARTICIPANTS: Eyes clinically graded as high-risk PDR at a tertiary care center, followed up for at least 6 months.

• METHODS: Eligible eyes underwent single-shot 26 × 21-mm SS-OCTA imaging (DREAM OCT, Intalight Inc.). A validated deep learning-based algorithm segmented the vitreous cavity slab to generate *en face* OCTA images for automated detection and quantification of RNV membrane and the vascular areas. Lesions were classified as elevated when they were separated from the internal limiting membrane (ILM) and attached when there was no space between the lesion and the ILM. We analyzed baseline OCTA-derived metrics for their predicting eyes that developed new or recurrent vitreous hemorrhage (VH) or tractional retinal detachment (TRD) during follow-up.

• MAIN OUTCOME MEASURES: Incidence of new or recurrent vitreous hemorrhage and traction retinal detachment.

• RESULTS: Over a median follow-up period of 291 days (range, 180-466), 8 of 18 eyes (44.4%) developed complications, with 7 (38.9%) developing VH and 1 (5.6%) developing TRD. Among the 115 identified RNV lesions, 87 (75.7%) were located outside the arcades. Compared to eyes without complications, eyes with complications had a larger median total RNV membrane area (25.72 mm² vs 1.33 mm²; $P = .006$) and a larger median total RNV vascular area (9.72 mm² vs 0.76 mm²; $P = .010$). Eyes with complications had a larger elevated RNV membrane area (5.13 mm² vs 0.10 mm²; $P = .009$) and vascular area (2.69 mm² vs 0.05 mm²; $P = .007$), whereas attached RNV metrics were not significantly different between groups. Total RNV membrane area demonstrated the highest predictive performance for identifying eyes at risk of complications (AUC = 0.888), with a sensitivity of 87.5% and a specificity of 80.0% at a cutoff value of 3.40 mm².

• CONCLUSIONS: Widefield SS-OCTA is useful for evaluating RNV burden and its axial relationship to the ILM in high-risk PDR. Elevated baseline RNV, incorporating spatial and anatomic features, predicts subsequent tractional complications such as VH and TRD. These imaging biomarkers may complement current clinical staging of PDR. (Am J Ophthalmol 2026;283: 268–278. © 2025 Elsevier Inc. All rights are reserved, including those for text and data mining, AI training, and similar technologies.)

Accepted for publication December 19, 2025.

From the Casey Eye Institute (A.L.W., J.H., L.G., Y.G., T.T.H., C.J.F., M.T., B.K.Y., S.T.B., D.W.P., Y.J., T.S.H.), Oregon Health & Science University, Portland, Oregon, USA; Department of Ophthalmology (A.L.W.), Mackay Memorial Hospital, Hsinchu, Taiwan; Department of Biomedical Engineering (J.H., Y.G., Y.J.), Oregon Health & Science University, Portland, Oregon, USA

Inquiries to Thomas Hwang, Casey Eye Institute, Oregon Health & Science University, Portland, Oregon, USA; e-mail: hwangt@ohsu.edu

INTRODUCTION

Proliferative diabetic retinopathy (PDR) is a leading cause of legal blindness among working-age adults in the United States and globally.[1,2] As DR advances, progressive retinal nonperfusion and ischemia drive the formation of retinal neovascularization (RNV), where abnormal vessels breach the internal limiting membrane (ILM) and extend into the vitreous cavity, a signature of late-stage disease.[3,4] These fragile neovascular tufts are prone to leakage, fibrosis, and contraction, which may lead to irreversible visual impairment. Even under regular follow-up and timely treatment, complications such as vitreous hemorrhage (VH) and tractional retinal detachment (TRD) may still occur during the disease course.[5] A national real-world registry study showed that, among treated PDR eyes not lost to follow-up, 17.3% developed

© 2025 Elsevier Inc. All rights are reserved, including those for text and data mining, AI training, and similar technologies..
0002-9394/$36.00
https://doi.org/10.1016/j.ajo.2025.12.017

VH and 4.1% developed TRD within approximately 1 year of follow-up.[6] High-risk PDR eyes remain particularly vulnerable. Although panretinal photocoagulation (PRP) and anti-VEGF therapy reduce overall progression by inducing neovascular regression, prior clinical trials have shown that substantial rates of disease worsening continue despite treatment.[7,8] Early identification of patients at risk for such vision-threatening complications is critical for guiding clinical decisions and tailoring treatment strategies.

While systemic factors such as diabetes duration, glycemic control, and hypertension are well-established contributors to DR progression,[9] ocular imaging biomarkers have also emerged as important indicators of disease severity.[5] Traditionally, the detection and grading of RNV have relied on clinical examination, color fundus photography, and fluorescein angiography (FA). Although these tools remain the current standard, they are limited by qualitative assessment, lack of depth resolution, and inability to fully characterize neovascular morphology or its spatial relationship with adjacent vitreoretinal interface. Optical coherence tomography angiography (OCTA) overcomes these limitations by providing noninvasive, high-resolution, depth-resolved visualization of retinal microvasculature and their spatial anatomic relationships without dye injection,[10,11] enabling both *en face* and cross-sectional localization of RNV relative to the ILM and posterior hyaloid.[12] These capabilities open the door to incorporating quantitative imaging biomarkers describing the tomographic relationship between RNV and the posterior vitreous.[13,14]

Despite these advances, the prognostic significance of RNV morphologic features, particularly localized elevation of neovascular tissue, remains unexplored. Swept-source OCTA (SS-OCTA) offers enhanced visualization of the vitreous and vitreoretinal interface,[15] allowing for more detailed assessment of these structural relationships.[16] Our group has previously demonstrated that widefield SS-OCTA can effectively detect RNV lesions in the mid-peripheral retina,[17-19] a region particularly susceptible to diabetic microvascular changes. In addition, we have validated a deep learning-based RNV segmentation algorithm capable of precise, automated delineation of neovascular lesions while minimizing slab segmentation artifacts.[20] These innovations provide the opportunity to integrate the topographic and tomographic information of RNV from widefield OCTA to identify imaging biomarkers that may predict the development of complications in patients with high-risk PDR.

METHOD

This prospective, longitudinal, observational study (NIH grant R01 EY035410) was conducted at the Casey Eye Institute, Oregon Health & Science University, from December 2023 through June 2025. The study adhered to the tenets of the Declaration of Helsinki and complied with the Health Insurance Portability and Accountability Act of 1996. Approval was obtained from the Institutional Review Board of Oregon Health & Science University, and written informed consent was obtained from all participants.

• **STUDY PARTICIPANTS:** We recruited consecutive patients with a clinical diagnosis of high-risk PDR without traction retinal detachment and other concurrent ocular pathology based on fundus examination using the Early Treatment of Diabetic Retinopathy Study (ETDRS) criteria.[3,21] High-risk PDR was defined as either: (1) the presence of RNV accompanied by prior vitreous or preretinal hemorrhage within the past 3 months, or (2) RNV located on or within one disc diameter of the optic disc with a size equal to or greater than about one-quarter to one-third of the disc area, in the absence of vitreous or preretinal hemorrhage. The diagnosis of high-risk PDR was confirmed by ultra-widefield FA or ultra-widefield color fundus photography (Optos, Ltd., Dunfermline, UK). All participants had a minimum follow-up of 6 months after the baseline examination. Exclusion criteria included any media opacity precluding the grading of widefield SS-OCTA images and loss to follow-up. All participants underwent comprehensive ophthalmic examinations, including standard ETDRS visual acuity testing, intraocular pressure measurement, slit-lamp examination, and standard dilated fundus examination using slit-lamp biomicroscopy with a 90-diopter (D) or 78D lens, and indirect ophthalmoscopy. Complications were defined as the occurrence of any new or recurrent VH, or the development of TRD. All cases of complications were reviewed in a retrospective manner to confirm the appropriate diagnosis.

• **IMAGE ACQUISITION AND ANALYSIS:** Imaging was performed using a commercial (pending FDA approval) 200-kHz swept-source OCTA system (DREAM OCT, Intalight Inc.) with a central wavelength of 1050 nm, providing an axial resolution of 5.5 μm and a transverse resolution of 20 μm. Each eye was centered on the fovea during imaging, and scans were acquired using the OCTA volumetric scans of 26 × 21-mm with 1536 × 1240 sampling density. These settings provided a field of view up to an eye angle of 130 degrees, enabling high-resolution imaging of both the posterior pole and mid-peripheral retina.

RNV was defined by the presence of flow signals above the ILM into vitreous cavity on cross-sectional OCTA (overlaid on OCT), corresponding to epiretinal hyperreflective material on *en face* OCT or abnormal flow signals on *en face* OCTA. To optimize RNV detection, a deep learning-based RNV segmentation algorithm was applied, the technical details of which have been previously described elsewhere. Briefly, the algorithm comprises two components: one for vitreoretinal interface (VRI) segmentation and the other for *en face* RNV detection. The

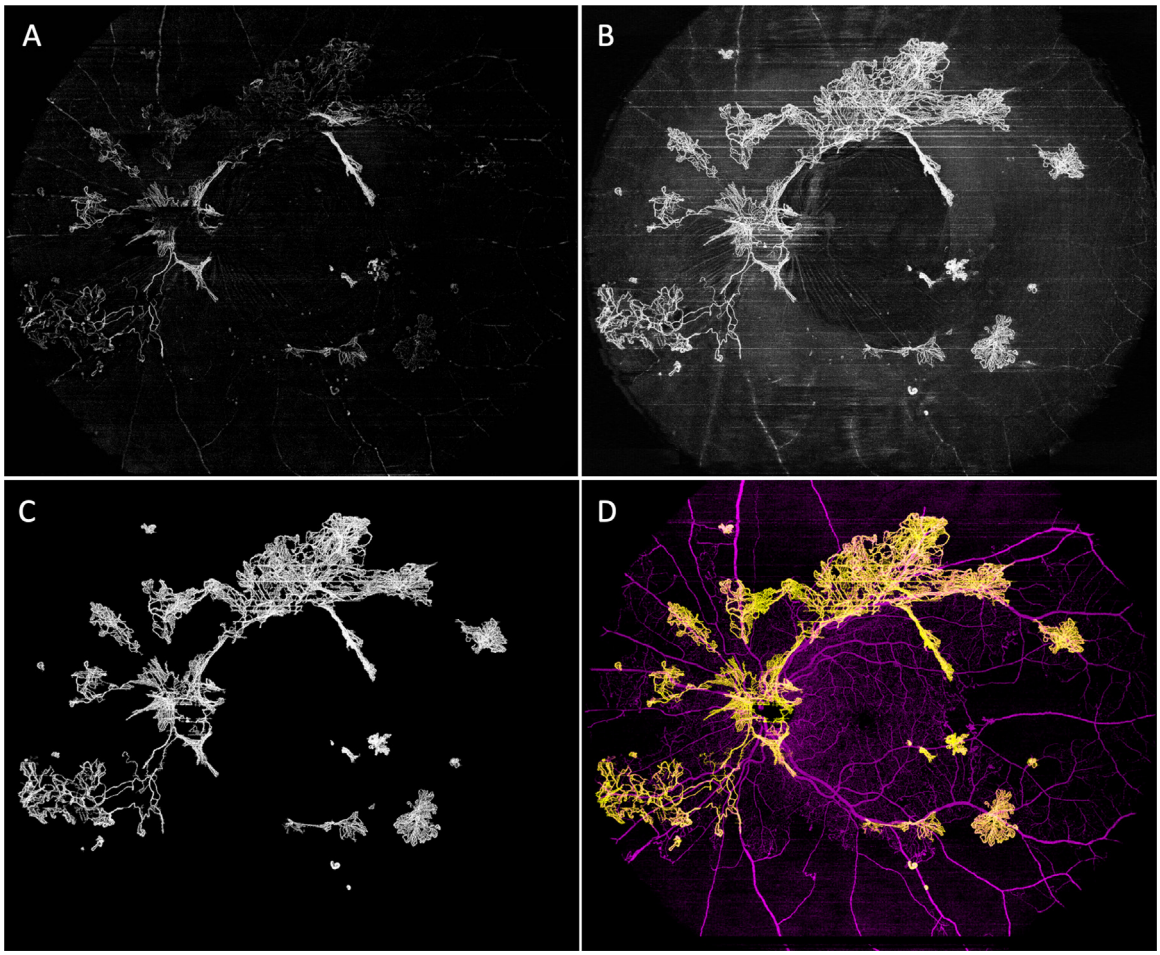

FIGURE 1. Segmentation and image processing of retinal neovascularizations (RNVs) in high-risk proliferative diabetic retinopathy. A. RNVs detection with a single-shot 26 × 21-mm *en face* widefield swept-source OCT angiography image using a vitreoretinal interface slab from commercially available software. B. RNV lesions are more clearly displayed following processing with our deep learning-based segmentation algorithm. C. The final output consists of pixel-level segmentation masks of neovascular vessels, enabling precise quantification without the need for manual background subtraction or noise removal. D. Segmented RNVs (yellow) are clearly visualized separately from the underlying retinal circulation (violet).

algorithm processes both structural OCT and angiographic OCTA volumetric inputs using a convolutional neural network. First, it identifies and segments the VRI to delineate the vitreous cavity. Next, the RNV detection model used *en face* OCT and OCTA projections with the vitreous slab as input to segment RNV lesions by extracting pathological structural and vascular features. The final output was a pixel-level segmentation mask of RNV lesions used for quantitative analysis (Figure 1). The accuracy and validity of this deep learning-based approach for *en face* RNV measurement have been described previously.[20] Manual correction of the ILM boundary was performed when necessary to ensure precise anatomical localization. All segmented RNV outputs were inspected by two certified graders (A.W. and J.H.) and confirmed by senior graders (T.S.H. and Y.J.). The number and distribution of RNV lesions were recorded, including their locations relative to the optic disc and vascular arcades. Additionally, RNVs located on the optic disc or within one-disc diameter from its margin were defined as neovascularization of the disc (NVD), while all other lesions were classified as neovascularization elsewhere (NVE). The RNV vascular area was quantified by calculating the number of pixels containing flow signals within each lesion and converted to square millimeters based on the size of pixel. The RNV membrane area was measured by outlining the outermost boundary of each RNV lesion, with the area similarly calculated in square millimeters using the same spatial calibration.

Posterior vitreous detachment (PVD) status was graded according to a previously described staging system.[22,23] Any discrepancies were resolved through joint review and adjudication by a third grader (T.S.H.). Stage 0 (no vitreoretinal separation) was defined by the presence of a visible

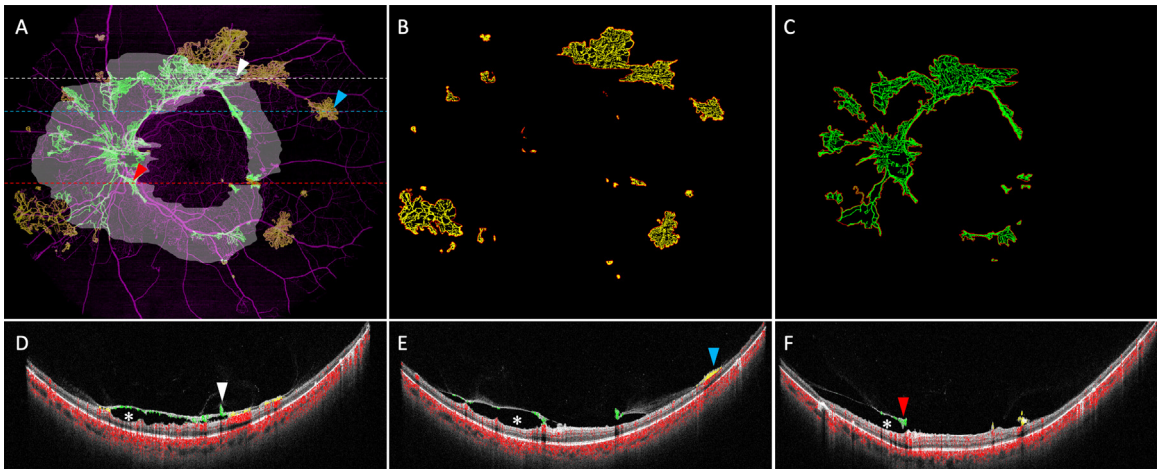

FIGURE 2. Morphologic classification of retinal neovascularizations (RNVs) in relation to vitreous status in high-risk proliferative diabetic retinopathy. (A) Same case as Figure 1. *En face* widefield OCT angiography shows RNV lesions classified into two morphologic types based on using a manual segmentation map of the vitreous detachment area (displayed as a translucent overlay). RNVs adherent to the retinal surface are labeled as attached RNVs (yellow), while those extending anteriorly along the detached posterior hyaloid face are labeled as elevated RNVs (green). Images of attached RNVs (B) and elevated RNVs (C) were binarized to calculate neovascularization areas and membrane areas (outlined in red) for quantitative analysis. D–F. Cross-sectional OCT images corresponding to different morphologic RNV types show abnormal flow signals breaching the inner limiting membrane (ILM), marked by white, blue, and red arrowheads at the respective scan positions indicated by matching dashed lines in (A). The white arrowhead indicates the junction between elevated and attached RNVs, where a elevated RNV has invaded the vitreous space after traversing the posterior hyaloid face. The blue and red arrowheads represent two distinct RNV types: one attached to the internal limiting membrane and confined to the attached posterior hyaloid face (blue), corresponding to attached RNV with yellow flow signals, and the other displaced anteriorly by vitreous traction along the outer surface of the detached posterior hyaloid face (red), corresponding to elevated RNV with green flow signals. Asterisks (*) indicate subhyaloid or sub-membrane cavities.

premacular bursa without any separation between the posterior vitreous cortex and the retinal surface. Stage 1 was defined as partial separation of the posterior vitreous cortex not involving the fovea, which was defined as a 1500-μm diameter circle centered on the foveal center. Stage 2 was defined as vitreoretinal separation involving part of the fovea with persistent attachment to the foveola. Stage 3 was characterized by vitreoretinal separation from the posterior pole, with persistent attachment to the optic disc. Stage 4 (complete PVD) was identified by complete detachment of the posterior vitreous cortex, evidenced either by direct visualization of a fully detached cortex or by the absence of both the premacular bursa and posterior vitreous cortex on the scan.

To generate ground truth labels for elevated RNVs, two masked graders (A.W. and L.G.) reviewed cross-sectional OCTA (overlaid on structural OCT) to identify the boundary between the detached posterior hyaloid face and the retinal surface. Using this information, the corresponding region was merged with the RNV segmentation map to classify neovascular lesions into two categories, processed through our custom software (COOL-ART).[24] Lesions adherent to the retinal surface were labeled as attached RNV, while those extending anteriorly along the detached posterior hyaloid face were labeled as elevated RNV (Figure 2).

• **STATISTICAL ANALYSIS:** All statistical analyses were performed using SPSS Statistics (version 26.0, IBM Corp., Armonk, NY). Descriptive statistics were used to summarize demographic, systemic, and ocular characteristics of the study cohort. Baseline widefield SS-OCTA metrics were evaluated as potential predictors for the development of complications. Fisher's exact test was used to cf categorical variables, while independent *t*-tests or Mann–Whitney U tests were applied for continuous variables, depending on the normality of data distribution. An area under the receiver operating characteristic curve (AROC) analysis was performed to assess the predictive performance of membrane area and vascular area measurements from different RNV morphologies in classifying eyes with or without complications. Sensitivity, specificity, and area under the curve values were calculated for each metric. The optimal thresholds for predicting complications were determined using the Youden index. All *P* values were two-tailed, and a value of $<.05$ was considered statistically significant.

RESULTS

A total of 21 eligible eyes from 21 patients with high-risk PDR were initially enrolled and underwent baseline exam-

TABLE 1. Baseline Demographic and Clinical Characteristics of the Study Participants

Parameters	($n = 18$)
Age, year	50.3 ± 11.36
Sex, n (male/female)	11/7
Laterality, n (right/left)	7/11
Most recent HbA1c (%), median (IQR)	8.4 (7.5-10.5)
Duration of DM (years), median (IQR)	19 (15-22)
DM type, n (%)	
Type 1	5 (27.8)
Type 2	13 (72.2)
High-risk PDR characteristics	
NVD ≥ one-quarter to one-third of the disc, eyes (%)	8 (44.4)
Recent vitreous/preretinal hemorrhage, eyes (%)	10 (55.6)
Treatment naïve, eyes (%)	7 (38.9)
Previous treatment	
Intravitreal VEGF injection, eyes	2
Panretinal photocoagulation, eyes	0
Both, eyes	9
BCVA at baseline (logMAR), median (IQR)	0.04 (0-0.12)
History of hypertension, n (%)	8 (44.4)
Systolic blood pressure, mm Hg	141.3 ± 16.91
Diastolic blood pressure, mm Hg	89.2 ± 9.36

BCVA = best-corrected visual acuity; DM = diabetes mellitus; HbA1c = Hemoglobin A1c; logMAR = logarithm of the minimum angle of resolution; NVD = neovascularization of the optic disc; PDR = proliferative diabetic retinopathy; VEGF = vascular endothelial growth factor.

ination. Of these, two eyes were excluded due to ungradable widefield SS-OCTA images caused by significant VH, and one eye was excluded due to loss to follow-up. This left 18 eyes available for the final analysis. Of these, 10 eyes (55.6%) had prior vitreous or preretinal hemorrhage within the past 3 months, and 8 eyes (44.4%) exhibited NVD equaling or exceeding one-quarter to one-third of the disc. The mean age of participants was 50.3 ± 11.36 years, including 11 males (61.1%) and 7 females (38.9%). Among the included eyes, 7 (38.9%) were treatment-naïve, defined as having received neither prior PRP nor intravitreal anti-VEGF injections. Demographic, systemic parameters, and ocular characteristics are summarized in Table 1.

We identified 115 RNV lesions across the 18 eyes using widefield SS-OCTA. Among these, 87 RNVs (75.7%) were located outside the arcades and 33 (28.7%) within the optic disc and arcades. Nine RNVs (7.8%) were classified as NVD, and 106 RNVs (92.2%) as NVE. The median membrane area of each RNV lesion was 0.26 mm² (IQR: 0.12-0.76), and the median vascular area was 0.18 mm² (IQR: 0.10-0.44). Regarding vitreous status, 3 eyes (16.7%) were graded as no PVD, 7 eyes (38.9%) as stage 1, and 7 eyes (38.9%) as stage 3; 1 eye (5.6%) had previously undergone vitrectomy for diabetic VH. Baseline widefield SS-OCTA metrics per eye are summarized in Table 2.

During a median follow-up period of 291 days (range, 180-466 days), 8 of 18 eyes (44.4%) developed complications, including new VH in 7 eyes (38.9%) and tractional retinal detachment without macular involvement in 1 eye (5.6%). All 18 eyes received treatment during the follow-up period, including PRP (range, 0-3 sessions; median, 1) or intravitreal anti-VEGF injections (range, 0-8; median, 3). Among the eight eyes that developed complications, all had received treatment prior to the onset of VH or TRD, including PRP (range, 0-3 sessions; median, 0.5) or intravitreal anti-VEGF injections (range, 0-6; median, 1) during the interval between baseline imaging and the complication event. There were no statistically significant differences in baseline demographic, systemic, or clinical characteristics between eyes that developed complications and those that did not (Table 3). Widefield SS-OCTA derived metrics related to PVD staging and the number of RNV lesions per eye did not differ significantly between the two groups. However, eyes with complications showed significantly greater total and elevated RNV burden, whereas attached RNV did not differ significantly.

The median total RNV membrane area was 25.72 mm² in the complication group vs 1.33 mm² in the noncomplication group ($P = .006$), and the median total RNV vascular area was 9.72 mm² vs 0.76 mm², respectively ($P = .010$).

TABLE 2. Baseline Widefield Swept-Source OCT Angiography Characteristics

Parameters	Data
PVD staging	
Stage 0, eyes (%)	3 (16.7)
Stage 1, eyes (%)	7 (38.9)
Stage 2, eyes (%)	0 (0)
Stage 3, eyes (%)	7 (38.9)
Stage 4, eyes (%)	0 (0)
Vitrectomized eyes	1 (5.6)
RNVs	
NVD, n (%)	9 (7.8)
NVE, n (%)	106 (92.2)
RNV membrane area (mm^2), median (IQR)	0.26 (0.12-0.76)
RNV vascular area (mm^2), median (IQR)	0.18 (0.10-0.44)
No. of RNVs per eye, median (IQR)	5 (4-8)
No. of RNVs located within the arcades per eye, median (IQR)	2 (1-3)
No. of RNVs located in mid periphery per eye, median (IQR)	3 (2-7)
Total RNV membrane area per eye (mm^2), median (IQR)	3.35 (0.68-23.89)
Attached RNV membrane area per eye (mm^2), median (IQR)	2.20 (0.41-9.88)
Elevated RNV membrane area per eye (mm^2), median (IQR)	0.63 (0-2.09)
Total RNV vascular area per eye (mm^2), median (IQR)	1.87 (0.48-8.64)
Attached RNV vascular area per eye (mm^2), median (IQR)	1.18 (0.23-3.82)
Elevated RNV vascular area per eye (mm^2), median (IQR)	0.44 (0-1.16)

NVD = neovascularization of the optic disc; NVE = neovascularization elsewhere; PVD = posterior vitreous detachment; RNV = retinal neovascularization.

TABLE 3. Baseline Characteristics Between Eyes With and Without Complications

Parameters	Complications (+) ($n = 8$)	Complications (−) ($n = 10$)	*P*-value
Age, year	47.6 ± 14.6	52.5 ± 8.1	.381[b]
Sex			1.000[a]
Female	3 (37.5)	4 (40.0)	
Male	5 (62.5)	6 (60.0)	
Laterality			1.000[a]
Right	5 (62.5)	6 (60.0)	
Left	3 (37.5)	4 (40.0)	
Most recent HbA1c (%), median (IQR)	8.7 (7.4-10.5)	8.3 (7.5-10.5)	.965[c]
Duration of DM (years), median (IQR)	20 (13-22)	19 (16-23)	1.000[c]
DM Type			.608[a]
Type 1	3 (37.5)	2 (20.0)	
Type 2	5 (62.5)	8 (80.0)	
Presence of NVD	4 (50.0)	4 (40.0)	.671[a]
Treatment naïve	4 (50.0)	3 (30.0)	.630[a]
BCVA (logMAR), median (IQR)	0.06 (0-0.57)	0.04 (0-0.10)	.822[c]
History of hypertension, n (%)	3 (37.5)	5 (50.0)	.664[a]
Systolic blood pressure, mm Hg	135.9 ± 17.61	145.6 ± 15.89	.236[b]
Diastolic blood pressure, mm Hg	87.8 ± 11.30	90.3 ± 7.94	.582[b]
Follow-up days, median (IQR)	261 (241-340)	294 (231-335)	.656[c]

BCVA = best-corrected visual acuity; DM = diabetes mellitus; HbA1c = hemoglobin A1c; logMAR = logarithm of the minimum angle of resolution; NVD = neovascularization of the optic disc.

[a] Fisher's exact test.

[b] Independent *t*-tests.

[c] Mann–Whitney U test.

TABLE 4. Comparison of OCT Angiography Characteristics Between Eyes With and Without Complications

Parameters	Complications (+) ($n = 8$)	Complications (−) ($n = 10$)	*P*-value
PVD staging			1.000
Stage 0, eyes (%)	1 (12.5)	2 (20.0)	
Stage 1, eyes (%)	4 (50.0)	3 (30.0)	
Stage 2, eyes (%)	0 (0.0)	0 (0.0)	
Stage 3, eyes (%)	3 (37.5)	4 (40.0)	
Stage 4, eyes (%)	0 (0.0)	0 (0.0)	
Vitrectomized eyes	0 (0.0)	1 (10.0)	
No. of RNVs per eye, median (IQR)	7 (5-11)	4 (2-6)	.117[a]
Total RNV membrane area per eye (mm^2), median (IQR)	25.72 (3.56-32.88)	1.33 (0.54-3.31)	.006[a]
Attached RNV membrane area per eye (mm^2), median (IQR)	9.48 (1.88-24.46)	1.31 (0.35-3.31)	.076[a]
Elevated RNV membrane area per eye (mm^2), median (IQR)	5.13 (1.68-20.50)	0.10 (0.00-0.41)	.009[a]
Total RNV vascular area per eye (mm^2), median (IQR)	9.72 (1.86-15.17)	0.76 (0.26-1.93)	.010[a]
Attached RNV vascular area per eye (mm^2), median (IQR)	3.64 (0.96-10.73)	0.71 (0.23-1.86)	.076[a]
Elevated RNV vascular area per eye (mm^2), median (IQR)	2.69 (0.90-8.40)	0.05 (0.00-0.25)	.007[a]

PVD = posterior vitreous detachment; RNV = retinal neovascularization.
[a]Mann–Whitney U test.

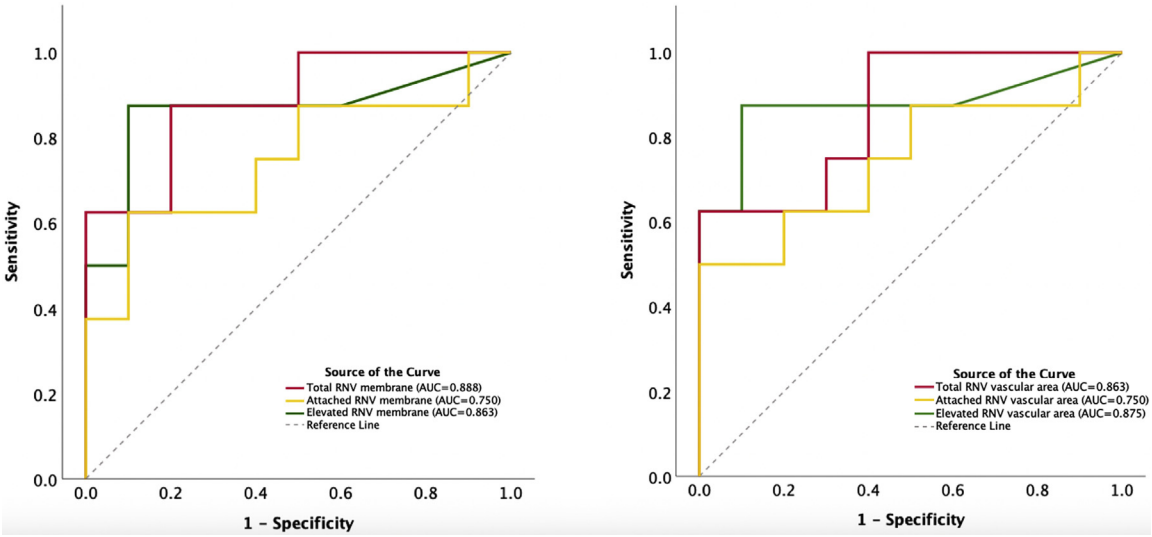

FIGURE 3. Receiver operating characteristic curves for identifying eyes at risk of complications. The red line represents the total RNV burden, the yellow line represents the attached RNV burden, and the green line represents the elevated RNV burden.

Elevated RNV membrane and vascular areas were also significantly greater in eyes with complications (membrane: 5.13 vs 0.10 mm², $P = .009$; vascular: 2.69 vs 0.05 mm², $P = .007$). Differences in attached RNV membrane and vascular areas showed trends but did not reach statistical significance (Table 4).

Receiver operating characteristic (AROC) curve analysis demonstrated good predictive performance of both total and elevated RNV parameters for identifying eyes at risk of developing complications (Figure 3). For RNV membrane area, total RNV demonstrated the highest performance with an AUC of 0.888, followed by elevated RNV (AUC = 0.863) and attached RNV (AUC = 0.750). For RNV vascular area, elevated RNV showed the highest AUC of 0.875, compared to 0.863 for total RNV and 0.750 for attached RNVs. Based on the Youden index, the optimal cutoff value for the total RNV membrane area was 3.40 mm², achieving a sensitivity of 87.5% and a specificity of 80.0% for identifying eyes at risk of complications in high-risk PDR.

DISCUSSION

This study demonstrated the utility of single-shot widefield SS-OCTA in quantifying elevated RNV in eyes with high-risk PDR for assessing the likelihood of developing VH or TRD. Most RNV lesions were located outside the arcades, and eyes with greater RNV burden were more likely to develop complications. These findings highlight the potential of topographic and tomographic RNV assessment using widefield OCTA as a noninvasive imaging biomarker to support individualized risk stratification and monitoring in high-risk PDR.

The pathophysiologic characteristics of RNV are key contributors to the development of VH, yet the underlying mechanisms remain incompletely understood.[5] Given that fibrovascular proliferations characteristically adhere to the vitreous framework and RNV are inherently fragile, vitreous contraction has been considered as a major factor predisposing to bleeding, particularly when extensive and tractional forces pull the lesions forward.[25] Previous studies have proposed various classification schemes to categorize RNV based on distinct morphological features.[26] Vaz-Pereira et al[13] used structural OCT to describe RNV subtypes as flat, forward, and tabletop based on their interaction with the posterior hyaloid and extent of anterior extension. Cui et al[14] have applied this morphologic classification to OCTA flow signal imaging and demonstrated that forward-type RNV carried a higher risk of VH development. However, in eyes with high-risk PDR, RNV morphologies often coexist, merge, and form complex proliferative networks, making it difficult to apply existing classification systems for quantitative tomographic analysis or clinical decision-making. Similarly, the number of RNV lesions alone may not accurately reflect the true neovascular burden.

In this study, we introduced a novel imaging biomarker framework that incorporates OCTA flow information to classify RNV lesions based on their spatial relationship with the vitreous status, categorizing them as either "attached" or "elevated." Notably, our findings demonstrate that elevated-type RNV, characterized by anterior extension along a separated hyaloid face and increased susceptibility to vitreoretinal traction, was significantly associated with subsequent VH and TRD events. Our result provides pathophysiologic support for previously proposed mechanisms implicating localized hyaloid traction and contraction of fibrovascular membrane in the pathogenesis of VH.[27] This approach provides a more clinically meaningful representation of RNV burden by delineating the tomographic complexity of RNV, offering valuable biomarkers for risk stratification in high-risk PDR.

High-risk PDR frequently manifests as extensive, confluent proliferative vessels involving both the posterior pole and mid-periphery. *En face* OCTA with VRI slabs enables visualization of the topographic features of RNV lesions[10,28]; however, frequent segmentation errors require extensive manual correction to accurately isolate pathologic flow signals.[29] Sustained ischemia and chronic inflammation promote excessive VEGF-driven angiogenesis and TGF-β–mediated fibrotic remodeling, leading to the formation of fibrovascular membrane composed of abnormal vessels intertwined with proliferative fibrotic membranes originating from the retinal surface.[30] Multidirectional tractional forces contribute to retinal distortion, loss of integrity and irregular elevations of the ILM, and indistinct pathological lesion margins. Some RNV lesions remain tightly adherent to the retina, making detection and boundary delineation especially challenging.[29] Furthermore, normal major retinal vessels, from which many RNV lesions originate, protrude from otherwise flat surface of the retina, which frequently results in erroneous inclusion of these vessels in the vitreous slab in rule-based segmentation. Accurate segmentation is required to represent the full extent of neovascular burden.

To address these challenges, we developed a deep learning-based segmentation algorithm designed to identify RNV in widefield SS-OCTA and apply it to the study datasets.[20] This automated tool helped us successfully detect RNV and provided several advantages. Unlike traditional VRI slab approaches, which are constrained by a fixed offset from the ILM and may miss anteriorly extended RNV along the detached hyaloid face beyond the slab boundary, our method captures RNV throughout the imaged vitreous cavity. By integrating both structural OCT and OCTA information from a single scan, the algorithm can also efficiently detect new-onset RNV lesions across diverse pathological stages of advanced PDR. Moreover, it eliminates the need for manual subtraction of superficial retinal vessels or noise removal, ensuring consistent RNV segmentation and reproducible, repeatable quantitative analysis.

Beyond prognostic risk stratification, this biomarker framework may also provide useful guidance for the management of advanced PDR. Medically, eyes with a large total RNV burden may benefit from earlier or more intensive treatment, and clinicians may consider concomitant PRP and anti-VEGF therapy to reduce the risk of ongoing neovascular progression.[31,32] An *en face* elevated-RNV segmentation map may also help guide PRP delivery by identifying areas where laser application could precipitate abrupt fibrovascular contraction, thereby reducing the risk of post-laser adverse effects. Close surveillance is warranted following anti-VEGF therapy, given the potential for crunch syndrome,[33] particularly in eyes with extensive elevated RNV threatening the macula. Together, these OCTA-derived biomarkers may assist clinicians in optimizing therapeutic sequencing and determining follow-up intervals according to individualized risk profiles.

In eyes with diabetic TRD, widefield SS-OCTA has been shown to reliably capture the clinically relevant feature of

fibrovascular proliferation tractional membranes, both pre- and postoperatively.[12] Preoperative assessment is important, as identification of the optimized dissection plane is essential to minimize the risk of iatrogenic retinal breaks and intraoperative hemorrhage.[34] On FA, fibrovascular membranes often appear hyperfluorescent with leakage, making it challenging to delineate the true margins, vascularity, and degree of elevation of fibrovascular membranes from the retinal surface. In contrast, OCTA enables precise tomographic visualization of fibrovascular proliferation and their spatial relationship with the posterior hyaloid, allowing the surgeon to differentiate vascularized from avascular traction sites, evaluate the extent of vitreoretinal adhesion, and localize focal vitreous detachment planes that can guide safer dissection. If a preoperative *en face* RNV segmentation map is available, integrating both attached and elevated information relative to the retinal surface, the surgeon could more efficiently identify the optimal surgical plane for segmentation or delamination, while reducing potential complications.

Accurate interpretation of the posterior vitreous status is critical in eyes with PDR, as vitreoschisis can mimic posterior vitreous detachment and lead to misidentification of the posterior hyaloid face. Both histopathologic and imaging studies have demonstrated that diabetic vitreopathy often results in anomalous posterior vitreous separation, producing split layers of the posterior cortical vitreous, a pathology termed vitreoschisis.[35-37] On OCT, vitreoschisis typically appears as two or more distinct hyperreflective membranes on B-scans, indicating splitting of the posterior vitreous cortex, with the more anterior membrane falsely mimicking a detached hyaloid face.[13,37] Therefore, careful volumetric or raster scan review is essential, rather than relying on a single B-scan.

This study has several limitations that should be considered. First, the sample size was small. However, due to the severity and complexity of high-risk PDR, our analysis of over a hundred RNV lesions provides representative insights into the disease characteristics. Larger multicenter prospective studies are warranted to validate these findings and improve generalizability. Second, although this was a longitudinal study, it was only prospective in terms of baseline enrollment. Follow-up was conducted as part of routine clinical care, with a nonstandardized treatment exposure across the cohort. Variability in treatment timing, intensity, and adherence may have influenced clinical outcomes and may confound associations between baseline RNV morphology and complication risk. Nonetheless, all patients were managed by senior retinal specialists at the same academic medical center, following the American Academy of Ophthalmology Preferred Practice Patterns for high-risk PDR.[5] Third, the performance of current SS-OCTA instruments is limited by media opacity. As a result, we enrolled high-risk PDR with prior VH within the past 3 months only if hemorrhage had cleared sufficiently for adequate imaging. Thus, when interpreting our results in clinical practice or comparing them with other studies, potential differences in enrollment criteria should be considered. Nonetheless, defining new or recurrent complication event as the endpoint reflects real-world clinical conditions and addresses the need for risk stratification. Additionally, image distortion due to the curved surface of the peripheral retina remains a confounding factor, potentially impacting the calculation of peripheral RNV parameters. To address this, we used lesion counts for topographic information presentation and performed per-eye analyses for quantitative assessments of RNV membrane and vascular area. Finally, in advanced or involuted PDR, complications may arise from tractional forces on shrinkage fibrovascular membrane, including fibrosis-related contraction after laser treatment or the crunch phenomenon following anti-VEGF therapy.[33] Although we did not analyze these mechanisms in relation to our outcomes, they are recognized traction-prone contributors to vision-threatening complications.

CONCLUSION

In conclusion, elevated RNV burden measured with wide-field SS-OCTA predicts vision-threatening complications in high-risk PDR. These quantitative imaging biomarkers offer objective risk stratification and may complement current clinical staging of PDR. Further studies incorporating follow-up OCTA metrics and treatment response are needed to validate these findings and confirm their clinical utility.

CREDIT AUTHORSHIP CONTRIBUTION STATEMENT

AN-LUN WU: Writing – original draft, Methodology, Investigation, Formal analysis. **JINYI HAO:** Visualization, Investigation. **LIQIN GAO:** Writing – review & editing, Methodology, Formal analysis. **YUKUN GUO:** Visualization, Investigation. **TRISTAN T. HORMEL:** Writing – review & editing, Validation. **CHRISTINA J. FLAXEL:** Writing – review & editing, Data curation. **MERINA THOMAS:** Writing – review & editing, Data curation. **BENJAMIN K. YOUNG:** Writing – review & editing, Data curation. **STEVEN T. BAILEY:** Writing – review & editing, Investigation, Data curation. **DONG-WOUK PARK:** Writing – review & editing, Methodology, Data curation. **YALI JIA:** Writing – review & editing, Validation, Methodology, Investigation. **THOMAS S. HWANG:** Writing – review & editing, Validation, Supervision, Investigation, Data curation, Conceptualization.

Funding/Support: This work was supported by grants from National Institutes of Health (R01 EY 036429, R01 EY035410, R01 EY024544, R01 EY027833, R01 EY031394, R43EY036781, P30 EY010572, T32 EY023211, UL1TR002369); the Jennie P. Weeks Endowed Fund; the Malcolm M. Marquis, MD Endowed Fund for Innovation; Unrestricted Departmental Funding Grant and Dr. H. James and Carole Free Catalyst Award from Research to Prevent Blindness (New York, NY); Edward N. & Della L. Thome Memorial Foundation Award, and the Bright Focus Foundation (G2020168, M20230081). The funding source had no role in the design and conduct of the study; collection, management, analysis, and interpretation of the data; preparation, review, or approval of the manuscript; and decision to submit the manuscript for publication.
Financial Disclosures: Yukun Guo: Optovue/Visionix (P), Genentech/Roche (P, R), Ifocus Imaging (P); Tristan.T. Hormel: Ifocus Imaging (I); Yali Jia: Optovue/Visionix (P, R), Genentech/Roche (P, R, F), Ifocus Imaging (I, P), Optos (P), Boeringer Ingelheim (C), Kugler (R); Steven T. Bailey: Optovue/Visionix (F). These potential conflicts of interest have been reviewed and managed by OHSU. Other authors declare no conflicts of interest related to this article.

REFERENCES

1. Shaw JE, Sicree RA, Zimmet PZ. Global estimates of the prevalence of diabetes for 2010 and 2030. *Diabetes Res Clin Pract*. 2010;87(1):4–14. doi:10.1016/j.diabres.2009.10.007.
2. Gross JG, Glassman AR, Liu D, et al. Five-year outcomes of panretinal photocoagulation vs intravitreous ranibizumab for proliferative diabetic retinopathy: a randomized clinical trial. *JAMA Ophthalmol*. 2018;136(10):1138–1148. doi:10.1001/jamaophthalmol.2018.3255.
3. Early treatment Diabetic Retinopathy Study design and baseline patient characteristics. ETDRS report number 7. *Ophthalmology*. 1991;98(5 Suppl):741–756. doi:10.1016/s0161-6420(13)38009-9.
4. Tsuboi K, Mazloumi M, Guo Y, et al. Early sign of retinal neovascularization evolution in diabetic retinopathy: a longitudinal OCT angiography study. *Ophthalmol Sci*. 2024;4(2):100382. doi:10.1016/j.xops.2023.100382.
5. Lim JI, Kim SJ, Bailey ST, et al. Diabetic retinopathy preferred practice pattern(R). *Ophthalmology*. 2025. doi:10.1016/j.ophtha.2024.12.020.
6. Khurana RN, Wang JC, Zhang S, Li C, Lum F. Loss to follow up in patients with proliferative diabetic retinopathy treated with Anti-VEGF therapy and/or panretinal photocoagulation in the United States. *Ophthalmol Retina*. 2024;8(10):953–961. doi:10.1016/j.oret.2024.04.016.
7. The Diabetic Retinopathy Study Research Group. Photocoagulation treatment of proliferative diabetic retinopathy. Clinical application of Diabetic Retinopathy Study (DRS) findings, DRS Report Number 8. *Ophthalmology*. 1981;88(7):583–600.
8. Bressler SB, Beaulieu WT, Glassman AR, et al. Factors associated with worsening proliferative diabetic retinopathy in eyes treated with panretinal photocoagulation or ranibizumab. *Ophthalmology*. 2017;124(4):431–439. doi:10.1016/j.ophtha.2016.12.005.
9. Xie X, Atkins E, Lv J, et al. Effects of intensive blood pressure lowering on cardiovascular and renal outcomes: updated systematic review and meta-analysis. *Lancet*. 2016;387(10017):435–443. doi:10.1016/S0140-6736(15)00805-3.
10. Jia Y, Bailey ST, Hwang TS, et al. Quantitative optical coherence tomography angiography of vascular abnormalities in the living human eye. *Proc Natl Acad Sci U S A*. 2015;112(18):E2395–E2402. doi:10.1073/pnas.1500185112.
11. Jia Y, Tan O, Tokayer J, et al. Split-spectrum amplitude-decorrelation angiography with optical coherence tomography. *Opt Express*. 2012;20(4):4710–4725. doi:10.1364/OE.20.004710.
12. Russell JF, Scott NL, Townsend JH, et al. Wide-field swept-source optical coherence tomography angiography of diabetic tractional retinal detachments before and after surgical repair. *Retina*. 2021;41(8):1587–1596. doi:10.1097/IAE.0000000000003146.
13. Vaz-Pereira S, Dansingani KK, Chen KC, Cooney MJ, Klancnik Jr JM, Engelbert M. Tomographic relationships between retinal neovascularization and the posterior vitreous in proliferative diabetic retinopathy. *Retina*. 2017;37(7):1287–1296. doi:10.1097/IAE.0000000000001336.
14. Cui Y, Zhu Y, Lu ES, et al. Widefield swept-source OCT angiography metrics associated with the development of diabetic vitreous hemorrhage: a prospective study. *Ophthalmology*. 2021;128(9):1312–1324. doi:10.1016/j.ophtha.2021.02.020.
15. Itakura H, Kishi S, Li D, Akiyama H. Observation of posterior precortical vitreous pocket using swept-source optical coherence tomography. *Invest Ophthalmol Vis Sci*. 2013;54(5):3102–3107. doi:10.1167/iovs.13-11769.
16. Hamada M, Hirai K, Wakabayashi T, et al. Practical utility of widefield OCT angiography to detect retinal neovascularization in eyes with proliferative diabetic retinopathy. *Ophthalmol Retina*. 2024;8(5):481–489. doi:10.1016/j.oret.2023.11.009.
17. Hormel TT, Liang GB, Wei X, et al. Visualizing features with wide-field volumetric OCT angiography. *Opt Express*. 2024;32(6):10329–10347. doi:10.1364/OE.510640.
18. Jia Y, Hormel TT, Hwang TS, et al. Widefield OCT angiography. *Prog Retin Eye Res*. 2025;107:101378. doi:10.1016/j.preteyeres.2025.101378.
19. Wu AL, Guo Y, Hormel TT, et al. Wide-field OCTA quantified peripheral nonperfusion areas predict the risk of subclinical neovascularization. *Eye (Lond)*. 2025;39(12):2467–2473. doi:10.1038/s41433-025-03891-2.
20. Hao J, Wang J, Tsuboi K, et al. Robust detection of retinal neovascularization in widefield optical coherence tomography. arXiv preprint arXiv:2511.17744. 2025.
21. Early Treatment Diabetic Retinopathy Study Research Group. Grading diabetic retinopathy from stereoscopic color fundus photographs—an extension of the modified airlie house classification. ETDRS report number 10. *Ophthalmology*. 1991;98(5 Suppl):786–806.
22. Uchino E, Uemura A, Ohba N. Initial stages of posterior vitreous detachment in healthy eyes of older persons evaluated by optical coherence tomography. *Arch Ophthalmol*. 2001;119(10):1475–1479. doi:10.1001/archopht.119.10.1475.

23. Kraker JA, Kim JE, Koller EC, George JC, Hwang ES. Standard 6-mm compared with widefield 16.5-mm OCT for staging of posterior vitreous detachment. *Ophthalmol Retina*. 2020;4(11):1093–1102. doi:10.1016/j.oret.2020.05.006.
24. Zhang M, Wang J, Pechauer AD, et al. Advanced image processing for optical coherence tomographic angiography of macular diseases. *Biomed Opt Express*. 2015;6(12):4661–4675. doi:10.1364/BOE.6.004661.
25. Davis MD. Diabetic retinopathy. A clinical overview. *Diabetes Care*. 1992;15(12):1844–1874. doi:10.2337/diacare.15.12.1844.
26. Nouri H, Abtahi SH, Mazloumi M, Samadikhadem S, Arevalo JF, Ahmadieh H. Optical coherence tomography angiography in diabetic retinopathy: a major review. *Surv Ophthalmol*. 2024;69(4):558–574. doi:10.1016/j.survophthal.2024.03.004.
27. El Annan J, Carvounis PE. Current management of vitreous hemorrhage due to proliferative diabetic retinopathy. *Int Ophthalmol Clin*. 2014;54(2):141–153. doi:10.1097/IIO.0000000000000027.
28. Hwang TS, Jia Y, Gao SS, et al. Optical coherence tomography angiography features of diabetic retinopathy. *Retina*. 2015;35(11):2371–2376. doi:10.1097/IAE.0000000000000716.
29. Lu ES, Cui Y, Le R, et al. Detection of neovascularisation in the vitreoretinal interface slab using widefield swept-source optical coherence tomography angiography in diabetic retinopathy. *Br J Ophthalmol*. 2022;106(4):534–539. doi:10.1136/bjophthalmol-2020-317983.
30. Cai J, Boulton M. The pathogenesis of diabetic retinopathy: old concepts and new questions. *Eye (Lond)*. 2002;16(3):242–260. doi:10.1038/sj.eye.6700133.
31. The Diabetic Retinopathy Study Research Group. Indications for photocoagulation treatment of diabetic retinopathy: diabetic retinopathy study report no. 14. *Int Ophthalmol Clin*. 1987;27(4):239–253. doi:10.1097/00004397-198702740-00004.
32. Martinez-Zapata MJ, Salvador I, Marti-Carvajal AJ, et al. Anti-vascular endothelial growth factor for proliferative diabetic retinopathy. *Cochrane Database Syst Rev*. 2023;3(3):CD008721. doi:10.1002/14651858.CD008721.pub3.
33. Tan Y, Fukutomi A, Sun MT, Durkin S, Gilhotra J, Chan WO. Anti-VEGF Crunch syndrome in proliferative diabetic retinopathy: a review. *Surv Ophthalmol*. 2021;66(6):926–932. doi:10.1016/j.survophthal.2021.03.001.
34. Chen SN, Chen SJ, Wu TT, Wu WC, Yang CH, Yang CM. Refining vitrectomy for proliferative diabetic retinopathy. *Graefes Arch Clin Exp Ophthalmol*. 2023;261(12):3659–3670. doi:10.1007/s00417-023-06134-w.
35. Schwatz SD, Alexander R, Hiscott P, Gregor ZJ. Recognition of vitreoschisis in proliferative diabetic retinopathy. A useful landmark in vitrectomy for diabetic traction retinal detachment. *Ophthalmology*. 1996;103(2):323–328. doi:10.1016/s0161-6420(96)30697-0.
36. Chu TG, Lopez PF, Cano MR, et al. Posterior vitreoschisis. An echographic finding in proliferative diabetic retinopathy. *Ophthalmology*. 1996;103(2):315–322. doi:10.1016/s0161-6420(96)30698-2.
37. Muqit MM, Stanga PE. Swept-source optical coherence tomography imaging of the cortical vitreous and the vitreoretinal interface in proliferative diabetic retinopathy: assessment of vitreoschisis, neovascularisation and the internal limiting membrane. *Br J Ophthalmol*. 2014;98(7):994–997. doi:10.1136/bjophthalmol-2013-304452.