International Journal of Colorectal Disease (2025) 40:224
https://doi.org/10.1007/s00384-025-05010-9

REVIEW

Taiwan society of colon and rectal surgeons' consensus on the management of hemorrhoidal disease

Tsung-Kun Chang[1,2,3] · Tao-Wei Ke[4] · Pao-Shiu Hsieh[5] · Shih-Ching Chang[6] · Wan Hsiang Hu[7] · Ching-Wen Huang[1,9] · Feng-Fan Chiang[11,12] · Hsiang-Lin Tsai[1,9] · Jin-Tung Liang[13] · Chien-Kuo Liu[8] · Jaw-Yuan Wang[1,2,9,10]

Received: 7 October 2024 / Accepted: 24 September 2025
© The Author(s) 2025

Abstract

Background Establishing statements backed by strong scientific evidence with the intention of standardizing and guiding Hemorrhoidal Disease (HD) diagnosis and treatment in both the general population and in specific patient groups is the aim of this consensus.

Methods A consensus panel of 11 surgical specialists from the Taiwan Society of Colon and Rectal Surgeons was convened from July 2023 to October 2024. Using a modified Delphi methodology, the panel addressed the diagnosis, treatment, prevention, and special situations of HD. Experts responded to a pre-meeting survey, and a literature search of English-language studies on clinical judgment, pharmacologic treatments, and surgical interventions was conducted. Draft statements were developed, discussed, and refined during the first meeting in July 2023. In April 2024, the panel reviewed updated studies, finalized recommendations, and voted anonymously. An online meeting in October 2024 validated and approved the recommendations, which were graded using the GRADE system.

Results A total of 9 consensus statements have been developed covering the diagnosis and management of HD. The general principle of this consensus statement is to follow most international guidelines. To tailor the local clinical practice, we also discussed the alternative treatment strategy for sclerotherapy, the use of traditional herbs/medicines, and the consideration of CRC screening test.

Conclusions These suggestions may represent a positive start toward recognized guidelines for improved hemorrhoidal disease treatment for all Taiwan healthcare professionals. As the first point of contact with patients, general practitioners, family medicine physicians, young surgeons, and pharmacists will find them to be quite valuable.

Keywords Hemorrhoidal disease · Treatment · Medicine · Surgery · Consensus

Introduction

Hemorrhoidal disease (HD) is the most common pathology of the anorectal region in adults worldwide [1, 2]. It is associated with major socioeconomic and medical problems. The incidence of HD varies widely between countries, depending on the documentation method. Reports from the UK suggest that 13% to 36% of the general population have hemorrhoids [3]. Similarly, reports from the USA in 1990 suggest that >10 million individuals, representing 4.4% of the entire population, have HD [1]. Many studies have been conducted worldwide to determine the incidence of and contributing factors to HD. Among all countries, Australia has been reported to have the highest rate of HD (38.93%), followed by Israel (16%) and South Korea (14.4%) [4, 5]. In a study of data obtained from the Korea National Health and Nutrition Examination Survey, 14.4% of the respondents claimed to have HD, with 7.2% reporting a confirmed diagnosis [6]. An epidemiological study examined HD in Taiwan by using data from the National Health Insurance Research Database, which contains the claims data of 1 million patients randomly selected in 2000, 2005, and 2010. The results indicated that 1.37% to 2.01% of Taiwanese adults have HD, with approximately 30% of them receiving surgical treatment [7]. Internal hemorrhoids may be identified in up to 86% of patients undergoing proctoscopy, although most are asymptomatic [8]. HD may be asymptomatic or may present with a wide range of clinical symptoms, including rectal bleeding. The majority of patients with HD are asymptomatic and do not require surgical treatment. The

Extended author information available on the last page of the article

Published online: 30 October 2025

potential risk factors for HD are male sex, age between 45 and 65 years, low-fiber diet, stress, depression, high body mass index, abdominal obesity, pregnancy, prolonged sitting, and high intra-abdominal pressure [9].

Due to the lack of developed consensus guidelines for the management of HD in Taiwan, we aim to make a positive start toward recognized guidelines for improved management of HD for all healthcare professionals in Taiwan. This consensus guideline is an expert consensus tailored to local clinical practice based on current scientific evidence.

Methods

The consensus panel, consisting of 11 surgical specialists from the Taiwan Society of Colon and Rectal Surgeons, was convened from July 2023 to October 2024 using a modified Delphi methodology to provide recommendations that ensure the best possible diagnosis and treatment of HD in Taiwan (Fig. 1). Experts responded to a pre-meeting survey on four topics, including diagnosis, treatment, prevention, and special situations of HD, and then, the survey results were discussed at the first consensus meeting. Statements were drafted based on expert feedback and a literature search of electronic medical databases (including PubMed, Cochrane Review Library) conducted in July 2023 for relevant studies published after 2010. Keyword combinations and search filters are listed in Supplementary Table 1. We conducted a literature search for original English-language studies on clinical judgment, efficacy of pharmacologic treatments, and effectiveness of surgical treatments published between 2010 and 2023.

The included studies were used to draft statements that were discussed and modified by the experts during the first consensus meeting in July 2023. In the second consensus meeting, experts discussed the statements, made recommendations, reviewed newly published studies, and voted anonymously in April 2024.

A 5-point Likert scale was used to record the level of expert agreement for each statement: a, fully agree; b, agree with minor reservations; c, agree with major reservations; d, disagree with reservations; e, disagree completely. Consensus was reached when a statement received agreement (a, b, or c) from ≥75% of the expert group. A strong recommendation was given when a statement received ≥90% agreement.

An online meeting was then held in October 2024 to validate and approve the recommendations. The recommendations were defined and graded based on the current levels of evidence and in accordance with the GRADE system (Grading of Recommendations, Assessment, Development and Evaluation) [10].

Result

A total of 9 consensus statements were formed.

Statement 1. The following are the recommendations for diagnosing HD:

- Anoscopy/digital rectal examination should be used to determine the type and degree of HD (No GRADE, Experts' opinion)
- The signs and symptoms of HD should be examined (No GRADE, Experts' opinion)

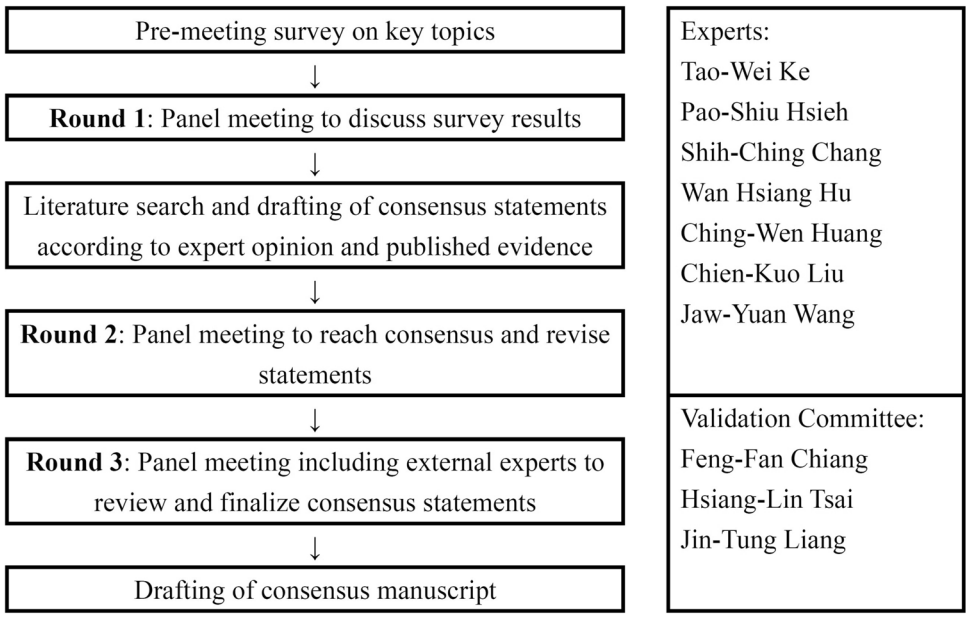

Fig. 1 Flow diagram of the consensus forming process and members of the expert consensus guidelines meeting on hemorrhoidal disease

- In addition to physical examination, the patient's medical history should be obtained (No GRADE, Experts' opinion)

(100% agreement for all sub-items)

To achieve positive patient outcomes, HD should be appropriately diagnosed and managed. Hemorrhoids can be divided into three types based on their location in relation to the dentate line: internal (above or proximal), external (below or distal), and mixed [2]. Internal hemorrhoids are further divided into four grades based on the degree of prolapse from the anal canal [11]. Patients with hemorrhoids often present with bleeding, swelling, prolapse, pain, and itching, with anemia observed in severe cases.

HD is typically diagnosed by taking the patient's medical history and performing a physical examination. Performing an appropriate physical examination and additional diagnostic workup is essential before attributing painless rectal bleeding to HD.

The first step in diagnosing HD involves taking the patient's medical history, identifying symptoms suggestive of HD, and examining risk factors such as pregnancy, low-fiber diet, constipation, and sedentary lifestyle. Reviewing the patient's treatment history can provide valuable insights into their symptoms and general health. History-taking usually involves questions regarding the patient's food and bowel habits. In addition, the patient's frequency of exercise and drug use and whether any blood relatives of the patient have colon polyps or cancer can be inquired. A history of chronic or uncontrolled portal hypertension in a patient can differentiate between HD and anorectal varices. In addition, a history of inflammatory bowel disease (IBD) and any symptoms associated with decreased anal continence can inform the optimal course of action.

Physical examination should be conducted to rule out other anorectal diseases and confirm HD. Physical examination should include anorectal digital examination, perianal tissue inspection, and evaluation of the degree of hemorrhoidal prolapse during strengthening. Anoscopy could also be conducted to identify internal hemorrhoids or anorectal pathology during the examination. After patients experience painless rectal bleeding, and anoscopy examination reveals unremarkable findings, diagnostic colonoscopy could be performed as a standard procedure.

Acute lower gastrointestinal bleeding is a common complication of HD [12]. In addition to being a sign of colon cancer, rectal bleeding is a common early sign of diverticular disease, angiodysplasia, IBD, and other colorectal conditions. Because performing hemorrhoid surgery on patients with IBD or colorectal cancer (CRC) can be devastating, colonoscopy could be indicated in patients who experience rectal bleeding. In addition, due to the high incidence of CRC in Taiwan, CRC screening tests should be considered in patients with unusual clinical presentations, such as bowel habit changes, refractory or unusual bleeding sites, abdominal pain, or body weight loss.

Statement 2. The following are the recommendations for dietary and lifestyle modifications for patients with HD:

- Dietary and lifestyle modifications could be the primary treatment strategies applied for achieving regular defecation with soft stools (Quality of evidence: Moderate; Recommendation: Strong)
- Active prevention and early intervention should be the main treatment strategies for patients with HD (No GRADE, Experts' opinion)
- Patients' preferences and characteristics could be considered throughout the treatment and decision-making processes (No GRADE, Experts' opinion)

(100% agreement for all sub-items)

Depending on its grade, HD can be treated with either invasive surgical procedures or noninvasive medical strategies. Noninvasive medical strategies cannot reverse the underlying structural changes in hemorrhoidal tissue, and invasive surgical procedures are associated with high risks of complications and recurrence. In addition, if not appropriately treated, the severity and symptoms of HD often worsen over time. Therefore, the basic treatment approach for HD involves active prevention and early intervention, including components related to dietary modifications, medical attention, and changes to potential risk factors.

HD is influenced by sociodemographic factors such as age, sex, socioeconomic status, and educational level [13]. Many other factors also contribute to the development of HD, such as family history of HD, extended straining, delayed evacuation, constipation, delayed bowel movement, persistent cough, dietary habits, insufficient water intake, lifestyle habits, and overweight [14, 15]. For patients with HD, their preferences and characteristics should be accounted for during treatment and decision-making.

For any grade of HD, lifestyle modifications should be recommended as the main treatment strategy and as a preventative measure against exacerbation. These modifications include returning to a normal diet, eating more foods rich in dietary fibers, drinking sufficient water every day, refraining from lifting heavy objects, and adopting a sedentary lifestyle. Unhealthy lifestyle habits, such as drinking, eating spicy food or nuts, standing and walking for more than 4 h, spending excessive amounts of time on the toilet seat, and irregular defecation, can increase the risk of HD [16]. One key goal of the conservative treatment of HD is to maintain a balanced diet with sufficient fiber

and fluid intake for improving the consistency of stools. Recommendations for lifestyle modifications should be provided to each patient during the treatment course, and these recommendations can also mitigate the risk of recurrence in case additional intervention is required.

Currently, dietary modifications and increased fiber intake are recommended as general guidelines for the conservative treatment and prevention of HD. Alonso-Coello et al. [17] reported that consuming diets rich in fibers is associated with a reduction of 50% in the clinical symptoms of HD. However, consuming diets rich in fibers has no effect on patients with grade III or IV hemorrhoids and prolapse [18].

Statement 3. The following are the recommendations for the medical treatment of HD:

- Conservative treatment should be considered for all grades of HD, whereas surgery should be considered for grade III or IV internal HD (Quality of evidence: Moderate; Recommendation: Strong)
- Common over-the-counter topical medications could be used to provide temporary relief for HD (Quality of evidence: Low; Recommendation: Weak)
- Micronized purified flavonoid fractions (MPFFs) could be used to rapidly ameliorate the symptoms of HD (Quality of evidence: Moderate; Recommendation: Moderate)

(100% agreement for all sub-items)

HD can cause mild symptoms, ephemeral symptoms, or severe persistent symptoms. Treatment is not required if the hemorrhage is not symptomatic. Generally, the clinical treatment provided for HD depends on its severity. Specifically, patients with grade I or II internal HD could receive conservative treatment, whereas patients with grade III or IV internal HD could receive radical surgical treatment. Treatment plans range from simple conservative measures to medical therapy, in-office procedures, and ultimately surgical treatment, depending on the severity of symptoms, grade of HD, patient age, and comorbidities. In terms of medical care, irritation and pain can be temporarily relieved by using creams and suppositories containing astringents, analgesics, and steroids.

Sitting in a warm sitz bath at 40 to 42 °C for 3 min is a conventional and often recommended treatment for several anal conditions, including HD [19]. Despite the positive effects of this treatment approach, few randomized controlled trials have determined its effects on pain associated with HD.

HD can be topically treated with ointments, creams, or rectal suppositories. Topical treatments primarily include local anesthetics, corticosteroids, antibiotics, and anti-inflammatory medications, which ameliorate symptoms. Despite its promising effects, topical therapy is not sufficiently supported by scientific research [15]. Anti-inflammatory suppositories are often used to treat HD, primarily because inflammation causes pain, perianal skin irritation, and ultimately bleeding [10, 11, 20]. However, their effectiveness for treating HD remains to be confirmed [8–11].

Flavonoids are orally administered herbal drugs that have anti-inflammatory properties, and they can increase vascular tone, improve lymphatic drainage, and stabilize capillary permeability. Phlebotonics such as MPFFs are primarily used for the management of HD. These medications mitigate the risk of recurrence because they address the metabolic aspects of chronic venous insufficiency associated with HD [21]. In clinical practice, MPFFs consisting of 90% diosmin and 10% hesperidin are the most commonly used. Their small size (less than 2 μm) facilitates their rapid absorption. A recent clinical trial demonstrated that MPFFs are effective against chronic venous diseases and hemorrhoid symptoms. The trial obtained positive outcomes in patients with all grades of HD who received MPFF-based treatment before irreversible degenerative changes in their hemorrhoidal plexus ligaments [22]. In a recent meta-analysis for a wide variety of phlebotonics, including MPFFs, for the treatment of HD, phlebotonics were associated with statistically significant improvements in bleeding and symptom management of acute HD and in bleeding after hemorrhoidectomy [23]. Multiple randomized controlled trials have indicated that MPFFs have positive effects on pain, tenesmus, pruritus, and bleeding after hemorrhoidectomy [19, 24].

Traditional herbal medicines are widely available as over-the-counter drugs in Asian countries. Huai Hua San is a common traditional Chinese medicine used to regulate blood components, clear the intestine, and stop bleeding. It is widely used in clinical settings to treat diseases such as HD, colitis, or other fecal and blood-borne diseases [25]. Bromelain is a cysteine protease found in pineapples. Because of its anti-inflammatory properties, it is often used for the treatment of HD and ulcerative colitis [26, 27]. In short, traditional herbs/medicines may relieve certain patients' hemorrhoidal symptoms temporarily, but long-term efficacy and safety lack evidence from large-scale randomized clinical trials. The use of traditional herbs/medicines in clinical practice should be done with caution.

Statement 4. The following are the recommendations for the prevention of HD recurrence:

- The prevention of HD recurrence hinges on the avoidance of constipation and the engagement in physical activity (Quality of evidence: Moderate to High; Recommendation: Strong)
- MPFFs are effective in reducing the risk of HD recurrence (Quality of evidence: Moderate to High; Recommendation: Moderate)

(100% agreement for all sub-items)

Decreasing the likelihood of constipation can prevent the recurrence of HD and can alleviate the current discomfort associated with HD. The ingestion of foods that are rich in dietary fiber and an adequate intake of water are fundamental for the mitigation of the risk of recurrent HD and for the enhancement of bowel function.

For patients with HD, the primary goal of engaging in physical activity is to promote regular bowel movements, improve circulation, and strengthen the muscles in the pelvic area and lower back. Insufficient physical activity may increase the risk of constipation and thereby adversely affect the current HD, which presumably leads to its recurrence.

In a meta-analysis comparing phlebotonics with no therapy or placebo, the risk of recurrence was statistically significantly lower for patients receiving MPFFs [28].

Statement 5. The following are the opinions of experts regarding different procedures and surgeries.

Statement 5-1: Choice of outpatient procedures

- If a patient with symptomatic HD does not respond to conservative treatment, outpatient surgical procedures should be considered before surgical treatment (No GRADE, Experts' opinion)
- The choice of the outpatient surgical procedure primarily depends on local availability, physician experience, and patient preference (No GRADE, Experts' opinion)
- RBL is effective and safe for the majority of patients with grade I to III internal hemorrhoids (Quality of evidence: Moderate to High; Recommendation: Strong)
- RBL is relatively contraindicated in patients with coagulopathy, a compromised immune system, or portal hypertension (Quality of evidence: High; Recommendation: Strong)
- Outpatient procedures would not be considered for patients with grade IV internal hemorrhoids (No GRADE, Experts' opinion)

(100% agreement for all sub-items)

The common outpatient procedures performed for internal hemorrhoids are RBL, bipolar diathermy (Bicap, HET bipolar system), laser photocoagulation, infrared coagulation, sclerotherapy, and cryosurgery. The choice of the procedure primarily depends on local availability.

For patients with grade I, II, or III internal hemorrhoids, RBL is recommended because it is more effective and involves fewer treatments than sclerotherapy and infrared coagulation [29, 30]. For patients on anticoagulant or antiplatelet drugs, patients with a compromised immune system, and patients with portal hypertension, sclerotherapy is recommended, if available, because it is associated with a lower risk of delayed bleeding compared with RBL [9]. Surgical suture ligation may be considered as an alternative to sclerotherapy, if it is unavailable.

RBL is a commonly used technique because it is effective [29–33], inexpensive, and easy to perform, and it is rarely associated with severe complications [32, 34]. If multiple sessions of RBL are required, repeat banding may be performed at intervals > 14 days, so that any swelling or ulceration can subside. The most common complication of RBL is pain, which occurs in approximately 8% of cases [32, 34, 35]. Other complications include delayed hemorrhage, hemorrhoidal thrombosis, local infection, and sepsis [36–38].

In laser hemorrhoidoplasty, a laser is used to coagulate the blood vessels in hemorrhoids, leading to their shrinkage. This technique can be used for patients with grade II and III HD, and it is associated with minor postoperative pain and minimal perianal wounding, generating negligible postoperative discomfort [39]. When laser hemorrhoidoplasty is used to treat patients with grade IV hemorrhoids, additional caution should be exercised in terms of postoperative complications [40]. In addition, the external part of the hemorrhoids may still need to be surgically removed after laser therapy. In summary, laser hemorrhoidoplasty offers a minor advantage over other approaches in terms of postoperative pain and wound healing; a disadvantage is the expensive equipment required for laser hemorrhoidoplasty.

The HET Bipolar Ligator System uses bipolar energy to treat grade I or II internal bleeding hemorrhoids that are refractory to medical therapy [20, 41]. This system can be used as an alternative to RBL.

Infrared coagulation involves the direct application of infrared light to hemorrhoidal tissue. These infrared light waves are converted into heat, which causes protein necrosis within hemorrhoids. This procedure is effective for grade I, II, or III internal bleeding hemorrhoids. Compared with RBL, infrared coagulation is associated with a higher rate of recurrence but fewer complications and less immediate postoperative discomfort [42, 43].

Injection sclerotherapy is used to treat patients with grade I or II internal bleeding hemorrhoids, with a reported success rate of 75% to 89% [44, 45]. Compared with RBL, this procedure is associated with a higher rate of recurrence but a lower risk of rebleeding [30]. Therefore, sclerotherapy is particularly useful for patients with coagulopathies or portal hypertension because of the lack of eschar formation as well as for immunocompromised patients because of the lower risk of anorectal sepsis compared with RBL or hemorrhoidectomy. The most validated agents include 3% polidocanol foam [46] and ALTA (aluminum potassium sulfate and tannic acid) [47].

Cryosurgery involves the use of special probes cooled with liquid nitrogen to achieve freezing, necrosis, and

subsequent fixation of the hemorrhoidal cushion. This procedure is associated with a high rate of complications and low patient satisfaction [48].

Statement 5-2: General indications for surgery

- Surgery should not be used as the first line of treatment, except in complex cases.
- Symptomatic HD which is refractory or intolerant to conservative treatment or outpatient procedures.
- Grade III/IV or mixed type HD.
- Symptomatic HD with a concomitant anorectal condition requiring surgery.

Statement 5-3: Surgical procedures for internal HD

- Conventional hemorrhoidectomy is associated with a high rate of postoperative complications but a low rate of recurrence (Quality of evidence: Moderate to High; Recommendation: Moderate)
- Hemorrhoidal artery ligation is associated with a low rate of postoperative complications but a high rate of recurrence (Quality of evidence: Moderate; Recommendation: Moderate)
- Stapled hemorrhoidopexy is associated with intermediate risks of postoperative complications and recurrence (Quality of evidence: Moderate to High; Recommendation: Moderate)
- Conventional hemorrhoidectomies performed using advanced energy devices are associated with low levels of pain but are expensive procedures (Quality of evidence: Moderate to High; Recommendation: Moderate)

(100% agreement for all sub-items)

The methods of internal hemorrhoidectomy differ primarily in terms of how the hemorrhoidal tissue is removed and whether the rectal mucosa is closed. Conventional hemorrhoidectomies are primarily divided into two types: closed (Ferguson) and open (Milligan–Morgan, excision and ligation without mucosal closure). Closed hemorrhoidectomy is commonly associated with a low rate of infection [49], whereas open hemorrhoidectomy is preferable for acute gangrenous hemorrhoids because mucosal closure cannot be conducted without undue tension due to tissue edema and necrosis [50]. Overall, no definitive advantage is observed between open and closed hemorrhoidectomy [49, 51]. All three internal hemorrhoidal columns are usually simultaneously treated. Utilizing energy equipment such as advanced bipolar devices and harmonic scalpels in conventional hemorrhoidectomies may reduce intraoperative bleeding and postoperative pain, but these devices have high costs [52, 53].

Doppler-guided hemorrhoidal artery ligation (DGHAL) and transanal hemorrhoidal dearterialization can be performed with or without mucopexy [54–56]. These techniques can be used in patients with grade II or III HD and are effective and safe. Compared with transanal hemorrhoidal dearterialization, DGHAL is associated with a lower rate of postoperative complications, including pain, but a higher rate of recurrence [57, 58]. In the treatment of low-grade symptomatic HD, hemorrhoidal artery ligation revealed a similar recurrence rate compared to repeated RBL, but it was more expensive and associated with more early postoperative pain[59].

Stapled hemorrhoidopexy is a time-saving alternative to conventional internal hemorrhoidectomy [60, 61]. Although this technique does not directly treat external hemorrhoids, it is used to treat patients with bleeding or prolapsing grade II to IV internal hemorrhoids who do not respond to RBL and patients who seek a less painful alternative to conventional surgery but are willing to accept a higher risk of recurrence [62, 63]. No significant differences are typically observed in the majority of postoperative complications between conventional hemorrhoidectomy and stapled hemorrhoidopexy, although some severe complications have been reported in patients undergoing stapled hemorrhoidopexy, such as rectal perforation, pelvic sepsis, and rectovaginal fistulas [64].

Statement 5-4: Surgical procedures for external HD

- External HD typically require no surgical treatment (No GRADE, Experts' opinion)
- Hemorrhoidal excision for thrombosed external HD has a lower recurrence rate than simple incision and thrombus evacuation (Quality of evidence: Moderate to High; Recommendation: Strong)

(100% agreement for all sub-items)

External HD is usually managed conservatively, unless patients have a skin tag large enough to cause skin irritation, itching, pain, or inability to maintain proper hygiene, in which case excision may be beneficial. For patients with thrombosed external hemorrhoids who present with persistent pain (typically within 72 h of onset), hemorrhoidal excision provides immediate relief [65]. Complete excision of thrombosed hemorrhoids is associated with a lower recurrence rate of 5% to 19% compared to 30% for simple incision and thrombus evacuation [66–68]. After 48 to 72 h, the thrombus typically contracts, ameliorating the patient's symptoms and eliminating the need for surgical treatment.

Statement 6. The following are the recommendations for the preparation of patients before surgical procedures:

- Lifestyle modifications and medical treatment (e.g., stool softeners and MPFFs) should be used as the first line of treatment.

- Preoperative evaluation should include a detailed history, physical examination involving external anal inspection, digital rectal examination, and anoscopy.
- Medications, particularly those that increase the risk of bleeding, should be reviewed and preferably discontinued in the perioperative period, depending on the indications for treatment and the risk of discontinuation.
- The administration of a cleansing enema prior to the procedure may be considered. Complete mechanical bowel preparation would not be necessary (Quality of evidence: Moderate; Recommendation: Moderate)
- Prophylactic antibiotics are not indicated in the majority of clinical scenarios, as the risk of infection is low. Patients with underlying immunosuppression may benefit from perioperative antibiotics (Quality of evidence: Moderate; Recommendation: Strong)
- Hemorrhoidal surgery can be performed under general anesthesia, conscious sedation, regional anesthesia (spinal, epidural), perianal block, or straight local anesthesia. The choice of anesthesia is based on the surgeon's preference, although patient-related factors may also be considered.

(100% agreement for all sub-items)

Statement 7. The following are the recommendations for postoperative treatment and practice:

- Lifestyle modifications should be maintained.
- MPFFs could be used postoperatively to reduce pain (Quality of evidence: Moderate to High; Recommendation: Moderate) and mitigate the risk of recurrence. (Quality of evidence: Low; Recommendation: Weak)
- Oral analgesics such as nonsteroidal anti-inflammatory drugs or acetaminophen could be used to control postoperative pain. Opioids should be used with caution because they may cause constipation.
- Laxatives could be used to ensure soft and regular bowel movement.
- Warm water sitz baths may be employed as needed to alleviate discomfort and other types of anal discomfort.
- The most prevalent complications associated with conventional hemorrhoidectomy include urinary retention, urinary tract infection, fecal impaction, and delayed bleeding.
- Perineal sepsis is typically a rare, yet life-threatening complication associated with all surgical procedures. Patients exhibiting a triad of symptoms, including severe pain, urinary retention, and fever, may require prompt further evaluation and management.

(100% agreement for all sub-items)

Statement 8. The following are the recommendations for special situations:

In patients with special situations, conservative nonsurgical treatment could be the initial treatment of choice for HD (No GRADE, Experts' opinion)

(100% agreement for all sub-items)

Special situation 1: Pregnant women

Symptomatic HD has a prevalence of 25% to 35% in pregnant women, and it is particularly common in the last trimester of pregnancy and immediately after delivery [69]. Its symptoms range from mild (e.g., itching, discomfort) to severe (e.g., prolonged bleeding). Because these symptoms typically decrease after delivery, conservative treatment is primarily administered during pregnancy. Their treatment includes conservative local therapy, dietary modifications, lying on the left side, and preventive measures [70]. The utilization of warm sitz baths may be more effective than anorectal creams for recovery from hemorrhoidal symptoms [71]. Surgical treatments such as hemorrhoidectomy are rarely necessary and are used only in cases of strangulated or extensively thrombosed hemorrhoids or intractable bleeding. If necessary, surgical procedures such as thrombectomy, local excision, or hemorrhoidectomy can be performed on pregnant women without compromising the safety of the fetus [72, 73]. During pregnancy and immediately after delivery, hemorrhoidal surgery should be reserved for cases with severe complications that are refractory to medical treatment.

Special situation 2: Immunocompromised patients

In immunocompromised patients, HD should be conservatively managed because of the risks of sepsis and poor wound healing associated with anorectal procedures [74]. In this patient population, sclerotherapy is regarded as a safe alternative treatment for hemorrhoidal bleeding, when necessary [75, 76]. If sclerotherapy is not feasible, conservative treatment could be considered for patients with grade I, II, and III symptomatic hemorrhoids, whereas hemorrhoidectomy could be considered for patients with grade IV or complicated hemorrhoids.

Special situation 3: Patients on anticoagulant or antiplatelet drugs

Patients on anticoagulant or antiplatelet drugs often present with bleeding hemorrhoids. However, the bleeding episodes are usually self-limiting and do not require drug discontinuation or reversal of their medications. The majority of patients with low-grade (grade I or II) HD respond to conservative treatment. In cases of persistent bleeding, in addition to drug discontinuation, sclerotherapy also could be considered. Rubber band ligation (RBL) is relatively contraindicated in patients on anticoagulant or antiplatelet drugs because of the risk of catastrophic rectal bleeding after the eschar is cast off. If RBL or hemorrhoidectomy is required for high-grade or complicated HD, anticoagulant or antiplatelet medications should be reviewed and preferably discontinued in the perioperative period, depending

on the indications for treatment and the risk of discontinuation [9].

However, there is a risk of so-called rebound hypercoagulability in patients who undergo cessation of anticoagulants and then restart them, thus increasing the risk of adverse thrombotic events. In patients suffering from refractory hemorrhoidal bleeding who are unable to stop anticoagulant or antiplatelet drugs, injection sclerotherapy with polidocanol foam [46] or ALTA [47], or sclerobanding [77] may be safe and effective treatment options, although further high-quality evidence is needed. Transanal hemorrhoidal dearterialization [78] has been proven safe in a cohort of patients mainly taking acetylsalicylic acid (ASA), so it cannot be recommended for patients taking other anticoagulants.

Special situation 4: Patients with portal hypertension

Patients with portal hypertension should be differentiated in diagnosis between rectal variceal bleeding and hemorrhoidal bleeding [79]. In patients with portal hypertension, rectal variceal bleeding is commonly treated with suture ligation or medications, whereas hemorrhoidal bleeding is commonly treated conservatively. Patients who do not respond to conservative treatment are usually treated using sclerotherapy. In these patients, RBL is also contraindicated because of its risk of delayed bleeding. Patients who do not respond to sclerotherapy often require suture.

Recent studies suggest that treatments including RBL, injection sclerotherapy with various agents, hemorrhoidopexy, and the emborrhoid technique [80] are effective and safe for this population [81, 82]. The findings of these studies may necessitate a shift in our approach to the care of these patients; however, further investigation is required to substantiate these claims.

Special situation 5: Patients with IBD

In patients with IBD, hemorrhoidal surgery is often associated with major complications, including sepsis, stenosis, fistulas, fecal incontinence, nonhealing wounds, and even a need for proctectomy. Because of the high complication rate, the majority of patients with IBD who are present with symptomatic HD are conservatively managed with a high-fiber diet, oral hydration, warm sitz baths, and oral phlebotonics. In addition, IBD flares should be controlled. Some patients who are present with symptoms refractory to medical therapy may undergo surgical treatment if their IBD is under control. These patients should be informed of the high risks of any intervention. For this patient population, no optimal surgical treatment is yet available, and the majority of findings are from small retrospective studies conducted many years ago [83]. Surgeons often prefer conventional hemorrhoidectomy or minimally invasive techniques such as RBL or hemorrhoidal artery ligation. Hemorrhoidopexy may be associated with life-threatening complications [84].

So far, no consensus has been reached regarding the exact indications for surgery in patients with IBD and HD. D'Ugo et al. [83, 85] described that the first-line management for these patients should involve medical therapy given that spontaneous healing is possible. Despite the high risk of complications in patients with IBD, in nonresponsive patients, surgical options in selected patients can be considered for achieving acceptable results [86]. In cases of IBD, surgery is recommended only during the remission phase.

Statement 9. The following are the recommendations for referring patients to a colorectal surgeon depending on their grade and symptoms:

- A referral to a colorectal surgeon should be considered for patients with unconfirmed diagnoses, poor responses to treatment, or complicated HD (No GRADE, Experts' opinion)
- Refer for procedure:

1. Symptomatic low-grade (grade I or II) internal HD refractory to at least 1 week of medical treatment
2. Symptomatic high-grade (grade III or IV) internal HD
3. Complicated HD associated with thrombosis, strangulation, prolapse, incarceration, or ulceration

(100% agreement for all sub-items)

HD represents a common condition that is usually diagnosed and treated by general practitioners. The majority of patients with low-grade (grade I or II) internal HD respond to conservative treatment and do not require further management. Patients with HD that are refractory or with complicated HD are referred to a specialist for potential intervention and rectal bleeding for potential colonoscopy.

Conclusions

Consensus on the management of HD

Figure 2 is the schematic of Taiwan Society of Colon and Rectal Surgeons HD consensus. Conservative treatment is appropriate for the majority of patients with low-grade HD. Although oral phlebotonics may ameliorate the symptoms of HD, dietary and lifestyle modifications remain the first step of treatment for achieving regular defecation with soft stools. Patients in Taiwan may also try using traditional herbs/medicines to relieve hemorrhoidal symptoms. In clinical practice, the use of these agents is not recommended based on current evidence. According to the clinical data of patients with HD, oral MPFFs are suitable and effective for all grades of HD. Surgical treatment for HD is often reserved for patients with severe conditions or patients who

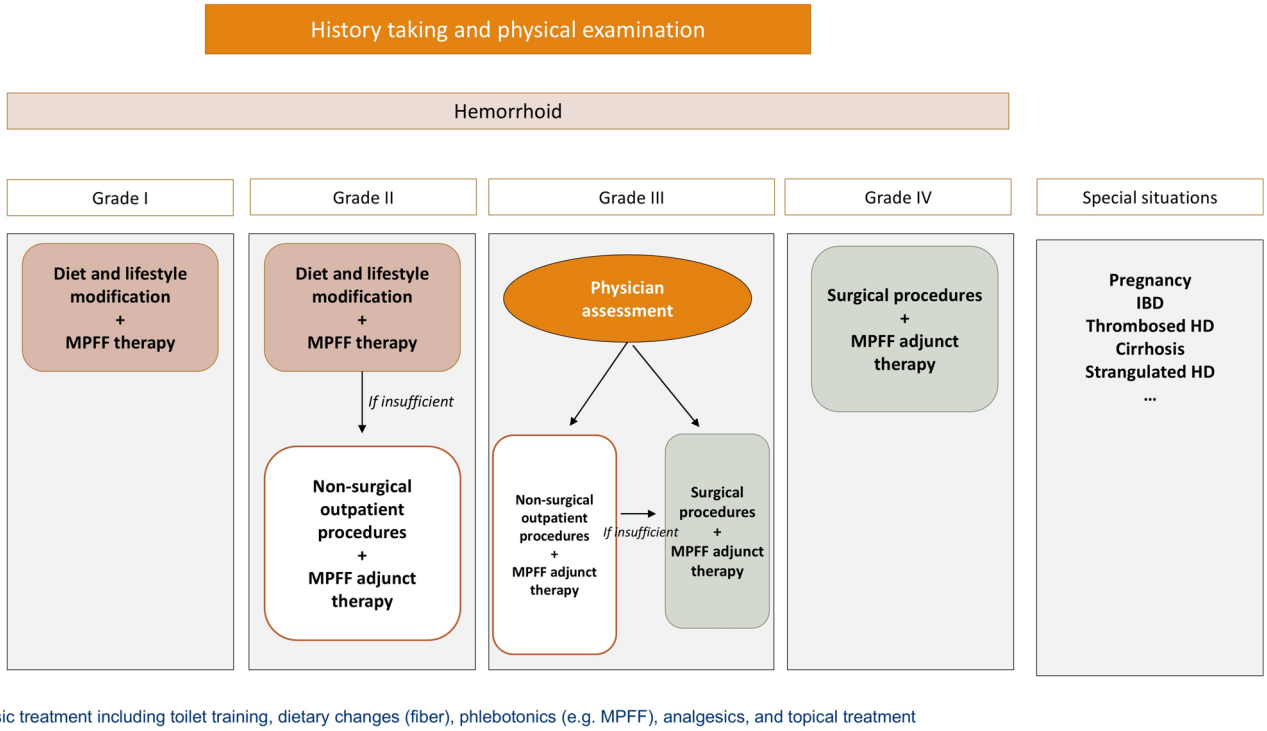

Fig. 2 The schematic of Taiwan Society of Colon and Rectal Surgeons' hemorrhoidal disease consensus

do not respond to conservative treatment. Postoperative MPFFs in patients with advanced HD who have undergone surgery may be effective in eliminating associated discomfort. MPFFs may also prevent the recurrence of HD.

In Taiwan, sclerotherapy is rarely performed due to lack of sclerosing agents and national insurance coverage. In this consensus, we recommend alternative treatment strategies, especially for immuno-compromised or cirrhotic patients. In addition, due to the high incidence of CRC in Taiwan, CRC screening tests should be considered in patients with unusual clinical presentation, such as bowel habit changes, refractory or unusual bleeding sites.

Overall, the treatment outcomes of patients with HD are often complicated by certain clinical conditions, such as pregnancy, IBD, thrombosed HD, cirrhosis, and strangulated HD. Therefore, caution should be exercised when performing any outpatient procedures on these patients to avoid potentially fatal outcomes, and conservative treatment should be used as the first line of treatment.

Supplementary Information The online version contains supplementary material available at https://doi.org/10.1007/s00384-025-05010-9.

Acknowledgements The authors are grateful to all the experts for their professional views and active contributions to the topic during the advisory board meetings that preceded this publication. T.K.C. drafted the main text of the manuscript. All authors reviewed the manuscript and approved the version to be published. J.Y.W. agrees to take responsibility for all aspects of the work and to ensure that questions regarding the accuracy or integrity of any part of the work are appropriately investigated and resolved. This work was supported by grants through funding from the National Science and Technology Council (NSTC 112-2314-B-037-050-MY3, NSTC 114-2314-B-037-103-MY3, NSTC 114-2321-B-037-003) and the Ministry of Health and Welfare (MOHW113-TDU-B-222-134014) and funded by the health and welfare surcharge of on tobacco products, and the Kaohsiung Medical University Hospital (KMUH113-3R31, KMUH113-3R32, KMUH113-3R33, KMUH113-3M58, KMUH113-3M59, KMUH-S11412, KMUH-SH11403), Kaohsiung Medical University Research Center Grant (KMU-TC113A04) and National Tsing Hua University-Kaohsiung Medical University Joint Research Project (NTHU-KMU-KT114P008). In addition, this study was supported by the Grant of Taiwan Precision Medicine Initiative and Taiwan Biobank, Academia Sinica, Taiwan, R.O.C.

Author contribution The authors thank all expert panelists for their professional views and active contributions to the topic in advisory board meetings preceding this publication. T.K.C. wrote the main manuscript text. All authors reviewed the manuscript and approved the version to be published. J.Y.W. agrees to be accountable for all aspects of the work in ensuring that questions related to the accuracy or integrity of any part of the work are appropriately investigated and resolved.

Funding This manuscript is not supported by any funding.

Data availability No datasets were generated or analyzed during the current study.

Declarations

Ethics approval This type of study does not need ethical approval.

Informed consent This type of study does not need informed consent.

Conflict of interest The authors declare no competing interests.

Open Access This article is licensed under a Creative Commons Attribution-NonCommercial-NoDerivatives 4.0 International License, which permits any non-commercial use, sharing, distribution and reproduction in any medium or format, as long as you give appropriate credit to the original author(s) and the source, provide a link to the Creative Commons licence, and indicate if you modified the licensed material. You do not have permission under this licence to share adapted material derived from this article or parts of it. The images or other third party material in this article are included in the article's Creative Commons licence, unless indicated otherwise in a credit line to the material. If material is not included in the article's Creative Commons licence and your intended use is not permitted by statutory regulation or exceeds the permitted use, you will need to obtain permission directly from the copyright holder. To view a copy of this licence, visit http://creativecommons.org/licenses/by-nc-nd/4.0/.

References

1. Johanson JF, Sonnenberg A (1990) The prevalence of hemorrhoids and chronic constipation. An epidemiologic study. Gastroenterology 98(2):380–386
2. Pata F et al (2021) Anatomy, physiology and pathophysiology of haemorrhoids. Rev Recent Clin Trials 16(1):75–80. https://doi.org/10.2174/1574887115666200406115150
3. Loder PB et al (1994) Haemorrhoids: pathology, pathophysiology and aetiology. Br J Surg 81(7):946–954. https://doi.org/10.1002/bjs.1800810707
4. Riss S et al (2012) The prevalence of hemorrhoids in adults. Int J Colorectal Dis 27(2):215–220. https://doi.org/10.1007/s00384-011-1316-3
5. Carter D et al (2013) Prevalence and clinical associations of hemorrhoids at screening colonoscopy. World J Colorectal Surg 3(2):10
6. Brown SR (2017) Haemorrhoids: an update on management. Ther Adv Chronic Dis 8(10):141–147. https://doi.org/10.1177/2040622317713957
7. Yao Y-S, Lan T-Y, Tang G-J (2021) Characteristics of hemorrhoids patients in Taiwan- a descriptive analysis based on the national health insurance database. Fu-Jen J Med 19(4):1–12. https://doi.org/10.3966/181020932021121904001
8. Sureshkumar S et al (2018) Clinical tests combined with color Doppler versus color Doppler alone in identifying incompetent perforator veins of the lower limb: a prospective analytical study. Cureus 10(1):e2026. https://doi.org/10.7759/cureus.2026
9. Lohsiriwat V (2015) Treatment of hemorrhoids: a coloproctologist's view. World J Gastroenterol 21(31):9245–9252. https://doi.org/10.3748/wjg.v21.i31.9245
10. Schünemann HJ et al (2003) Letters, numbers, symbols and words: how to communicate grades of evidence and recommendations. CMAJ 169(7):677–680
11. Banov L Jr et al (1985) Management of hemorrhoidal disease. J S C Med Assoc 81(7):398–401
12. Aoki T et al (2019) Initial management for acute lower gastrointestinal bleeding. World J Gastroenterol 25(1):69–84. https://doi.org/10.3748/wjg.v25.i1.69
13. Hong J et al (2022) Socio-demographic factors and lifestyle associated with symptomatic hemorrhoids: big data analysis using the National Health insurance service-national health screening cohort (NHIS-HEALS) database in Korea. Asian J Surg 45(1):353–359
14. Hong YS et al (2022) Risk factors for hemorrhoidal disease among healthy young and middle-aged Korean adults. Sci Rep 12(1):129. https://doi.org/10.1038/s41598-021-03838-z
15. Peery AF et al (2015) Risk factors for hemorrhoids on screening colonoscopy. PLoS ONE 10(9):e0139100. https://doi.org/10.1371/journal.pone.0139100
16. De Marco S, Tiso D (2021) Lifestyle and risk factors in hemorrhoidal disease. Front Surg 8:729166. https://doi.org/10.3389/fsurg.2021.729166
17. Alonso-Coello P et al (2006) Fiber for the treatment of hemorrhoids complications: a systematic review and meta-analysis. Am J Gastroenterol 101(1):181–188. https://doi.org/10.1111/j.1572-0241.2005.00359.x
18. Moesgaard F et al (1982) High-fiber diet reduces bleeding and pain in patients with hemorrhoids: a double-blind trial of Vi-Siblin. Dis Colon Rectum 25(5):454–456. https://doi.org/10.1007/BF02553653
19. Hussain SM et al (2020) Experience with Haemorrhoidal artery ligation under direct vision at a tertiary care hospital: a case series. J Pak Med Assoc 70(6):1089–1093. https://doi.org/10.5455/JPMA.300504
20. Malik F et al (2019) 2820 A retrospective study to assess safety and efficacy of the HET bipolar ligator system for the treatment of grade I and II internal hemorrhoids. Off J Am Coll Gastroenterol | ACG 114:S1555. https://doi.org/10.14309/01.ajg.0000600812.99559.24
21. Zagriadskii EA, Bogomazov AM, Golovko EB (2018) Conservative treatment of hemorrhoids: results of an observational multicenter study. Adv Ther 35(11):1979–1992. https://doi.org/10.1007/s12325-018-0794-x
22. Aziz Z et al (2018) Efficacy and tolerability of micronized purified flavonoid fractions (MPFF) for haemorrhoids: a systematic review and meta-analysis. Complement Ther Med 39:49–55
23. Sheikh P, Lohsiriwat V, Shelygin Y (2020) Micronized purified flavonoid fraction in hemorrhoid disease: a systematic review and meta-analysis. Adv Ther 37(6):2792–2812. https://doi.org/10.1007/s12325-020-01353-7
24. La Torre F, Nicolai AP (2004) Clinical use of micronized purified flavonoid fraction for treatment of symptoms after hemorrhoidectomy: results of a randomized, controlled, clinical trial. Dis Colon Rectum 47(5):704–710. https://doi.org/10.1007/s10350-003-0119-1
25. Chen P-Y et al (2021) Revealing the mechanism of "Huai Hua San" in the treatment of ulcerative colitis based on network pharmacology and experimental study. J Ethnopharmacol 281:114321
26. Rathnavelu V et al (2016) Potential role of bromelain in clinical and therapeutic applications. Biomed Rep 5(3):283–288
27. Inchingolo F et al (2010) Clinical trial with bromelain in third molar exodontia. Eur Rev Med Pharmacol Sci 14(9):771–774
28. Alonso-Coello P et al (2006) Meta-analysis of flavonoids for the treatment of haemorrhoids. Br J Surg 93(8):909–920. https://doi.org/10.1002/bjs.5378
29. MacRae HM, McLeod RS (1995) Comparison of hemorrhoidal treatment modalities. A meta-analysis. Dis Colon Rectum 38(7):687–694. https://doi.org/10.1007/BF02048023
30. MacRae HM, McLeod RS (1997) Comparison of hemorrhoidal treatments: a meta-analysis. Can J Surg 40(1):14–17
31. Bleday R et al (1992) Symptomatic hemorrhoids: current incidence and complications of operative therapy. Dis Colon Rectum 35(5):477–481. https://doi.org/10.1007/BF02049406
32. Iyer VS, Shrier I, Gordon PH (2004) Long-term outcome of rubber band ligation for symptomatic primary and recurrent internal hemorrhoids. Dis Colon Rectum 47(8):1364–1370. https://doi.org/10.1007/s10350-004-0591-2

33. Cocorullo G (2017) The non-surgical management for hemorrhoidal disease. A systematic review. G Chir 38(1):5–14. https://doi.org/10.11138/gchir/2017.38.1.005
34. Khubchandani IT (1983) A randomized comparison of single and multiple rubber band ligations. Dis Colon Rectum 26(11):705–708. https://doi.org/10.1007/BF02554977
35. Marshman D et al (1989) Hemorrhoidal ligation. A review of efficacy. Dis Colon Rectum 32(5):369–371. https://doi.org/10.1007/BF02563683
36. Wechter DG, Luna GK (1987) An unusual complication of rubber band ligation of hemorrhoids. Dis Colon Rectum 30(2):137–140. https://doi.org/10.1007/BF02554954
37. Scarpa FJ, Hillis W, Sabetta JR (1988) Pelvic cellulitis: a life-threatening complication of hemorrhoidal banding. Surgery 103(3):383–385
38. Albuquerque A (2016) Rubber band ligation of hemorrhoids: a guide for complications. World J Gastrointest Surg 8(9):614–620. https://doi.org/10.4240/wjgs.v8.i9.614
39. Wee IJY et al (2023) Laser hemorrhoidoplasty versus conventional hemorrhoidectomy for grade II/III hemorrhoids: a systematic review and meta-analysis. Ann Coloproctol 39(1):3–10. https://doi.org/10.3393/ac.2022.00598.0085
40. Ram E et al (2023) Laser hemorrhoidoplasty for II-IV grade hemorrhoids: should we treat them the same? Updates Surg 75(3):635–642. https://doi.org/10.1007/s13304-023-01480-0
41. Kantsevoy SV, Bitner M (2013) Nonsurgical treatment of actively bleeding internal hemorrhoids with a novel endoscopic device (with video). Gastrointest Endosc 78(4):649–653. https://doi.org/10.1016/j.gie.2013.05.014
42. Poen AC et al (2000) A randomized controlled trial of rubber band ligation versus infra-red coagulation in the treatment of internal haemorrhoids. Eur J Gastroenterol Hepatol 12(5):535–539. https://doi.org/10.1097/00042737-200012050-00010
43. Marques CF et al (2006) Early results of the treatment of internal hemorrhoid disease by infrared coagulation and elastic banding: a prospective randomized cross-over trial. Tech Coloproctol 10(4):312–317. https://doi.org/10.1007/s10151-006-0299-5
44. Khoury GA et al (1985) A randomized trial to compare single with multiple phenol injection treatment for haemorrhoids. Br J Surg 72(9):741–742. https://doi.org/10.1002/bjs.1800720924
45. Mann CV, Motson R, Clifton M (1988) The immediate response to injection therapy for first-degree haemorrhoids. J R Soc Med 81(3):146–148. https://doi.org/10.1177/014107688808100309
46. Salgueiro P et al (2022) Polidocanol foam sclerotherapy in the treatment of hemorrhoidal disease in patients with bleeding disorders: a multicenter, prospective, cohort study. Tech Coloproctol 26(8):615–625. https://doi.org/10.1007/s10151-022-02600-5
47. Yano T et al (2013) Outcomes of case-matched injection sclerotherapy with a new agent for hemorrhoids in patients treated with or without blood thinners. Surg Today 43(8):854–858. https://doi.org/10.1007/s00595-012-0365-8
48. Buls JG, Goldberg SM (1978) Modern management of hemorrhoids. Surg Clin North Am 58(3):469–478. https://doi.org/10.1016/s0039-6109(16)41530-6
49. Nisar PJ et al (2004) Stapled hemorrhoidopexy compared with conventional hemorrhoidectomy: systematic review of randomized, controlled trials. Dis Colon Rectum 47(11):1837–1845. https://doi.org/10.1007/s10350-004-0679-8
50. Lumb KJ et al (2006) Stapled versus conventional surgery for hemorrhoids. Cochrane Database Syst Rev 2006(4):Cd005393. https://doi.org/10.1002/14651858.CD005393.pub2
51. Giordano P et al (2009) Long-term outcomes of stapled hemorrhoidopexy vs conventional hemorrhoidectomy: a meta-analysis of randomized controlled trials. Arch Surg 144(3):266–272. https://doi.org/10.1001/archsurg.2008.591
52. Wang JY et al (2006) Randomized controlled trial of LigaSure with submucosal dissection versus Ferguson hemorrhoidectomy for prolapsed hemorrhoids. World J Surg 30(3):462–466. https://doi.org/10.1007/s00268-005-0297-1
53. Wang JY et al (2007) Prospective, randomized, controlled trial of Starion vs Ligasure hemorrhoidectomy for prolapsed hemorrhoids. Dis Colon Rectum 50(8):1146–1151. https://doi.org/10.1007/s10350-007-0260-3
54. Giordano P et al (2009) Transanal hemorrhoidal dearterialization: a systematic review. Dis Colon Rectum 52(9):1665–1671. https://doi.org/10.1007/DCR.0b013e3181af50f4
55. Forrest NP et al (2010) Doppler-guided haemorrhoidal artery ligation with recto anal repair: a new technique for the treatment of symptomatic haemorrhoids. Int J Colorectal Dis 25(10):1251–1256. https://doi.org/10.1007/s00384-010-0951-4
56. Faucheron JL et al (2011) Doppler-guided hemorrhoidal artery ligation and rectoanal repair (HAL-RAR) for the treatment of grade IV hemorrhoids: long-term results in 100 consecutive patients. Dis Colon Rectum 54(2):226–231. https://doi.org/10.1007/DCR.0b013e318201d31c
57. Sajid MS et al (2012) A systematic review comparing transanal haemorrhoidal de-arterialisation to stapled haemorrhoidopexy in the management of haemorrhoidal disease. Tech Coloproctol 16(1):1–8. https://doi.org/10.1007/s10151-011-0796-z
58. Bursics A et al (2004) Comparison of early and 1-year follow-up results of conventional hemorrhoidectomy and hemorrhoid artery ligation: a randomized study. Int J Colorectal Dis 19(2):176–180. https://doi.org/10.1007/s00384-003-0517-9
59. Brown S et al (2016) The HubBLe trial: haemorrhoidal artery ligation (HAL) versus rubber band ligation (RBL) for symptomatic second- and third-degree haemorrhoids: a multicentre randomised controlled trial and health-economic evaluation. Health Technol Assess 20(88):1–150. https://doi.org/10.3310/hta20880
60. Huang WS et al (2007) Randomized comparison between stapled hemorrhoidopexy and Ferguson hemorrhoidectomy for grade III hemorrhoids in Taiwan: a prospective study. Int J Colorectal Dis 22(8):955–961. https://doi.org/10.1007/s00384-006-0244-0
61. Watson AJ et al (2017) A pragmatic multicentre randomised controlled trial comparing stapled haemorrhoidopexy with traditional excisional surgery for haemorrhoidal disease: the eTHoS study. Health Technol Assess 21(70):1–224. https://doi.org/10.3310/hta21700
62. Lan P et al (2006) The safety and efficacy of stapled hemorrhoidectomy in the treatment of hemorrhoids: a systematic review and meta-analysis of ten randomized control trials. Int J Colorectal Dis 21(2):172–178. https://doi.org/10.1007/s00384-005-0786-6
63. Jayaraman S, Colquhoun PH, Malthaner RA (2007) Stapled hemorrhoidopexy is associated with a higher long-term recurrence rate of internal hemorrhoids compared with conventional excisional hemorrhoid surgery. Dis Colon Rectum 50(9):1297–1305. https://doi.org/10.1007/s10350-007-0308-4
64. Angelone G, Giardiello C, Prota C (2006) Stapled hemorrhoidopexy. Complications and 2-year follow-up. Chir Ital 58(6):753–760
65. Linares Santiago E et al (2001) Effectiveness of hemorrhoidal treatment by rubber band ligation and infrared photocoagulation. Rev Esp Enferm Dig 93(4):238–247
66. Jongen J et al (2003) Excision of thrombosed external hemorrhoid under local anesthesia: a retrospective evaluation of 340 patients. Dis Colon Rectum 46(9):1226–1231. https://doi.org/10.1007/s10350-004-6719-6
67. Hawkins AT et al (2024) The American Society of Colon and Rectal Surgeons clinical practice guidelines for the management of hemorrhoids. Dis Colon Rectum 67(5):614–623. https://doi.org/10.1097/dcr.0000000000003276
68. Greenspon J et al (2004) Thrombosed external hemorrhoids: outcome after conservative or surgical management. Dis Colon Rectum 47(9):1493–1498. https://doi.org/10.1007/s10350-004-0607-y

69. Abramowitz L, Batallan A (2003) Épidémiologie des lésions anales (fissure et thrombose hémorroïdaire externe) pendant la grossesse et le post-partum. Gynecol Obstet Fertil 31(6):546–549. https://doi.org/10.1016/s1297-9589(03)00127-9
70. Abramowitz L et al (2011) Haemorrhoidal disease in pregnancy. Presse Med 40(10):955–959. https://doi.org/10.1016/j.lpm.2011.06.015
71. Shirah BH et al (2018) Hemorrhoids during pregnancy: sitz bath vs. ano-rectal cream: a comparative prospective study of two conservative treatment protocols. Women Birth 31(4):e272–e277. https://doi.org/10.1016/j.wombi.2017.10.003
72. Saleeby RG et al (1991) Hemorrhoidectomy during pregnancy: risk or relief? Dis Colon Rectum 34(3):260–261. https://doi.org/10.1007/BF02090166
73. Medkova Y et al (2024) Thrombosed external hemorrhoids during pregnancy: surgery versus conservative treatment. Updates Surg 76(2):539–545. https://doi.org/10.1007/s13304-023-01741-y
74. Morandi E et al (1999) Prospective study of healing time after hemorrhoidectomy: influence of HIV infection, acquired immunodeficiency syndrome, and anal wound infection. Dis Colon Rectum 42(9):1140–1144. https://doi.org/10.1007/bf02238565
75. Buchmann P, Seefeld U (1989) Rubber band ligation for piles can be disastrous in HIV-positive patients. Int J Colorectal Dis 4(1):57–58. https://doi.org/10.1007/bf01648552
76. Scaglia M et al (2001) Injection treatment of hemorrhoids in patients with acquired immunodeficiency syndrome. Dis Colon Rectum 44(3):401–404. https://doi.org/10.1007/bf02234740
77. Pata F et al (2023) Sclerobanding in the treatment of second and third degree hemorrhoidal disease in high risk patients on antiplatelet/anticoagulant therapy without suspension: a pilot study. Front Surg 10:1290706. https://doi.org/10.3389/fsurg.2023.1290706
78. Atallah S et al (2016) Transanal hemorrhoidal dearterialization (THD): a safe procedure for the anticoagulated patient? Tech Coloproctol 20(7):461–466. https://doi.org/10.1007/s10151-016-1481-z
79. Hosking SW et al (1989) Anorectal varices, haemorrhoids, and portal hypertension. Lancet 1(8634):349–352. https://doi.org/10.1016/s0140-6736(89)91724-8
80. Giurazza F et al (2020) Emborrhoid in patients with portal hypertension and chronic hemorrhoidal bleeding: preliminary results in five cases with a new coiling release fashion "Spaghetti technique." Radiol Med 125(10):1008–1011. https://doi.org/10.1007/s11547-020-01194-y
81. Komporozos V et al (2021) Rubber band ligation of symptomatic hemorrhoids: an old solution to an everyday problem. Int J Colorectal Dis 36(8):1723–1729. https://doi.org/10.1007/s00384-021-03900-2
82. Ponte SB et al (2025) Treatment of hemorrhoidal disease in patients with liver cirrhosis: a systematic review. GE Port J Gastroenterol 32(2):95–108. https://doi.org/10.1159/000540702
83. D'Ugo S et al (2013) Medical and surgical treatment of haemorrhoids and anal fissure in Crohn's disease: a critical appraisal. BMC Gastroenterol 13:47. https://doi.org/10.1186/1471-230x-13-47
84. McCloud JM, Jameson JS, Scott AN (2006) Life-threatening sepsis following treatment for haemorrhoids: a systematic review. Colorectal Dis 8(9):748–755. https://doi.org/10.1111/j.1463-1318.2006.01028.x
85. D'Ugo S et al (2015) Hemorrhoids and anal fissures in inflammatory bowel disease. Minerva Gastroenterol Dietol 61(4):223–33. R08Y9999N00A150011
86. Lightner AL et al (2020) Excisional hemorrhoidectomy: safe in patients with Crohn's disease? Inflamm Bowel Dis 26(9):1390–1393. https://doi.org/10.1093/ibd/izz255
87. Cengiz TB, Gorgun E (2019) Hemorrhoids: a range of treatments. Cleve Clin J Med 86(9):612–620. https://doi.org/10.3949/ccjm.86a.18079

Publisher's Note Springer Nature remains neutral with regard to jurisdictional claims in published maps and institutional affiliations.

Authors and Affiliations

Tsung-Kun Chang[1,2,3] · Tao-Wei Ke[4] · Pao-Shiu Hsieh[5] · Shih-Ching Chang[6] · Wan Hsiang Hu[7] · Ching-Wen Huang[1,9] · Feng-Fan Chiang[11,12] · Hsiang-Lin Tsai[1,9] · Jin-Tung Liang[13] · Chien-Kuo Liu[8] · Jaw-Yuan Wang[1,2,9,10]

✉ Chien-Kuo Liu
crs.liuck@gmail.com

✉ Jaw-Yuan Wang
Jawyuanwang@gmail.com; cy614112@ms14.hinet.net

1 Division of Colorectal Surgery, Department of Surgery, Kaohsiung Medical University Hospital, Kaohsiung Medical University, Kaohsiung 80708, Taiwan

2 Graduate Institute of Clinical Medicine, College of Medicine, Kaohsiung Medical University, Kaohsiung 80708, Taiwan

3 Department of Surgery, Faculty of Post-Baccalaureate Medicine, College of Medicine, Kaohsiung Medical University, Kaohsiung 80708, Taiwan

4 Division of Colorectal Surgery, Department of Surgery, China Medical University Hospital, Taichung 40402, Taiwan

5 Division of Colon and Rectal Surgery, Department of Surgery, Chang Gung Memorial Hospital-Linkou, Taoyuan 33305, Taiwan

6 Division of Colon and Rectal Surgery, Department of Surgery, Taipei Veterans General Hospital, Taipei 11217, Taiwan

7 Division of Colorectal Surgery, Department of Surgery, Kaohsiung Chang Gung Memorial Hospital, Chang Gung University College of Medicine, Kaohsiung, Taiwan

8 Division of Colorectal Surgery, Department of Surgery, Mackey Memorial Hospital, Zhongshan, Taipei 10449, Taiwan

9 Department of Surgery, Faculty of Medicine, College of Medicine, Kaohsiung Medical University, Kaohsiung 80708, Taiwan

10 Graduate Institute of Medicine, College of Medicine, Kaohsiung Medical University, Kaohsiung 80708, Taiwan

11 Division of Colorectal Surgery, Department of Surgery, Taichung Veterans General Hospital, Taichung 407219, Taiwan

12 Department of Food and Nutrition, Providence University, Taichung 433303, Taiwan

13 Division of Colorectal Surgery, Department of Surgery, National Taiwan University Hospital and College of Medicine, Taipei 100229, Taiwan