NEW TECHNOLOGY REPORT

Artificial Intelligence-Based Total Mesorectal Excision Plane Navigation in Laparoscopic Colorectal Surgery

Takahiro Igaki, M.D.[1,2,3] • Daichi Kitaguchi, M.D.[1,2] • Shigehiro Kojima, M.D., Ph.D.[1]
Hiro Hasegawa, M.D., Ph.D.[1,2] • Nobuyoshi Takeshita, M.D., Ph.D.[1]
Kensaku Mori, Ph.D.[4] • Yusuke Kinugasa, M.D., Ph.D.[3] • Masaaki Ito, M.D., Ph.D.[1,2]

1 Surgical Device Innovation Office, National Cancer Center Hospital East, Kashiwa, Chiba, Japan
2 Department of Colorectal Surgery, National Cancer Center Hospital East, Kashiwa, Chiba, Japan
3 Department of Gastrointestinal Surgery, Tokyo Medical and Dental University Graduate School of Medicine, Bunkyo-Ku, Tokyo, Japan
4 Graduate School of Informatics, Nagoya University, Furo-cho, Chikusa-ku, Nagoya, Aichi, Japan

See video on DCR YouTube Channel at https://youtu.be/qVWVVrB7_1s

BACKGROUND: Total mesorectal excision is the standard surgical procedure for rectal cancer because it is associated with low local recurrence rates. To the best of our knowledge, this is the first study to use an image-guided navigation system with total mesorectal excision.

IMPACT OF INNOVATION: The impact of innovation is the development of a deep learning-based image-guided navigation system for areolar tissue in the total mesorectal excision plane. Such a system might be helpful to surgeons because areolar tissue can be used as a landmark for the appropriate dissection plane.

TECHNOLOGY, MATERIALS, AND METHODS: This was a single-center experimental feasibility study involving 32 randomly selected patients who had undergone laparoscopic left-sided colorectal resection between 2015 and 2019. Deep learning-based semantic segmentation of areolar tissue in the total mesorectal excision plane was performed. Intraoperative images capturing the total mesorectal excision scene extracted from left colorectal laparoscopic resection videos were used as training data for the deep learning model. Six hundred annotation images were created from 32 videos, with 528 images in the training and 72 images in the test data sets. The experimental feasibility study was conducted at the Department of Colorectal Surgery, National Cancer Center Hospital East, Chiba, Japan. Dice coefficient was used to evaluate semantic segmentation accuracy for areolar tissue.

PRELIMINARY RESULTS: The developed semantic segmentation model helped locate and highlight the areolar tissue area in the total mesorectal excision plane. The accuracy and generalization performance of deep learning models depend mainly on the quantity and quality of the training data. This study had only 600 images; thus, more images for training are necessary to improve the recognition accuracy.

CONCLUSION AND FUTURE DIRECTIONS: We successfully developed a total mesorectal excision plane image-guided navigation system based on an areolar tissue segmentation approach with high accuracy. This may aid surgeons in recognizing the total mesorectal excision plane for dissection.

Funding/Support: None reported.

Financial Disclosure: None reported.

The protocol for this study was reviewed and approved by the ethics committee of National Cancer Center Hospital East, Chiba, Japan (registration no: 2020-315). Informed consent was obtained from all patients. The study conformed to the provisions of the 1964 Declaration of Helsinki (revised in Brazil in 2013).

Correspondence: Masaaki Ito, M.D., Ph.D., Surgical Device Innovation Office, National Cancer Center Hospital East, 6-5-1, Kashiwanoha, Kashiwa, Chiba 277-8577, Japan. E-mail: maito@east.ncc.go.jp

Dis Colon Rectum 2022; 65: e329–e333
DOI: 10.1097/DCR.0000000000002393
© The ASCRS 2022

The concept of total mesorectal excision (TME) is one of the most important developments in rectal cancer surgery. TME, popularized by Prof Heald in the early 1980s, involves sharp and precise dissection of the mesorectum with all associated lymph nodes through the avascular embryologic plane.[1] After the introduction of TME, the rate of local recurrence (LR) had markedly decreased and overall survival improved.[2,3] However, TME is challenging because it requires an understanding of complex

Copyright © The American Society of Colon & Rectal Surgeons, Inc. Unauthorized reproduction of this article is prohibited.

anatomy and precise dissection skills in the deep pelvis. Therefore, the average learning curve for competency is more than 40 cases per surgeon,[4] yet the surgical techniques directly related to the quality of TME influence the LR rate.[5,6] Even for experienced surgeons, it is sometimes difficult to recognize the gap between tissues of different embryological origins; therefore, although TME is important, there is no intuitive and easy method to perform TME.

With the recent rapid development of artificial intelligence, various image recognition technologies have been developed. Convolutional neural networks have been mainly used for deep learning-based image recognition tasks in recent studies. In the surgical domain, deep learning-based image recognition is applied to automatically recognize the location of critical anatomical structures, such as organs, major vessels, and surgical instruments during surgery (eg, automatic prostate recognition during transanal TME).[7] Therefore, it has the potential to be used as a fully automatic image-guided surgical system and might improve surgical safety, efficiency, and skill equalization. To the best of our knowledge, no studies thus far have reported the use of the TME navigation system using a deep learning approach.

In our study, we focused on the recognition of the correct dissection layer during surgery. In TME, the "holy plane" lies between the mesorectal fascia and the parietal pelvic fascia.[8] This plane has avascular and areolar tissues, and the identification of areolar tissue during surgery could be helpful in performing TME safely and accurately. Here, we aimed to develop a deep learning model for automatic areolar tissue segmentation and to assess the feasibility of image-guided TME.

MATERIALS AND METHODS

From the institutional intraoperative video data set, 32 videos of laparoscopic left-sided colorectal resection were randomly selected for the study. The surgeries were performed in the Department of Colorectal Surgery at National Cancer Center Hospital East, Chiba, Japan, between 2015 and 2019. For preprocessing, the videos were converted into MP4 format with a display resolution of 1280 × 720 pixels at a frame rate of 30 frames per second. Six hundred intraoperative images capturing the TME scene were randomly extracted and divided into 2 subsets. Specifically, 88% of the images were used to train the algorithms, and 12% were used to test the algorithms. The areolar tissue area was manually annotated into each image extracted by a colorectal surgeon (T.I.).

The semantic segmentation task, in which the model classifies every pixel of an image and recognizes the objects in the image as pixel aggregate, was performed using an open-source software for deep learning, DeepLabv3plus.[9] In this study, for the static images, pixels recognized as the areolar tissue area by the model were shown in red, and pixels recognized as background (ie, other than the areolar tissue area) were shown in black (Fig. 1). In addition, in the video, pixels recognized as the areolar tissue area were overlaid with white, and those recognized as the background were not colored (see video on DCR YouTube Channel at https://youtu.be/qVWVVrB7_1s). Pretraining of the model was performed on the ImageNet 2012 image database, which contains more than 14 million images of general objects (eg, animals, scenes, and food).[10] As postprocessing, areas of segmentation mask with 800 pixels or less were excluded from the output images.

The dice coefficient (DC) was obtained for each image to evaluate the accuracy of areolar tissue segmentation and used as the evaluation metric in this study. DC was defined as follows:

$$DC = 2 \times True\ \ positive / 2 \times True\ \ positive + False\ \ positive + False\ \ negative$$

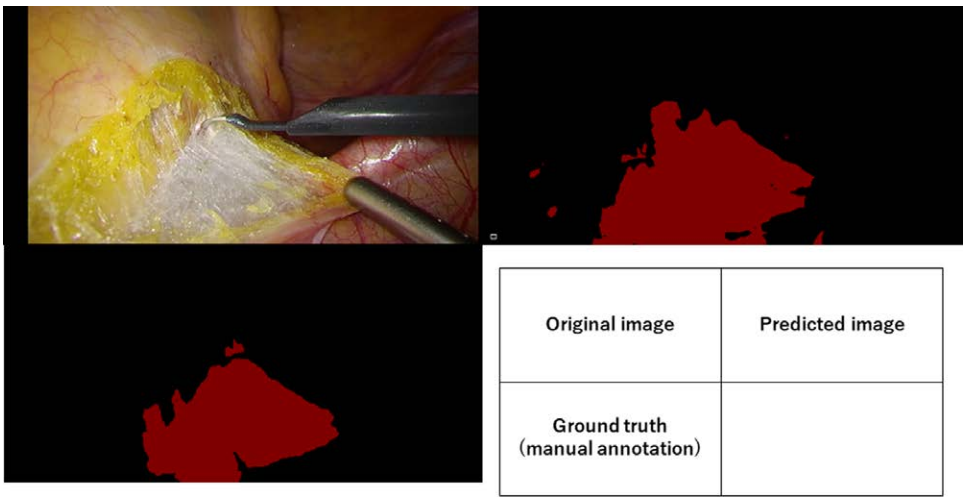

FIGURE 1. Surgeon's ground truth and predicted result with this model for a still surgery image.

Copyright © The American Society of Colon & Rectal Surgeons, Inc. Unauthorized reproduction of this article is prohibited.

It indicates the degree of match between the segmentation area with the deep learning model and manual annotation. The DC ranged between 0 and 1, where 1 indicates perfect segmentation and 0 indicates no pixel overlap between the predicted area and the ground truth area.

The protocol for this study was reviewed and approved by the ethics committee of National Cancer Center Hospital East, Chiba, Japan (registration No. 2020-315). Informed consent was obtained from all patients. The study conformed to the provisions of the 1964 Declaration of Helsinki (revised in Brazil in 2013).

RESULTS

The patient characteristics are summarized in Table 1. In the study cohort, 19 male and 13 female patients were included; the median age was 62.4 (range, 35–82) years, and the median BMI was 22.8 (range, 18.1–28.3) kg/m^2. The major clinical stage was stage 1 (18/32).

Six hundred annotation images were created from 32 videos, with 528 images in the training and 72 images in the test data sets. The DC for the complete evaluation image data set was 0.84. Figure 1 shows the results of areolar tissue segmentation observed in the representative images of the test data set. The **Video** shows good qualitative results of areolar tissue segmentation in the TME.

DISCUSSION

In this study, an automatic image recognition model for areolar tissue was developed with a high DC (0.84). This model could locate and highlight areolar tissue to be dissected for TME using an actual intraoperative video. The highlighted areolar tissue area was present in the TME plane—that is, between the layer covering the pelvic autonomic nerves and the mesorectal fascia. Therefore, the complete TME procedure could be achieved by simply dissecting along the highlighted area, which could lead to oncological safety and complete removal of the rectal cancer with minimal neurovascular damage or impact on urinary or sexual function. These results demonstrated that a deep learning-based image-guided navigation surgical system can be applied for TME.

TABLE 1. Patient characteristics

Characteristics	*N = 28 (528 images)*	*N = 4 (72 images)*
Sex (male), n (%)	19 (67.9)	1 (25)
Age (y), median (range)	63 (43–82)	54.5 (35–71)
BMI (kg/m^2), median (range)	22.8 (18.1–28.3)	22.8 (21.2–24.3)
Clinical stage in carcinoma case (UICC eighth edition), n (%)		
I	16 (57.1)	2 (50)
II	9 (32.1)	1 (25)
III	2 (7.1)	1 (25)
IV	1 (3.6)	0

UICC = International Union Against Cancer.

Figures 2 and 3 and the video illustrate the results of areolar tissue segmentation in the TME. When a surgeon's left hand made appropriate traction, the areolar tissue area was highlighted, and the bilateral hypogastric nerves were visualized outside the highlighted area. When the surgeon's right hand dissected within the highlighted area, the mesorectum and bilateral hypogastric nerves were preserved. On the lateral side of the TME, where there is usually less loose areolar tissue than in the posterior area, our model could recognize the areolar tissue. Therefore, the proposed deep learning model could recognize the areolar tissue areas in almost all scenes of the TME, as shown in the video.

A circumferential resection margin (CRM) of 1.0 mm or less after rectal cancer surgery is thought to increase the risk of LR[11]; thus, in cases of advanced stage, surgeons should maximize the probability of obtaining a tumor-free margin by adopting more external dissection in TME. However, because the autonomic nerves are closely placed to the rectum, there is a risk of nerve injury even with TME, resulting in sexual and bladder dysfunction.[12] Therefore, in cases of early tumor stage, more internal dissection should be suggested on the basis of the concept of nerve-sparing TME. Thus, depending on the tumor stage, in terms of depth of tumor invasion and the presence of mesorectal lymph node metastasis, it is crucial to consider whether the areolar tissue should be dissected on the internal or external side of the layers. When this concept is applied to the proposed system, dissection should be performed outside the highlighted area to preserve CRM in advanced cases, whereas it should be performed inside the highlighted area to avoid nerve injury in early-stage cases. Because the areolar tissue lies between various structures and not just the TME plane around the rectum, this image-guided navigation concept is applicable to other GI operations. Furthermore, recognition of the layer to be dissected will play a pivotal role in the automation of surgery in the future.

Although we focused on developing the image-guided system in this study, the proposed technology is also promising for application to automatic skill assessment of the TME. Several studies have reported on surgical skill assessments focused on exposure and dissection.[13,14] The better the traction applied, the larger the areolar tissue area. Thus, the size of the highlighted area shows the degree of traction. In addition, the proposed model can analyze how accurately the surgeon dissected within the highlighted area, because dissection outside the highlighted area might indicate an inappropriate dissection procedure. In future studies, we will evaluate the usefulness of the navigation system and apply the skill assessment.

Copyright © The American Society of Colon & Rectal Surgeons, Inc. Unauthorized reproduction of this article is prohibited.

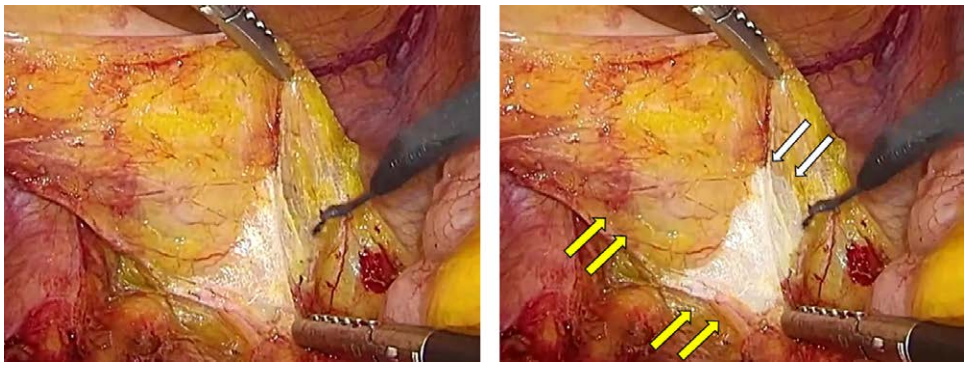

FIGURE 2. Posterior dissection in total mesorectal excision. A representative image highlighting areolar tissue in the actual intraoperative video with this model. The upper yellow arrows identify the mesorectal fascia; lower yellow arrows, the left hypogastric nerve; and white arrows, the areolar tissue.

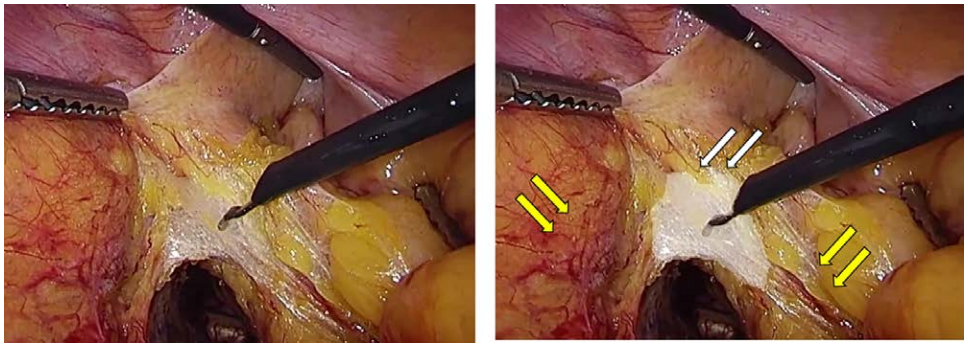

FIGURE 3. Left lateral dissection in total mesorectal excision. A representative image highlighting areolar tissue in the actual intraoperative video with this model. The right yellow arrows identify the mesorectal fascia; left yellow arrows, the fascia covering the pelvic autonomic nerves; and white arrows, the areolar tissue.

This study had several limitations. In general, the accuracy and generalization performance of deep learning models depend mainly on the quantity and quality of the training data. Because this study had only 600 images, more images are necessary to better train the system to improve the recognition accuracy. In the future, it would be better to increase the amount of training data and subsequently introduce the system clinically into actual surgery to verify the improvement in outcomes.

CONCLUSION

We successfully developed a TME plane image-guided navigation system based on the areolar tissue segmentation approach with high accuracy. This could lead to the realization of an automatic image navigation colorectal surgery system. Furthermore, there are various other possible uses of our system, such as surgical guidance, evaluation of quality, skill assessment, and automation of surgical robots.

KEY WORDS: Artificial intelligence; Computer vision; Intraoperative image-guided navigation; Laparoscopic colorectal surgery; Semantic segmentation; Total mesorectal excision.

REFERENCES

1. Heald RJ, Ryall RD. Recurrence and survival after total mesorectal excision for rectal cancer. *Lancet.* 1986;1:1479–1482.
2. van Lingen CP, Zeebregts CJ, Gerritsen JJ, Mulder HJ, Mastboom WJ, Klaase JM. Local recurrence of rectal cancer after total mesorectal excision without preoperative radiotherapy. *Int J Gastrointest Cancer.* 2003;34:129–134.
3. Kapiteijn E, Putter H, van de Velde CJ; Cooperative investigators of the Dutch ColoRectal Cancer Group. Impact of the introduction and training of total mesorectal excision on recurrence and survival in rectal cancer in The Netherlands. *Br J Surg.* 2002;89:1142–1149.
4. Mackenzie H, Miskovic D, Ni M, et al. Clinical and educational proficiency gain of supervised laparoscopic colorectal surgical trainees. *Surg Endosc.* 2013;27:2704–2711.
5. Garlipp B, Ptok H, Schmidt U, et al. Factors influencing the quality of total mesorectal excision. *Br J Surg.* 2012;99:714–720.
6. Wiggers T, van de Velde CJ. The circumferential margin in rectal cancer. Recommendations based on the Dutch Total Mesorectal Excision Study. *Eur J Cancer.* 2002;38:973–976.
7. Kitaguchi D, Takeshita N, Matsuzaki H, et al. Computer-assisted real-time automatic prostate segmentation during TaTME: a single-center feasibility study. *Surg Endosc.* 2021;35:2493–2499.
8. Heald RJ. The 'Holy Plane' of rectal surgery. *J R Soc Med.* 1988;81:503–508.
9. Chen LC, Zhu Y, Papandreou G, Schroff F, Adam H. Encoder-decoder with atrous separable convolution for semantic image

Copyright © The American Society of Colon & Rectal Surgeons, Inc. Unauthorized reproduction of this article is prohibited.

segmentation. In: Ferrari V, Hebert M, Sminchisescu C, Weiss Y, eds. *Computer Visions – ECCV 2018. Lecture Notes in Computer Science*. Vol 11211. Cham, Switzerland: Springer International Publishing, AG; 2018. doi: 10.1007/978-3-030-01234-2_49.

10. Russakovsky O, Deng J, Su H, et al. ImageNet large scale visual recognition challenge. *Int J Comput Vis.* 2015;115:211–252.
11. Nagtegaal ID, Marijnen CA, Kranenbarg EK, van de Velde CJ, van Krieken JH; Pathology Review Committee; Cooperative Clinical Investigators. Circumferential margin involvement is still an important predictor of local recurrence in rectal carcinoma: not one millimeter but two millimeters is the limit. *Am J Surg Pathol.* 2002;26:350–357.
12. Havenga K, Enker WE, McDermott K, Cohen AM, Minsky BD, Guillem J. Male and female sexual and urinary function after total mesorectal excision with autonomic nerve preservation for carcinoma of the rectum. *J Am Coll Surg.* 1996;182:495–502.
13. Curtis NJ, Foster JD, Miskovic D, et al. Association of surgical skill assessment with clinical outcomes in cancer surgery. *JAMA Surg.* 2020;155:590–598.
14. Miskovic D, Ni M, Wyles SM, et al; National Training Programme in Laparoscopic Colorectal Surgery in England. Is competency assessment at the specialist level achievable? A study for the national training programme in laparoscopic colorectal surgery in England. *Ann Surg.* 2013;257:476–482.

Copyright © The American Society of Colon & Rectal Surgeons, Inc. Unauthorized reproduction of this article is prohibited.