Annals of Gastroenterological Surgery

WILEY

ORIGINAL ARTICLE OPEN ACCESS

Artificial Intelligence-Guided Total Mesorectal Excision: Development of a Deep Learning Model to Identify the Pelvic Fascial Plane Anatomy

Yuta Suzuki[1,2] | Daichi Kitaguchi[1,3] | Norihito Kosugi[1] | Hiro Hasegawa[1,3] | Nobuyoshi Takeshita[1] | Yusuke Kinugasa[2] | Masaaki Ito[1,3]

[1]Department for the Promotion of Medical Device Innovation, National Cancer Center Hospital East, Chiba, Japan | [2]Department of Gastrointestinal Surgery, Graduate School of Medical and Dental Sciences, Institute of Science Tokyo, Tokyo, Japan | [3]Department of Colorectal Surgery, National Cancer Center Hospital East, Chiba, Japan

Correspondence: Masaaki Ito (maito@east.ncc.go.jp)

Received: 11 March 2025 | **Revised:** 30 May 2025 | **Accepted:** 26 June 2025

Funding: This study was funded by the Terumo Life Science Foundation (grant number: 22-T008).

Keywords: artificial intelligence | coloproctectomy | deep learning | rectal neoplasms | total mesorectal excision

ABSTRACT

Aim: Total mesorectal excision entails dissection of the "holy plane" without damaging the mesorectal and parietal pelvic fasciae. We aimed to train a deep learning model to identify the anatomical landmarks of the pelvic fascial surface during total mesorectal excision and evaluate its performance to validate artificial intelligence-guided total mesorectal excision.

Methods: In this single-center, retrospective, observational study, a deep learning model that can automatically identify the anatomical landmarks in the pelvic fascial plane during laparoscopic total mesorectal excision in real time was developed. Target anatomical landmarks included the mesorectal fascia, parietal pelvic fascia, and the holy plane between them. Feature Pyramid Networks and EfficientNetB7 were adopted as the neural network architecture and backbone network, respectively. The surgical videos used for training and validation data were different. The Dice Similarity Coefficient, recall, and Normalized Surface Dice, which were calculated using five-fold cross-validation, were used as the evaluation metrics.

Results: Overall, 2861 images from 157 surgical videos were annotated and used for the training and validation datasets. In the semantic segmentation task, the Dice Similarity Coefficients for the mesorectal fascia, parietal pelvic fascia, and holy plane were 90.4%, 90.6%, and 68.5%, respectively. The Normalized Surface Dices for the three fasciae were 70.4%, 73.2%, and 54.6%, respectively.

Conclusions: We constructed a deep learning model that recognizes three regions for total mesorectal excision—the mesorectal fascia, parietal pelvic fascia, and intervening holy plane—with a relatively high Dice Similarity Coefficient, successfully providing proof of concept for artificial intelligence-guided total mesorectal excision.

1 | Introduction

Colorectal cancer is the third most commonly diagnosed cancer, accounting for an estimated 1.2 million new cases and 600 000 deaths per year worldwide [1, 2]. Rectal cancer accounts for approximately 40% of all cases of CRC, whose incidence and mortality rates have undergone a steady rise globally [3]. The mainstay of surgical treatment for patients requiring rectal

Yuta Suzuki and Daichi Kitaguchi have contributed equally to this work.

This is an open access article under the terms of the Creative Commons Attribution-NonCommercial-NoDerivs License, which permits use and distribution in any medium, provided the original work is properly cited, the use is non-commercial and no modifications or adaptations are made.

© 2025 The Author(s). *Annals of Gastroenterological Surgery* published by John Wiley & Sons Australia, Ltd on behalf of The Japanese Society of Gastroenterological Surgery.

cancer resection is total mesorectal excision (TME), whose concept was popularized and promoted by Heald [4]. TME entails removal of the rectal cancer with its primary lymphovascular drainage as an intact unit, achieved by deliberate dissection along embryologically determined planes between the mesorectal and parietal pelvic fasciae. An avascular, areolar tissue plane known as the "holy plane" lies between them, which can be exposed by appropriate traction on the mesorectal fascia during surgery [5–7].

Meticulous, sharp dissection along this plane is essential to secure the circumferential resection margin (CRM) and facilitate proper TME, as an inadequate CRM is the main prognostic factor for local recurrence after TME [8, 9]. Additionally, TME is associated with pelvic autonomic nerve preservation, which averts urogenital and anorectal dysfunction [7, 10]. Sexual and anorectal dysfunction are among the most frequent complications associated with TMEs, followed by surgically induced postoperative neurogenic urinary dysfunction, which occurs in approximately one-third of cases [11]. Intraoperative damage to the pelvic autonomic nerves is the primary cause underlying postoperative sexual and urinary dysfunction after rectal cancer surgery [12, 13]. Therefore, accurate understanding of the fascial plane anatomy is crucial to achieve proper TME with oncological safety and functional preservation.

The theories of surgical expertise and empirical evidence suggest that expert surgeons can understand and visualize "safe" and "dangerous" zones of dissection within hostile territory and unknown anatomy [14]. Moreover, TME requires dissection of the holy plane, a "safe zone," without damaging the mesorectal and parietal pelvic fasciae, which are deemed "dangerous zones." Real-time intraoperative guidance on the patient's anatomy may improve surgical quality and safety, and artificial intelligence (AI), especially deep learning-based computer vision, which can be used for the identification and classification of objects in images and videos, might provide a solution. This study aimed to train deep learning models to identify anatomical landmarks in the pelvic fascial plane to achieve TME, and assess their performance to provide proof of concept of AI-guided TME.

2 | Materials and Methods

2.1 | Study Design

The protocol for this single-center, retrospective, observational study was reviewed and approved by the Ethics Committee of the National Cancer Center Hospital East (NCCHE), Chiba, Japan (registration number: 2020-315). Informed consent was obtained from all study participants in an opt-out manner according to the Ethical Guidelines for Medical and Biological Research Involving Human Subjects [15]. This study conformed to the provisions of the Declaration of Helsinki, 1964 (and 2013 revision in Brazil) [16].

2.2 | Semantic Segmentation Model

A deep learning model that can automatically identify anatomical landmarks in the pelvic fascial plane during laparoscopic TME in real time was developed. Target anatomical landmarks included the mesorectal fascia, parietal pelvic fascia, and holy plane between them. The mesorectal and parietal pelvic fasciae are considered "dangerous zones" in relation to oncological safety and functional preservation, respectively; conversely, the holy plane is regarded as a "safe zone," where dissection is recommended. The model employed a semantic segmentation algorithm that can interpret the meaning of each pixel in an image and display the recognition target as pixel aggregates. Feature Pyramid Networks [17] and EfficientNetB7 [18] were adopted as the neural network architecture and backbone network, respectively. The schema of the neural network architecture is shown in Figure 1. The network of the model was pretrained using ImageNet [19]. Details of the other hyperparameters used for model development are listed in Table S1.

2.3 | Dataset

Laparoscopic TME videos recorded between October 2013 and 2020 at NCCHE were collected and converted to MP4 format with a display resolution of 1280×720 pixels and a frame rate of 30 frames per second. The surgical videos were divided into static image units, and images capturing TME performed along

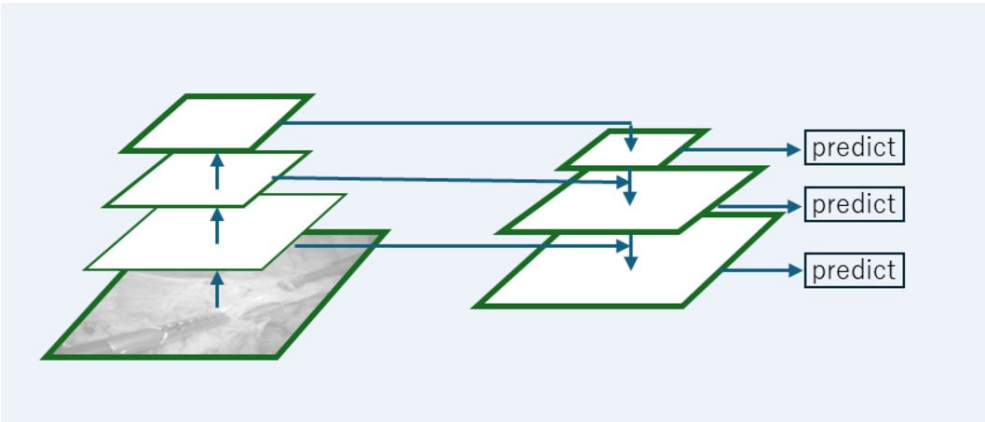

FIGURE 1 | Neural network architecture.

the correct planes of dissection were extracted for the annotation process.

2.4 | Annotation

In this study, the annotation process entailed manually labeling pixels corresponding to the mesorectal fascia, parietal pelvic fascia, and intervening holy plane on images. The process was performed by eight annotators under the supervision of two board-certified colorectal surgeons, and any discrepancies in annotation coverage were resolved by discussion on each occasion. Information on both annotated pixels and background images was input into the model as training data. The reference annotated images are shown in Figure 2. The TME plane was divided into three parts for convenience: the mesorectal fascia covering the mesorectum, which was colored blue; the parietal pelvic fascia covering the pelvic wall, which was colored red; and the intervening holy plane, which was colored green.

2.5 | Code and Computer Specifications

The code was written using Python version 3.6 (Python Software Foundation) and is available via GitHub upon reasonable request. Implementation of the model was based on TensorFlow (Google Inc., Mountain View, CA, USA), an open-source library for deep learning tasks. A computer equipped with a Tesla T4 GPU with 16 GB of VRAM (NVIDIA Corp., Santa Clara, CA, USA) and Xeon Gold 6230 CPU (2.10 GHz, 20 Core) with 48 GB of RAM (Intel Corp., Santa Clara, CA, USA) was used for network training.

2.6 | Evaluation Metrics

The surgical videos used for training and validation data were distinct. The Dice Similarity Coefficient (DSC), recall, and precision—calculated based on the number of true positives (TPs), false positives (FPs), and false negatives (FNs)—were used as the evaluation metrics.

Metrics such as the DSC and recall do not inherently include thresholds in their mathematical definitions, as they are computed directly from the number of TPs, FPs, and FNs.

The formula used to calculate these three metrics was as follows:

$$\mathrm{DSC} = \frac{2\mathrm{TP}}{2\mathrm{TP} + \mathrm{FP} + \mathrm{FN}}$$

$$\mathrm{Recall} = \frac{\mathrm{TP}}{\mathrm{TP} + \mathrm{FN}}$$

$$\mathrm{Precision} = \frac{\mathrm{TP}}{\mathrm{TP} + \mathrm{FP}}$$

The Normalized Surface Dice (NSD) was also employed as an evaluation metric [20]. The NSD served as a distance-based measurement for assessing performance. In contrast to the DSC, which measures the overlap of volumes, the NSD measures the overlap of two surfaces—that is, mask borders [20]—making it a suitable metric for the evaluation of the fascial planes, which were the recognition targets in this study. The formula for the NSD was as follows, where G and P represent mask borders of the ground truth and prediction, respectively.

$$\mathrm{NSD} = \frac{2\left(G \bigcap P\right)}{G + P}$$

Five-fold cross-validation was performed to calculate the above-mentioned indices. From a surgical standpoint, these evaluation metrics reflect how accurately the model can identify and delineate critical anatomical structures. A high DSC indicates strong agreement with the ground truth, suggesting that the model can reliably localize the target structure during surgery. NSD is particularly important for evaluating the fascial planes, where precise boundary recognition is essential for safe and effective dissection. Figure 3 presents representative examples of segmentation with high and low NSD. In both cases, the DSC remained relatively high due to sufficient regional overlap, but the NSD revealed differences in boundary alignment, particularly around the holy plane. These examples illustrate the manner in which DSC and NSD complement each other in capturing both overall segmentation performance and clinically relevant boundary accuracy.

3 | Results

3.1 | Annotation Dataset

A total of 2861 images from 157 surgical videos were annotated and used for the training and validation datasets. The number of videos and images used for cross-validation is shown in Table 1. All patients underwent laparoscopic TME, including

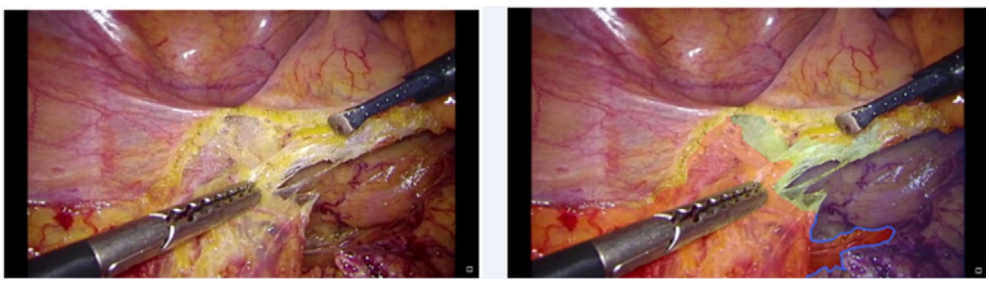

FIGURE 2 | Annotated image. The left panel shows the background image and the right panel shows annotated pixels.

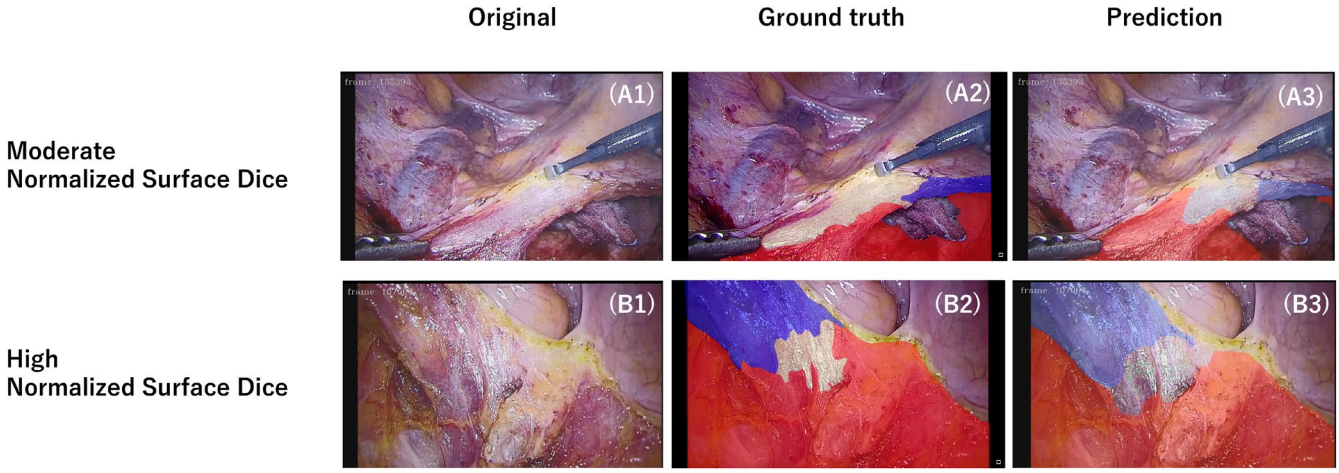

FIGURE 3 | Representative images showing the comparison of segmentation accuracy in cases with high and low Normalized Surface Dice (NSD) values. (A1–A3) A case with a high NSD value, where the predicted segmentation closely matches the ground truth. (B1–B3) A case with a lower NSD due to boundary misalignment around the holy plane. Although the Dice Similarity Coefficient remains relatively high in both cases, the NSD reflects the differences in boundary alignment with greater clarity. From left to right: Manual annotation by surgeons, original laparoscopic image, and the model's predicted segmentation. In the annotations, the mesorectal fascia is depicted in red, the parietal pelvic fascia in blue, and the holy plane in green. In the predicted images, the holy plane is depicted in white for visiblity.

TABLE 1 | Number of cases and videos.

	CV1	CV2	CV3	CV4	CV5
Videos	29	31	34	31	32
Images	548	573	581	585	574

Note: All videos and images are divided into five segments; four were used in the training dataset, and one was used in the validation dataset.
Abbreviation: CV, cross-validation.

low anterior resection and intersphincteric resection, for rectal cancer. The patient background information was missing in 11 cases; the available patient background information for 146 cases is listed in Table 2.

3.2 | Model Performance

The results of quantitative evaluation using the DSC, precision, recall, and NSD are shown in Table 3.

The DSC values in the semantic segmentation task were similar for the mesorectal and parietal pelvic fasciae at 90.4% and 90.6%, respectively, and lower for the holy plane at 68.5%. The NSDs for the three fasciae were 70.4%, 73.2%, and 54.6%, respectively. The results of inference by the model are shown in Figure 4 and Video S1, where the left side displays the original image, and the right shows the image with the inference outputs overlaid. The blue region is inferred to be the mesorectum covered by mesorectal fascia, the red region is the pelvic wall covered by the parietal pelvic fascia, and the white region is the intervening holy plane. The holy plane was demarcated in green in the annotation, while the output results are shown in white to ensure visibility. The video shows that the three

TABLE 2 | Patients' background characteristics.

Variables	All cohort ($n = 157$)
Sex (male)	103 (65.6)
Age (year)	64 (37–86)
BMI (kg/m^2)	23.2 (14.5–32.1)
Tumor localization	
Rectosigmoid	52 (33.1)
Upper rectum	86 (54.8)
Lower rectum	8 (5.1)
Unknown	11 (7.0)
Clinical stage in carcinoma cases (UICC eight edition)	
I	62 (42.5)
II	36 (24.7)
III	34 (23.3)
IV	11 (7.5)
Unknown	3 (2.0)
TME quality	
Complete	146 (93.0)
Unknown	11 (7.0)
Neoadjuvant therapy	
Neoadjuvant radiotherapy	9 (6.2)

Note: Data are presented as the number of cases (%). Continuous variables are presented as the median (range).
Abbreviations: BMI, body mass index; TME, total mesorectal excision; UICC, Union for International Cancer Control.

TABLE 3 | Model performance across five-fold cross-validation.

Metric	Region	CV1	CV2	CV3	CV4	CV5	Mean
Normalized Surface Dice	Blue	0.72	0.74	0.72	0.73	0.73	0.728
	Red	0.73	0.74	0.73	0.74	0.72	0.732
	Green	0.54	0.55	0.54	0.54	0.56	0.546
Dice Similarity Coefficient	Blue	0.89	0.92	0.89	0.91	0.91	0.90
	Red	0.91	0.91	0.91	0.90	0.90	0.91
	Green	0.69	0.69	0.69	0.67	0.69	0.69
Recall	Blue	0.89	0.93	0.90	0.93	0.90	0.91
	Red	0.91	0.91	0.91	0.89	0.91	0.91
	Green	0.74	0.68	0.73	0.78	0.70	0.73
Precision	Blue	0.90	0.91	0.88	0.89	0.91	0.90
	Red	0.91	0.91	0.90	0.91	0.90	0.91
	Green	0.65	0.70	0.66	0.59	0.68	0.66

Note: The table depicts figures describing the accuracy of each region by the model. Each color corresponds to the following anatomical regions: blue = mesorectal fascia, red = parietal pelvic fascia, green = holy plane. Each evaluation metric is defined as follows: the Normalized Surface Dice evaluates boundary accuracy, the Dice Similarity Coefficient measures region overlap, recall indicates the sensitivity of prediction, and precision represents the proportion of true positive predictions among all positive predictions.
Abbreviation: CV, cross-validation.

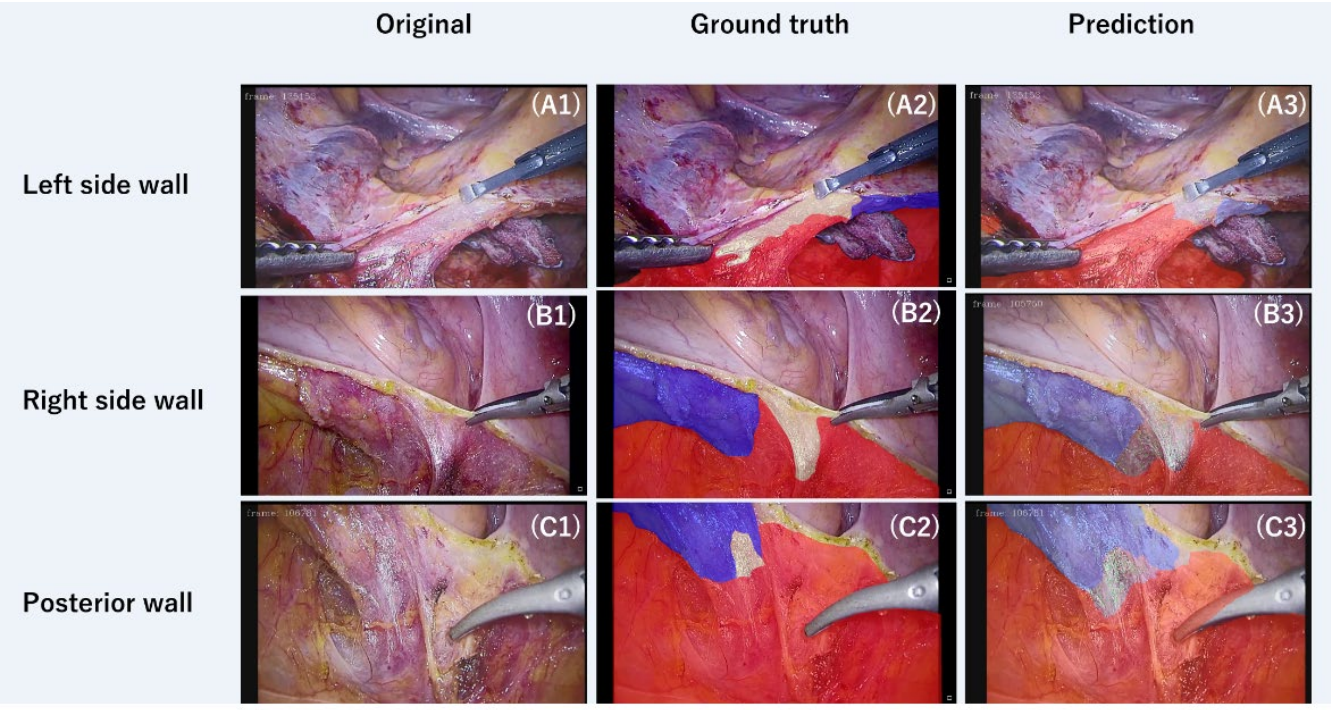

FIGURE 4 | Segmentation results across different pelvic wall regions. Each row presents a different anatomical area: (A) left wall, (B) right wall, and (C) posterior wall. The columns show (from left to right) the original image (1), ground truth (2), and AI prediction (3). In the annotations, the mesorectal fascia is shown in red, the parietal pelvic fascia in blue, and the holy plane in green. In the predicted images, the holy plane is depicted in white for visiblity.

regions are generally inferred correctly; however, some instances where the surgical field moved significantly due to forceps, or where the pelvic wall was incorrectly inferred to be in the red region, were observed.

4 | Discussion

In this study, we constructed a deep learning model to identify the mesorectal fascia covering the mesorectum, parietal

pelvic fascia covering the pelvic wall, and intervening holy plane during TME. The model was constructed using 2861 images extracted from 157 cases of laparoscopic TME surgery. The region-wise DSCs were 90.6% for the mesorectal fascia, 90.4% for the parietal pelvic fascia, and 68.5% for the holy plane. To achieve TME, each part of the pelvic fascial anatomy should be recognized separately, suggesting that the developed model may provide important information for TME.

Visualization of the target organ and surrounding anatomy is one of the most fundamental elements of precise and safe surgery. Preoperative medical images, such as those obtained via computed tomography (CT) and magnetic resonance imaging (MRI), are commonly utilized to acquire anatomical information [21, 22]; an intraoperative navigation system that uses this information to present the positional relationship of the target organ and surrounding anatomy to the surgeon in real time is also being studied [23–26]. However, surgical navigation using preoperative images is problematic because it cannot respond to changes in the surgical field during the operation. Organs such as the intestines can undergo significant deformations and movements during surgery, resulting in notable differences between the intraoperative situation and preoperative images, making their application cumbersome. Overcoming this problem requires a system that can navigate images even in intraoperative conditions that differ from those of preoperative images. In this milieu, imaging navigation using deep learning that leverages a vast number of images obtained intraoperatively as training data may be promising [27, 28].

The recurrence rates, survival rates, and quality of life of patients with rectal cancer have improved significantly, owing to advances in preoperative staging, pathologic evaluation, development of multidrug therapy, and surgical techniques. However, the most significant contribution to advancements in rectal cancer care may be the standardization and widespread implementation of TME, which was first conceptualized by Heald in 1979 [4]. TME involves the removal of the mesorectum without damaging the mesorectal and parietal pelvic fasciae, while preventing urogenital and anorectal dysfunction [5–7]. Heald posited that rectal cancer does not spread distally along the muscular tube, but rather along areas of active lymphatic and venous flow. Therefore, surgery for rectal cancer requires the removal of these structures to arrest the spread of cancer. Heald explained that the potential space along the avascular interface between the mesorectum and surrounding somatic structures, namely the holy plane, is the appropriate plane of dissection for removal [4]. Adequate TME along the holy plane is essential in rectal cancer surgery and remains a major prognostic factor for recurrence [29].

Deep learning models aimed at supporting the execution of TME should be able to recognize and identify the mesorectal and parietal pelvic fasciae as well as the intervening holy plane. Furthermore, these regions must be accurately visualized in real time during surgery. Accuracy in recognizing the boundaries of each region is especially crucial for achieving the research concept in this study. In our previous research [30], the model was only able to recognize the holy plane; however, in the present study, we augmented this ability to include the mesorectum and parietal pelvic fasciae. In this study, we evaluated the boundary recognition accuracy of the deep learning model using the NSD. The deep learning model developed in this study only displays each area as a region with different colors; in the future, it is necessary to devise a system aimed at improving surgical outcomes by implementing methods such as triggering alarms to alert surgeons when they try to perform dissection in the wrong region. The incorporation of such functions was not feasible in our previous study, which only recognized the holy plane. Moreover, there is potential for this model to be utilized for surgical skill evaluation by measuring metrics such as the number of wrong incisions made into the mesorectal and parietal pelvic fascial regions as well as the duration of accurate dissection within the holy plane.

This study has some limitations. First, it is in the proof-of-concept phase and has not been implemented in real-world clinical settings; therefore, we could not verify whether the application of the deep learning model would yield an improvement in patient outcomes. Future clinical studies are warranted to demonstrate its real-world utility. Second, the accuracy of the model was insufficient. Although the DSC was relatively high at 90% for the mesorectal and parietal pelvic fascial regions, it was lower for the holy plane region at 68%, probably due to its smaller size, which makes the Dice score more sensitive to minor errors. Furthermore, to attain the objective of this study, which is performing TME while preserving the pelvic nerves, it is essential to improve the accuracy of the boundaries of each region, as indicated by the NSD. Although the NSD is less susceptible to region size, it also showed lower performance for the holy plane, probably due to the difficulty in recognizing its boundary. This is because, unlike the other two structures, the holy plane is not a distinct anatomical entity, but a virtual plane whose appearance changes with lighting and traction. Third, the training data were acquired from a single institution, were limited to laparoscopic TME, and did not include robotic surgery. Additionally, since all cases underwent standard TME, training data for cases where TME was performed incorrectly are lacking. Future studies should incorporate larger samples and a more diverse range of data, focusing on cases involving TME performed along incorrect planes of dissection, lower rectum involvement, as well as cases treated with chemoradiotherapy and total neoadjuvant therapy. Fourth, the developed model does not yet possess the ability to perform real-time inference, which is essential for clinical application. The processing time for intraoperative images is challenging; however, it is believed that this issue could be overcome by improving processing speeds due to advancements in personal computer performance, enabling real-time inference.

5 | Conclusion

In this study, we constructed a deep learning model that recognizes three regions—the mesorectal fascia, parietal pelvic fascia, and intervening holy plane—during TME with a relatively high DSC, successfully providing proof of concept for AI-guided TME. This system is expected to find application in clinical practice in the future and further improve surgical outcomes.

Author Contributions

Yuta Suzuki: validation, writing – original draft, writing – review and editing. **Daichi Kitaguchi:** methodology, validation, formal analysis,

investigation, data curation, writing – original draft, writing – review and editing. **Norihito Kosugi:** software, validation, formal analysis, investigation, project administration. **Hiro Hasegawa:** validation, investigation. **Nobuyoshi Takeshita:** validation. **Yusuke Kinugasa:** writing – review and editing. **Masaaki Ito:** conceptualization, methodology, validation, formal analysis, resources, writing – review and editing, visualization, supervision, funding acquisition.

Acknowledgments

This work was supported by the Terumo Life Science Foundation. We would like to thank Editage (www.editage.jp) for English language editing.

Ethics Statement

This protocol of this single-center, retrospective, observational study was reviewed and approved by the Ethics Committee of the National Cancer Center Hospital East (NCCHE), Chiba, Japan.

Consent

Informed consent was obtained from all study participants in an opt-out manner, according to the Ethical Guidelines for Medical and Biological Research Involving Human Subjects. Registration number: 2020-315.

Conflicts of Interest

Author Y.K. (Yusuke Kinugasa) is an editorial board member of the *Annals of Gastroenterological Surgery*. The other authors declare no conflicts of interest.

Data Availability Statement

The datasets used and/or analyzed in the present study are available from the corresponding author on reasonable request. The corresponding author had full access to all the data in the study and takes responsibility for the integrity of the data and the accuracy of the data analysis.

References

1. H. Brenner, M. Kloor, and C. P. Pox, "Colorectal Cancer," *Lancet* 383, no. 9927 (2014): 1490–1502.

2. H. Sung, J. Ferlay, R. L. Siegel, et al., "Global Cancer Statistics 2020: GLOBOCAN Estimates of Incidence and Mortality Worldwide for 36 Cancers in 185 Countries," *CA: A Cancer Journal for Clinicians* 71, no. 3 (2021): 209–249.

3. E. F. Onyoh, W. F. Hsu, L. C. Chang, Y. C. Lee, M. S. Wu, and H. M. Chiu, "The Rise of Colorectal Cancer in Asia: Epidemiology, Screening, and Management," *Current Gastroenterology Reports* 21, no. 8 (2019): 36.

4. R. J. Heald, "A New Approach to Rectal Cancer," *British Journal of Hospital Medicine* 22, no. 3 (1979): 277–281.

5. G. Salerno, C. Sinnatamby, G. Branagan, I. R. Daniels, R. J. Heald, and B. J. Moran, "Defining the Rectum: Surgically, Radiologically and Anatomically," *Colorectal Disease* 8, no. Suppl 3 (2006): 5–9.

6. R. J. Heald, "The 'Holy Plane' of Rectal Surgery," *Journal of the Royal Society of Medicine* 81, no. 9 (1988): 503–508.

7. R. J. Heald, E. M. Husband, and R. D. Ryall, "The Mesorectum in Rectal Cancer Surgery—The Clue to Pelvic Recurrence?," *British Journal of Surgery* 69, no. 10 (1982): 613–616.

8. P. Quirke, R. Steele, J. Monson, et al., "Effect of the Plane of Surgery Achieved on Local Recurrence in Patients With Operable Rectal Cancer: A Prospective Study Using Data From the MRC CR07 and NCIC-CTG CO16 Randomised Clinical Trial," *Lancet* 373, no. 9666 (2009): 821–828.

9. R. J. Heald, I. Santiago, O. Pares, C. Carvalho, and N. Figueiredo, "The Perfect Total Mesorectal Excision Obviates the Need for Anything Else in the Management of Most Rectal Cancers," *Clinics in Colon and Rectal Surgery* 30, no. 5 (2017): 324–332.

10. G. Bregni, T. Akin Telli, S. Camera, et al., "Grey Areas and Evidence Gaps in the Management of Rectal Cancer as Revealed by Comparing Recommendations From Clinical Guidelines," *Cancer Treatment Reviews* 82 (2020): 101930.

11. F. Nocera, F. Angehrn, M. von Flüe, and D. C. Steinemann, "Optimising Functional Outcomes in Rectal Cancer Surgery," *Langenbeck's Archives of Surgery* 406, no. 2 (2021): 233–250.

12. M. H. Chew, Y. T. Yeh, E. Lim, and F. SeOw-Choen, "Pelvic Autonomic Nerve Preservation in Radical Rectal Cancer Surgery: Changes in the Past 3 Decades," *Gastroenterology Report* 4, no. 3 (2016): 173–185.

13. H. S. Kim, J. H. Kang, S. Y. Yang, and N. K. Kim, "Long-Term Voiding and Sexual Function in Male Patients After Robotic Total Mesorectal Excision With Autonomic Nerve Preservation for Rectal Cancer: A Cross-Sectional Study," *Surgical Laparoscopy, Endoscopy & Percutaneous Techniques* 30, no. 2 (2020): 137–143.

14. A. Madani, M. C. Vassiliou, Y. Watanabe, et al., "What Are the Principles That Guide Behaviors in the Operating Room?: Creating a Framework to Define and Measure Performance," *Annals of Surgery* 265, no. 2 (2017): 255–267.

15. J. Eba and K. Nakamura, "Overview of the Ethical Guidelines for Medical and Biological Research Involving Human Subjects in Japan," *Japanese Journal of Clinical Oncology* 52, no. 6 (2022): 539–544.

16. World Medical Association, "World Medical Association Declaration of Helsinki: Ethical Principles for Medical Research Involving Human Subjects," *Journal of the American Medical Association* 310, no. 20 (2013): 2191–2194.

17. X. Zhang, Y. Li, J. Du, et al., "Feature Pyramid Networks and Long Short-Term Memory for EEG Feature Map-Based Emotion Recognition," *Sensors (Basel)* 23, no. 3 (2023): 1622.

18. V. Panteris, D. Kalles, V. S. Verykios, et al., "A Deep Learning Model for Classifying Histological Types of Colorectal Polyps," *Studies in Health Technology and Informatics* 305 (2023): 549–552.

19. O. Russakovsky, J. Deng, H. Su, et al., "ImageNet Large Scale Visual Recognition Challenge," *International Journal of Computer Vision* 115, no. 3 (2015): 211–252.

20. T. Ross, A. Reinke, P. M. Full, et al., "Robust Medical Instrument Segmentation (ROBUST-MIS) Challenge 2019," *arXiv* (2020), https://doi.org/10.7303/syn18779624.

21. A. Filter, "The History, Development and Impact of Computed Imaging in Neurological Diagnosis and Neurosurgery: CT, MRI, and DTI," *Nature Proceedings* (2009), https://doi.org/10.1038/npre.2009.3267.3.

22. P. C. Lauterbur, "Image Formation by Induced Local Interaction: Examples Employing Nuclear Magnetic Resonance," *Nature* 242 (1973): 190–191.

23. S. Atallah, B. Martin-Perez, and S. Larach, "Image-Guided Real-Time Navigation for Transanal Total Mesorectal Excision: A Pilot Study," *Techniques in Coloproctology* 19, no. 11 (2015): 679–684.

24. P. M. Black, T. Moriarty, E. Alexander, 3rd, et al., "Development and Implementation of Intraoperative Magnetic Resonance Imaging and Its Neurosurgical Applications," *Neurosurgery* 41, no. 4 (1997): 831–842; discussion 842–845.

25. Y. Muragaki, H. Iseki, T. Maruyama, et al., "Usefulness of Intraoperative Mafnetic Resonance Imaging for Glioma Surgery," *Acta Neurochirurgica Supplement* 98 (2006): 67–75.

26. S. S. Chopra, S. C. Schmidt, R. Eisele, et al., "Initial Results of MR-Guided Liver Resection in a High-Field Open MRI," *Surgical Endoscopy* 24, no. 10 (2010): 2506–2512.

27. D. Kitaguchi, N. Takeshita, H. Matsuzaki, et al., "Realtime Vascular Anatomical Image Navigation for Laparoscopic Surgery: Experimental Study," *Surgical Endoscopy* 36, no. 8 (2022): 6105–6112.

28. A. Madani, B. Namazi, M. S. Altieri, et al., "Artificial Intelligence for Intraoperative Guidance Using Semantic Segmentation to Identify Surgical Anatomy During Laparoscopic Cholecystectomy," *Annals of Surgery* 276, no. 2 (2022): 363–369.

29. J. Knol and D. S. Keller, "Total Mesorectal Excision Technique—Past, Present, and Future," *Clinics in Colon and Rectal Surgery* 33, no. 3 (2020): 134–143.

30. T. Igaki, D. Kitaguchi, S. Kojima, et al., "Artificial Intelligence-Based Total Mesorectal Excision Plane Navigation in Laparoscopic Colorectal Surgery," *Diseases of the Colon and Rectum* 65, no. 5 (2022): e329–e333.

Supporting Information

Additional supporting information can be found online in the Supporting Information section.