Image Enhancement Technique for MRI Brain Images

Toufique Ahmed Soomro
Dept. of Electronics Engineering
The University of Lakano
Larkano, Pakistan
toufique_soomro@uolrk.edu.pk

Mahaveer Rathi
ETSI Telecommunication
Universidad de Malaga
Malaga, Spain
mahaveer.rathi@gmail.com

Shafique Ahmed Soomro
Dept. of Electrical Engineering
Indus University
Karachi, Pakistan
shafiq.soomro@indus.edu.pk

Muhammad Usman Keerio
Depart. of Electrical Engineering
QUEST
Nawabshah, Pakistan
usmankeerio@quest.edu.pk

Pardeep Kumar
Dept. of Software Engineering
QUEST
Nawabshah, Pakistan
pardeep.kumar@quest.edu.pk

Enrique Nava Baro
ETSI Telecommunication
Universidad de Malaga
Malaga, Spain
en@uma.es

2024 Global Conference on Wireless and Optical Technologies (GCWOT) | 979-8-3315-3427-1/24/$31.00 ©2024 IEEE | DOI: 10.1109/GCWOT63882.2024.10805684

***Abstract*—Magnet Resonance Imaging (MRI) is a medical imaging technique that produces high-quality images of human body organs. MRI is mostly used to analyze brain images and diagnose brain tumors. MRI images suffer from noise and low varying contrast. The noise is the main factor that degrades the image quality and affects the image's contrast. The image enhancement technique is proposed, and it contains only three stages. The first stage handles the noise level of MRI brain images using a sub-space least square estimator, the second stage is for contrast normalization using the Retinex algorithm, and the third stage is for contrast enhancement using independent component analysis. The Oasis image database contains data from 38 patients and three sets of image views of each patient as axial, coronal, and sagittal images. Peak signal-to-noise ratio (PSNR) and contrast improvement ratio are evaluation parameters. It is observed that the axial and coronal image databases gave an efficient contrast improvement ratio of 1.4 at 2.5dB and 1.29 at 2.29dB, respectively, compared to the sagittal image view of 1.18 at 2.35dB.**

Keywords—MRI Brain images, Image Enhancement, Contrast Improvement Ratio, and Peak signal noise Ratio.

I. Introduction

In a medical examination, Magnet Resonance Imaging uses pulses of radio wave energy and a magnetic field to render structures in the body and visualise organs as an image. Many cases of MRIs have different information about human body organs because it depends upon the position of the human body[1]. Every MRI machine has a different function for visualisation of the human body. An ultrasound, CT (computed tomography) scan, x-ray scan, and MRI of various body parts shows problems other methods cannot observe 2]. MRI imaging also observes brain abnormalities such as lesions andumors [3].

One of the most serious and potentially fatal diseases that are drastically rising in the human population is brain tumors. A brain tumor is a mass of tissue created by aberrant brain cells growing out of control [4]. Primary brain tumors account for the majority of brain tumors found in children [5]. However, in adults, brain tumors are classified as secondary or metastatic tumors indicating that the cancer has moved from the breast, lung, or other parts of the body to the brain [6], [7]. It was predicted that people with secondary brain tumors would only live for a few weeks following the discovery of the tumor [7], [8], [9]

The image of the brain's internal structure is made with the help of brain scanning. To check for brain tumors the most often used scans are PET (positron emission tomography) CT or CAT (computed tomography) and MRI [10] [11]. The study of the human brain has found that MRI is one of the most advanced medical imaging methods that is a useful tool. Ironically the quality of the brain image has significantly improved due to the information provided by MR images regarding the soft tissue anatomy. MRI scan images are utilised in computer intelligence to accurately detect diseases such as brain tumors through image processing methods [12]. To do this algorithm must be created that will enable computers to distinguish between the normal and abnormal MRI images displayed in Figure 1.

II. Literature Review

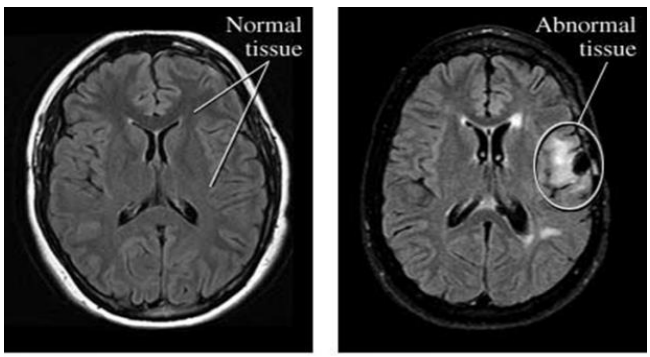

Fig. 1. Normal Brain Image and Abnormal Brain Image [25]

Many researchers [2], [11], [13] use segmentation techniques to detect brain tumors but these techniques require pre-processing steps such as noise reduction uniform contrast, and contrast enhancement. The two main steps in image pre-processing are image enhancement and noise removal[1],

Authorized licensed use limited to: Sharda University. Downloaded on October 14,2025 at 05:26:42 UTC from IEEE Xplore. Restrictions apply.

[14]. It is possible to remove noise by applying filters such as Laplacian Robert and Prewitt Sobel median. However, to improve the efficacy of image enhancement techniques contrast normalisation technique is a necessary step in the case of medical images. This study created a non-invasive image processing method to address the fluctuating low contrast problems and noise levels of MRI brain images. Three steps made up the technique: the first removed noise using the sub-space Least sq. Estimator (LSE) technique [15], [16] the second normalised contrast using the Macann Retinex algorithm [17], and the third enhanced the MRI brain image [18] using independent component analysis. Peak signal-to-noise ratio and contrast measurement are the foundation for the performance assessment. Utilised is the Oasis publicly accessible database. As seen in Figure 2, it was divided into three sets, each of which included 38 MRI brain images of each panel axial coronal and sagittal views.

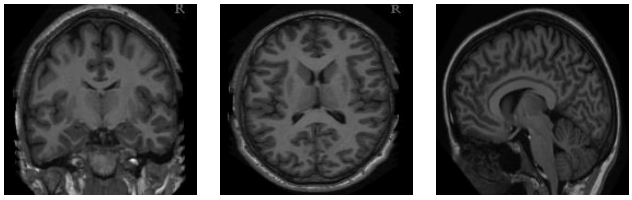

Axial View Coronal View Sagittal View

Fig. 2. Example of one set of Oasis MRI Image Dataset

III. PROPOSED APPROACH

Consider Figure 3 in the proposed MRI brain image enhancement technique with a combination of three techniques comprising three stages. The First stage contains Sub space least square estimator, which is used to handle the noise level of the image. The second stage is contrasts normalisation through the Retinex algorithm and the third stage performs contrast enhancement using Independent Component Analysis (ICA) else. Retinex and ICA together used by H. Nugroho et al[19] on model retinal fundus images and later Toufique et al [20] applied Retinex along with ICA on real fundus images. These three stages are elaborated below sub-sections.

A. Contrast Normalisation

The MRI brain image is processed using the Retinex algorithm to generate the corresponding normalised image as shown in Figure 3. Normalisations primary goal is to produce the uniform contrast Retinex image depicted in Figure 3. For contrast normalisation, the Retinex McCann algorithm is employed. A multilevel one-dimensional Retinex algorithm [21] was developed by McCann et al. [17] to improve the random walk Retinex algorithm. McCann et al. [17] presented the iterative Retinex though, which uses ratio-product-reset-average to iterate through concepts of multi-resolution pyramids, as shown in Figure 4.

The algorithm produces data layers that mimic a multi-resolution image pyramid as shown in Figure 4 by averaging the input data as an image. One of the most important parts of the Retinex method for calculating lightness is comparing a pixel's value to other pixels in the image. Starting at the highest most averaged level of the multi-resolution pyramid this comparison is made.

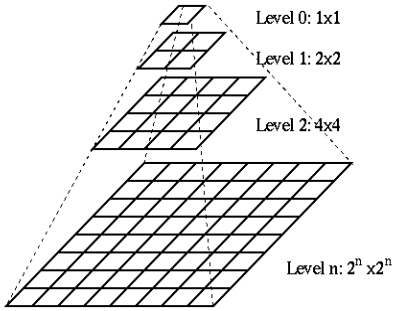

Fig. 4. Image Pyramid [26]

The Retinex algorithm uses a multi-resolution pyramid to process picture data. The image lightness is first calculated at a lower resolution (the top level of the pyramid) to propagate these lightness values down to the next level by replicating pixels. Starting from this initial estimate, lightness estimates at each level are refined until the original image resolution is reached at the base of the pyramid. The pyramid structure is used by the algorithm to guide its iterations. It starts moving from long-distance iterations toward short-distance iterations gradually.

The direction of pixel comparison shifts clockwise and the spacing between the pixels being compared gets smaller by one pixel shift at each step [22]. Each step of the process computes the reflectance part iteratively a predetermined number of times using the ratio-product-reset-average operation. For the algorithm to work the number of iterations is essential[23].

B. Least Squares Estimator (LS)

The Least Square Estimator (LSE) is a linear sub-space technique. According to Equation 1 for estimation H, LSE [23] decreases the distance between the signal sub-space $s = H\Theta$ and the noisy vectors $x \in R^m$.

$$min_{H,\Theta}\|x - H\Theta\|_2^2 = min_{H,\Theta}\{\left((x - H\Theta)^T(x - H\Theta)\right)\} \quad (1)$$

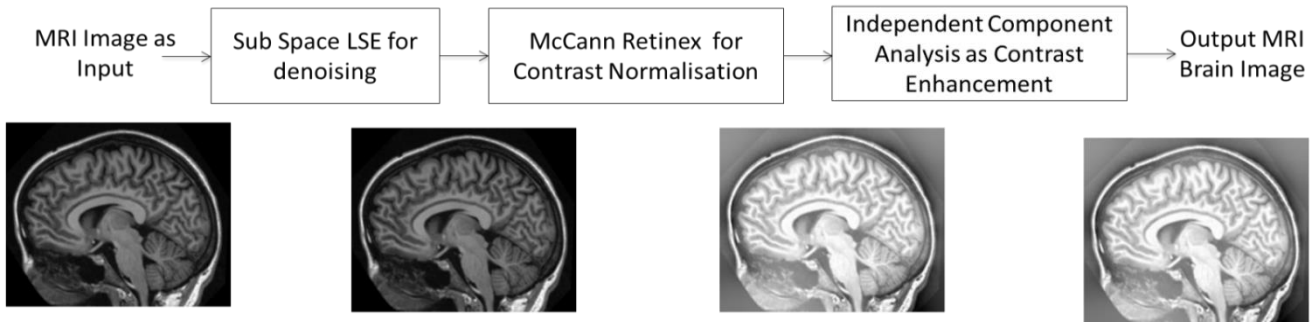

Fig. 3. Example of one set of Oasis MRI Image Dataset

Authorized licensed use limited to: Sharda University. Downloaded on October 14,2025 at 05:26:42 UTC from IEEE Xplore. Restrictions apply.

Mathematically it is demonstrated in Equation 2, as shown below for a data matrix with n realisations $X \in R^{m\times n}$ and a low-rank model $S = H\Theta$

$$min_{H,\theta}\|X - H\Theta\|_2^2 = min_{H,\theta}\{((X - H\Theta)^T(X - H\Theta))\} \quad (2)$$

To get noiseless data consider Equation 3

$$parent\varepsilon^2 = \|X - H\Theta\|_2^2 = \sum_{i=1}^{n}\|X - H\Theta\|_2^2 = \sum_{i=1}^{n}((x_i - H\Theta_i)^T(x_i - H\Theta_i)) \quad (3)$$

There are two estimation cases to get the noiseless data as defined in the following sub-section.

1) Case 1: Assume H is known: Assume **H** is known in Equation 7, and then the gradient of ε^2 concerning $\boldsymbol{\Theta}$ is given by Equation 4.

$$\frac{\partial\varepsilon^2}{\partial\boldsymbol{\Theta}} = \left(\frac{\partial\varepsilon^2}{\partial\boldsymbol{\Theta_1}}, \frac{\partial\varepsilon^2}{\partial\boldsymbol{\Theta_2}} \ldots \frac{\partial\varepsilon^2}{\partial\boldsymbol{\Theta_n}}\right) = (-2H^T(x_1 - H\Theta_1), -2H^T(x_2 - H\Theta_2), \ldots -2H^T(x_n - H\Theta_n) \quad (4)$$

If the gradient is zero, then LSE is associated with Equation 5.

$$[\boldsymbol{\Theta_1}\ \boldsymbol{\Theta_2} \ldots \boldsymbol{\Theta_n}] = (H^TH)^{-1}H^T \times [\boldsymbol{x_1}\ \ \boldsymbol{x_2} \ldots \boldsymbol{x_n}] = \hat{\Theta}_{LS} = (H)^{-1}H^T \times X = H^+X \quad (5)$$

Here pseudo inverse for H is H^+For the estimation of S, signal space is shown in Equation 6.

$$\hat{S}_{LS} = H\hat{\Theta}_{LS} = H(H^TH)^{-1}H^TX = (HH^+)X = P_H \quad (6)$$

2) Case 2: Assume H is unknown: In the second case we can assume that **H** is unknown then ε^2 must be minimised concerning H. Using the estimated $\hat{\Theta}_{LS}$ as Equation 7.

$$\varepsilon^2 = \|X - H\Theta\|_F^2 = tr((X - H\Theta)^T(X - H\Theta)) = tr((X - H(H^TH)^{-1}H^TX)^T(X - H(H^TH)^{-1}H^TX)) = tr(P_HX^TXP_H) = tr(P_{\bar{H}}R_{\bar{X}}P_{\bar{H}}) \quad (7)$$

The signal subspace {span(H)} which is determined by the least squares (LS) estimate of the matrix H, as given in Equation 8 is an orthogonally complement subspace to which the operation $P_{\bar{H}} = I - P_H$ is applied.

$$H\hat{}_LS = V_XI \quad (8)$$

The expected LS of noiseless data of vector S is given in Equation 9.

$$\hat{S}_{LS} = \boldsymbol{H}(H^TH)^{-1}H^TX = V_{XI}\,(V_{XI}{}^TV_{XI})^{-1}V_{XI}{}^TX = (V_{XI}\,V_{XI}{}^T)X = P_{V_{XI}}\,X \quad (9)$$

Equation 9 represents the projection of X on the signal subspace.

C. Contrast Enhancement:

The symmetrical orthogonalization method with the FastICA algorithm is used to estimate independent components because it is highly accurate and computationally efficient for high-dimensional data [20]. The output image from the Retinex algorithm (Normalised Images) is then fed into the ICA as shown in Figure 3. The low-contrast MRI brain image is improved in this case. Two criteria are used to evaluate the performance of the enhancement technique. The white foreground representing the brain's nerves and the black background representing the brain's nerves in an MRI brain image are used to measure contrast. The second parameter studies the impact of noise on image contrast and is the Peak Signal to Noise Ratio.

D. Signal-to-Noise Ratio of the Fundus Images:

The noisy signal or image ratioo the signal level or image is known as the Peak Signal to Noise Ratio (PSNR) [24]. Scientifically is shown in Equation 10.

$$PSNR = 20\log_{10}\left(\frac{R}{\sigma}\right) \quad (10)$$

Since R is the maximum value of the image and is regarded as the peak intensity of a digital image it can range from 0 to 255 in Equation 10. Whereas σ is the variance of the image intensities.

E. Contrast determination:

Though contrast measurement is a crucial parameter for biomedical images there are numerous ways to compute image contrast[20]. The contrast of the MRI brain image is calculated as the absolute mean intensity difference between the black background and the white foregrounds, as seen in Figure 5. Consider Figure 5, where the blue dots show the pixel value of white foregrounds, and the red dots show the pixels of black background. Equation 11 is used to determine this.

$$C_{|fn-bn|} = \left|\frac{1}{n}\left(\sum_{i=1}^{n} I_{fni} - \sum_{i=1}^{n} I_{bni}\right)\right| \quad (11)$$

Here, the contrast between the black background and the white foreground of the MRI Image $C_{|fn-bn|}$ is the contrast MRI of the brain. The terms, I_{fni} and I_{bni}, respectively are the intensities of the white foreground of the MRI brain image and the black background. Here n defines the number of pixels, which has values of n=100. The location of a pixel is selected randomly while measuring contrast.

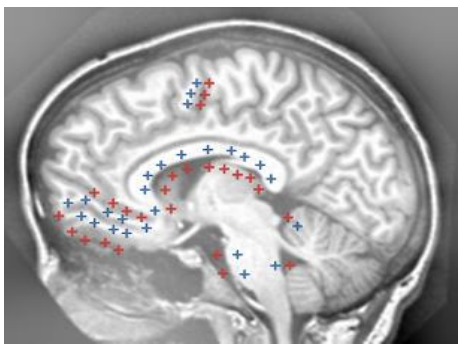

Fig. 5. Contrast measurements Method of MRI Brain Image

IV. Results & Analysis

The observations of PSNR and the contrast of MRI brain images of the OASIS database are discussed in this results and analysis section. The database contained three sets of each view, i.e., 38 patients named 38 images of Axial View, 38 images of Coronal View images, and 38 images of Sagittal View. The Oasis image database contains a resolution of 176×208. The above-defined sets database measures the

Authorized licensed use limited to: Sharda University. Downloaded on October 14,2025 at 05:26:42 UTC from IEEE Xplore. Restrictions apply.

PSNR of the original image, PSNR of denoised LSE, and PSNR of the Retinex image. It is observed that the better PSNR is achieved in sagittal images (original image PSNR: 17.81dB, PSNR LSE: 19.05dB, PSNR Retinex: 20.15dB) view is 0.5dB more than axial (original image PSNR: 17.60dB, PSNR LSE: 18.8dB, PSNR Retinex: 20.1dB) and coronal views (original image PSNR: 17.44dB, PSNR LSE: 18.63dB, PSNR Retinex: 20.1dB) of images as shown in Figure 6.

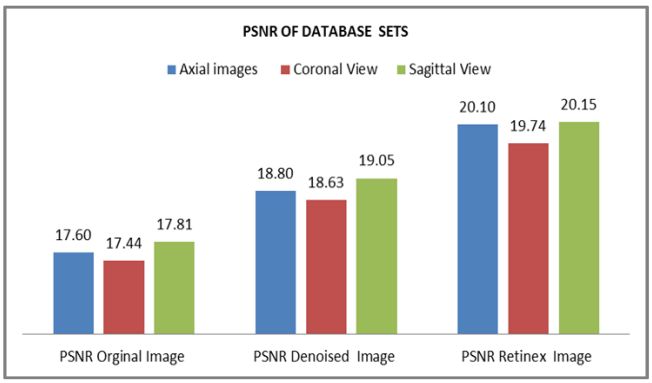

Fig. 6. PSNR (dB) observations in three sets of MRI Brain dataset

Furthermore, improved PSNR is observed among the original PSNR and PSNR of the denoised image. Improvement in PSNR is measured between the Retinex image PSNR and the PSNR of the denoised image. Overall, it has been measured that PSNR is improved between Retinex image PSNR and PSNR of original images. The average PSNR improvement of all three sets of images is shown in Figure 7. It is observed that sagittal images PSNR improvement in axial images is 2.5dB compared to coronal images 2.29dB and sagittal images 2.35dB and almost equal PSNR improvement achieved.

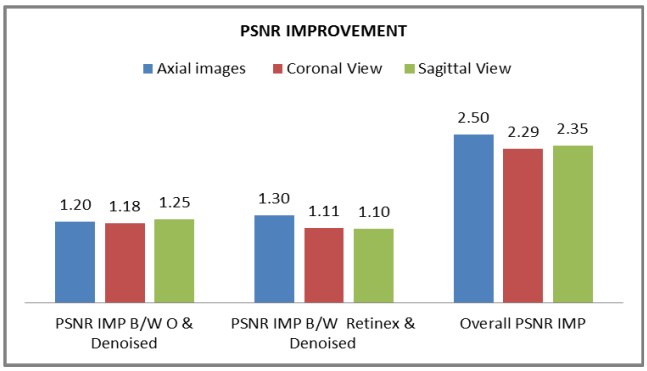

Fig. 7. PSNR Improvement (dB) of MRI Brain dataset

The contrast between the Retinex image output and the ICA image output image is calculated. It is the best observation to know the best contrast set of MRI brain images dataset as it is observed that almost equal PSNR measurement is achieved. Still, the contrast in the sagittal image is achieved low compared to axial images of a coronal view of MRI brain database as shown in Figure 8. Almost equal contrast value is obtained in the axial and coronal view images databases, and abnormalities in these image views are observed more easily than in sagittal image views. The contrast improvement ratio between the Retinex image and the contrast of ICA images are shown in Figure 9 along with overall PSNR improvement. It is observed that Axial image views achieved the highest PSNR: 2.5dB improvement and gave the highest contrast improvement ratio of 1.40, respectively coronal images PSNR: 2.29dB and CIR: 1.29 and sagittal PSNR: 2.35dB CIR: 1.18. The contrast needs to improve in the sagittal images, which suffered from more varying low contrast than axial and coronal images, as shown in Figure 2.

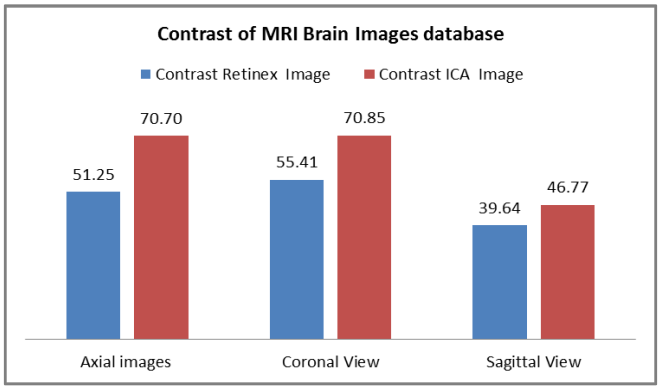

Fig. 8. Contrast Observation of MRI Brain Images

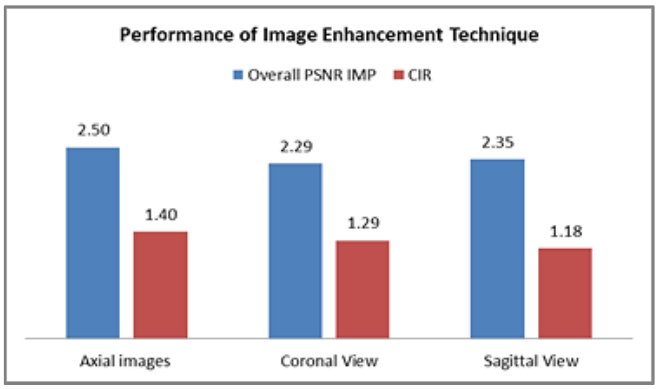

Fig. 9. Performance of Image Enhancement Technique

V. CONCLUSION

This research paper presents an image enhancement technique for MRI brain images and provides a comparative contrast analysis of MRI image views, including axial, coronal, and sagittal views. The goal is to identify MRI image views with the lowest contrast to further enhance them for better diagnosis of brain lesions. The evaluation parameters used are peak signal-to-noise ratio (PSNR) and contrast. The axial and coronal image views had a contrast enhancement ratio (CIR) of 1.4 to 2.5 dB and 1.29 to 2.29 dB, respectively, while the sagittal image had a CIR of 1.18 to 2.35 dB.

In future research, the goal will be to achieve equal or better CIR across all MRI image views to facilitate the accurate detection of brain tumors. This will involve further refining image enhancement techniques to ensure consistent and reliable contrast enhancement. Advanced algorithms and machine learning models could be explored to dynamically adjust and optimise contrast enhancement for different MRI views.

During this study, certain limitations were encountered. A major limitation was the variability in image quality between different scanners and MRI settings, which impacted the consistency of results. To address this issue, future work could integrate a larger and more diverse dataset including images from multiple MRI devices and settings, ensuring that enhancement techniques are robust and generalisable. Another limitation was the computational complexity and time required for the image enhancement process. To alleviate

Authorized licensed use limited to: Sharda University. Downloaded on October 14,2025 at 05:26:42 UTC from IEEE Xplore. Restrictions apply.

this problem, optimised algorithms and parallel processing techniques can be used to reduce processing time without compromising the quality of the enhancements. Additionally, although the current study focused on contrast enhancement, other important image quality parameters, such as noise reduction, edge preservation, and texture enhancement, should also be considered in future research to provide more comprehensive enhancement of MRI images.

In conclusion, this study lays a solid foundation for improving MRI brain images, particularly in contrast enhancement. Future research can advance this field by addressing limitations and exploring new techniques, contributing to more accurate and efficient diagnosis of brain injuries.

REFERENCES

[1] T. A. Soomro, L. Zheng, A. J. Afifi, A. Ali, S. Soomro, and M. Yin, "Image segmentation for MR brain tumor detection using machine learning: A review," IEEE Rev. Biomed. Eng., vol. 16, pp. 70–90, 2023.

[2] R. S. Jeena and S. Kumar, "A comparative analysis of MRI and CT brain images for stroke diagnosis," in Emerging Research Areas and 2013 International Conference on Microelectronics, Communications and Renewable Energy (AICERA/ICMiCR), 2013, pp. 1–5.

[3] M. Ramamoorthy, S. Qamar, R. Manikandan, N. Z. Jhanjhi, M. Masud, and M. A. AlZain, "Earlier detection of brain tumor by pre-processing based on histogram equalization with neural network," Healthcare, vol. 10, p. 1218, 2022.

[4] F. J. Diaz-Pernas, M. Martinez-Zarzuela, M. Anton Rodriguez, and D. Gonzalez Ortega, "A deep learning approach for brain tumor classification and segmentation using a multiscale convolutional neural network," Healthcare, vol. 9, p. 153, 2021.

[5] K. N. S. Xavierarockiaraj and J. R. Maruni Devi, "Brain tumor detection using modified histogram thresholding-quadrant approach," Journal of Computer Applications (JCA), vol. 5, pp. 21–25, 2012.

[6] D. R. Nayak et al., "Brain tumour classification using noble deep learning approach with parametric optimisation through metaheuristics approaches," Computers, vol. 11, no. 1, p. 10, 2022.

[7] A. R. Kavitha, C. Chellamuthu, and K. Rupa, "An efficient approach for brain tumour detection based on modified region growing and neural network in MRI images," in Computing, Electronics and Electrical Technologies (ICCEET), 2012 International Conference on, 2012, pp. 1087–1095.

[8] E. M. Senan, M. E. Jadhav, T. H. Rassem, A. S. Aljaloud, B. A. Mohammed, and Z. G. Al-Mekhlafi, "Early diagnosis of brain tumour MRI images using hybrid techniques between deep and machine learning," Hindawi Comput. Math. Methods Med., vol. 2022, pp. 1–17, 2022.

[9] A. Mustaqeem, A. Javed, and T. Fatima, "An efficient brain tumor detection algorithm using watershed and thresholding based segmentation," International Journal of Image, Graphics and Signal Processing (IJIGSP), vol. 4, pp. 34–39, 2012.

[10] S. M. Alqhtani, T. A. Soomro, F. B. Ubaid, A. Ali, M. Irfan, and A. A. Asiri, "Contrast normalisation strategies in brain tumor imaging: from preprocessing to classification," Computational Modeling in Engineering & Sciences, vol. 140, no. 2, pp. 1539–1562, 2024, doi: 10.32604/cmes.2024.051475.

[11] D. Gurari, D. Theriault, M. Sameki, B. Isenberg, T. A. Pham, and A. Purwada, "How to collect segmentations for biomedical images? A benchmark evaluating the performance of experts, crowdsourced non-experts, and algorithms," in Applications of Computer Vision (WACV), 2015 IEEE Winter Conference on, 2015, pp. 1169–1176.

[12] J. G. Park and C. Lee, "Skull stripping based on region growing for magnetic resonance brain images," Neuroimage, vol. 47, no. 4, pp. 1394–1407, 2009.

[13] A. A. Asiri, T. A. Soomro, A. A. Shah, G. Pogrebna, M. Irfan, and S. Alqahtani, "Optimised brain tumor detection: A dual-module approach for MRI image enhancement and tumor classification," IEEE Access, vol. 12, pp. 42868–42887, 2024, doi: 10.1109/ACCESS.2024.3379136.

[14] M. M. Memon, M. M. Jawaid, S. Narejo, and M. Rathi, "Computer-assisted framework for automatic detection of structural hand deformities," Journal of Hunan University (Natural Sciences), vol. 48, no. 10, pp. 595–604, 2021.

[15] T. A. Soomro and J. Gao, "Neural network based denoised methods for retinal fundus images and MRI brain images," in 2016 International Joint Conference on Neural Networks (IJCNN), 2016, pp. 1151–1157, doi: 10.1109/IJCNN.2016.7727327.

[16] M. Z. Yusoff and N. Kamel, "A subspace approach with pre-whitening for measurements of latencies in visual evoked potentials," in Intelligent and Advanced Systems (ICIAS), 2010 International Conference on, 2010, pp. 1–6.

[17] E. H. Land and J. J. McCann, "Lightness and Retinex theory," J. Opt. Soc. Am., vol. 61, pp. 1–11, 1971.

[18] Y. Xian-Chuan, R. Jia-Mian, Z. Nan, and D. Guo-Sheng, "An optimal ICA algorithm applied to fMRI data," in Machine Learning and Cybernetics, 2007 International Conference on, 2007, pp. 3565–3570.

[19] H. A. Nugroho, "Non-invasive image enhancement of colour retinal fundus image for computerised diabetic retinopathy monitoring and grading system," M.S. thesis, Universiti Teknologi PETRONAS, 2012.

[20] T. A. Soomro, "Non-invasive image denoising and contrast enhancement techniques for retinal fundus images," M.S. thesis, Universiti Teknologi Petronas, 2014.

[21] J. Frankle and J. McCann, "Method and apparatus for lightness imaging," U.S. Patent 4,420,081, 1983.

[22] R. Sobol, "Improving the Retinex algorithm for rendering wide dynamic range photographs," J. Electron. Imaging, vol. 13, pp. 65–74, 2004.

[23] R. S. Manzoor, V. Jeoti, N. Kamel, and M. Asif, "A novel noise power and SNR estimation in WiMAX systems," in Information Technology, 2008. ITSim 2008. International Symposium on, 2008, pp. 1–6.

[24] J. S. Lihong, "Digital image enhancement and noise filtering by use of local statistics," IEEE Trans. Pattern Anal. Mach. Intell., vol. PAMI-2, pp. 165–168, 1980.

[25] The Radiology Assistant, "Enhancement patterns in CNS diseases," 2015. [Online]. Available: https://radiologyassistant.nl/en/pediatric-radiology/enhancement-patterns-in-cns-diseases.

[26] Z. Dong and B. Yong-qiang, "A novel fast haze removal technique for single image using image pyramid," in Control Conference (CCC), 2015 34th Chinese, 2015, pp. 3816–3821.

Authorized licensed use limited to: Sharda University. Downloaded on October 14,2025 at 05:26:42 UTC from IEEE Xplore. Restrictions apply.