4 교시

감독관확인

2023년도
기초의학종합평가 사진자료

응시번호		성명	

응시자는 시험 종료 후 문제지를 가지고 갈 수 있습니다.
문항 내용의 무단 복제, 전재 및 재배포를 금지합니다.
본 문제의 저작권은 한국의과대학·의학전문대학원협회(KAMC)에 있으며 상업적 목적으로 사용하는 경우 「저작권법」 위반으로 민·형사상 처분을 받을 수 있습니다.

KAMC 의학교육평가사업단
KAMC Medical Education Assessment Corporation

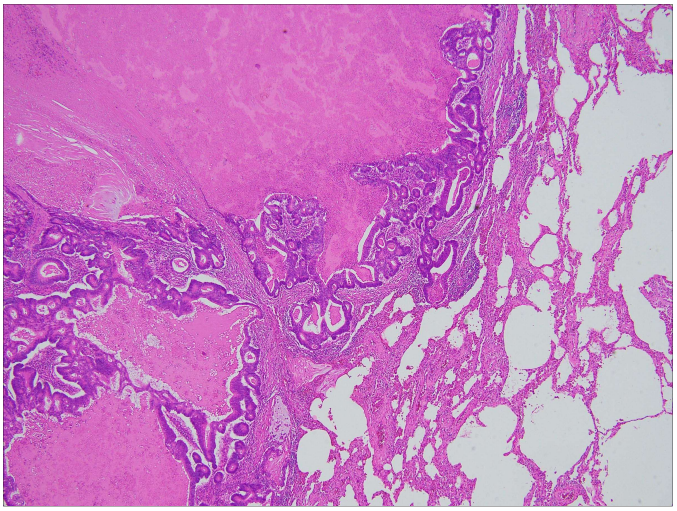

사진 1-1

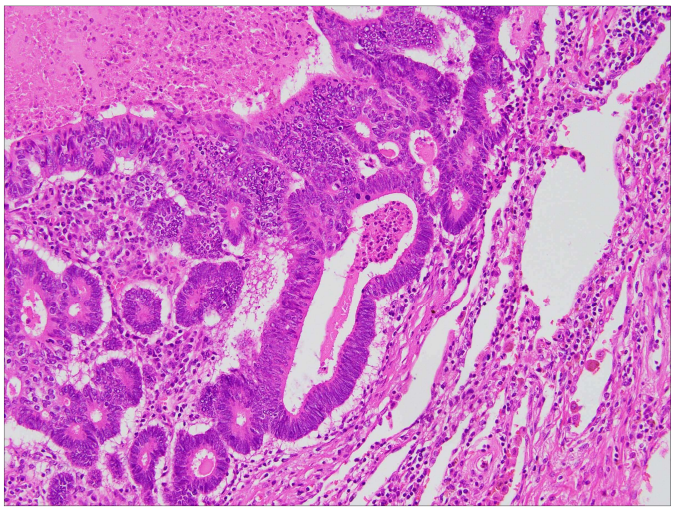

사진 1-2

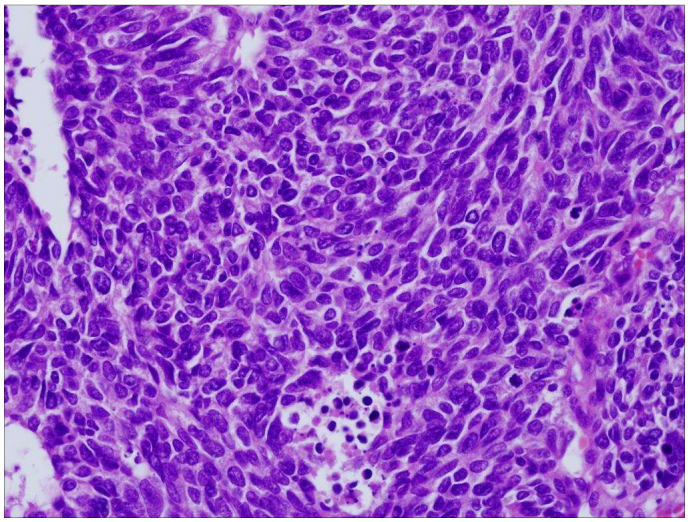

사진 2

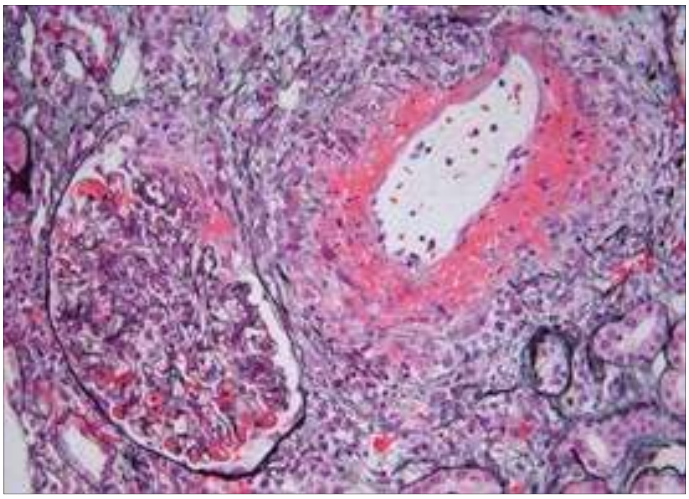

사진 3

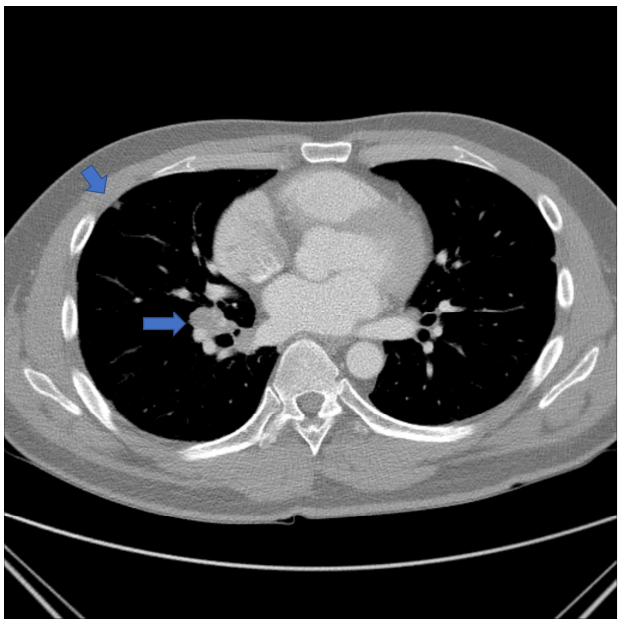

사진 4-1

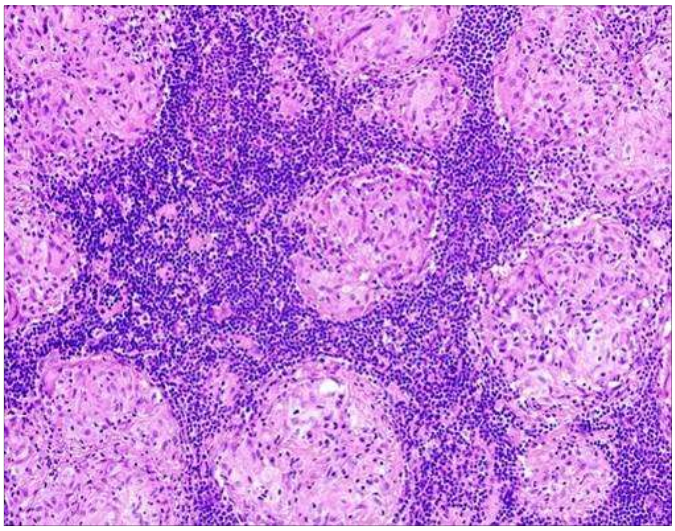

사진 4-2

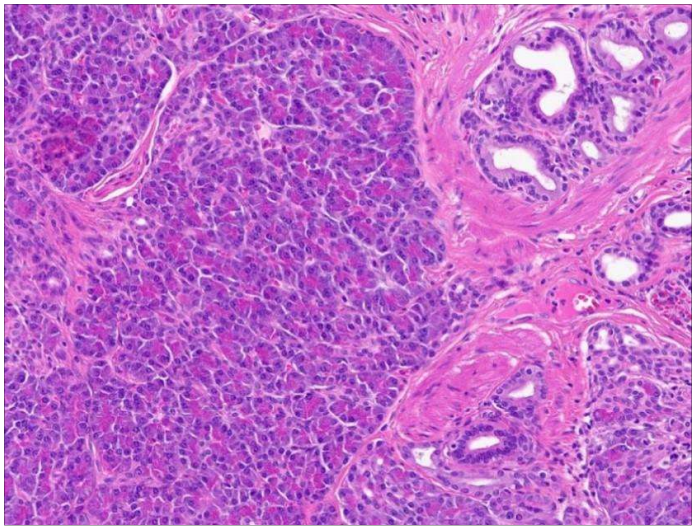

사진 5

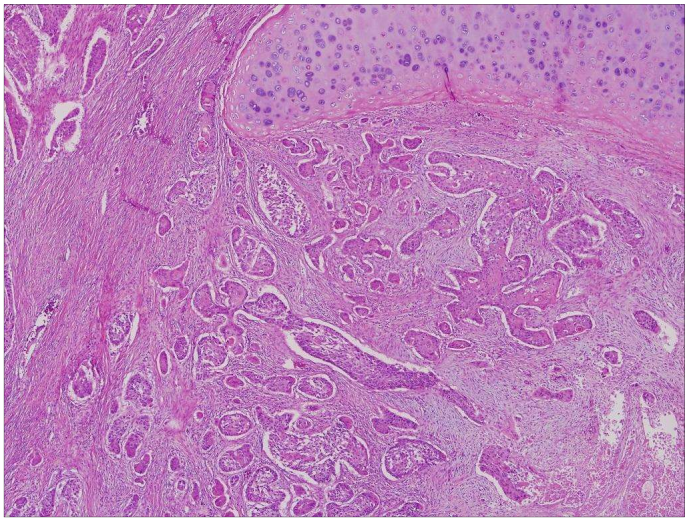

사진 6-1

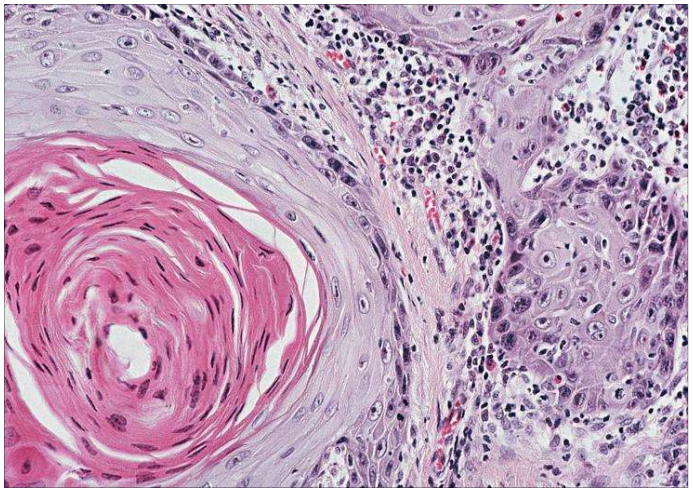

사진 6-2

사진 7

사진 8 - 1

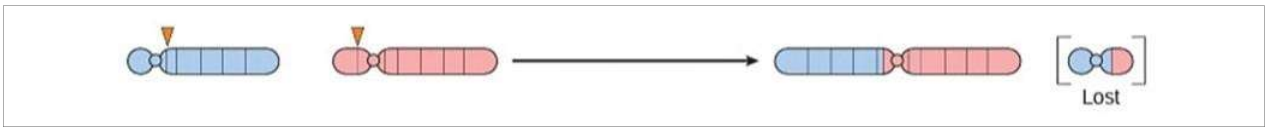

사진 8 - 2

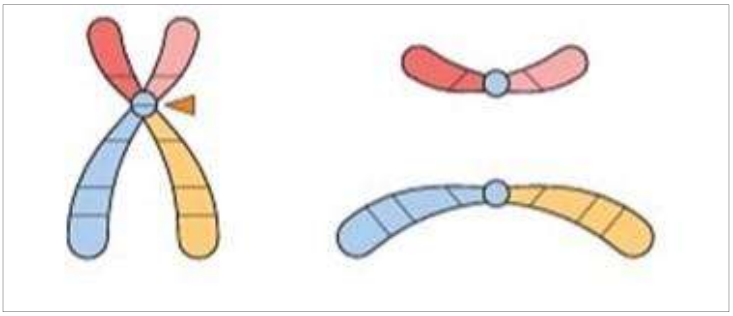

사진 8 - 3

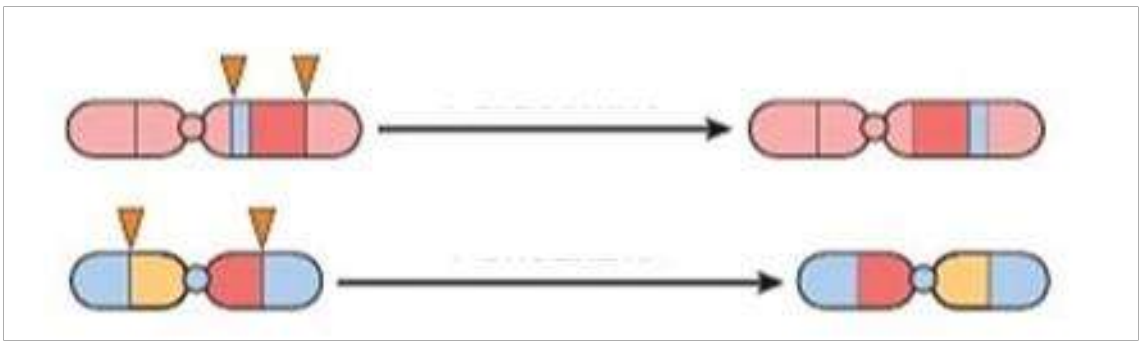

사진 8 - 4

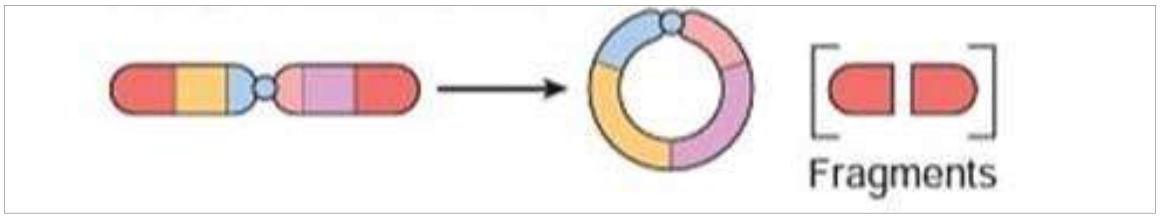

사진 8 - 5

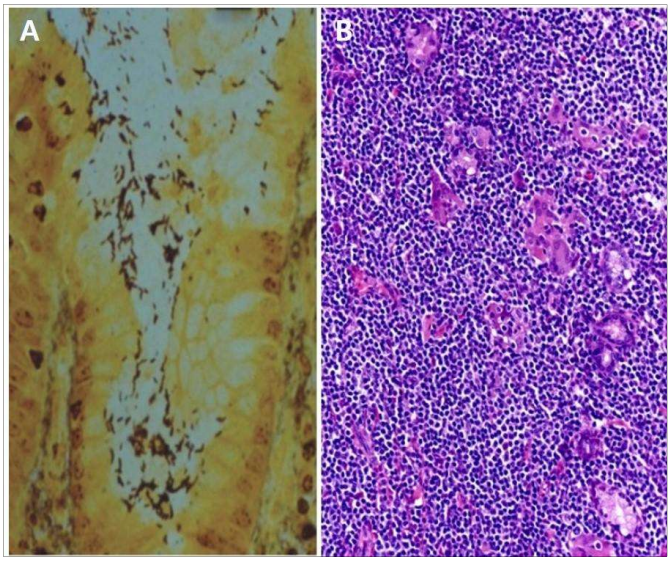

사진 9

사진 10

사진 11-1

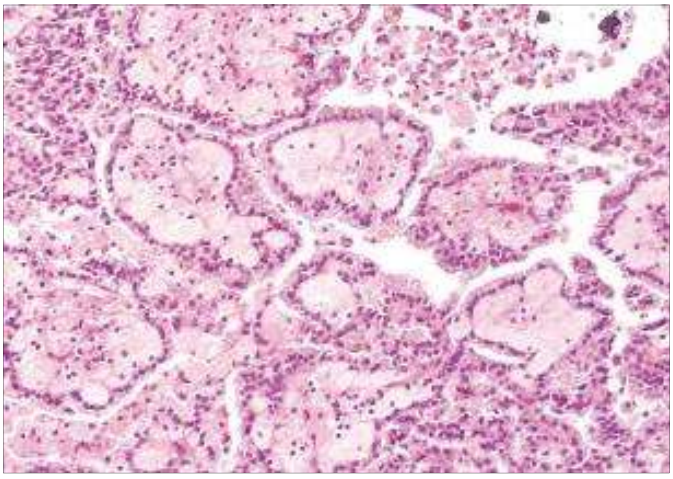

사진 11-2

사진 12-1

사진 12-2

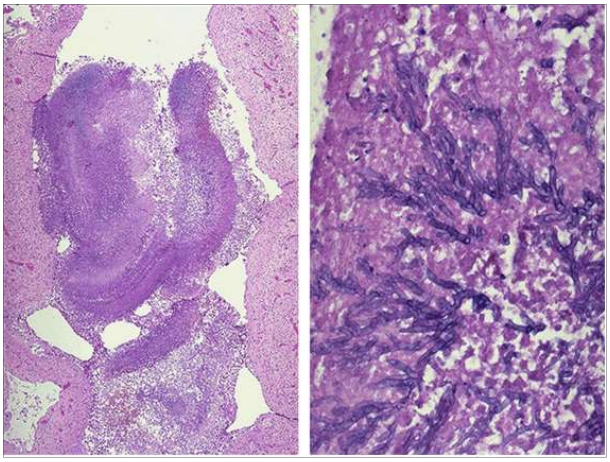

사진 13

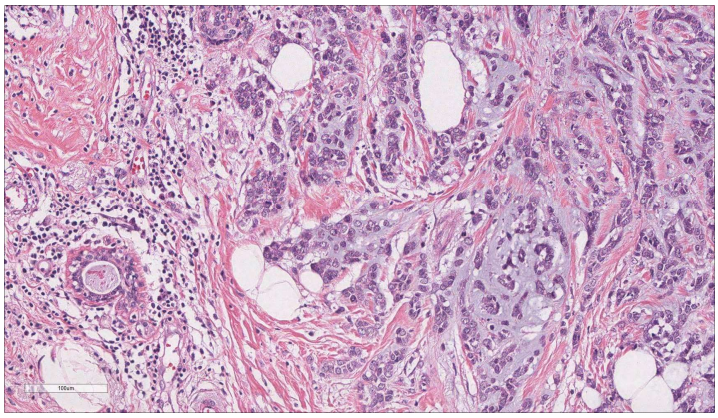

사진 14-1

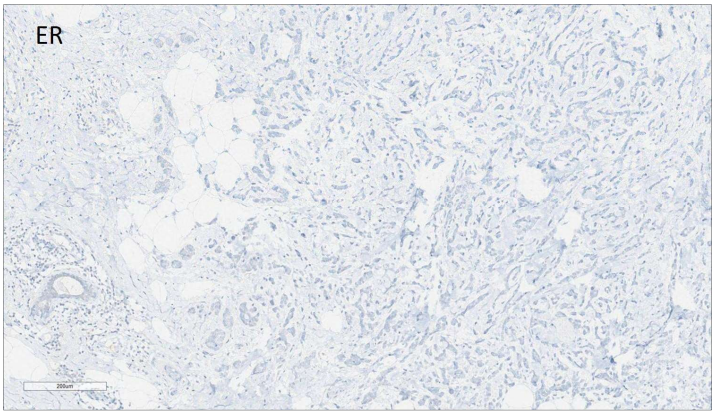

사진 14-2

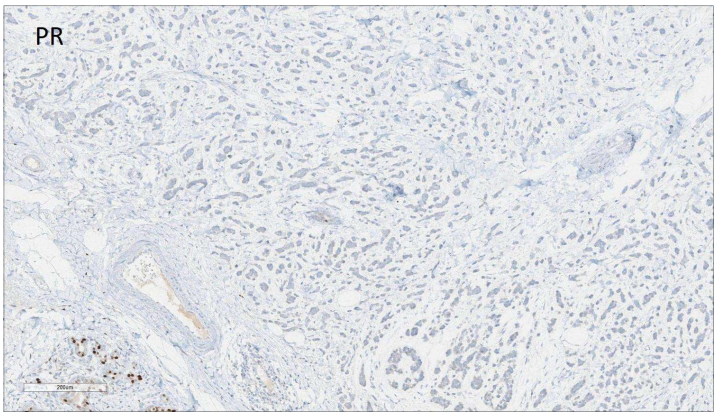

사진 14-3

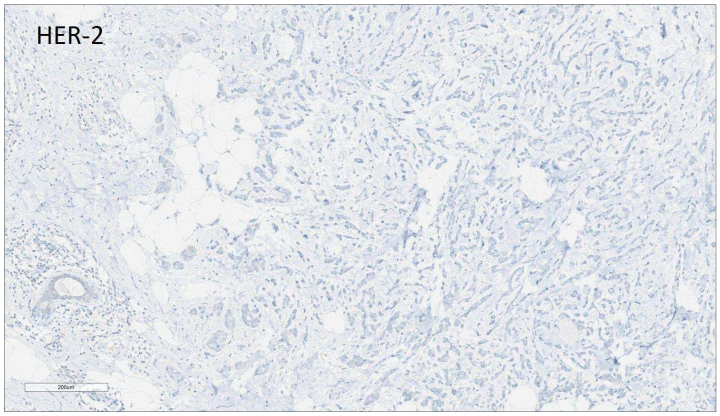

사진 14-4

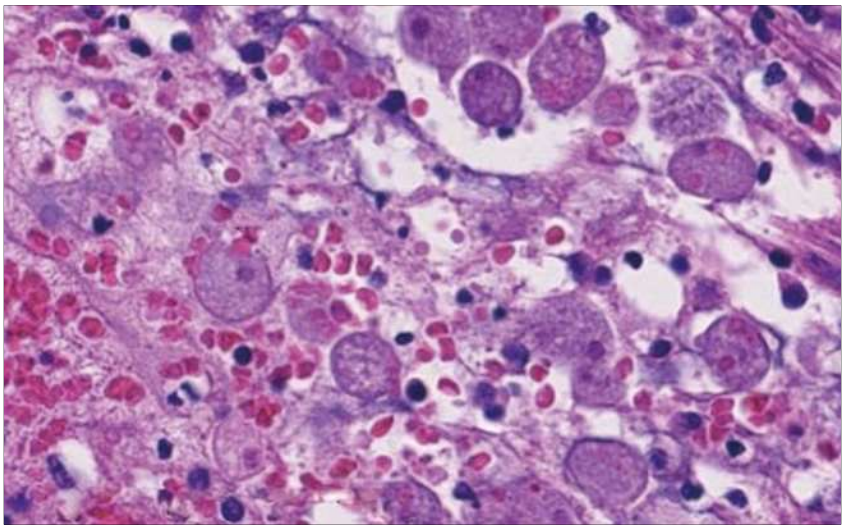

사진 15-1

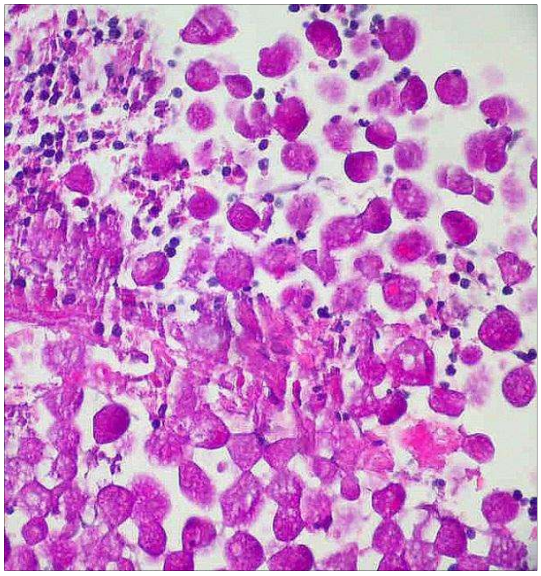

사진 15-2

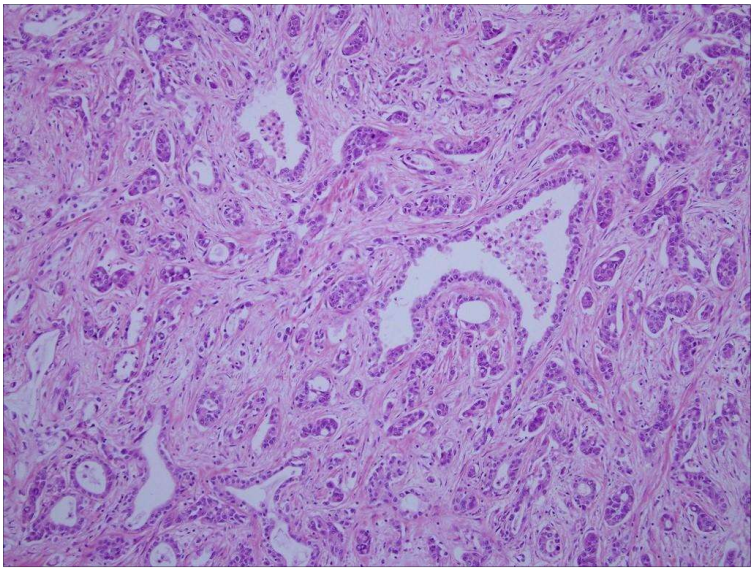

사진 16

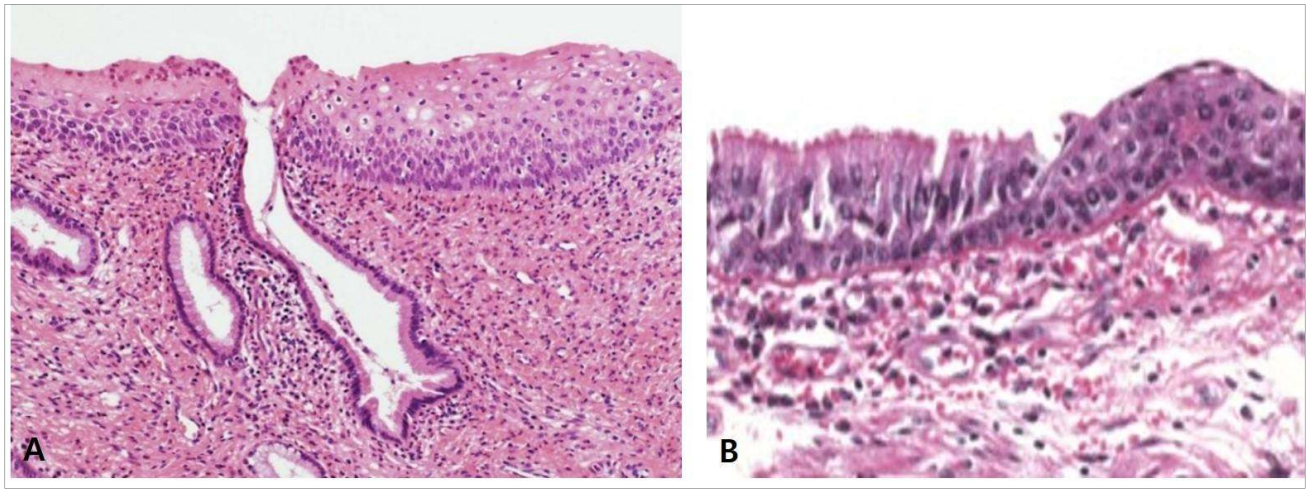

사진 17

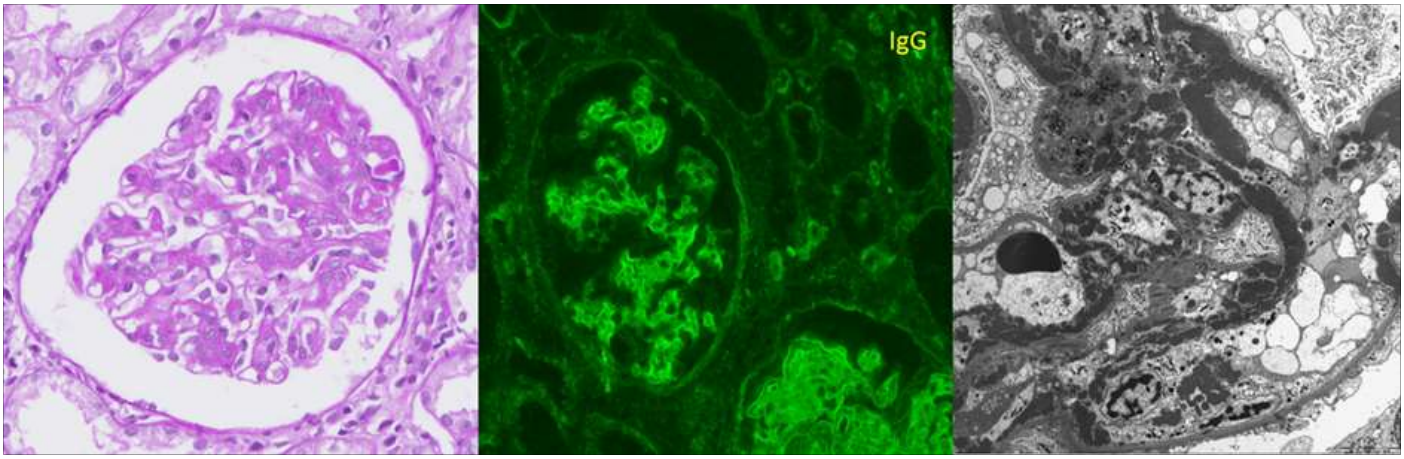

사진 18

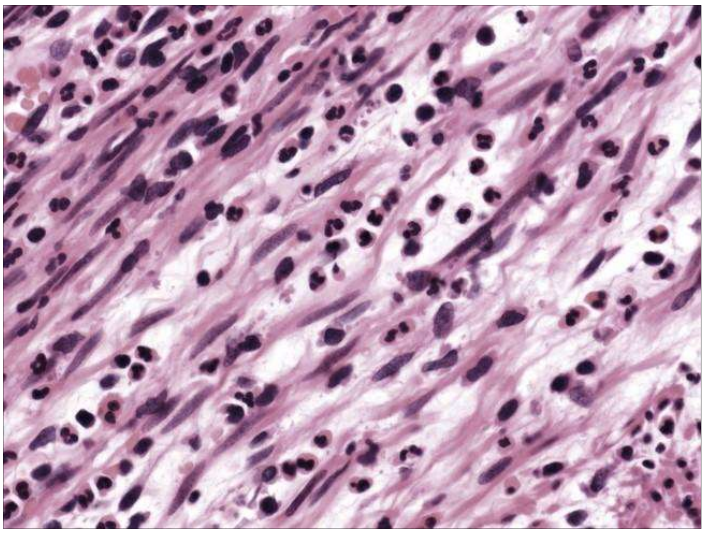

사진 19

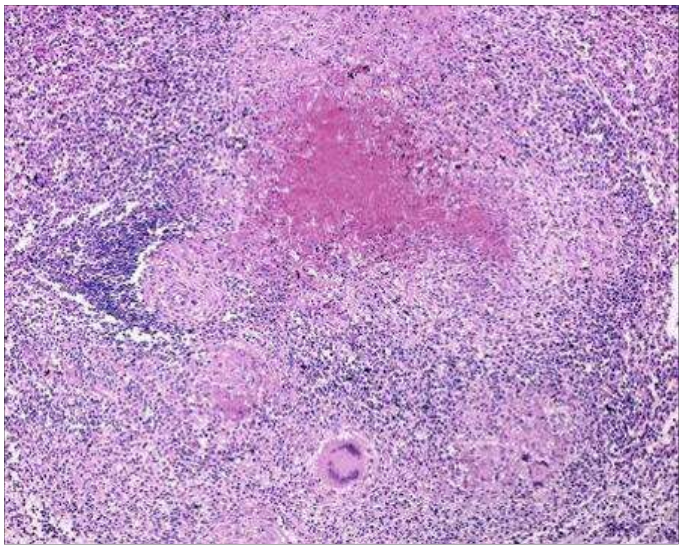

사진 20

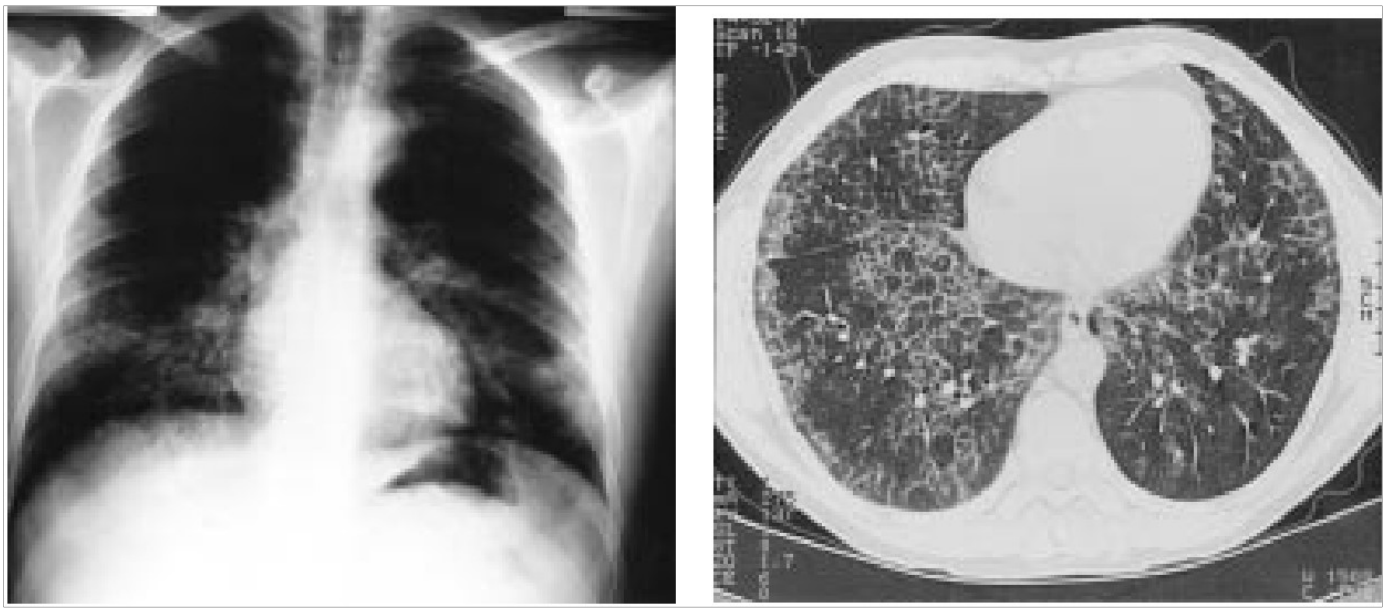

사진 21-1

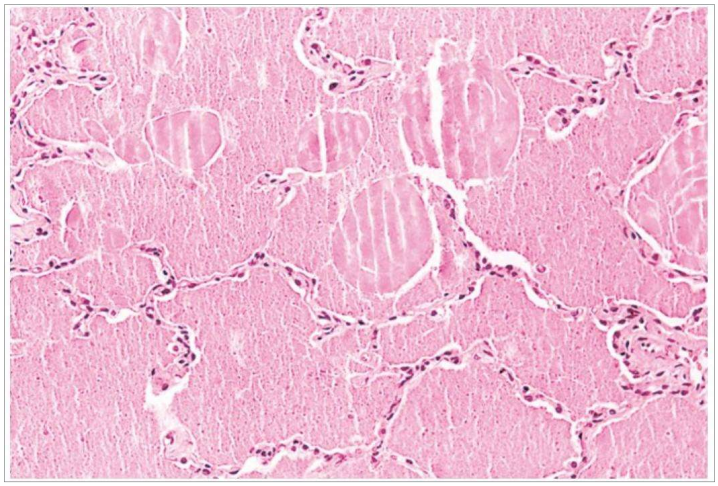

사진 21-2

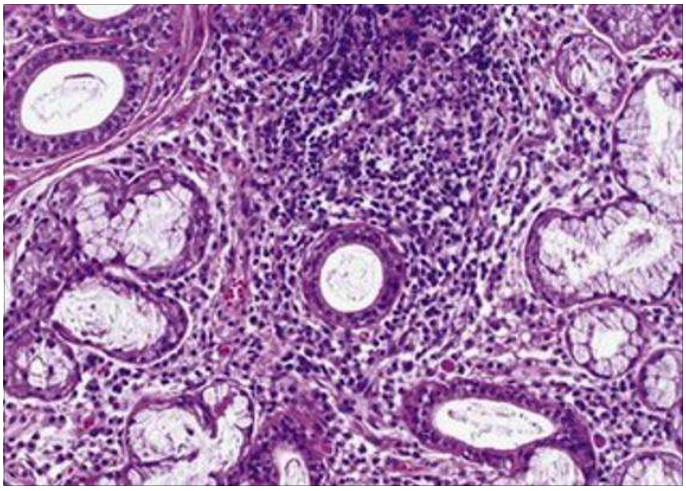

사진 22

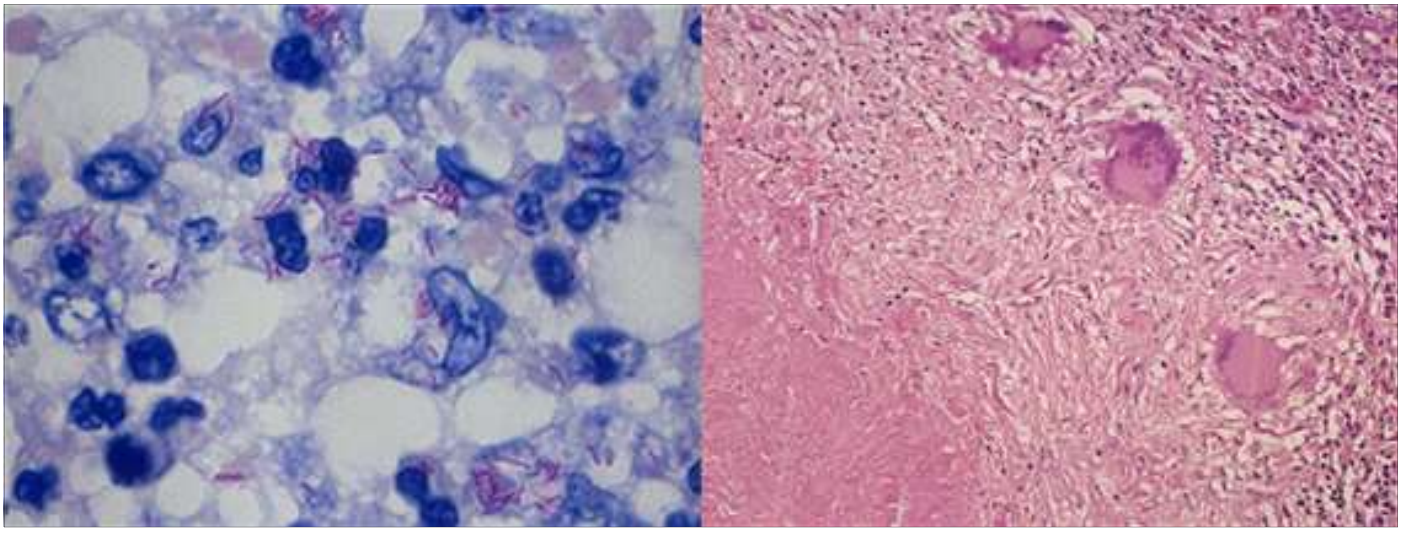

사진 23

사진 24

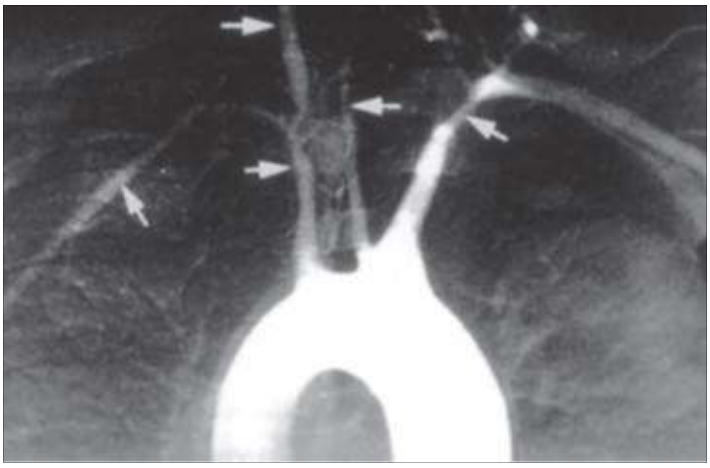

사진 25-1

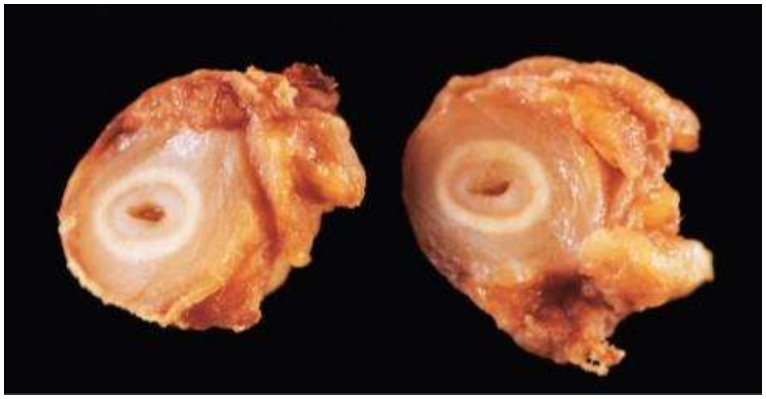

사진 25-2

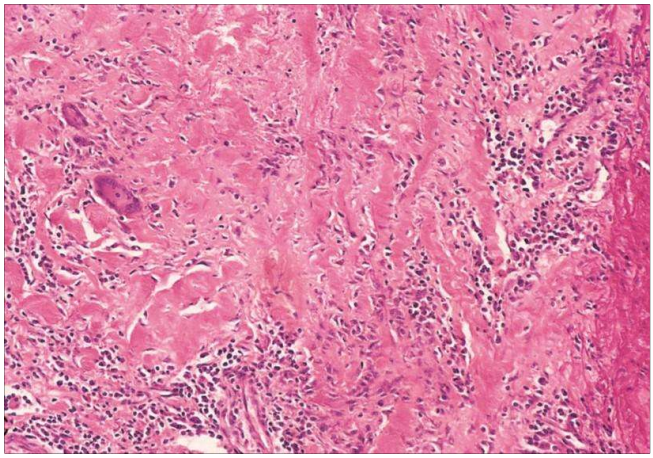

사진 25-3

- TX: Primary tumor cannot be assessed
- T0: No evidence of primary tumor
- Tis: Carcinoma in situ: intraepithelial tumor without invasion of the (A); high grade dysplasia
- T1: Tumor invades the (A), (B) or submucosa
  - T1a: Tumor invades the (A), or (B)
  - T1b: Tumor invades the submucosa

사진 26

사진 27-1

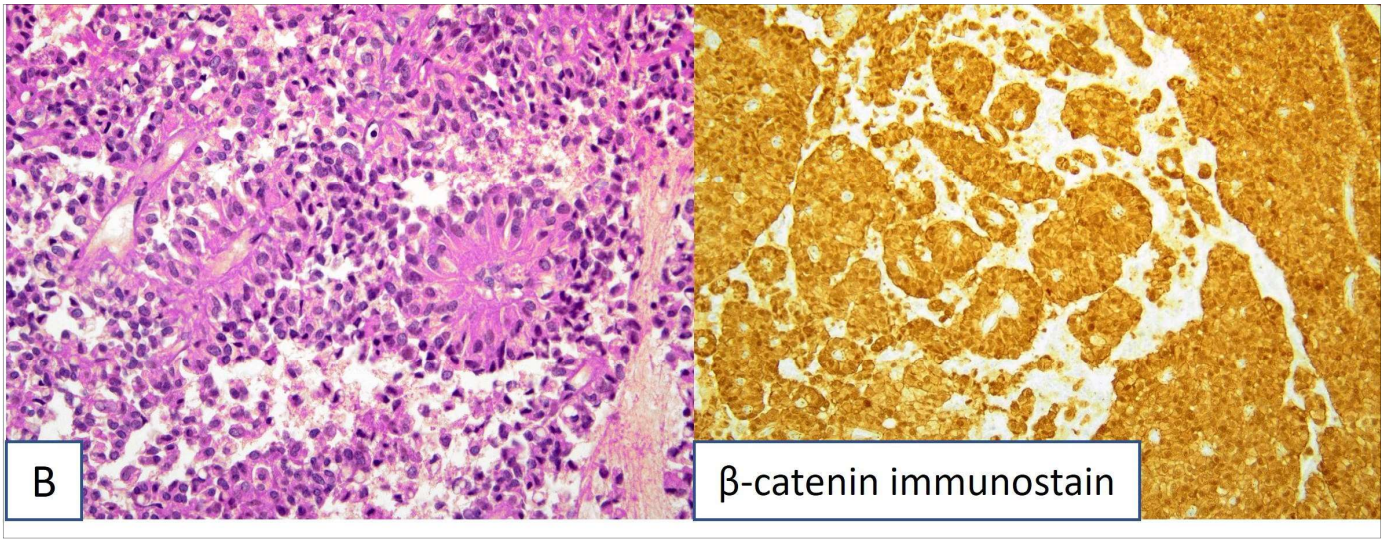

사진 27-2

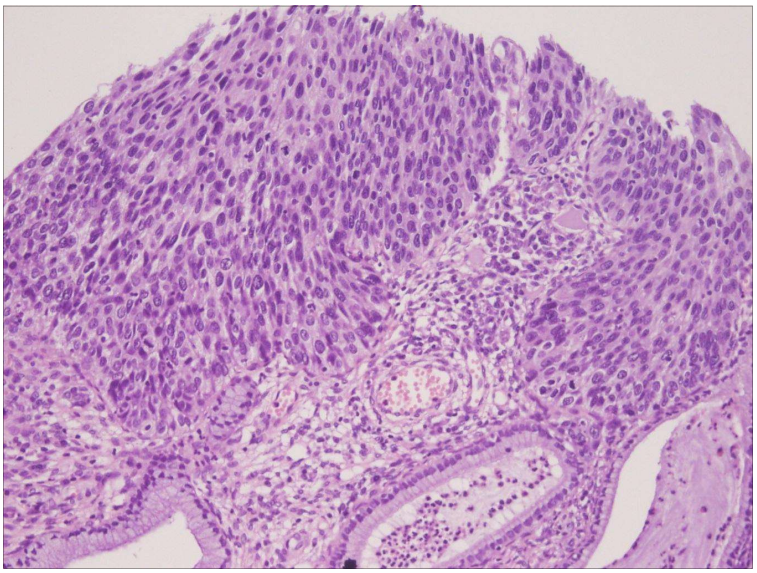

사진 28

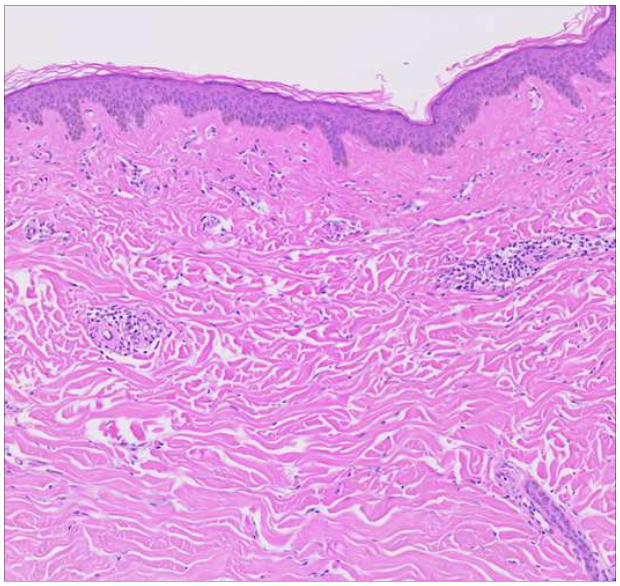

사진 29

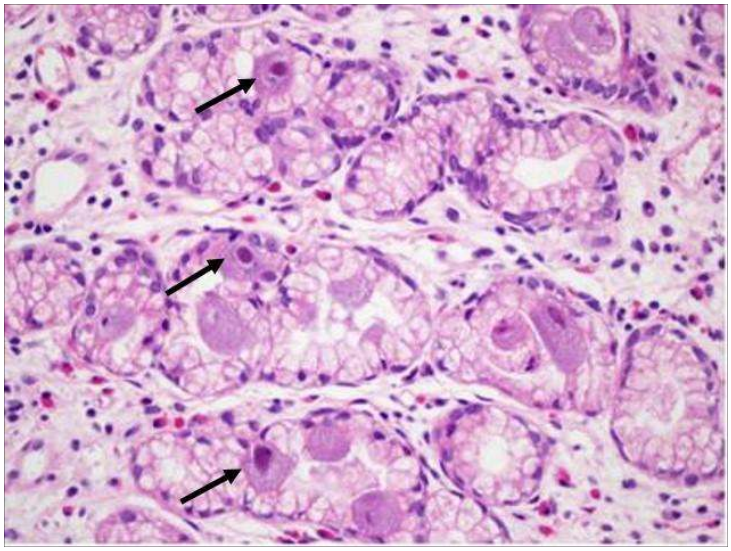

사진 30

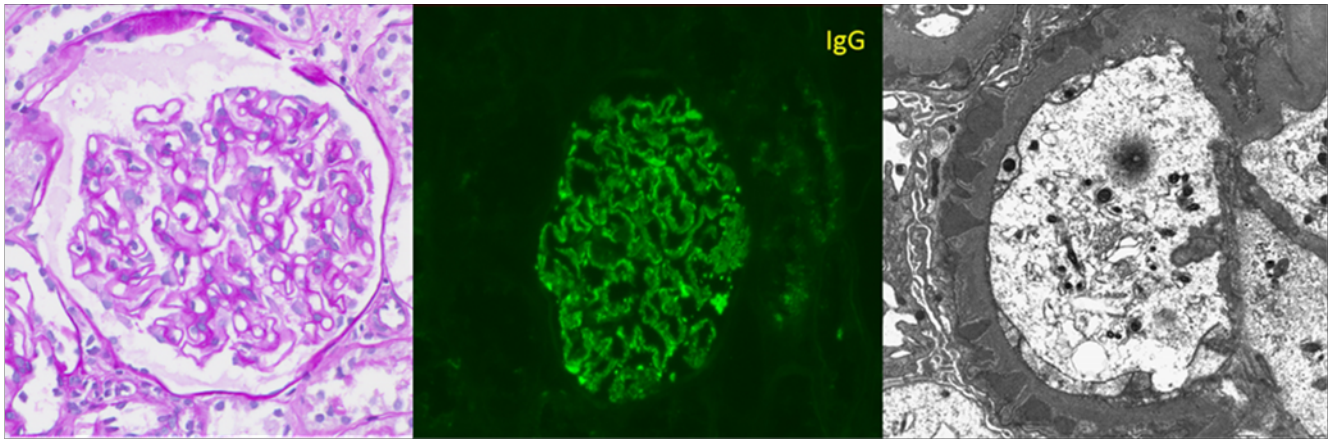

사진 31

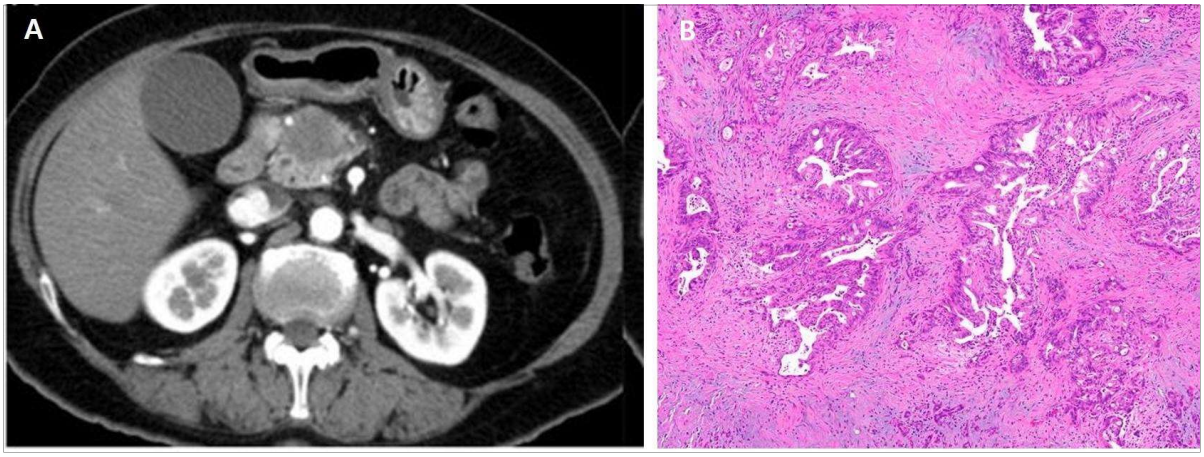

사진 32

사진 33

사진 34

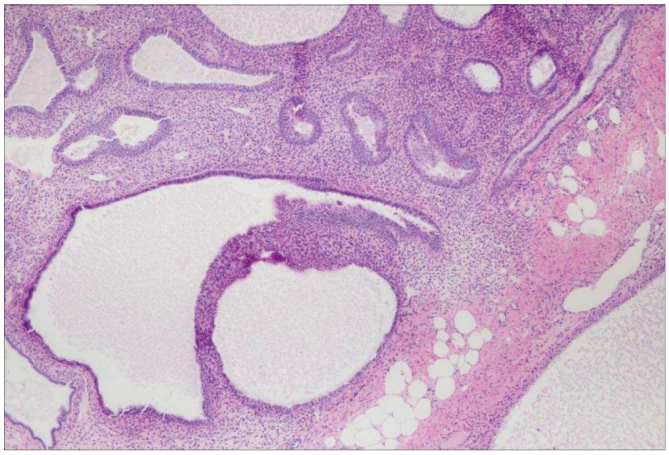

사진 35-1

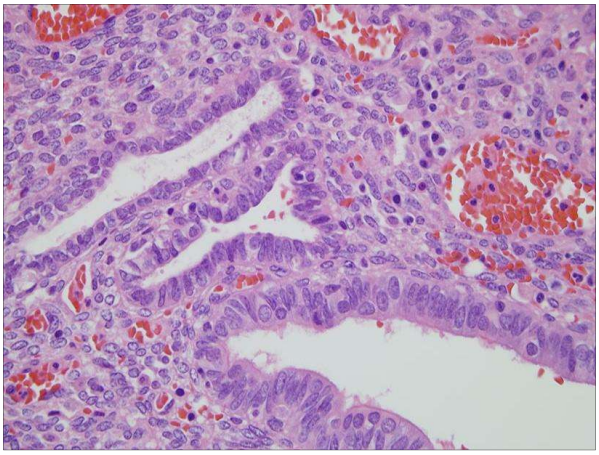

사진 35-2

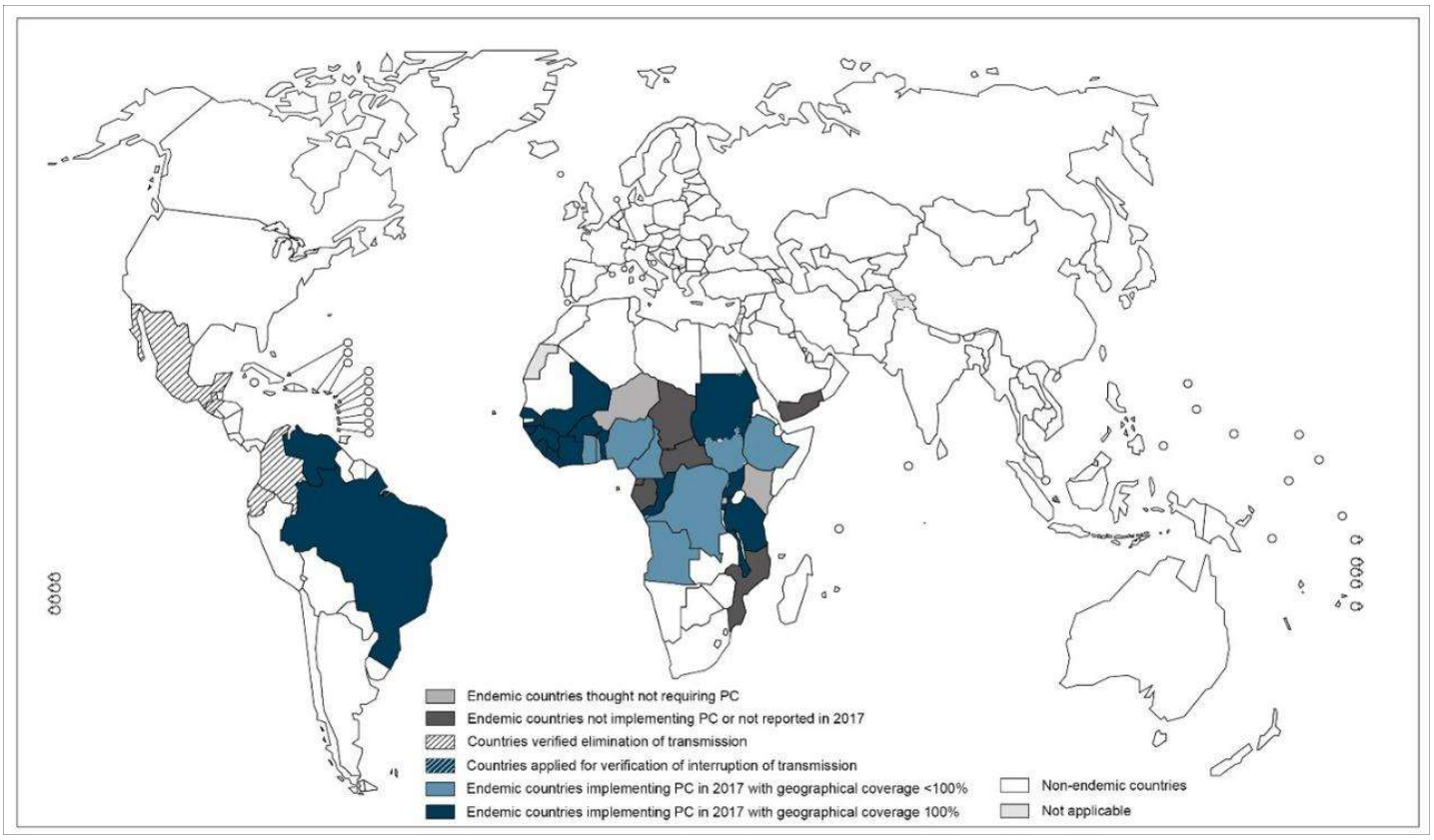

사진 36

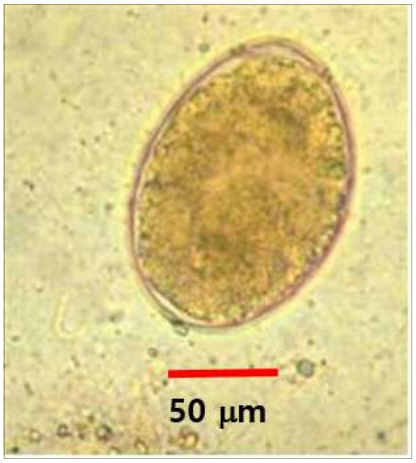

사진 37

사진 38-1

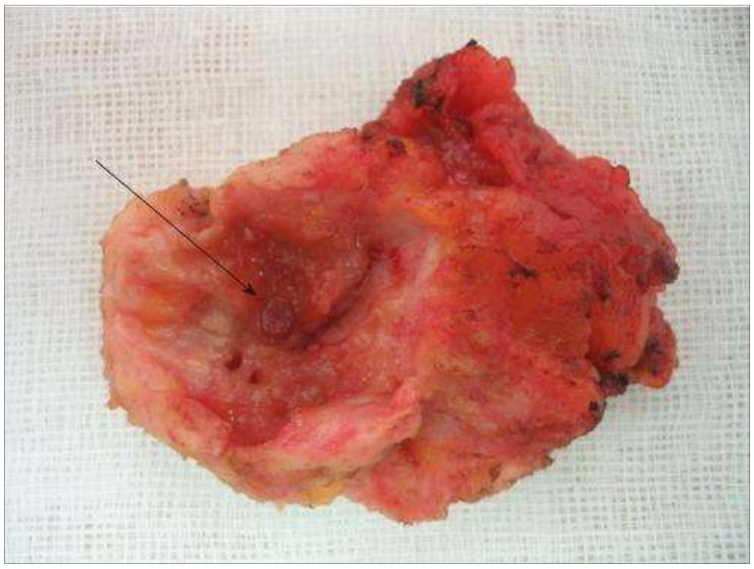

사진 38-2

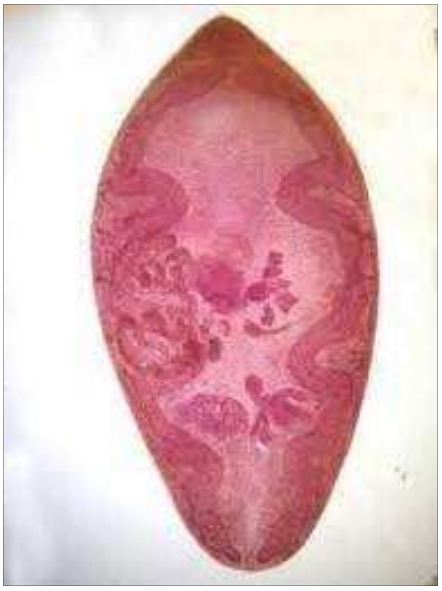

사진 38-3

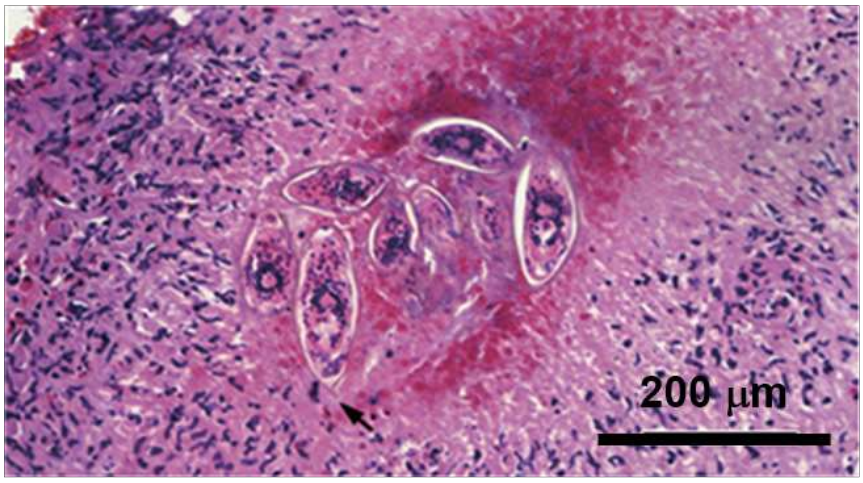

사진 39

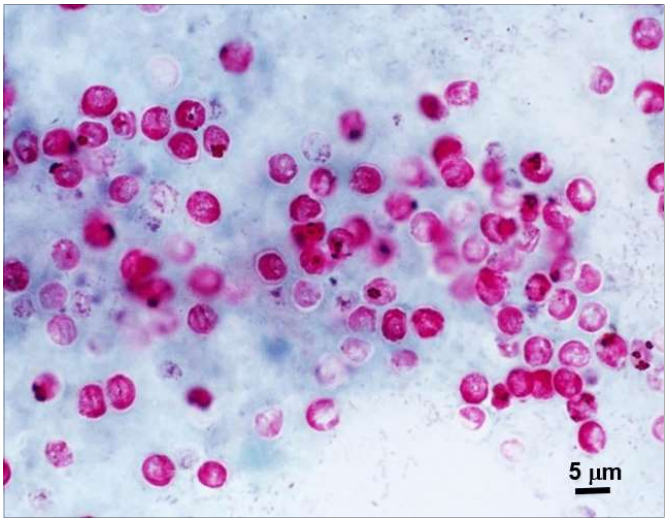

사진 40

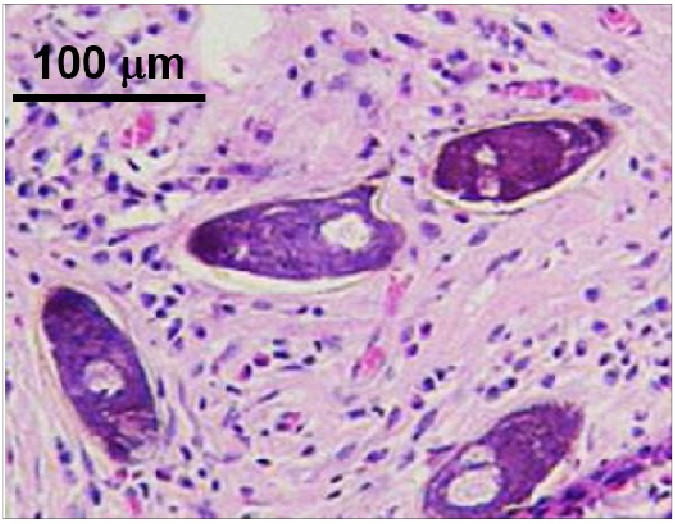

사진 41

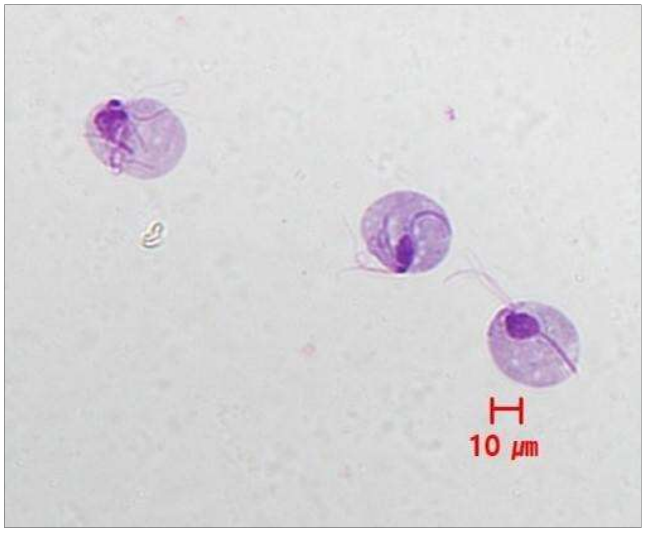

사진 42

사진 43-1

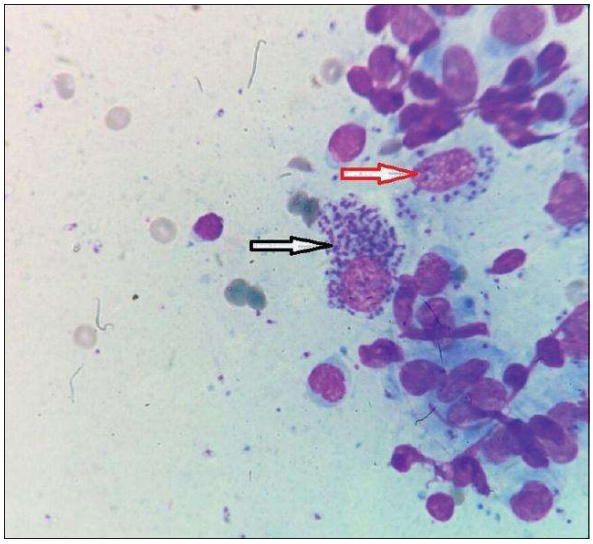

사진 43-2

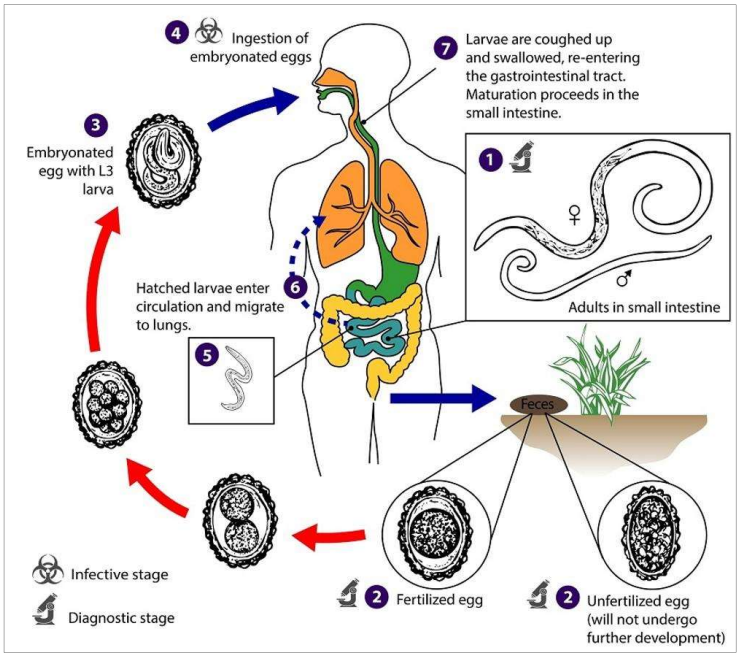

사진 44

사진 45

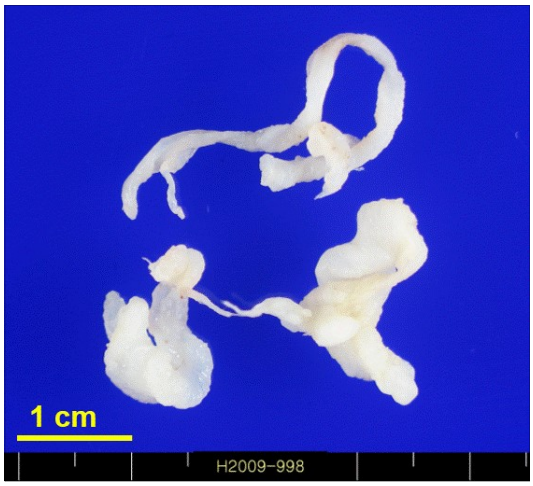

사진 46-1

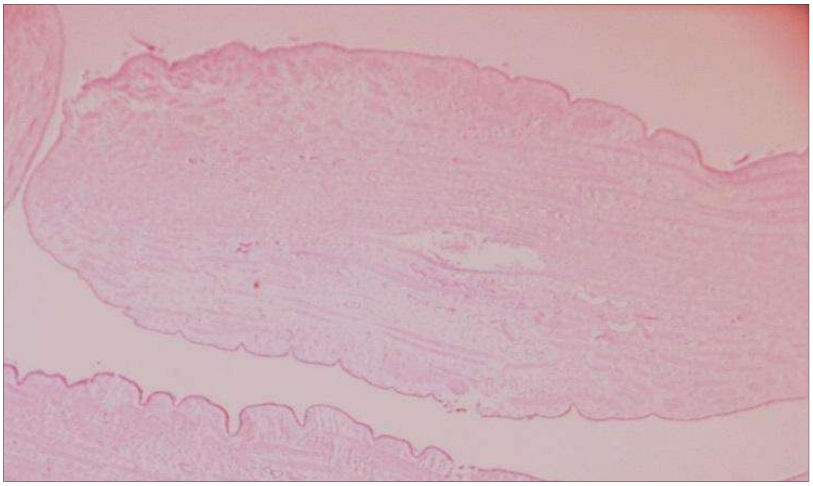

사진 46-2

사진 47



사진 48