Pattern 3

Hyperammonemic Encephalopathy and Acute Hepatic Encephalopathy

- high signal intensity symmetrically and bilaterally in the insular and cingulate gyri
- relative sparing of the occipital lobes and perirolandic region

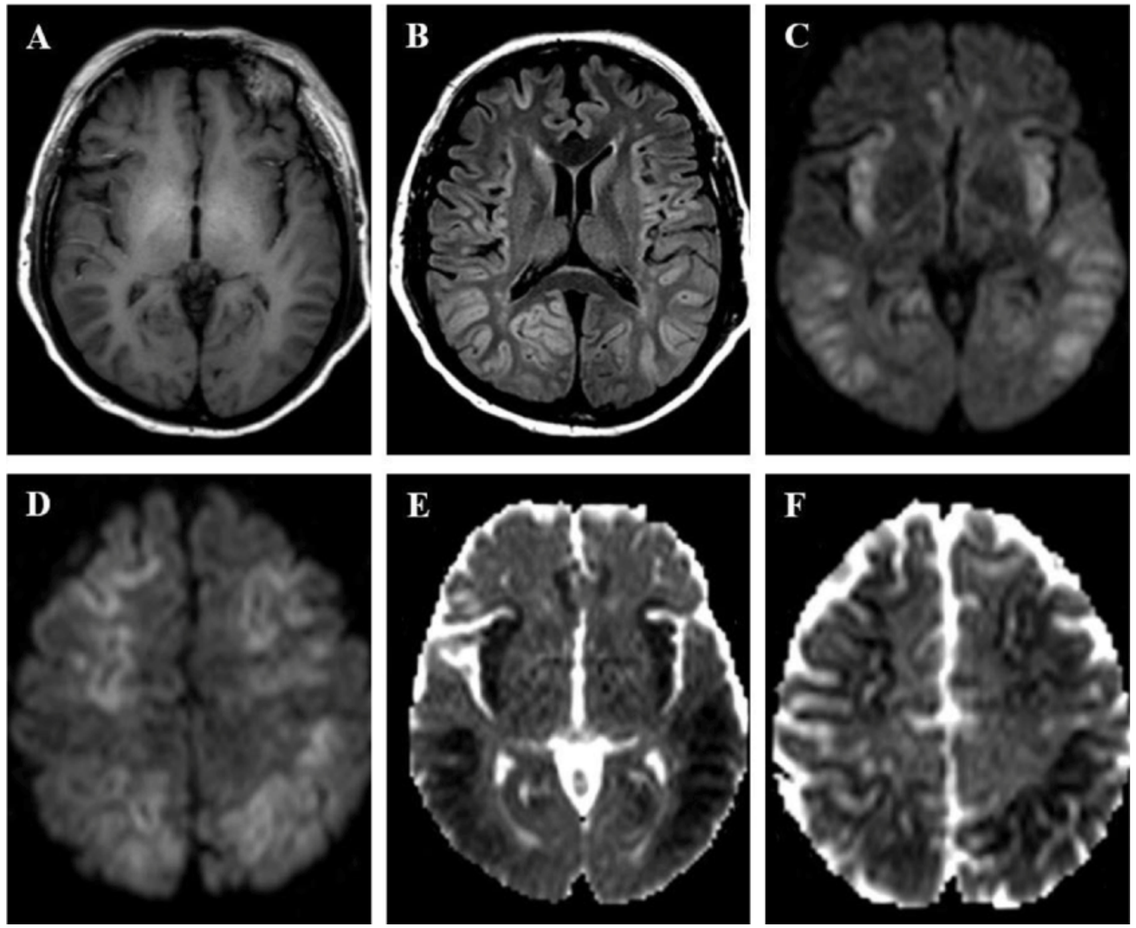

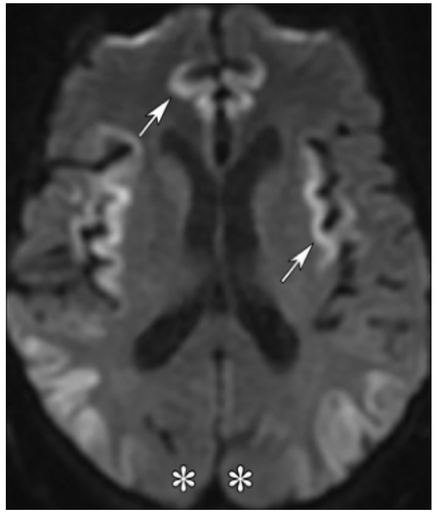

Pattern 3

Hypoxic ischemic encephalopathy
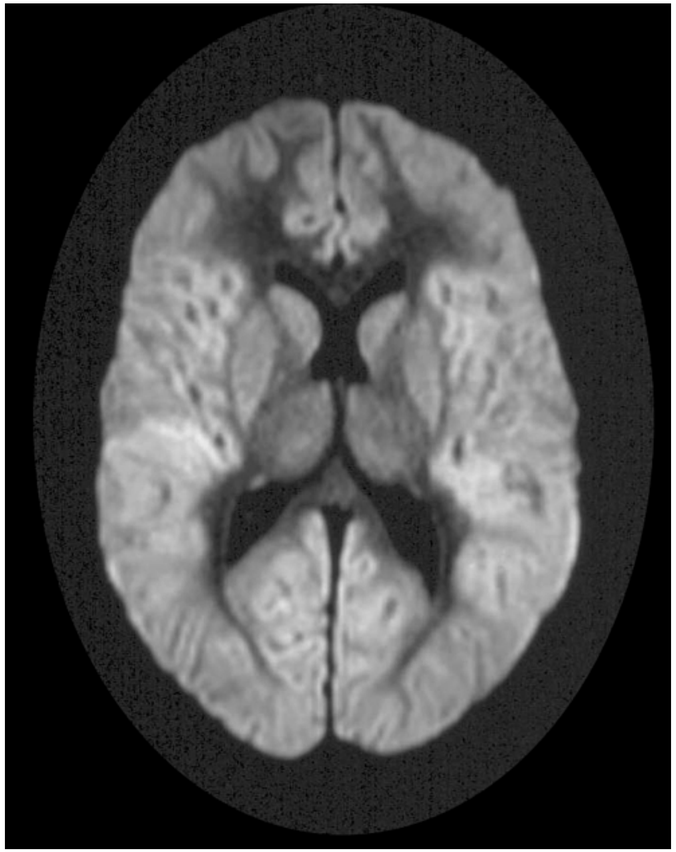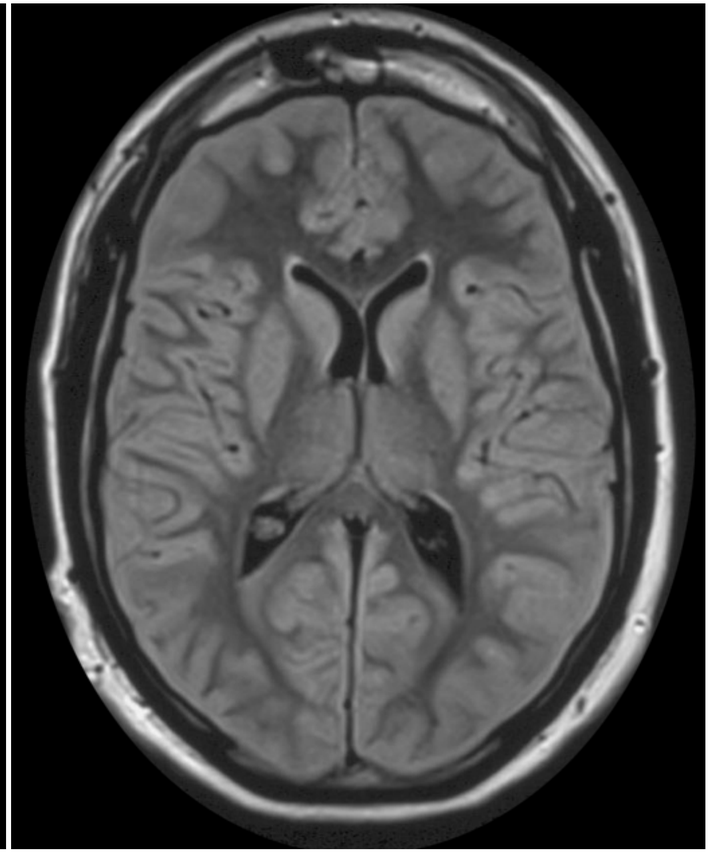
- can be subtle in the acute phase.
- increased DWI signal in cerebellar hemispheres, basal ganglia, or cerebral cortex
- favors perirolandic and occipital cortices