Pattern 1a: T2-weighted and FLAIR Hyperintensity

Wernicke Encephalopathy

- Mammillary bodies
- Medial thalami
- Periaqueductal gray
- Putamina
- Contrast enhancement possible

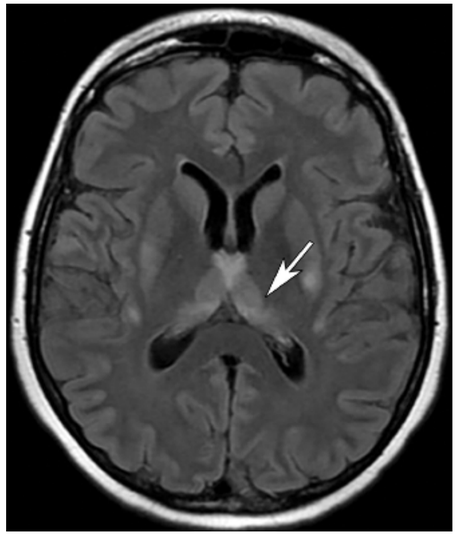

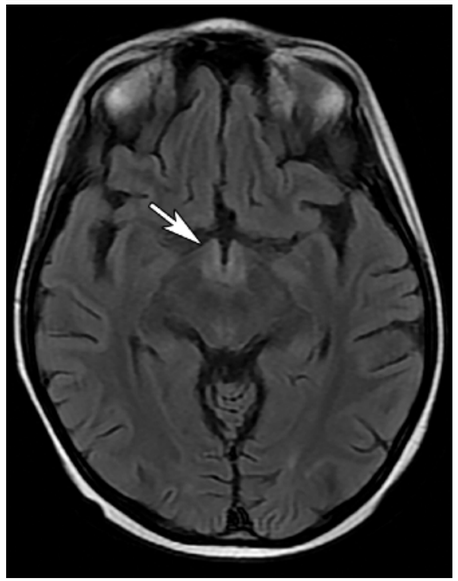

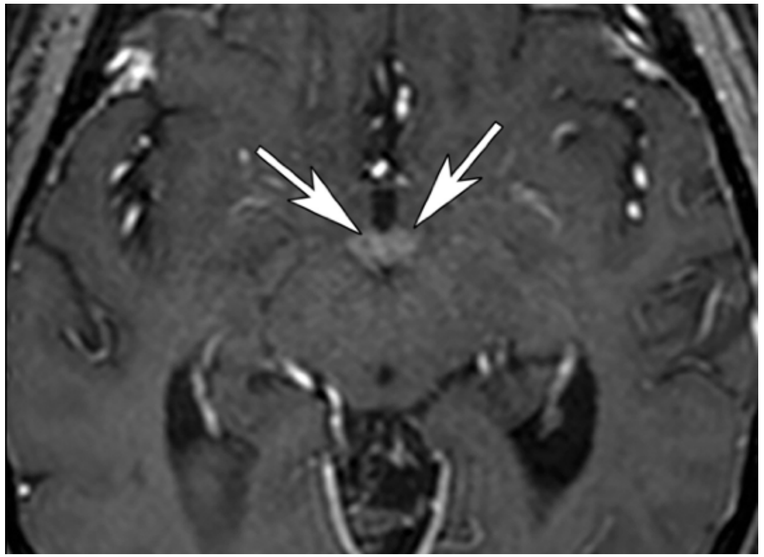

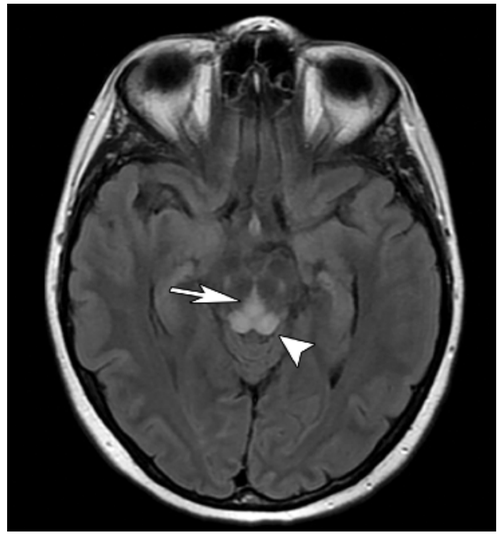

Why?
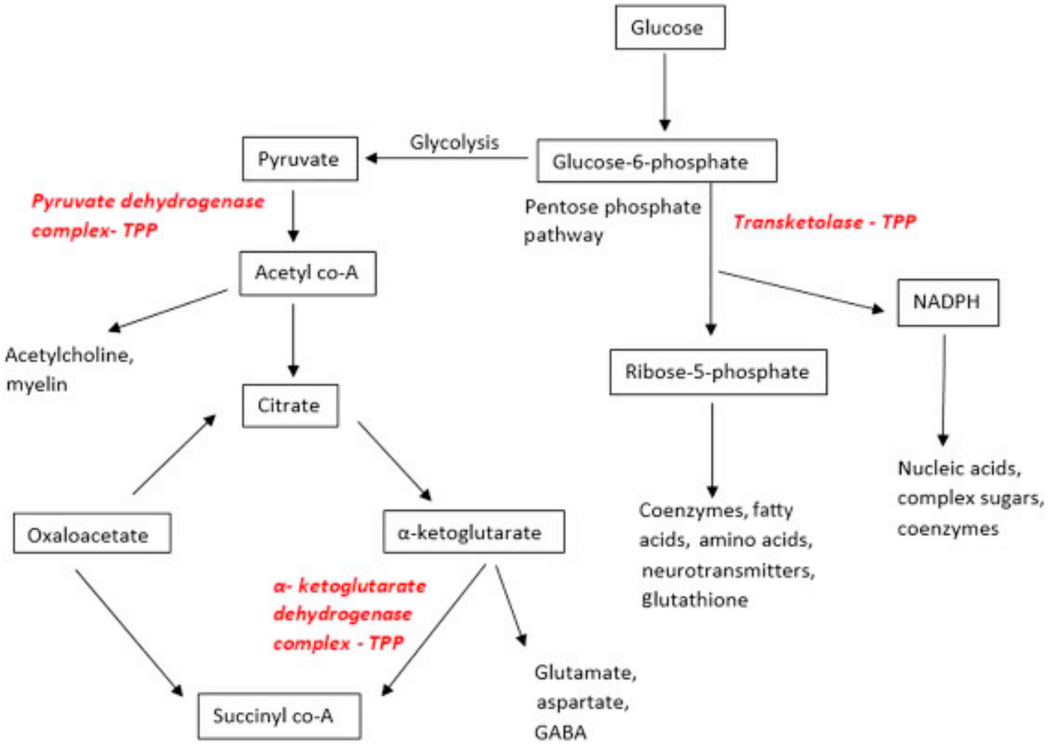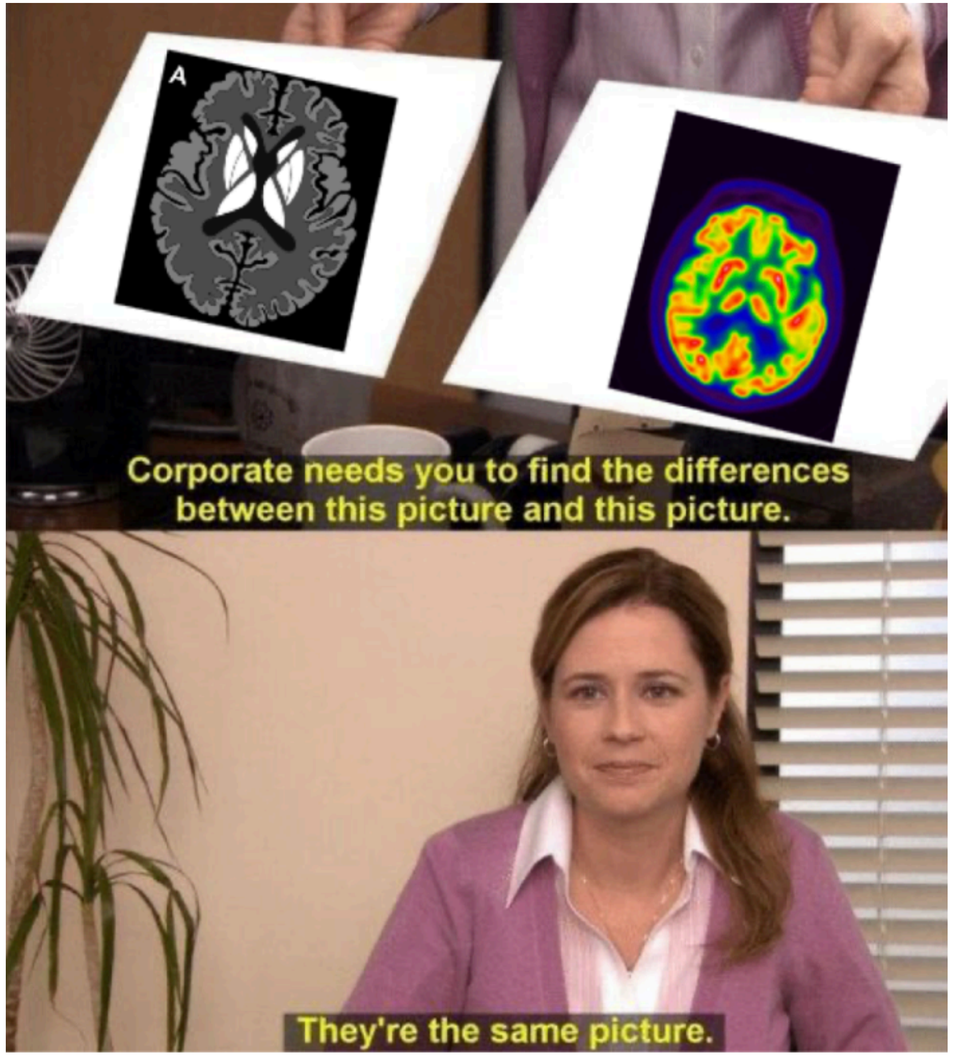
- Because thiamine is essential for aerobic glucose metabolism.