Pattern 3

Adult Hypoglycemic Encephalopathy

- predilection for posterior and deep regions
- symmetric hyperintensities on T2-weighted and FLAIR images and strong restricted diffusion affecting the gyri in the parieto-occipital and temporal regions on diffusion-weighted images
- hypoxic-ischemic brain injury

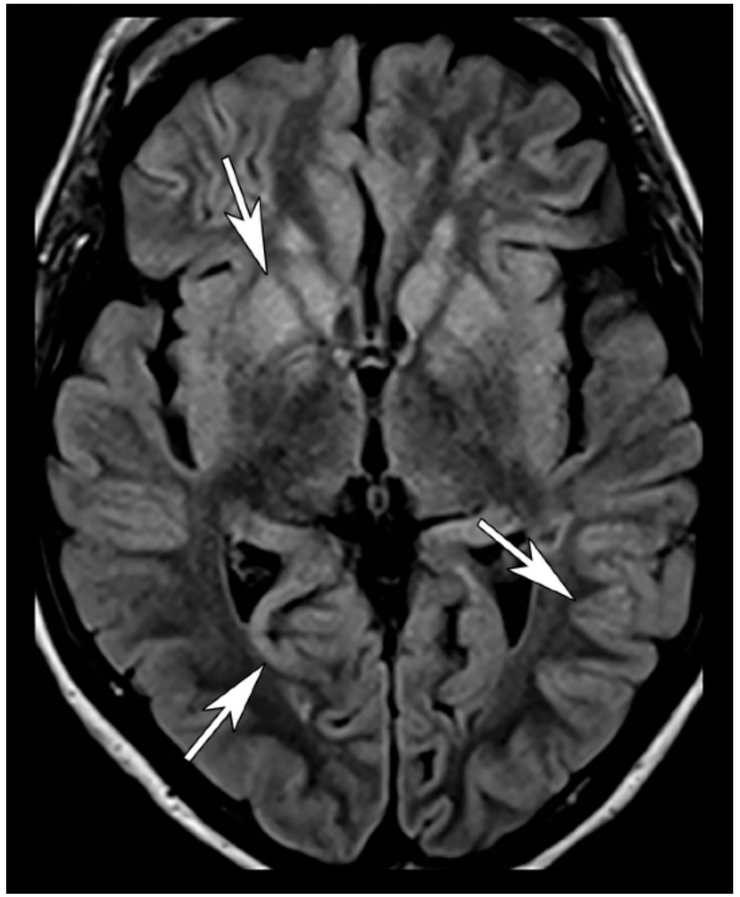

Pattern 3

Hyperammonemic Encephalopathy and Acute Hepatic Encephalopathy
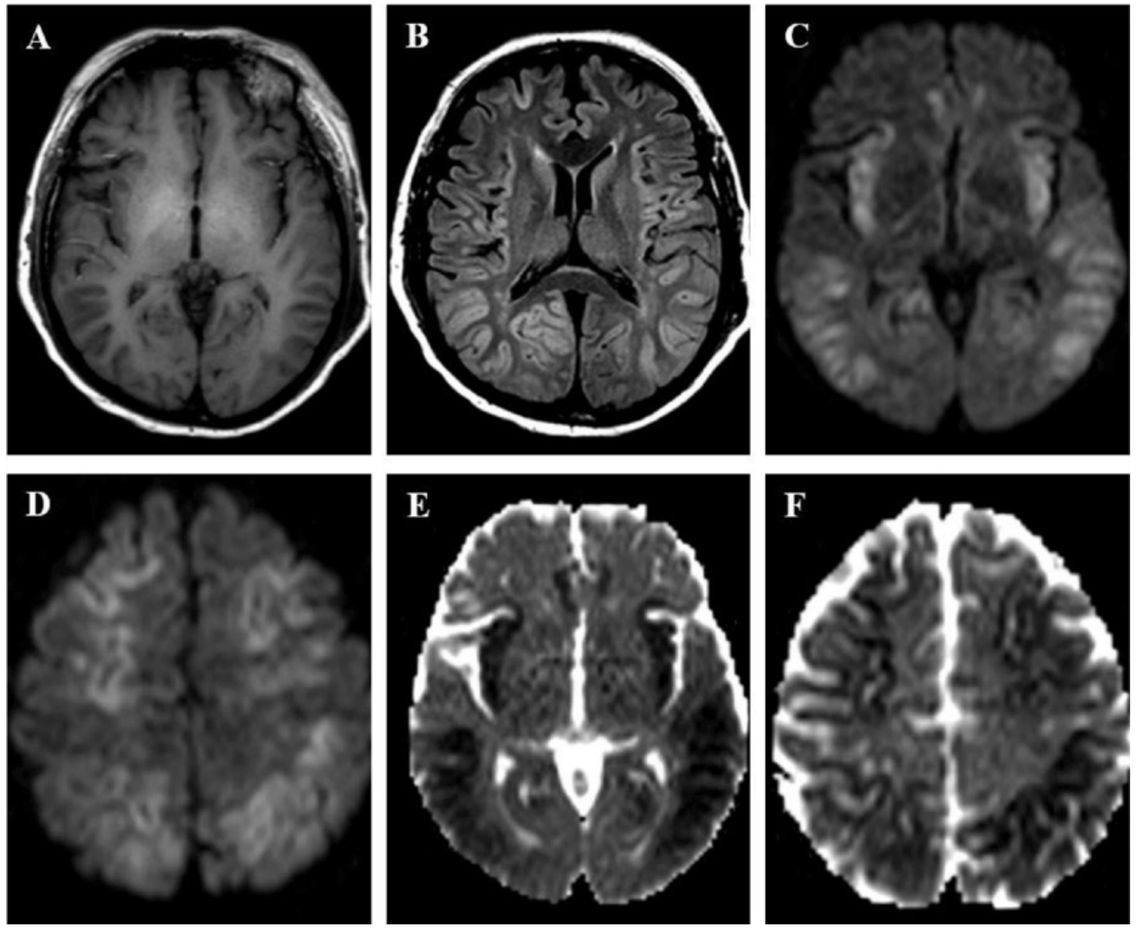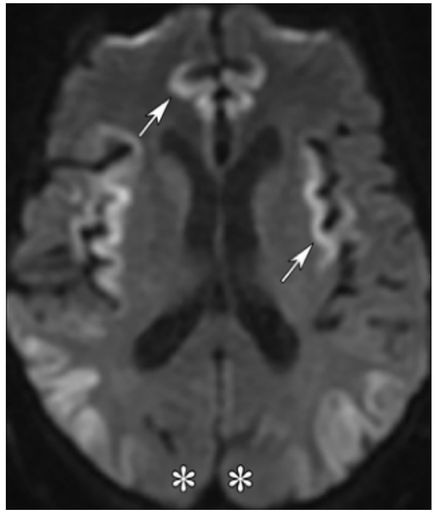
- high signal intensity symmetrically and bilaterally in the insular and cingulate gyri
- relative sparing of the occipital lobes and perirolandic region