Pattern 8

Parieto-occipital Subcortical Vasogenic Edema

- Posterior Reversible Encephalopathy Syndrome

Pattern 8

PRES, Posterior **R**eversible leuko**E**ncephalopathy **S**yndrome**,**
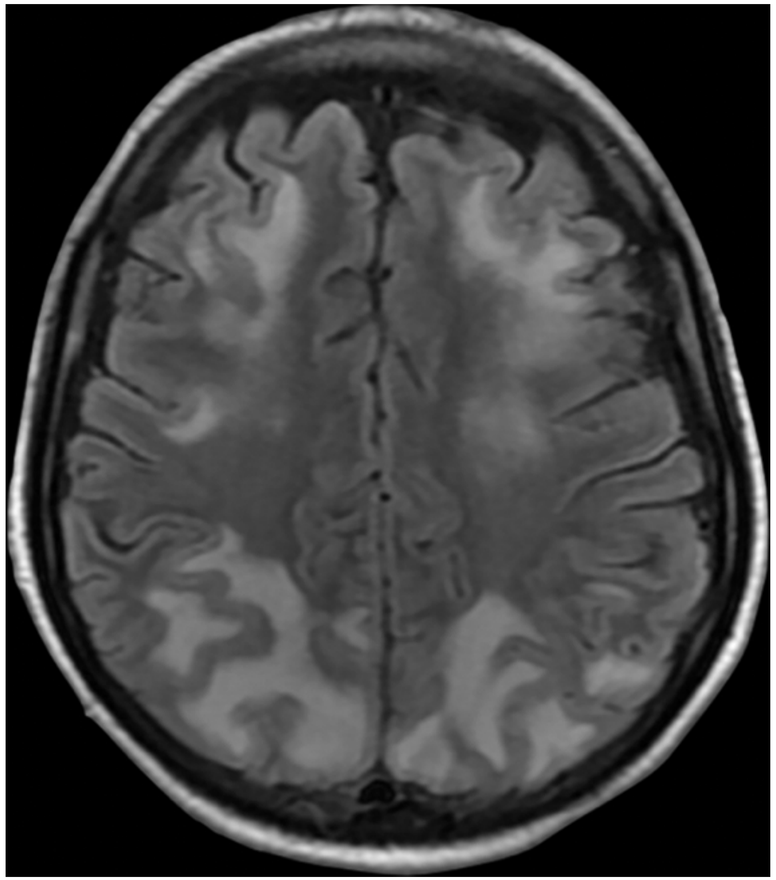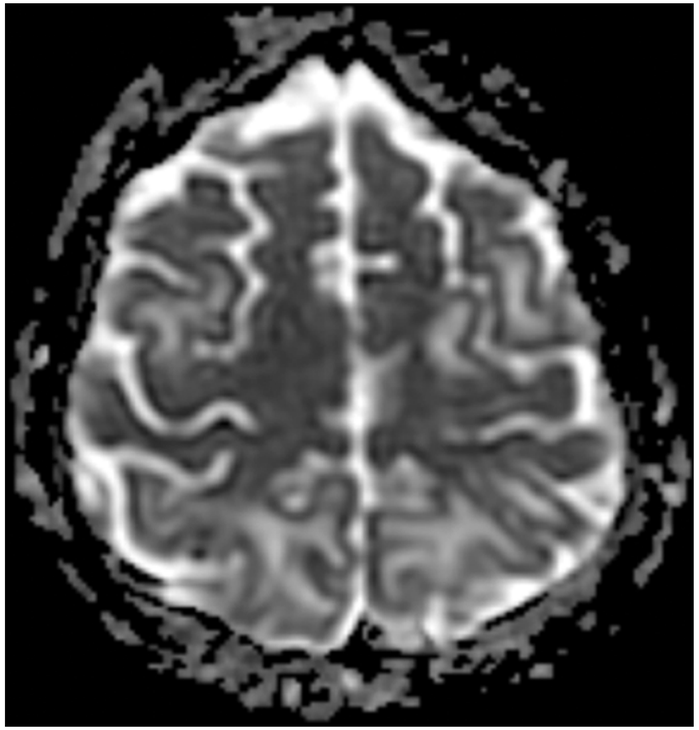
- classically described as a cerebrovascular autoregulatory disorder caused by hypertension
- vasogenic edema, commonly bilateral and asymmetric
- many patterns
  - parieto-occipital (classic)
  - superior frontal sulcus
  - holohemispheric watershed
  - sporadic (cerebellum, basal ganglia, brainstem)