Pattern 2

Metronidazole-induced Brain Toxicity

- bilateral symmetric lesions in the cerebellum, particularly involving the dentate nuclei
- can also occur with isoniazid

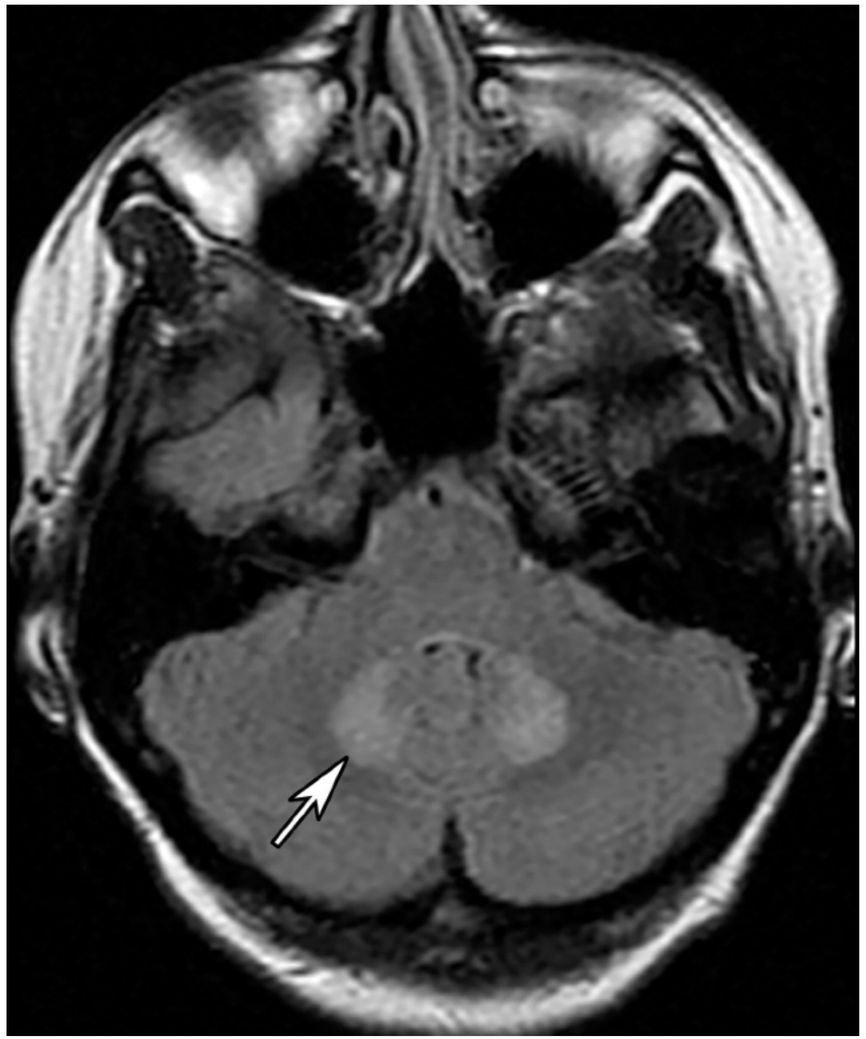

Pattern 2

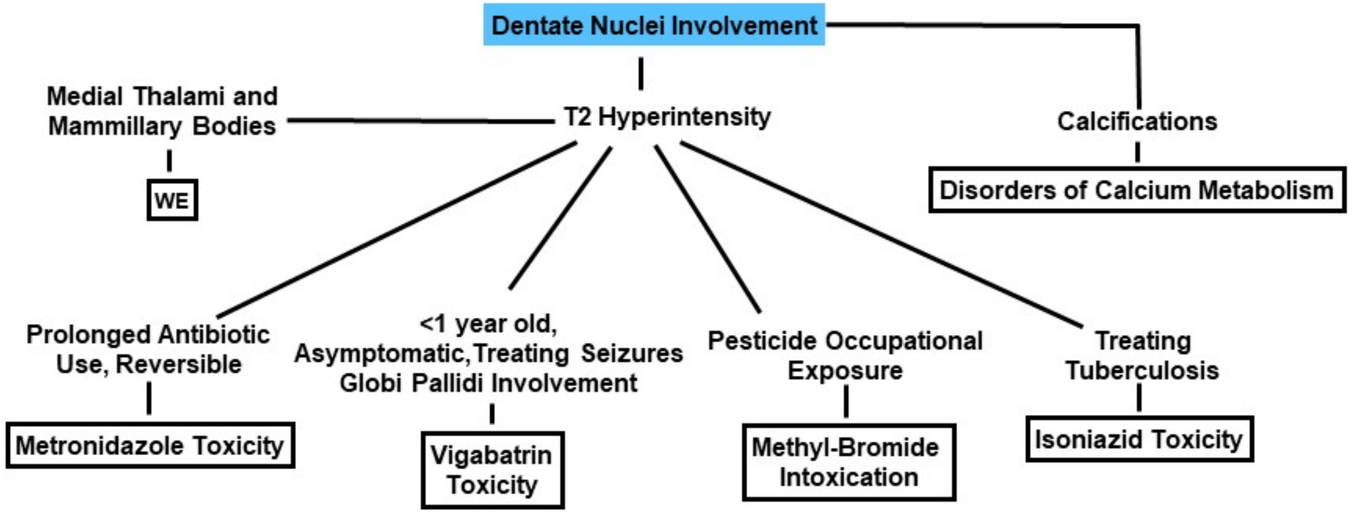
Dentate Nuclei Involvement
T2 Hyperintensity
Medial Thalami and Mammillary Bodies
WE
Calcifications
Disorders of Calcium Metabolism
Prolonged Antibiotic Use, Reversible
Metronidazole Toxicity
<1 year old, Asymptomatic, Treating Seizures Globi Pallidi Involvement
Vigabatrin Toxicity
Pesticide Occupational Exposure
Methyl-Bromide Intoxication
Treating Tuberculosis
Isoniazid Toxicity