Pattern 1b: T2 Hypointensity

Parathyroid-Hypofunction Disorders and Hyperparathyroidism-related Disorders

- hypoparathyroidism
- pseudohypoparathyroidism
- pseudopseudohypoparathyroidism
- calcium deposition in the basal ganglia

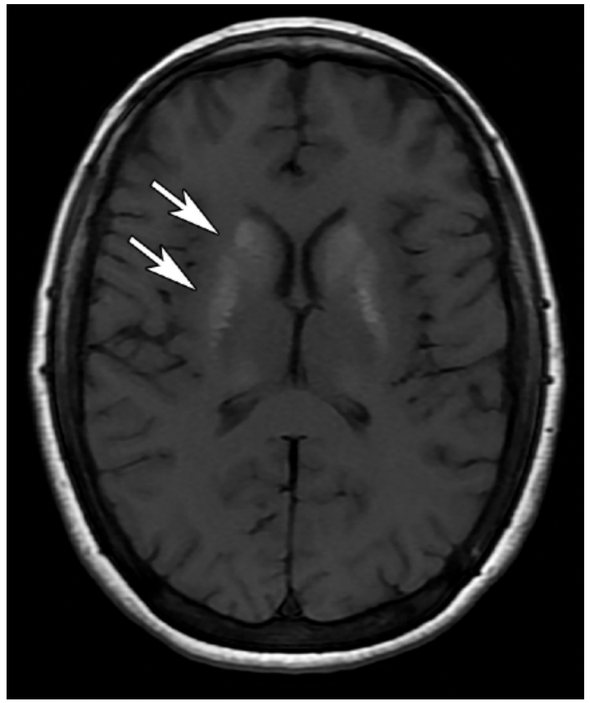

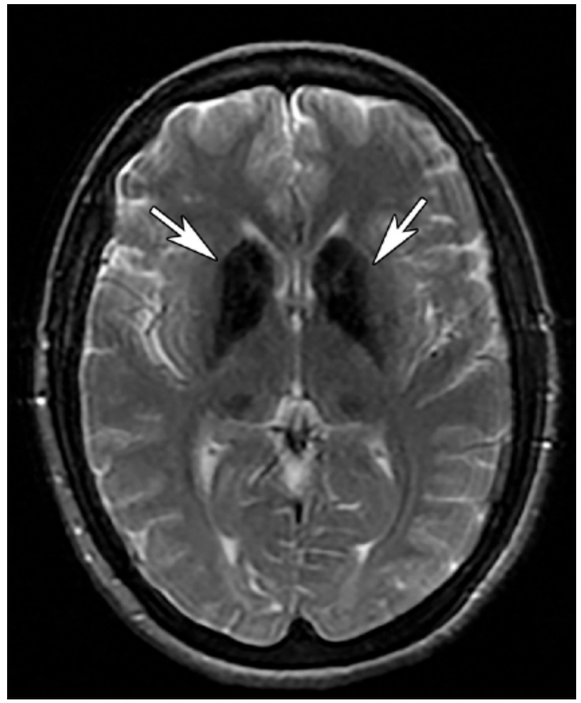

Pattern 1c: T1 Hyperintensity

Diabetic striatopathy or *hyperglycemia-induced hemichorea-hemiballismus*
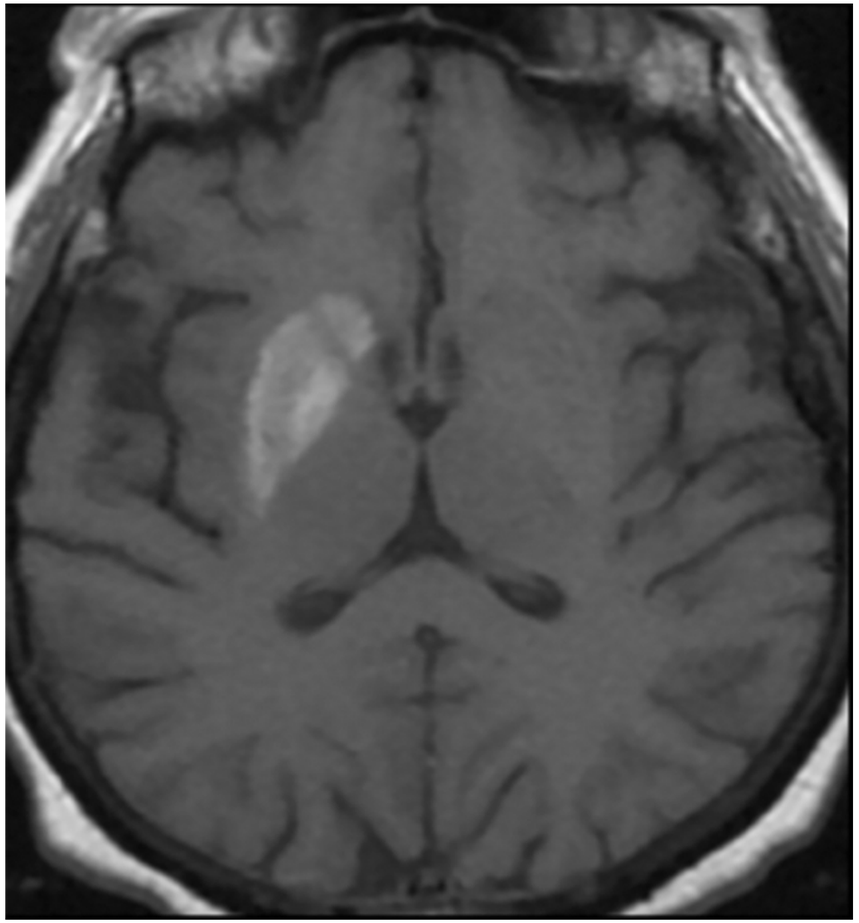
- unilateral T1 hyperintensity involving the striatum and hyperattenuation in the same region on CT images
- usually reversible