Pattern 9

Osmotic Demyelination Syndrome

- well-demarcated and symmetric, rounded, or trident-shaped lesions on the central pons that characteristically spare the peripheral pons and corticospinal tract regions
- 50% isolated to pons, 30% pontine and extrapontine, and 20% extrapontine only

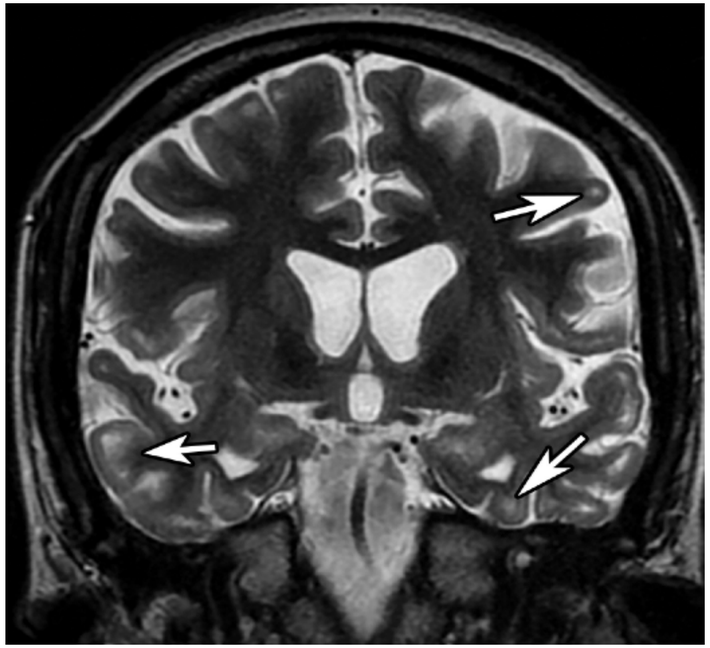

CHANTER Syndrome

Cerebellar **H**ippocampal **A**nd basal **N**uclei **T**ransient **E**dema with **R**estricted diffusion

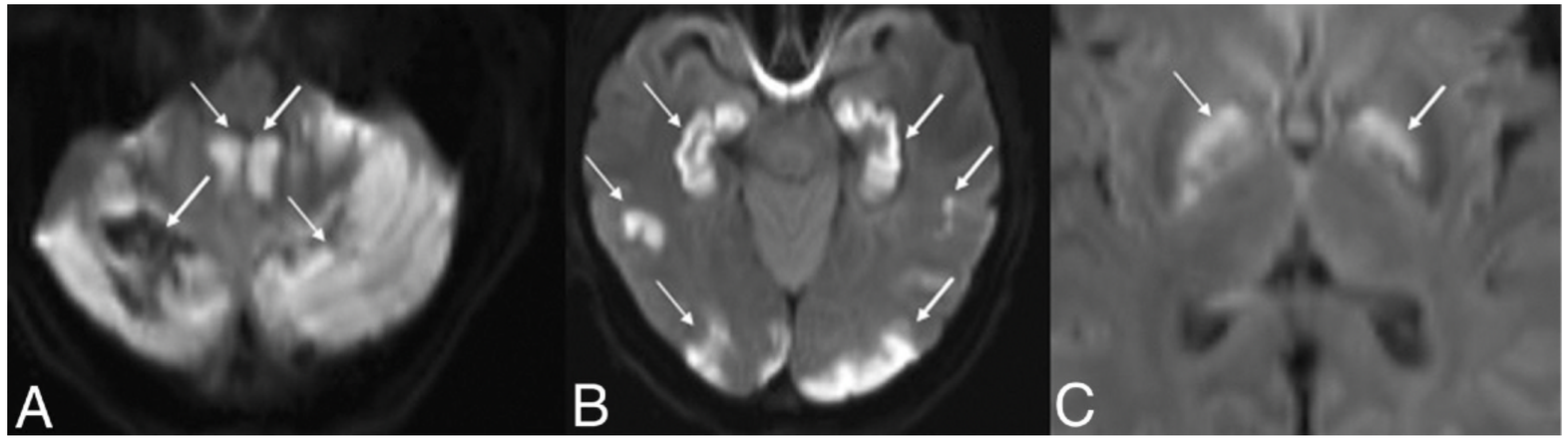

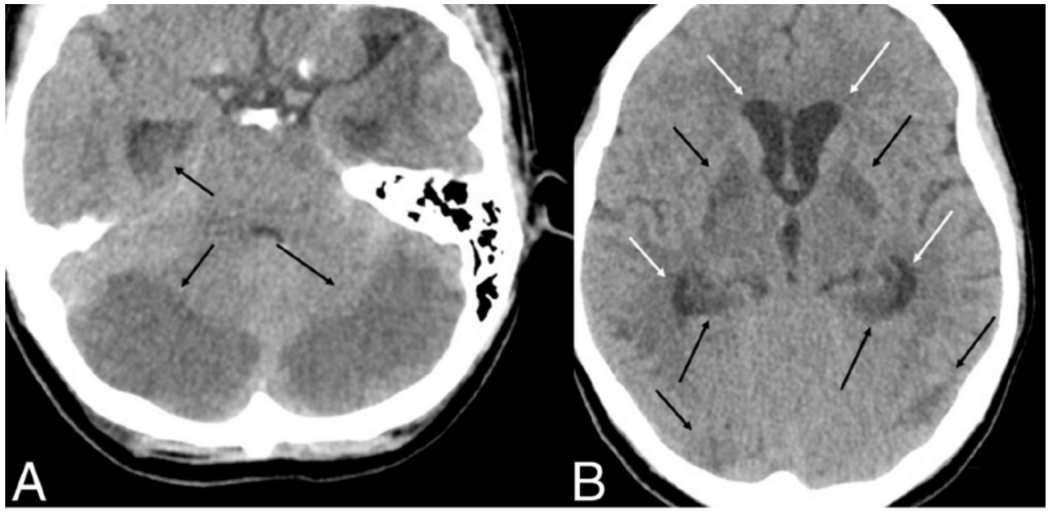

A 54-year-old woman presented in an unresponsive state after a fentanyl overdose.