Pattern 2

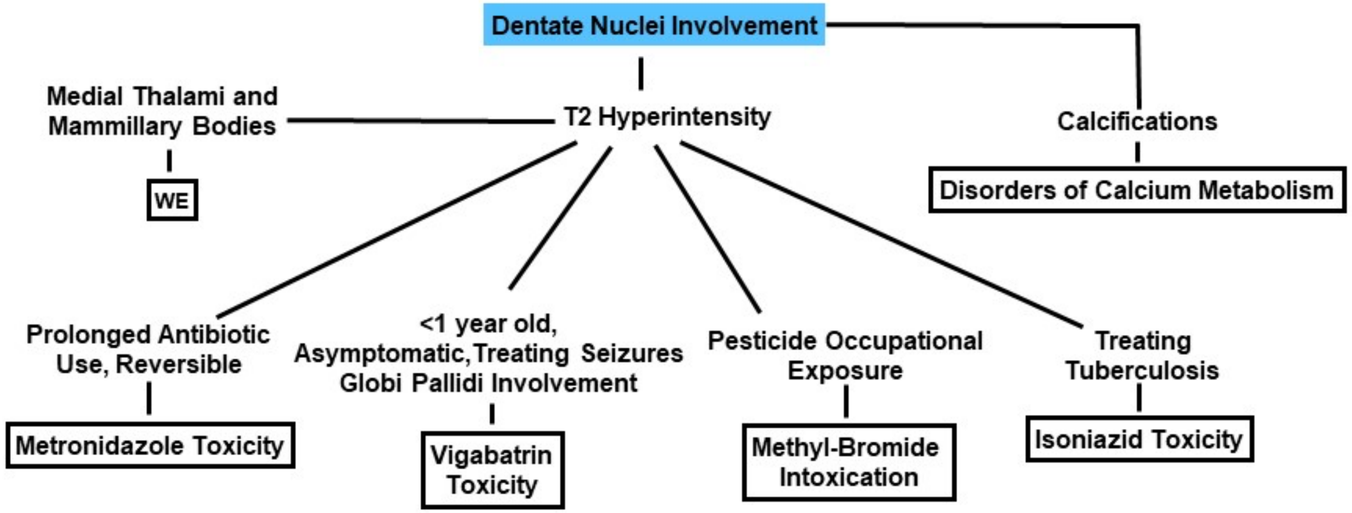
Dentate Nuclei Involvement
T2 Hyperintensity
Medial Thalami and Mammillary Bodies
WE
Calcifications
Disorders of Calcium Metabolism
Prolonged Antibiotic Use, Reversible
Metronidazole Toxicity
<1 year old, Asymptomatic, Treating Seizures Globi Pallidi Involvement
Vigabatrin Toxicity
Pesticide Occupational Exposure
Methyl-Bromide Intoxication
Treating Tuberculosis
Isoniazid Toxicity

Pattern 3

Prominent Cortical Involvement
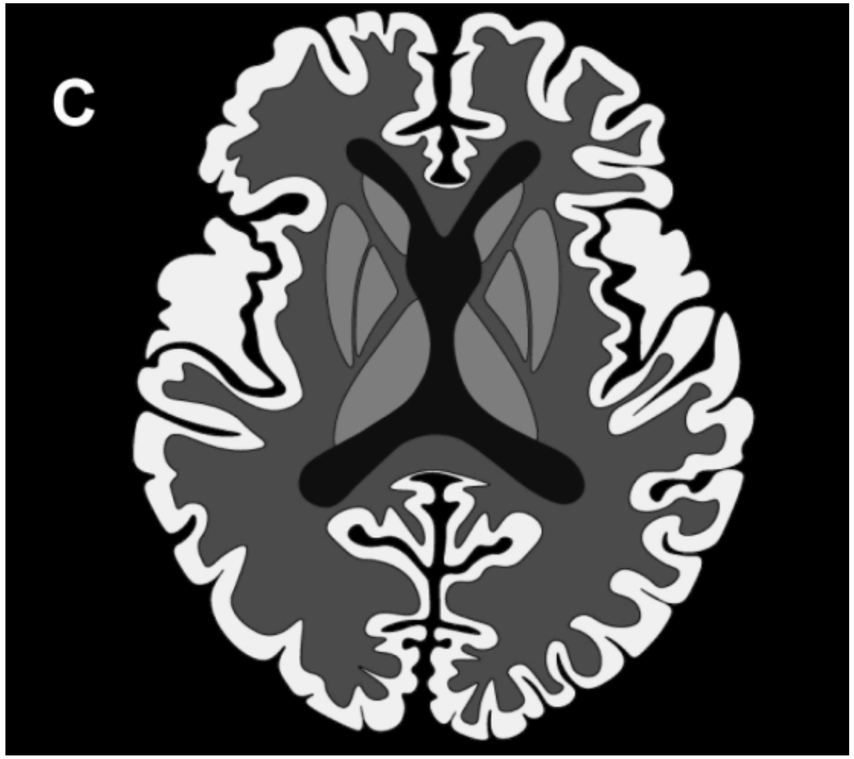
- Adult Hypoglycemic Encephalopathy
- Hyperammonemic Encephalopathy and AHE
- Hypoxic-ischemic encephalopathy