CHANTER Syndrome

Cerebellar **H**ippocampal **A**nd basal **N**uclei **T**ransient **E**dema with **R**estricted diffusion

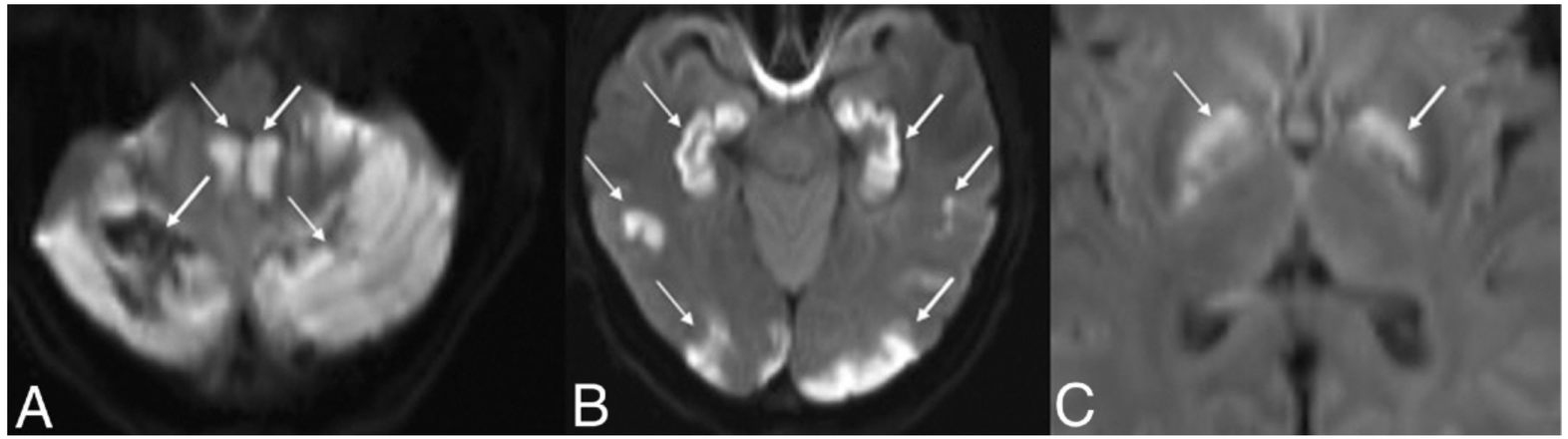

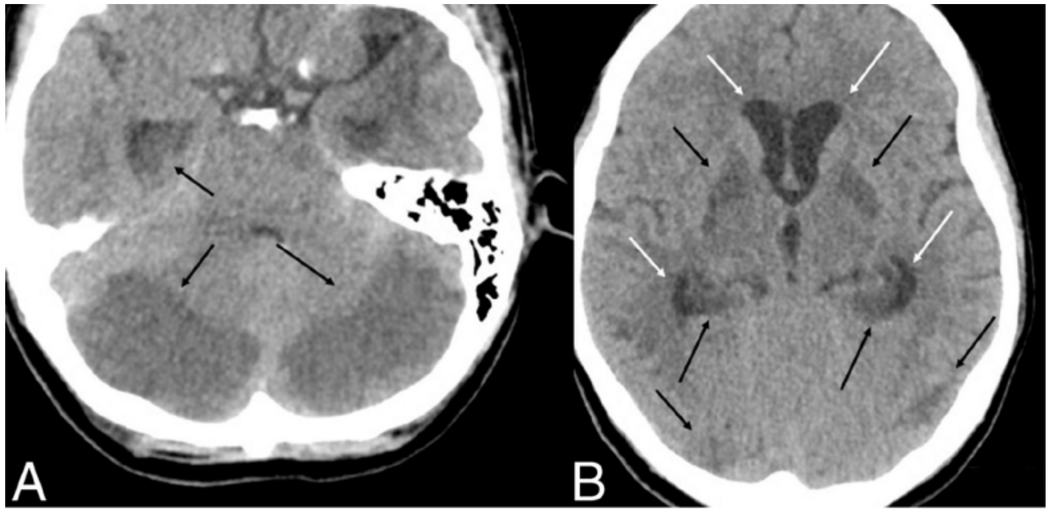

A 54-year-old woman presented in an unresponsive state after a fentanyl overdose.

Review

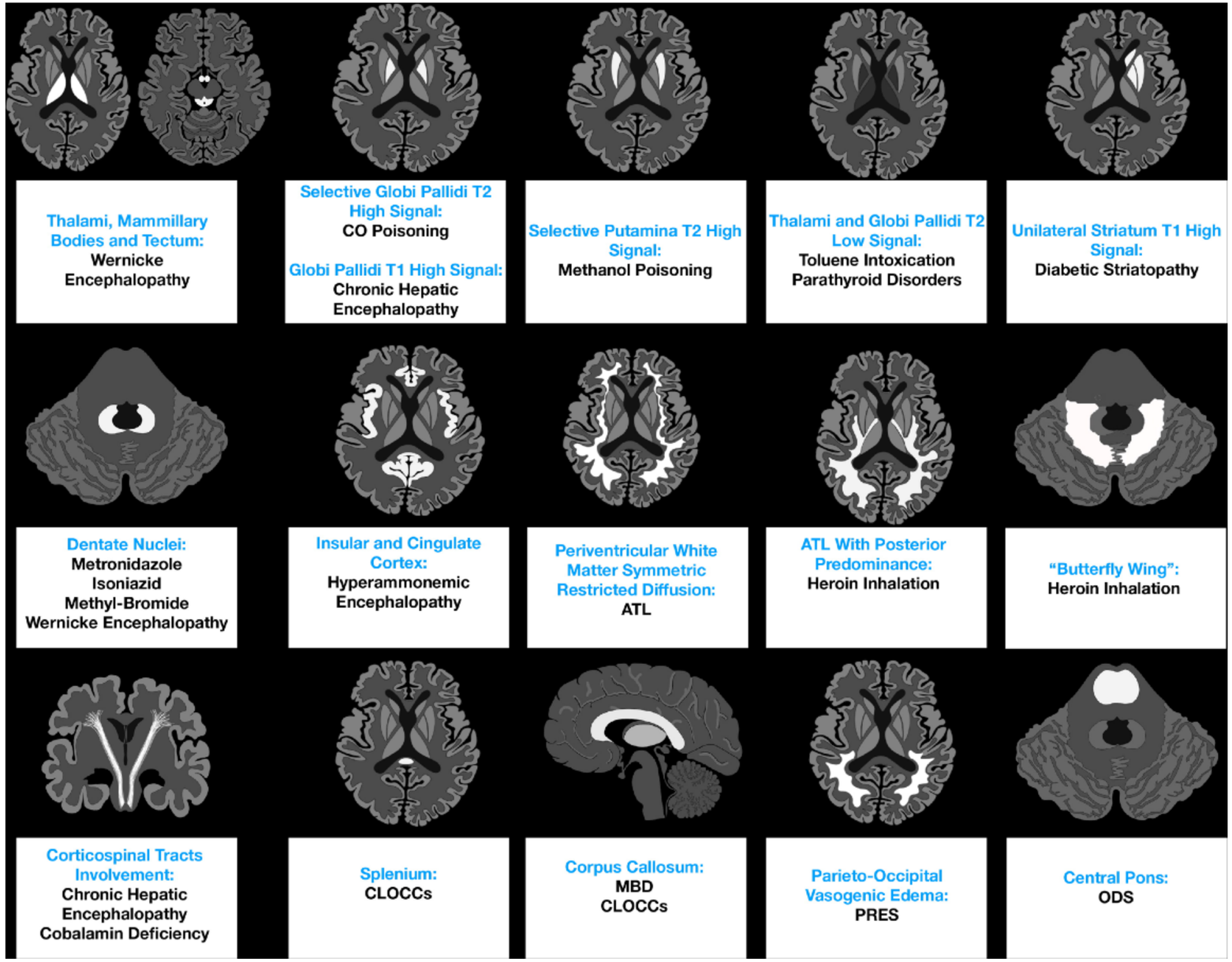
Thalami, Mammillary Bodies and Tectum:
Wernicke Encephalopathy
Selective Globi Pallidi T2 High Signal:
CO Poisoning
Globi Pallidi T1 High Signal:
Chronic Hepatic Encephalopathy
Selective Putamina T2 High Signal:
Methanol Poisoning
Thalami and Globi Pallidi T2 Low Signal:
Toluene Intoxication
Parathyroid Disorders
Unilateral Striatum T1 High Signal:
Diabetic Striatopathy
Dentate Nuclei:
Metronidazole
Isoniazid
Methyl-Bromide
Wernicke Encephalopathy
Insular and Cingulate Cortex:
Hyperammonemic Encephalopathy
Periventricular White Matter Symmetric Restricted Diffusion:
ATL
ATL With Posterior Predominance:
Heroin Inhalation
"Butterfly Wing":
Heroin Inhalation
Corticospinal Tracts Involvement:
Chronic Hepatic Encephalopathy
Cobalamin Deficiency
Splenium:
CLOCCs
Corpus Callosum:
MBD
CLOCCs
Parieto-Occipital Vasogenic Edema:
PRES
Central Pons:
ODS