Pattern 3

Prominent Cortical Involvement

- Adult Hypoglycemic Encephalopathy
- Hyperammonemic Encephalopathy and AHE
- Hypoxic-ischemic encephalopathy

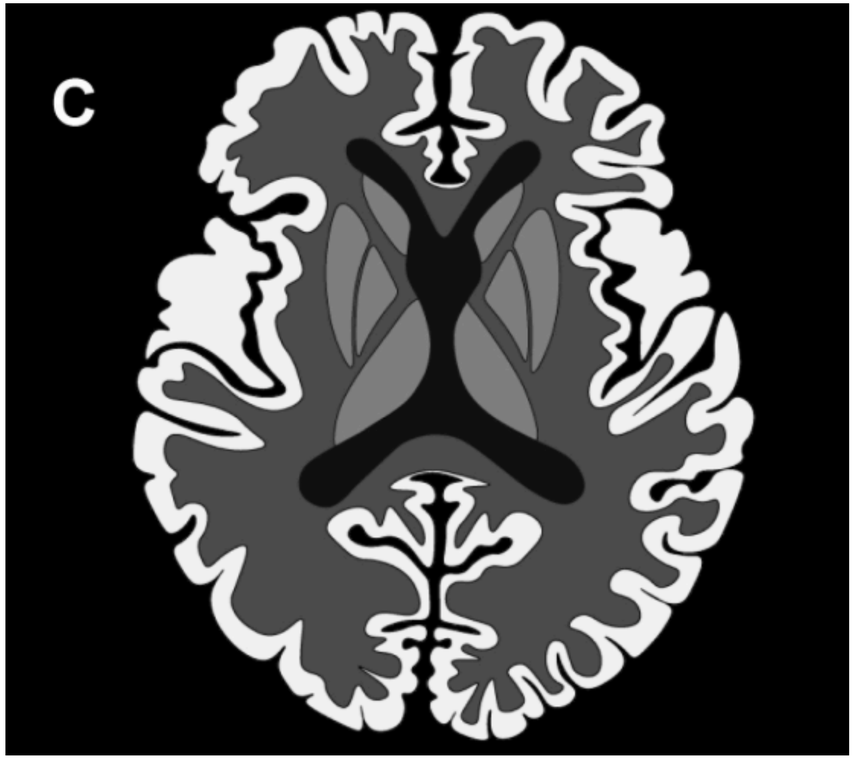

Pattern 3

Adult Hypoglycemic Encephalopathy
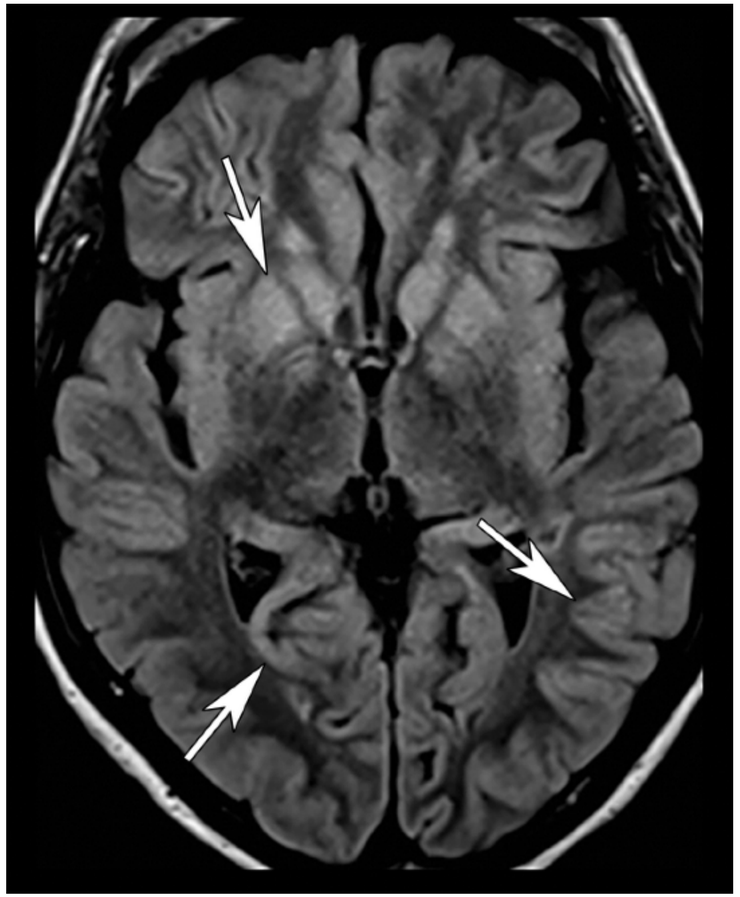
- predilection for posterior and deep regions
- symmetric hyperintensities on T2-weighted and FLAIR images and strong restricted diffusion affecting the gyri in the parieto-occipital and temporal regions on diffusion-weighted images
- hypoxic-ischemic brain injury