Pattern 6

Corpus Callosum Involvement

- Marchiafava-Bignami Disease
- RSL

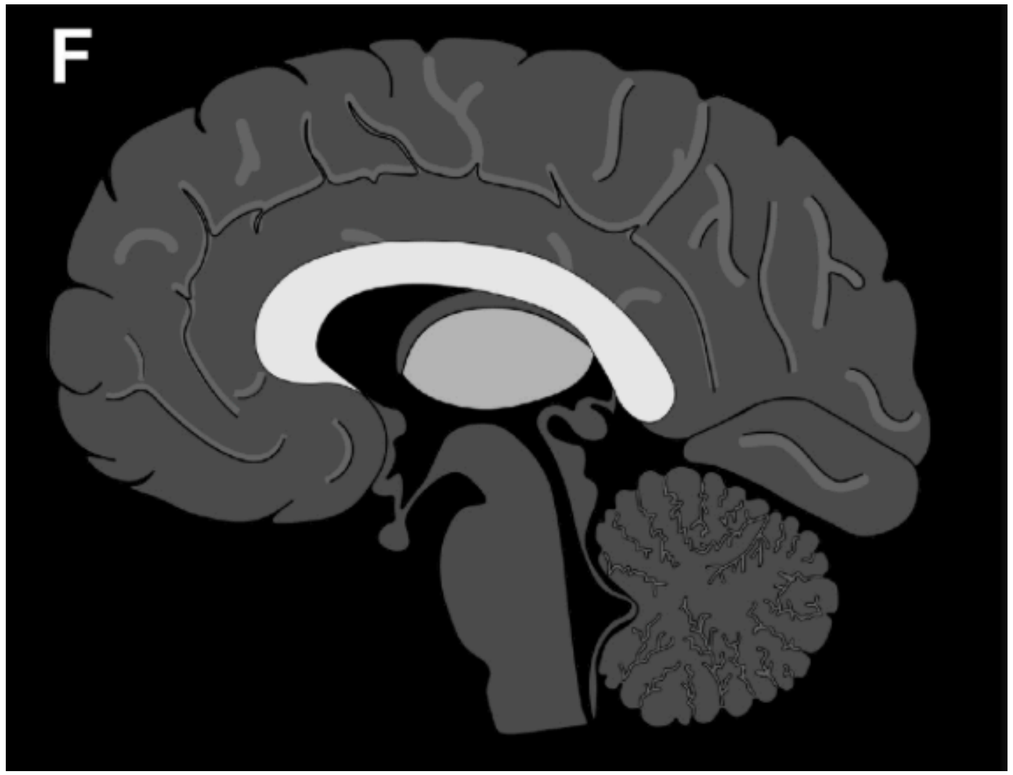

Pattern 6

Marchiafava-Bignami Disease
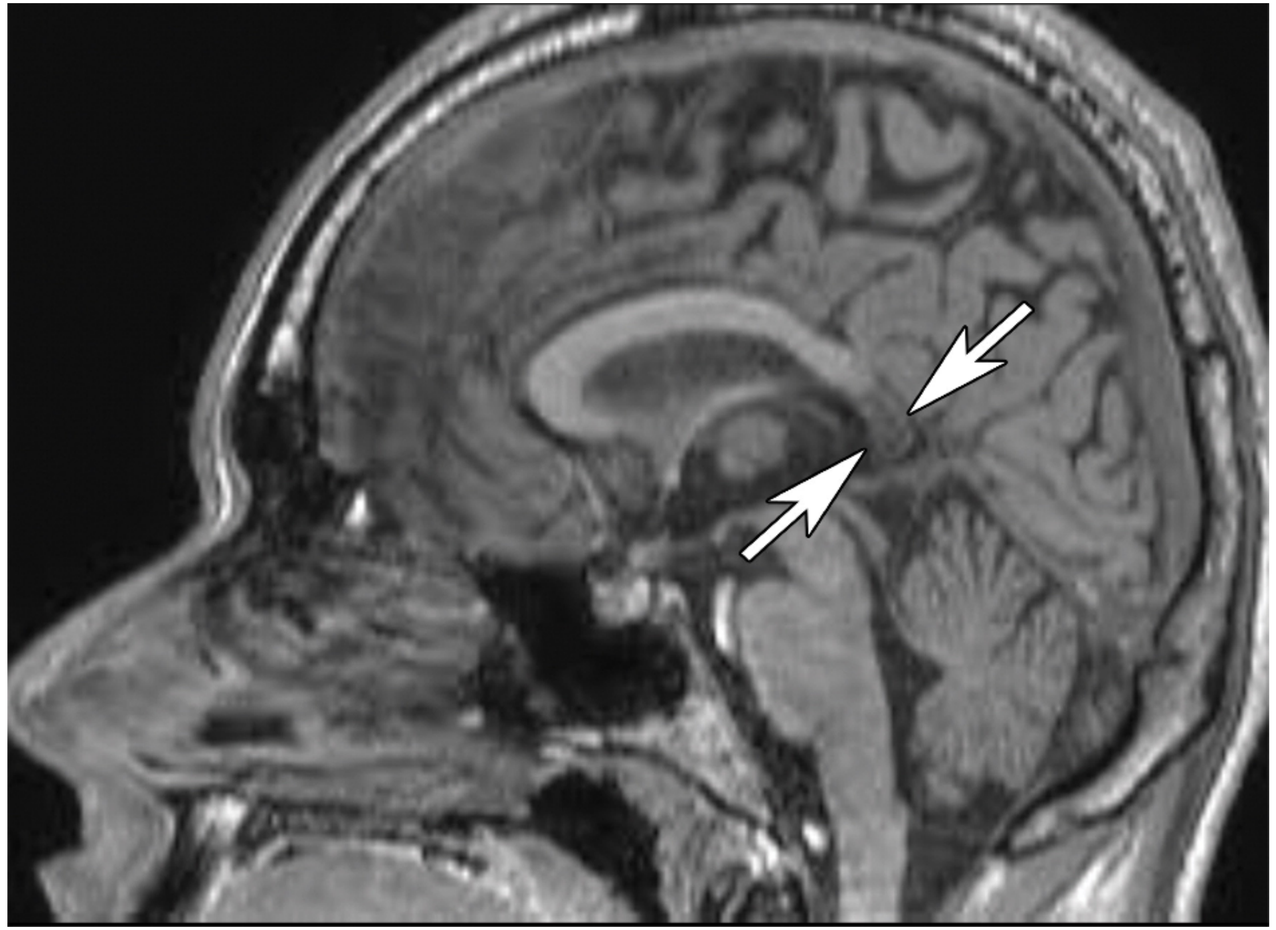
- Selective involvement of the middle layers of the corpus callosum in the context of chronic ethanol use
- sandwich sign— central callosal involvement sparing the periphery
- diffusion restriction occurring later