Pattern 6

RSL— Reversible Splenial Lesion

- also known as **CLOCC**— **C**ytotoxic **L**esion **O**f the **C**orpus **C**allosum
- ovoid lesions involving the central splenium
- splenium has a high density of excitatory receptors

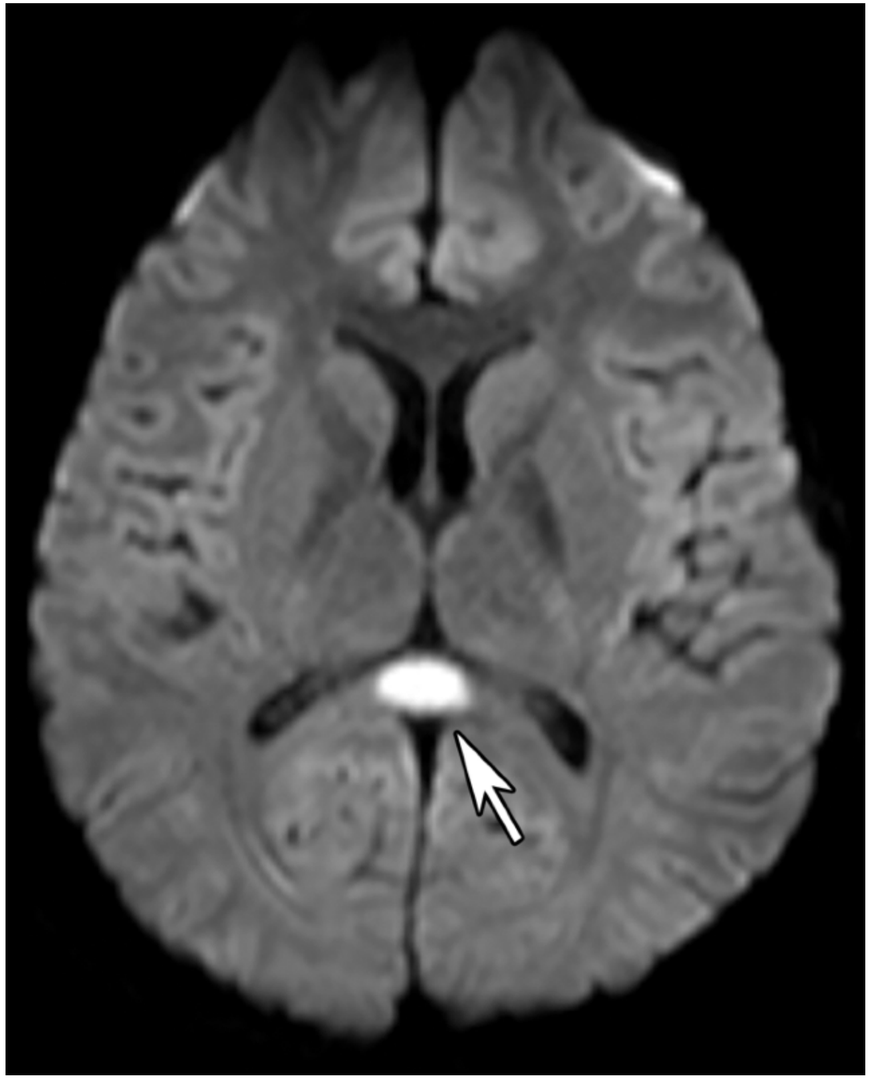

Pattern 7

Asymmetric White Matter Involvement (Demyelinating Disease Pattern)
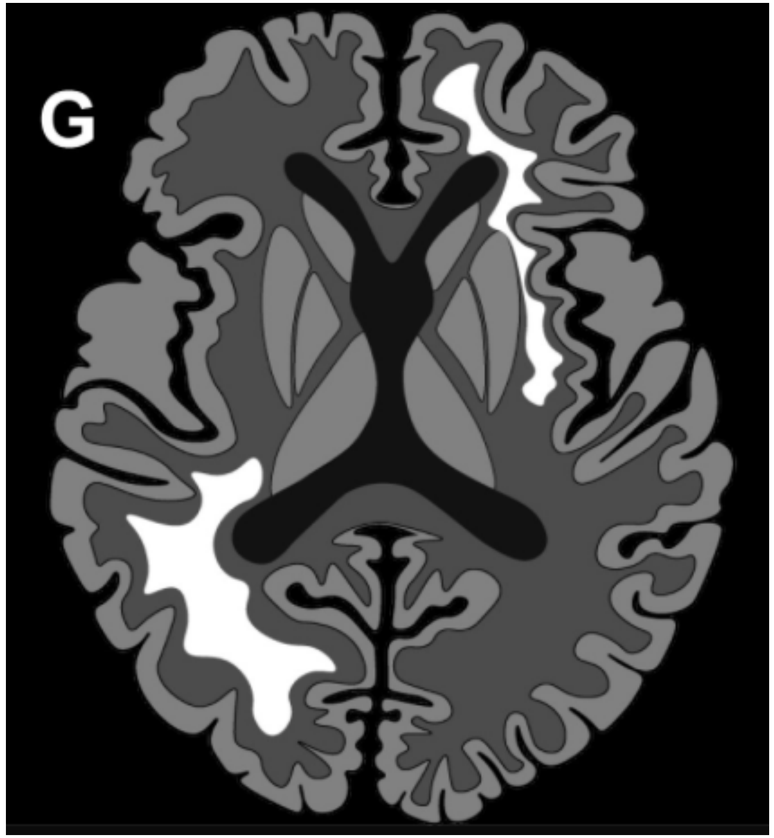
- Chemotherapeutic Agents
- Levamisole-induced Leukoencephalopathy