Types of cerebral edema

- **Cytotoxic**
  - extracellular water passes into cells
  - does not compromise the blood-brain barrier
  - mainly involves the gray matter
  - irreversible

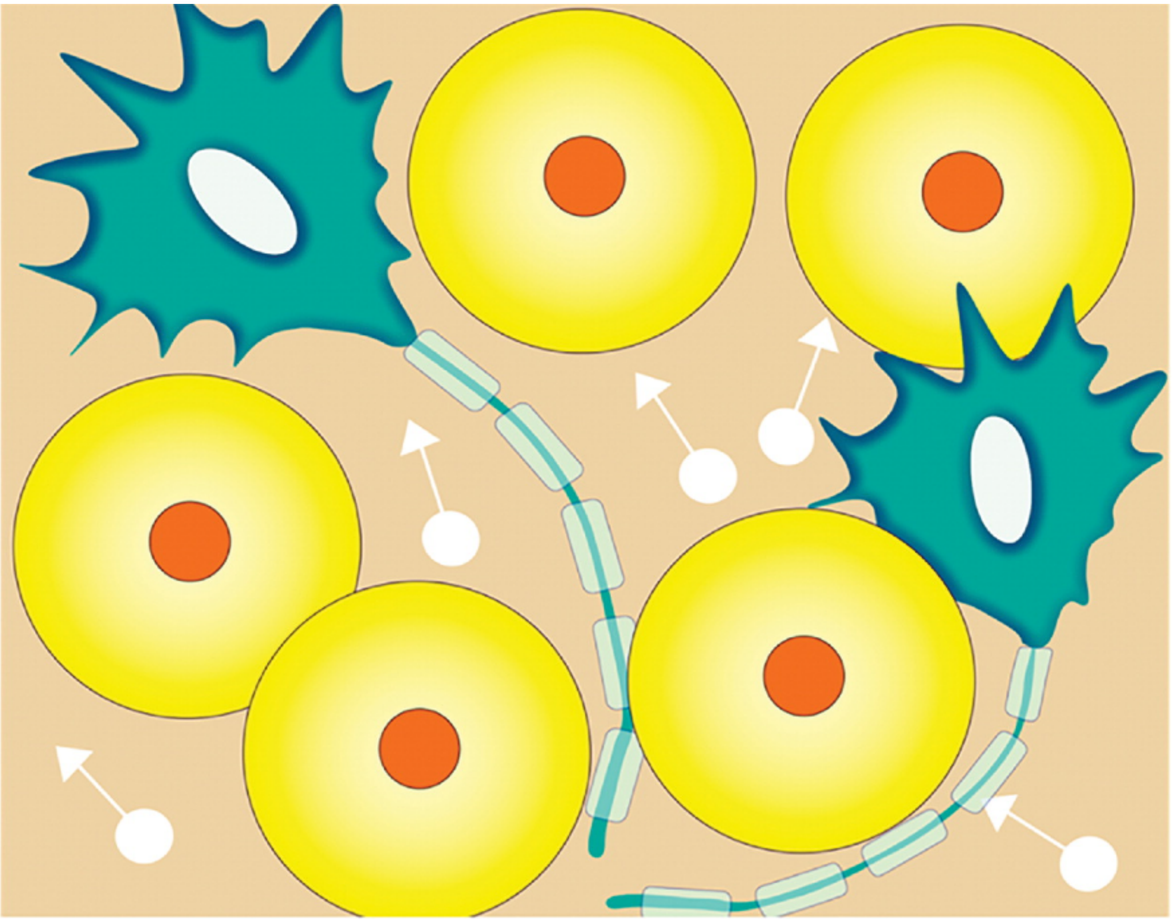

Types of cerebral edema
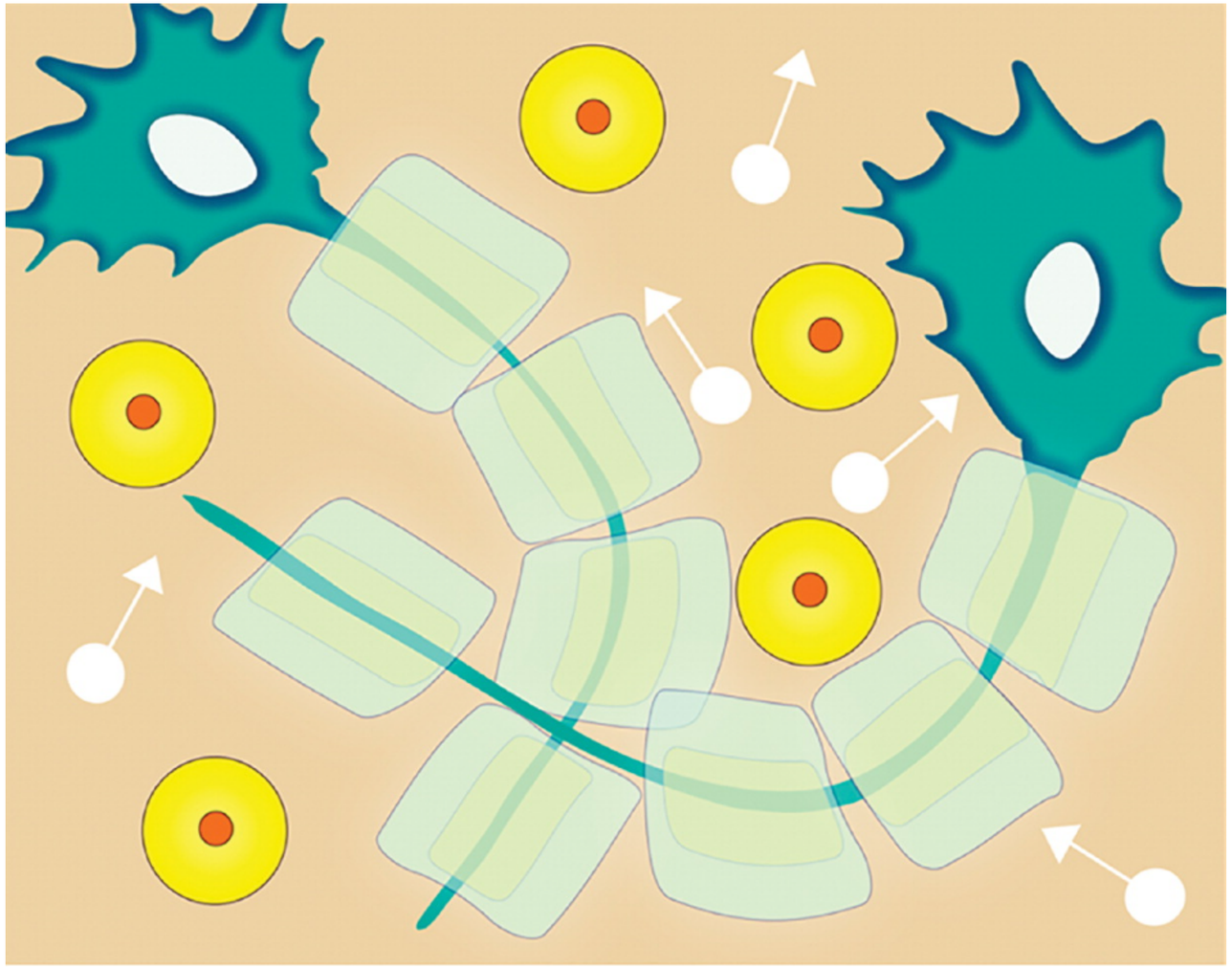
- **Intramyelinic**
  - edema in the periaxonal space and spaces between myelin layers
  - result of excitotoxic brain injury, excessive glutamate in the synaptic cleft
  - mainly involves the periventricular white matter and the splenium
  - reversible