Pattern 9

Symmetric Central Pontine Involvement

- Osmotic demyelination syndrome

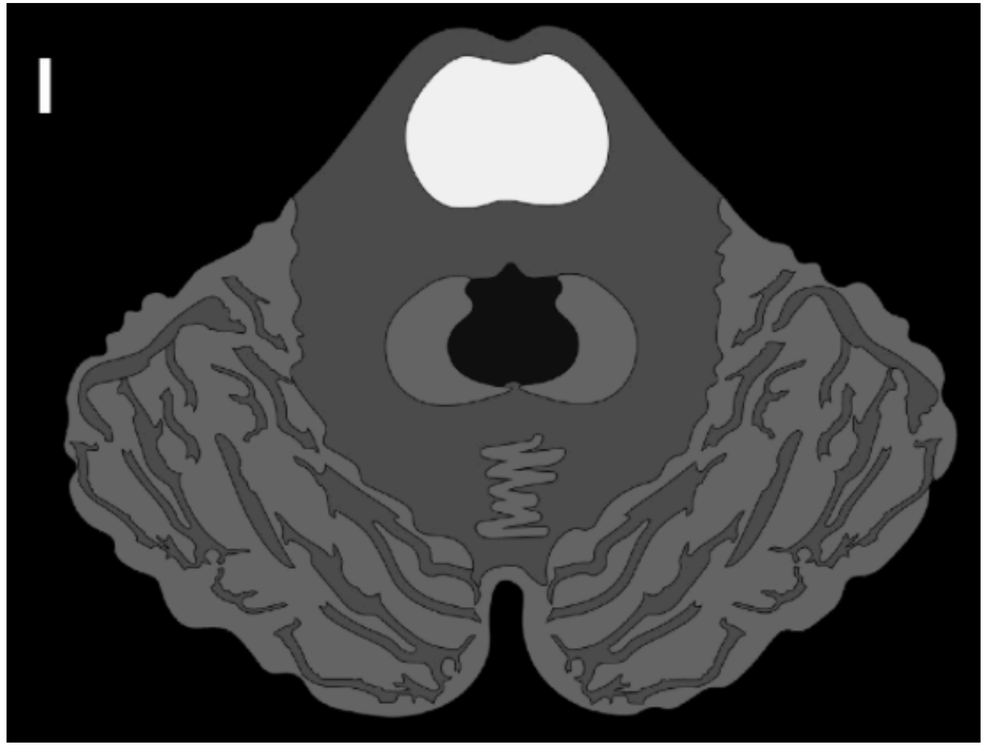

Pattern 9

Osmotic Demyelination Syndrome
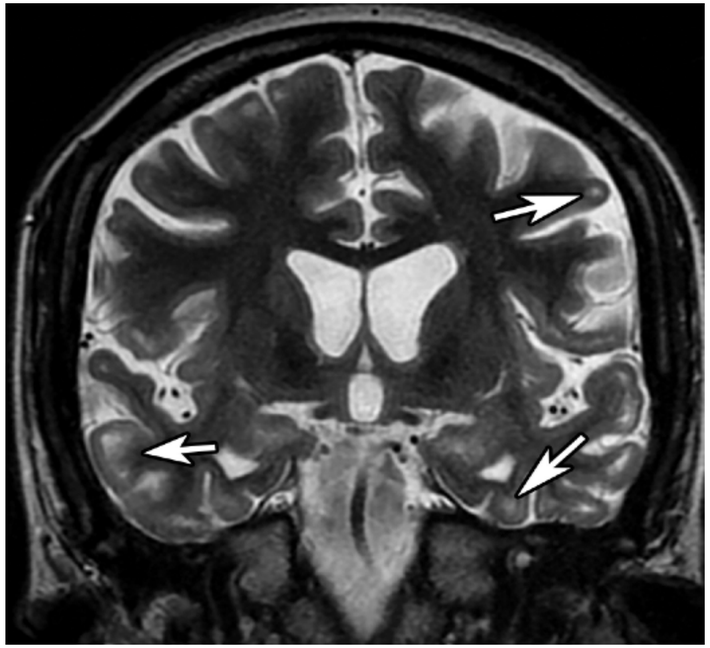
- well-demarcated and symmetric, rounded, or trident-shaped lesions on the central pons that characteristically spare the peripheral pons and corticospinal tract regions
- 50% isolated to pons, 30% pontine and extrapontine, and 20% extrapontine only