Pattern 6

Marchiafava-Bignami Disease

- Selective involvement of the middle layers of the corpus callosum in the context of chronic ethanol use
- sandwich sign— central callosal involvement sparing the periphery
- diffusion restriction occurring later

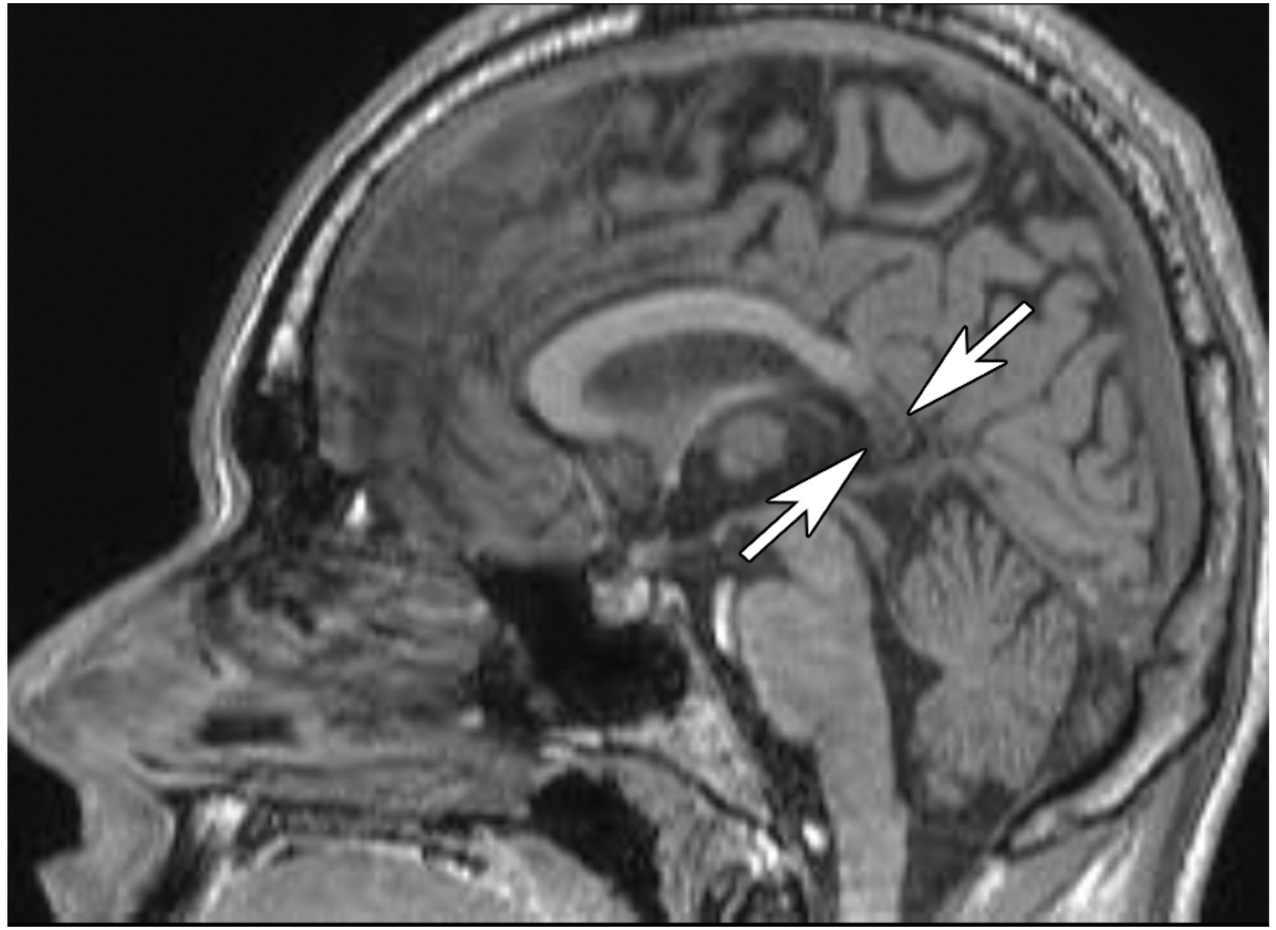

Pattern 6

RSL— Reversible Splenial Lesion
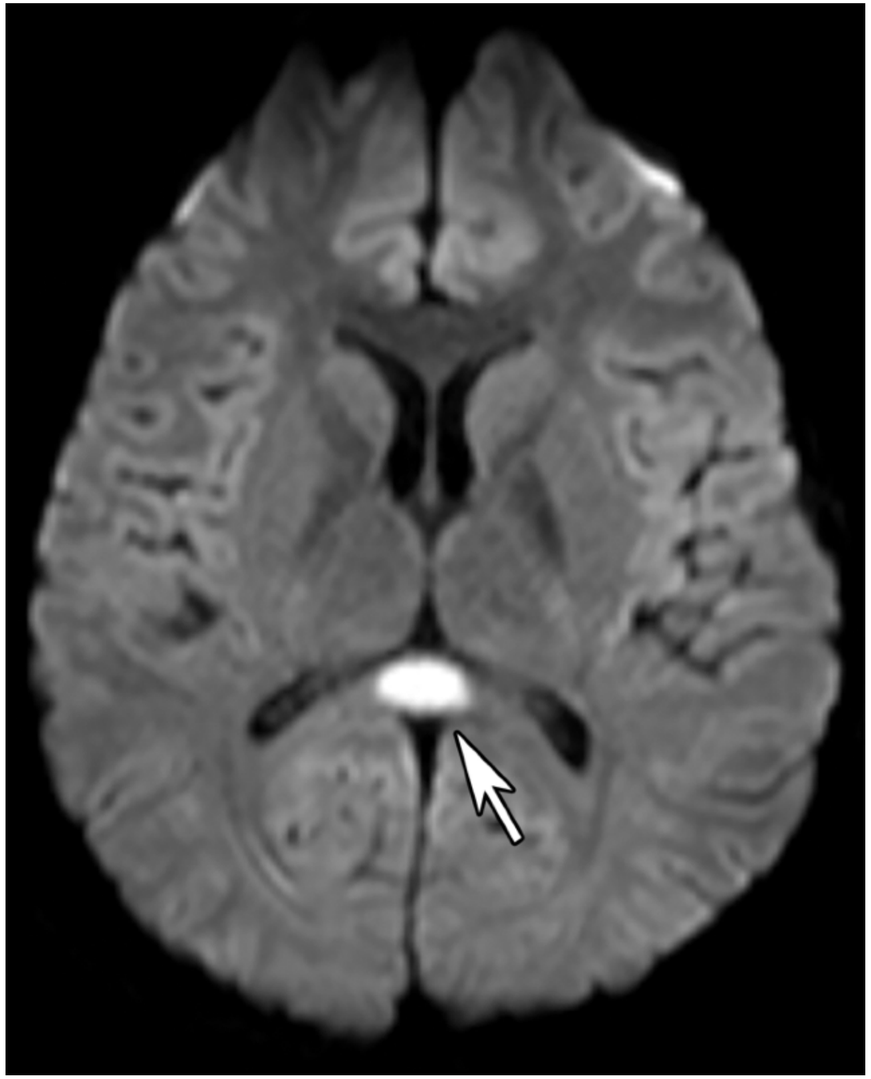
- also known as **CLOCC**— **C**ytotoxic **L**esion **O**f the **C**orpus **C**allosum
- ovoid lesions involving the central splenium
- splenium has a high density of excitatory receptors