Pattern 1c: T1 Hyperintensity

Diabetic striatopathy or *hyperglycemia-induced hemichorea-hemiballismus*

- unilateral T1 hyperintensity involving the striatum and hyperattenuation in the same region on CT images
- usually reversible

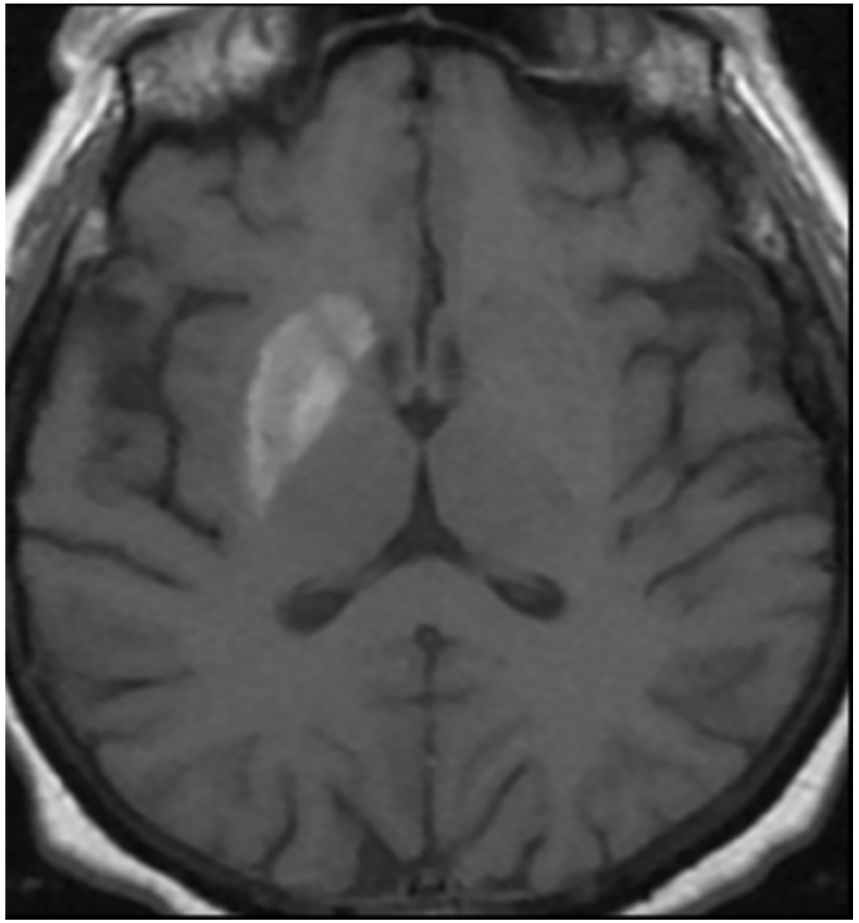

Pattern 1c: T1 Hyperintensity

Chronic hepatic encephalopathy

- bilateral and symmetric T1 hyperintensity involving the globi pallidi and substantiae nigrae — most likely due to **manganese** accumulation
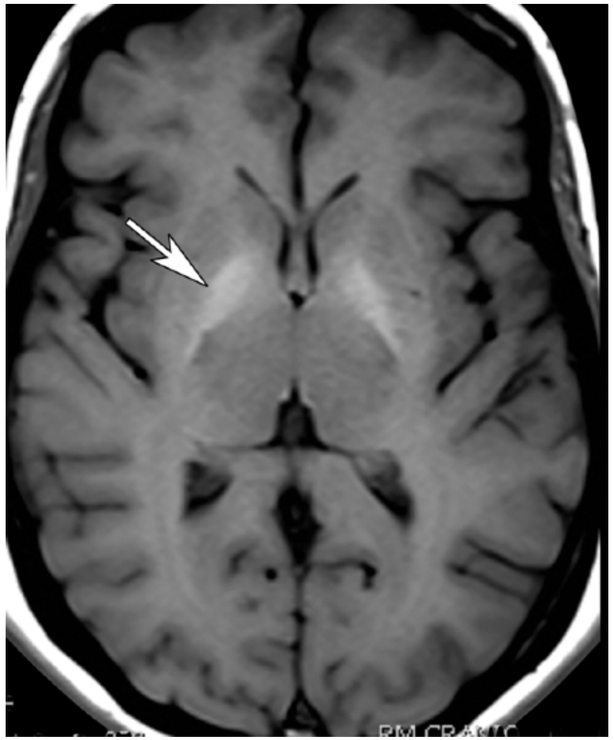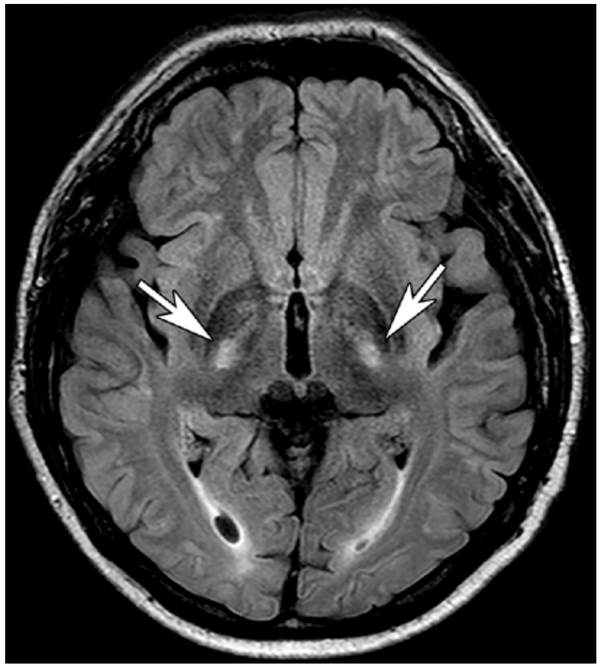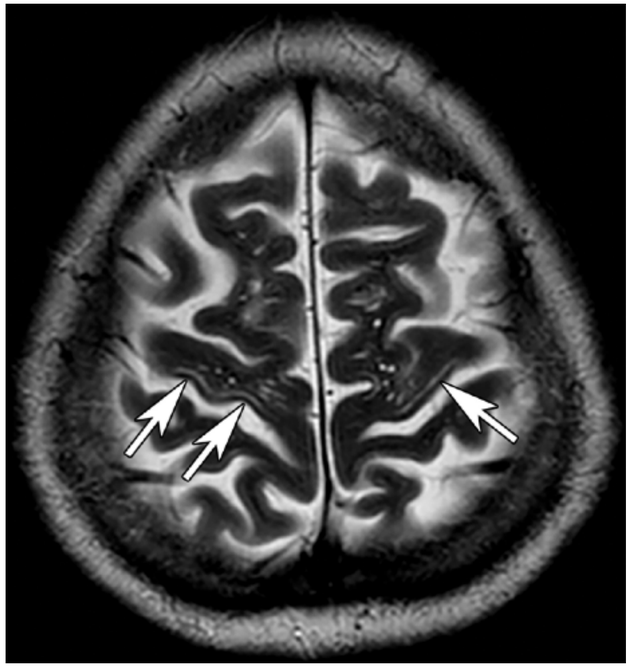
- corticospinal and perirolandic signal